ORTHODONTIA

AND

ORTHOPÆDIA OF THE FACE

BY

VICTOR HUGO JACKSON, M.D., D.D.S.

MEMBER OF THE NATIONAL DENTAL ASSOCIATION; PROFESSOR OF ORTHODONTIA IN THE DENTAL DEPARTMENT OF THE UNIVERSITY OF BUFFALO; FELLOW OF THE NEW YORK ACADEMY OF MEDICINE; MEMBER OF THE AMERICAN MEDICAL ASSOCIATION, ETC.

WITH SEVEN HUNDRED AND SIXTY ORIGINAL ILLUSTRATIONS

PHILADELPHIA AND LONDON
J. B. LIPPINCOTT COMPANY
1904

ELECTROTYPED AND PRINTED BY J. B. LIPPINCOTT COMPANY, PHILADELPHIA, U. S. A.

TO MY BROTHERS

DR. HARRY HAMILTON JACKSON

AND

DR. WALTER HINCKLEY JACKSON

THIS VOLUME IS

AFFECTIONATELY INSCRIBED

PREFACE

In writing this book it has been my purpose to present, in detail, yet in a concise and systematic form, a description of my methods of correcting irregularities of the teeth, and also to introduce a complete and original system for the orthopædic treatment of the face. I have aimed to treat the subject in such a manner as both to adapt it as a text-book for the student and to suggest methods of procedure for the active practitioner.

In 1887 I presented a simple wire device for the regulation of teeth which I termed a Crib.* The anchorage was gained by extending a spring-wire on the lingual and labial sides of the teeth near the gum, in some cases including all of the teeth, in others only a part of those in the arch; the spring on the labial and lingual sides was connected by passing wires over the arch at the junction of the teeth. Later I devised the Jackson system described. The anchorage is secured by spring-clasp attachments and partial-clasps, supporting a base-wire, to which any form of spring can be added.

The introduction of a new system necessitates new names, but an effort has been made to use those that will be readily understood, avoiding overfull descriptions and unnecessary technical terms.

In some of the chapters descriptions of a few well-known methods that have been used successfully by the profession are included. These are presented in order to assist practitioners who are using those methods and who are not yet familiar with the system of anchorage advocated in this work. The book contains four hundred and fifty pages of text, thirty-four insets, and an appendix including descriptive matter and forty-four page plates illustrating apparatus that has been used. There are in all eight hundred and one cuts, seven hundred and sixty of which are original with me.

Orthodontia has grown in importance until it has become a specialty of dentistry. It is engaging some of the most active and original minds in the profession. Opinions have been recorded, theories advanced and contested, until the literature of orthodontia has attained a volume proportionate to the importance of the subject.

---

* Jackson, Dental Cosmos, 1887, p. 375.

For many years I have applied in my own practice the principles explained in this book, and the results warrant me in giving a detailed description of my system. In the mean time I have been urging upon the profession, in writings and public demonstrations, the use of the spring as a force in regulating, and it is especially gratifying to note its more general adoption in place of screw-pressure.

Evolution is the law of our science as of other studies. To realize this, one has but to compare the methods of a few years ago with those of to-day. As it stands, my system of correcting irregularities includes important modifications of the appliances originally presented by me. The changes are in the line of simplicity and practicability.

In common with others who have devoted themselves to orthodontia, I desire to express my sense of obligation to the pioneers of the profession, who, working under disadvantages, have nevertheless done so much for dentistry and for humanity.

I freely give the results of my study to the profession. Beyond the copyright of this book, I reserve no exclusive rights in the system to which I have devoted years of thought and labor. I need not rehearse the perplexities and unforeseen obstacles which are at once the bane and the fascination of scientific research.

How far I have succeeded in conquering the difficulties in my path let others judge. The story of man's contest with the forces of nature is as old as the world. No one is more familiar with it than members of our profession, who work to relieve their fellow-beings of the consequences sometimes of misfortune, sometimes of folly.

Although no letters patent protect me in the material advantages of my system, I am not without a great reward; I shall find it in the knowledge that I have in a manner aided the work to which we give the best part of our lives, the best part of our knowledge. If my professional brothers find the system I have outlined a help to them in their practice, and a step along the road of progress, I am amply repaid.

I have endeavored to give credit to the authors for quotations and the appliances to which reference has been made. Acknowledgments are due Dr. J. O. Roe, the *Dental Cosmos*, *Items of Interest*, the *International Dental Journal*, and their editors for the use of cuts and other courtesies.

V. H. J.

New York.

CONTENTS

CHAPTER I

Etiology

CHAPTER II

The Alveolar Process

CHAPTER III

Occlusion and Articulation

CHAPTER IV

Examination of Patients—Record of Cases—Impressions—Models of Teeth—Cast of Features

CHAPTER V

Age for Regulation

CHAPTER VI

Extraction of Teeth for Relieving Irregularities

CHAPTER VII

Anchorage and Appliances

CHAPTER VIII

Wedging—Application of Force—Movements of the Teeth—Care of the Teeth and Appliances during Regulation

CHAPTER IX

Expansion of the Dental Arch

CHAPTER X

Contraction of the Dental Arch

CHAPTER XI

Incisors, to move Outward or Labially

CHAPTER XII

Incisors, to move Inward or Lingually

CHAPTER XIII

Incisors, to move Laterally

CHAPTER XIV

Incisors, to Rotate

CHAPTER XV

Incisors, to Depress—Shaping the Teeth

CHAPTER XVI

Incisors, to Elevate

CHAPTER XVII

Incisors, to move Bodily

CHAPTER XVIII

Prognathism

CHAPTER XIX

Receding Lower Jaw

CHAPTER XX

Lack of Occlusion

CHAPTER XXI

Cuspids, to move Outward—Forward in the Line of the Arch

CHAPTER XXII

Cuspids, to move Inward—Backward—Elevate—Depress—Rotate

CHAPTER XXIII

Bicuspids, to move Outward or in a Buccal Direction

CHAPTER XXIV

Bicuspids, to move Inward or in a Lingual Direction

CHAPTER XXV

Bicuspids, to move Backward in the Line of the Arch

CHAPTER XXVI

Bicuspids, to move Forward—To relieve Impaction—Elevate—Depress—Rotate

CHAPTER XXVII

Molars, to move Outward—Inward—Forward—Backward—Depress—Elevate

CHAPTER XXVIII

Retention of the Teeth

CHAPTER XXIX

General Orthopædia of the Face

APPENDIX

ORTHODONTIA

CHAPTER I

ETIOLOGY

The etiological factors that induce maldevelopment of the jaws and irregular positions of the teeth are divisible into two classes, *constitutional* and *local.*

The constitutional causes will be distinguished as *inherited* and *acquired.*

Some of the influences that effect these maldevelopments and irregularities are obscure. They are principally among the constitutional, the local causes being better understood.

Heredity.—The general law of descent from parent to offspring is nowhere more plainly shown than in the transmission of characteristics of the jaws and teeth. The inherited constitutional causes include the tendency of healthy persons to reproduce their peculiarities, whether normal or abnormal. These peculiarities are occasionally traceable through three or more generations, but they do not always appear continuously; they may pass over two or more generations and then reappear. Again, the children of the same parents may not all equally inherit the same constitutional tendencies. Figs. 1, 2, and 3 illustrate an interesting case of hereditary transmission of peculiarities of the features, from the grandfather to the daughter and to the granddaughter, the profile or general facial line being the same, with upturned pointed nose and receding lower jaw.

One of the most frequent causes of dental irregularity is the intermarriage of individuals of different race-characteristics. A common case is where the child inherits the small jaw of one parent and the large teeth of the other. There naturally being insufficient room in the arch for their free eruption, the teeth become crowded, spoiling the otherwise even contour and arrangement; or the opposite condition may occur, the large jaw of one parent and the small

teeth of the other being transmitted to the child, thus causing the interdental spaces to be unusually marked.

It is important that hereditary malformations of the child be corrected early, to prevent, as far as possible, their permanence, if not their recurrence.

Syphilis.—The influence of constitutional syphilis on developing osseous structures should have due consideration. The literature of the subject is so voluminous that the reader is referred to recent text-books.

There is a morbid constitutional condition affecting the lymphatic glandular system, generally termed *scrofula*. During childhood these glands undergo their greatest activity and development. Hence it is that the lymph-glands in the young are more prone to infection and alterations of nutrition than in adults. It is certain that a large percentage of deformities of the nose and jaws result directly or indirectly from malnutrition. At this time epithelial structures are also especially liable to take on disease.

Acquired Constitutional Causes.—Among the acquired causes of irregularity of the teeth and deformity of the jaws are those which are brought about by infection and by malnutrition and functional disturbances as exemplified in neuroses, scorbutus, and rhachitis, with nasal obstructions, adenoid vegetations, enlarged tonsils, hypertrophy of the tongue, etc.

Neurotic Tendencies.—As in all tissues, the nutrition of the bones and teeth is largely governed by and dependent upon the condition of the nervous system.

Kingsley says, in this connection,* "Laying aside all cases that may be due to an inherited tendency to follow or exaggerate some given type, together with those which are manifestly due to forces operating only after eruption, the primary cause, so far as the individual is concerned, of any general disturbance in the development of the permanent teeth, showing itself particularly in their malposition, is directly traceable to a lesion or innervation of the trigeminal nerve.

In 1869 Mummery called attention to the overtaxing of the active brain of children as probably a causal factor.† "According

---

* Kingsley's Oral Deformities, p. 21.

† Mummery, Transactions of the Odontological Society of Great Britain, 1869, p. 73.

Fig. 2.

Fig. 1.

Fig. 3.

to the best authorities, the most rapid increase in the size of the brain takes place before seven years of age ; and it must be remembered that the crowns of all of the permanent teeth, with the exception of the third molars, are in course of development simultaneously with this great advance in the size of the brain. May we not therefore reasonably suppose that through the diminished vitality consequent upon this diversion of the formative energy from the teeth, by premature mental exertion, these organs necessarily become degenerated; and that this circumstance constitutes one great difference between the teeth of the intellectual and those of the uncultivated families of mankind?"

The injurious effects of excessive mental activity on the developing child are being recognized by progressive educators, which lead us to hope that our school system and course of study may be so improved as to permit of a more normal physical development during this important period.*

Infantile Scorbutus.—Scorbutus is caused by depraved nutrition, usually resulting from improper feeding.† Symptoms of the affection are fretfulness, aversion to being handled, crying out as if in pain when lifted, tenderness of the lower limbs and indisposition to move them, swollen, spongy, bleeding gums, and progressive anæmia.

Rhachitis.—Rickets is a disease of childhood, due chiefly to deficient nutrition and bad environment. It is said to be inherited from the parents when one or both were affected with a cachexia or otherwise enfeebled condition. It has often been found, however, that the child has suffered from a lack of the vital stimuli, light, heat, air, and food, from the use of food unsuited to its age, or from a lack of phosphorus combinations in the blood, with a deficiency of lime salts in the bones. The lips are thin, pinched, and drawn ; there is retarded and painful eruption of the teeth, with unusual constitutional disturbances during dentition. Smith, who has had a large experience with rickets, states that it most frequently occurs at the age of six months to two years. Some years ago Roberts said that about thirty per cent. of children suffer more or less from rickets. Another authority has written : " One child in five is affected in good families." The early symptoms are fretfulness, tenderness on the

---

* Stuver, Dietetic and Hygienic Gazette, December, 1897, p. 784.

† Northrop, Crandall, Dental Cosmos, 1895, p. 503.

surface of the body, perspiration, general arrest of development, and bone-deformity later.

It will be observed, as we compare statistics, that there is but a slightly larger per cent. of cases that suffer with deformed nasal septi (which will be referred to later in this chapter) than are found to have been affected with some degree of rhachitis, and that a majority of cases of deflection of the septum appear at about the same time as when the deformity of the upper maxilla is first seen.

Roberts observes that in rhachitis* the flat bones are thickened from periosteal formation, especially near their growing edges, as well as softened. Green states that "The zone of the cartilaginous tissue, which in health while being transformed into bone is very thin, in rhachitis is greatly thickened beneath the periosteum." The alteration of the bones, according to Jenner, consists in an increased preparation for ossification, but an incomplete performance of the process.†

Fig. 4.

Human Skull, with Teeth removed.—A, junction of the two maxillary bones; B, centre line of second molar tooth; C, line of outer border of masseter muscle; D, outer border of zygomatic arch; E, lowest border of malar process of left superior maxillary bone.

Effects of Muscular Action.—The effect of the muscles on the bone and alveolar process, when there is a lack of density of those tissues, as in rhachitis, is often noticeable, causing malformation of the jaws and irregular positions of the teeth.‡

In Fig. 4 it will be seen that the distance from the junction of the maxillary bones, A, to the centre of the grinding surface of the second molar, B, is about the same as from the centre of the molar B to the

---

* Roberts, Theory and Practice of Medicine, p. 274.

† Jenner, On Rickets, Tuberculosis, Abdominal Tumors, 1895, p. 13.

‡ Jackson, Dental Cosmos, 1890, p. 289.

line of the outer border of the masseter muscle C. The action of this powerful muscle drawing downward on the zygomatic arch D, to the anterior two-thirds of which it is attached, combined with the action of the buccinator and temporal muscles, causes an upward pressure of the lower jaw against the superior maxilla at B. If there is a lack of density of the bones, as from rhachitis or other condition, the downward traction of the buccinator and masseter muscles on the outer surface of these bones will naturally cause a tipping towards each other of the lateral halves of the upper maxilla. The bones yield, and the anterior curve of the jaw is narrowed laterally, producing the V- or saddle-shaped arch, typical forms of which will be seen in Figs. 16 and 18.

This settling together of the lateral halves of the maxilla at the time the jaws should be developing results in the lateral constriction of the nares; and at the same time, the consequent arching upward of the palatine portion of the jaw further tends to constrict the apertures. In these cases we usually find the nasal processes of the superior maxillary bone bulging forward, the palatal portion excessively vaulted and thickened, the septum of the nose deflected, and the outer border of the supra-orbital arch sloping downward more than usual from the horizontal. It is to be borne in mind that the alveolar process will follow and support the teeth in any position that the teeth may be caused to assume.

Aside from diseases of the nasal organs and from hereditary tendencies, it is thought that these derangements most frequently occur as a result of an early rhachitic condition, an improved nutrition or degree of health being attained afterwards, the malformation persisting.

Analogous to the softened condition of the developing bones during rhachitis, teeth often have a depressed mark or sulcus across their surface, in which mark the structure is less dense than on either side. Its width indicates the checking of development during the course of some acute disease that interfered with nutrition. Third molars or wisdom-teeth at the time of eruption are also deficient in calcific deposit, their development taking place during the time of the extensive growth of the bony frame, and the teeth therefore receiving a lessened nutritive supply. These conditions are especially noticeable in the poorly nourished, but later in life wisdom-teeth become more dense, and when cared for often prove as strong or stronger than the adjoining ones. In the aged person they are

generally found doing service after the rest of the teeth have yielded to the ravages of time.

Fig. 5 represents a skull with the malar bone and a portion of the malar process removed, exposing the antrum of Highmore. It has been stated that the frontal sinuses, ethmoidal and sphenoidal cells, and a hollowing out of the malar bone for the antrum are seen about the second year after birth. Mayer * states, "The order in which these sinuses appear is as follows: 1, Maxillary at the fourth fetal month; 2, ethmoidal at the seventh fetal month; 3, sphenoidal at the third year of life; 4, frontal at the seventh year of life. The maxillary antrum is well defined at birth, but undergoes little change until the second dentition, the sixth to eighth year, from which date it develops rapidly in common with the facial bones."

Fig. 5.

Human Skull, with Malar Bone removed.—A, orbital ridge; B, spheno-maxillary fissure; C, antrum of Highmore; D, pterygoid process of sphenoid bone; E, temporal portion of zygomatic arch; F, auditory canal; G, mastoid process.

From birth to full development there is a constant change in the structure; bone is deposited on the outer surface with an absorption of the inner surface. The absorption is slow, and the walls do not reach their normal thinness until after the age of maturity. This is important when we consider how often disease attacks the nasal tissues, and its effect on the developing bone while these changes are taking place, including cases where there is an inharmonious development of the frontal and other cranial bones.

In Figs. 6 and 14 it will be seen that the principal anterior growth of the upper maxilla takes place at the suture at the anterior edge of the palate bone D. This bone forms a portion of the roof of the mouth, floor, outer wall of the nose, and floor of the orbit. It is attached by suture to the pterygoid process of the sphenoid bone on either side by a tuberosity or elongated wedge, projecting back-

* Mayer, Medical Record, August 10, 1901.

ward into the pterygoid notch. The pterygoid process (F) is practically a fixed point, in front of and near which the anterior development of the true maxilla takes place. The sphenoid is termed the key of the cranium, as it articulates with all of the cranial bones, and also, directly or indirectly, with the bones of the face. As we examine the skull, we find that the lateral growth of the sphenoid harmonizes the width from side to side of the posterior portion of the upper and lower maxilla, as no doubt it does other dimensions of the skull. The lower maxilla has a temporo-maxillary articulation. Its width is governed by the lateral growth of the greater wings of the sphenoid, which increases the distance between the glenoid fossæ to which the condyles of the jaw are attached. The width of the distal part of the upper maxilla is governed by the lateral growth of the body and greater wings of the sphenoid in connection with the outward movement of the pterygoid processes.

Fig. 6.

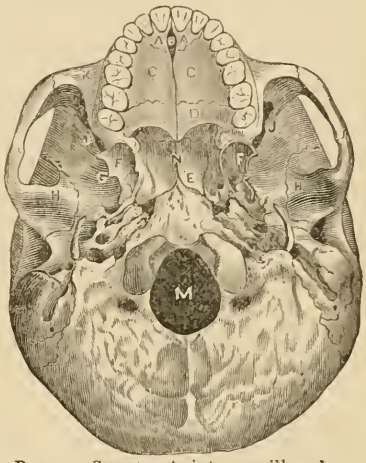

Base of Skull.—A, intermaxillary bone; B, anterior palatine canal; C, palate process of superior maxillary; D, palate bone; E, body of sphenoid bone; F, pterygoid process of spenoid; G, great wing of sphenoid; H, location of glenoid fossa; J, spheno-maxillary fissure; K, malar process of superior maxillary; M, foramen magnum; N, nasal septum (vomer). (Gray.)

The jaws are increased by building additional bone and process on the outer walls. Bones are the framework to which the muscles are attached as stays, and over which the integument is drawn. I believe, from the anatomy of the jaws, and from the large number of mouths it has been my fortune to examine and study, including both the so-called saddle- and V-shaped arches, that the muscles of those regions play not a small part in connection with other influences referred to in this chapter, in causing their variation from the normal type of development.

The tissues of the cheeks, lips, and tongue are looked upon as a matrix that influences to a large extent the form of the dental arch. This view has been advanced by anatomists and histologists for years, and is held by a majority of the profession.

When the tongue is at rest in its natural position within a normal

arch of teeth, it is forced forward, *with the dorsum in contact with the roof of the mouth* and the tip curved downward behind the lower and upper incisors. The influence of the tongue in shaping the arch and equalizing the jaws can be estimated to some extent by the pressure caused on the teeth in the act of swallowing.

Fig. 7.

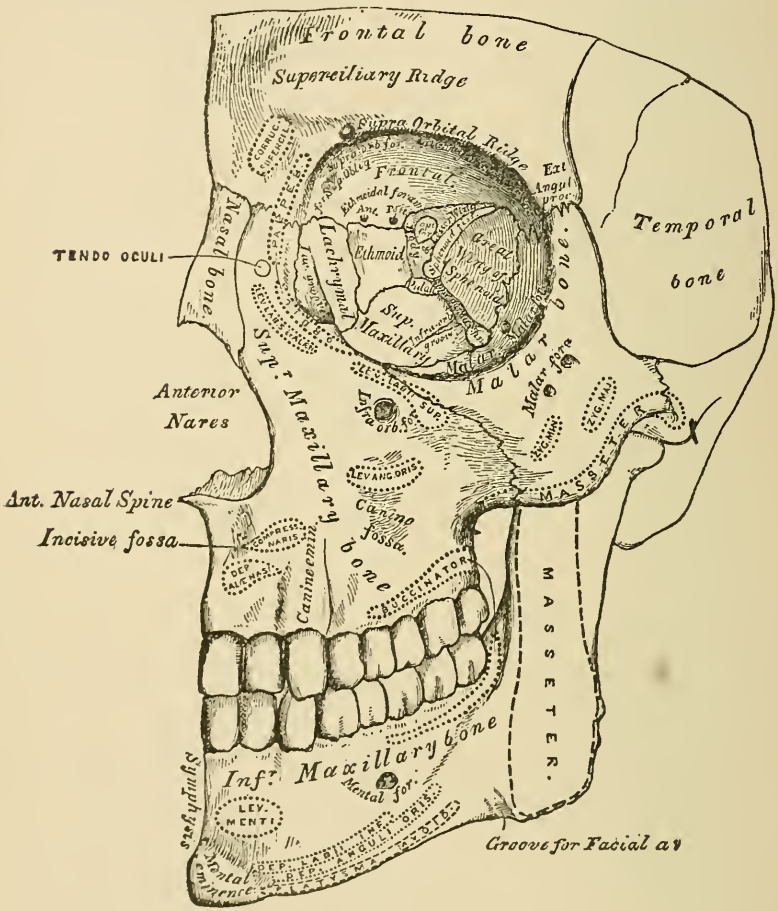

Anterior region of skull. (Gray.)

It will be observed in the aged, when from the early loss of the teeth the process is much absorbed, that while the tongue is at rest it is broadened, so that the edges and the tip are in contact with the cheeks and lips. In mouth-breathing, the jaws being separated, these tissues not only press unequally on the developing osseous structures,

but the tongue is taken away from its normal position, being drawn downward, removing the inner part of the matrix or support from the upper arch. The outer matrix consists of the muscles and other tissues of the lips and cheeks. All muscles have a natural tonicity. The orbicularis oris is a sphincter muscle. When the lips are closed it is at rest; when the mouth is open, as in mouth-breathing, the orbicularis oris, the buccinator, and other muscles are put on the stretch. Many of the fibres of these muscles blend.

The origin and insertion of the buccinator muscle are from the outer surface of the alveolar process of the upper and lower jaws (Fig. 7). In mouth-breathing, the jaws are separated, and the consequent unnatural continuous tension of this muscle on the outer walls of the alveolar process of the jaws changes their form, elevating the teeth of this region and tipping them inward. This is sometimes more apparent with the teeth of the lower arch.

The changing of the process in this manner, causing elevation of the teeth, may be confined to the distal part of the arch, the extrusion of the teeth causing lack of anterior occlusion. In other cases of mouth-breathing there is also a drawing downward of the muscles on the process in the anterior part of the arch, causing a general elevation of the teeth.

The orbicularis oris is composed of concentric fibres which surround the orifice of the mouth (Fig. 8). It consists of two thick semicircular planes of muscular fibre, which interlace on either side with those of the buccinator and other muscles inserted into the lips. To both the upper and the lower segments some special fibres are added, by which the lips are connected directly with the upper and lower maxillary bones and to the septum of the nose. The additional fibres for the lower segment arise from the inferior maxilla, externally to the levator labii inferioris. Those of the upper segment are of four bands, two arising from the alveolar border of the upper maxilla opposite the incisor teeth, and two connecting the upper lip to the septum of the nose, one on either side. When the mouth is held open continuously, as in mouth-breathing, the dragging of the muscles on the process gradually elevates it with the teeth, sometimes lengthening the features and making it difficult to close the lips, or causing an excessive lap of the teeth in occlusion, at the same time pulling downward on the nose. In Fig. 3 is illustrated a case of contraction of the muscles in the effort to close the lips,

causing extreme downward traction on the soft tissues, elevating the teeth, and also drawing down on and distorting the nose. This is

Fig. 8.

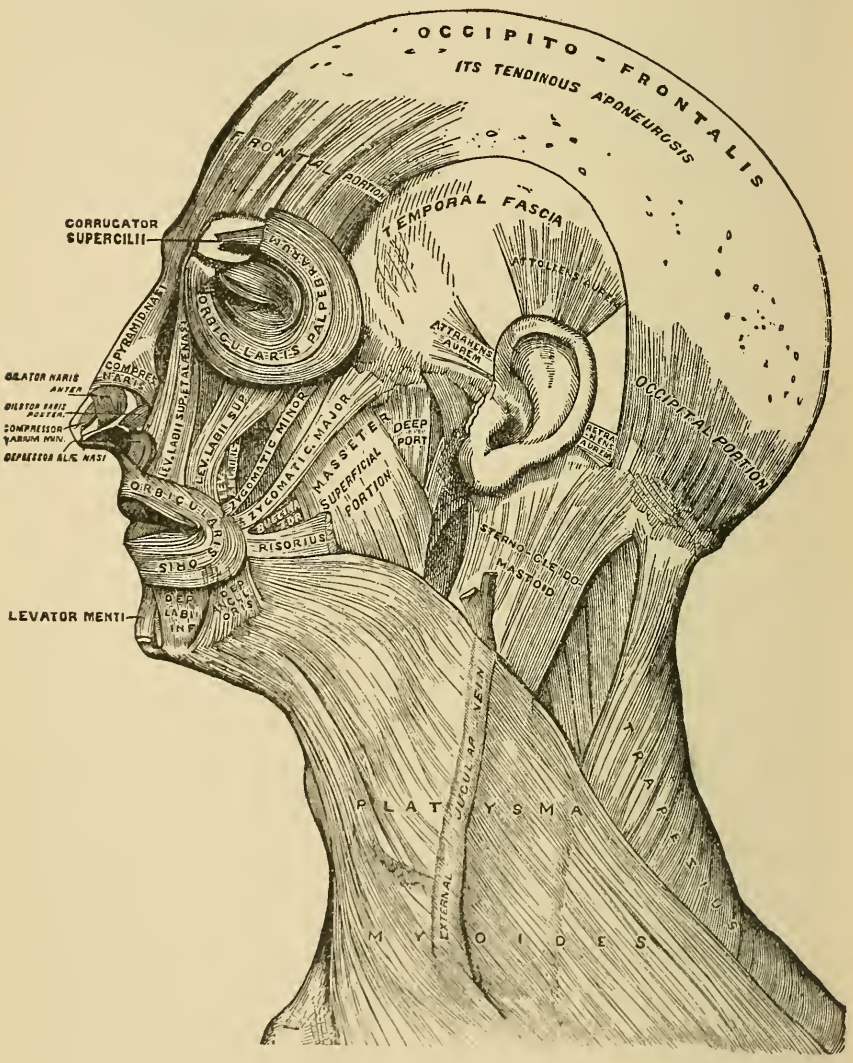

Muscles of the head, face, and neck. (Gray.)

relieved by depressing the teeth in their sockets, thus permitting the lips to close more freely. On the other hand, the set expression of the lips, from their resting too firmly together, usually results from

excessive loss of the occlusal surfaces of the teeth from abrasion, or from the depression of the occluding teeth with the process.

That the orbicularis oris and buccinator muscles act in harmony is shown by the action of the buccinator in chewing hard substances on one side of the mouth, when at each contraction the lips are drawn towards that side. It is the contraction of these muscles that causes the dimple in the cheek.

As the healthy tonicity of the muscles produces a natural tension in them even when at rest, we should not underestimate their power to influence developing bone. This natural tonicity of the muscles is more noticeable in some individuals than in others. That these tissues tend to influence the curve of the arch and position of the teeth is further illustrated in cases where one or more teeth have been removed on one side to relieve an overcrowded arch, and the central incisor of the opposite side has been forced far over the median line towards the space caused by extraction, with the circle of the arch still preserved. Another example is where the wisdom-tooth has erupted towards the cheek, in which case it is gradually directed by the pressure of the muscle to its normal position. Also when the muscles are paralyzed on one side of the face by an arrest of the nerve-stimulus, the soft tissues are drawn towards the other side of the face by the natural pull of the muscles not affected.

The influence of the lips, cheeks, and tongue on the developing arch can be understood by noticing their position in the edentulous, the lips being always turned inward; and the natural contraction of the lips often presses backward full plates of artificial teeth that have been adjusted, where there is much absorption in either the upper or lower jaw, so that the plates have to be readjusted with a view to this pressure. The contraction of scar-tissue draws on, and in some cases changes materially, the form of the process and position of the natural teeth. The continued traction of the congenitally shortened frenum often alters the process, and there may be a lack of symmetry of the skull of the babe which has become flattened from being allowed to lie more on one side than on the other.

Virchow, in speaking on the influence of the muscles on the pelvis when the bones are softened from rhachitis, says, "All these changes are to be attributed to the traction of the muscles and ligaments, as well as to the partial stoppage in the development of bone."

Fleischmann accounts for the changes in the shape of the lower and the upper jaw by the contraction of the muscles.*

Mouth-Breathing.—The general causes of mouth-breathing and its detrimental effect on the development of the nose and maxilla will now be considered. Mouth-breathing becomes a habit from necessity. The partial occlusion of one or both nasal fossæ from any cause is likely to make the patient a mouth-breather. It is the duty of the practitioner to direct the attention of parents to the inevitable troubles that will arise if the impediment to free nasal respiration is not removed so that the child may breathe freely through the nose.†

Mouth-breathing is usually accompanied with a disease of the glandular structures in the naso- or oro-pharynx. The posterior portion of the mouth has a chain of glands known as Waldeyer's ring. These consist of the faucial tonsils, the lingual tonsils, and the third or Luschka's tonsil, familiarly known as adenoids.

Enlarged Tonsils.—Chronic enlargement of tonsillar tissues is one of the causes of mouth-breathing. It is a disease of child-life. Some authors claim that enlargement of these glands has been observed in children born even before term, indicating direct heredity; others think that it is not congenital. Enlargement of the faucial tonsils is said to occur more frequently in the male. Rice says, "Ninety per cent. of the class of cases termed mouth-breathers in children are not simple ailments of catarrhal disease of the nose, but are evidences of obstruction which prevents nasal respiration. This obstruction is largely due to the presence of enlarged tonsils."‡ Hypertrophy of the lingual tonsil does not generally become evident before the age of sixteen. It occurs more commonly in the female. Hypertrophy of the pharyngeal or Luschka's tonsil will be considered under adenoid growths.

It is my opinion that the same systemic conditions that bring about an enlargement of these glands are operative in inducing some of the other conditions found in nasal stenosis that often accompanies them. Such are rhinitis, deflection of the septum, and maldevelopment of bones, each of which will be considered in its place.

---

* Ziemssen, Cyclopædia of the Practice of Medicine, Supplement, p. 109.

† Jackson, Dental Cosmos, 1890, p. 289.

‡ Rice, Medical News, February 4, 1899, p. 157.

Rhinitis.—Chronic rhinitis, or inflammation of the membranes of the nose, due originally to some form of infection, influences the adjacent developing bony structures, either stimulating or arresting their growth according to the activity of the affection.

In the lighter forms of rhinitis the natural blood supply is stimulated, adding to the nutrition, particularly at the sutures. This may result in an increased growth which may be shown in the prominent maxilla.

In the pronounced forms of rhinitis the membranes are thickened, interfering with nasal respiration. There is more congestion and stagnation of the circulation. The nutrition is interfered with and the vessels become much enlarged, resulting in partial or general arrest of development of the bone and alveolar process. This is not uncommon. It may be apparent in the flattened and sunken appearance of the middle third of the face in the region of the nose.

True inflammation of the mucous membrane results in hypertrophy of the connective tissue. Of one thousand cases that presented themselves for treatment at a New York Eye and Ear Infirmary, seven hundred and seventy-one were found to be suffering with some form of rhinitis.

Fig. 9.

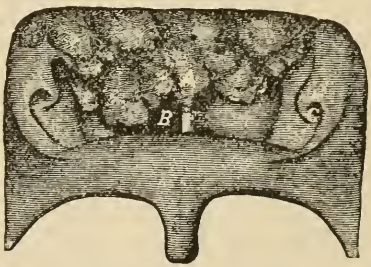

Adenoid growths in the upper part of the pharynx (*A*), obstructing the nasal passage (*B*), and encroaching upon the Eustachian tube (*C*). (Lefferts.)

Adenoid Growths, or Hypertrophy of the Lingual or Luschka's Tonsil, as a Cause of Nasal Obstruction.—Adenoid growths are rounded elevations of hypertrophied tissue found in the vault of the oro- or naso-pharynx (Fig. 9). They are the result of inflammation of the lymphoid tissue. Gleitsman* describes the chain of lymphatic glands as appearing in an aggregated as well as a disseminated form, and distributed uninterruptedly throughout the pharynx and nasopharynx.

Especial attention was first called to these abnormal growths by

* Gleitsman, Hyperplasia of the Lymphatic Tissue of the Pharynx and Nasopharynx, Medical News, January 19, 1889, p. 62.

Wilhelm Meyer, of Copenhagen, in 1870.* He gave to them the name Adenoid Vegetations in 1868.

He described two forms, the cristate, covering the posterior walls of the pharynx, especially the upper curved part back of the soft palate, and the cylindrical, occupying the lateral walls. The growths may be brittle, hard or tough, and at times soft and friable, but are all composed of the same adenoid tissue.

Meyer states that the mucous secretion from the adenoid vegetations is commonly abundant, and the tissue around them is always in a state of chronic catarrh. The neighboring parts covered with mucous membrane are usually found in an abnormal state, as the Eustachian tube and the middle ear, the turbinated bones, the soft palate, and the tonsils. The growths obstruct the posterior nasal orifices, as seen in Fig. 10, *A*. The obstructions may give rise to any of the following characteristic complications: in infancy, interference with nursing; later, narrow nasal orifices, dull and stupid facial expression (Figs. 11 and 12), breathing through the mouth, especially at night, snoring, sucking the air, "dead" pronunciation, languor, and irritability. The "dead" speech is composed of two constituents,—first, the impossibility of pronouncing the nasal sounds, m, n, ng; secondly, the loss of resonance in the anterior and posterior nares.

Fig. 10.

Adenoid development (*A*), interfering with nasal breathing by closing the upper part of the pharynx. (Delavan.)

The predisposing causes are youth, heredity, malnutrition, and frequently coryza, measles, and local irritations.

It will be remembered that the chronic congestion accompanying

* Meyer, Transactions Medico-Chirurgical Society, London, 1870, vol. liii.

Fig. 11.

Boy. Characteristic facial expression caused by adenoid vegetation. (Hooper.)

Fig. 12.

Girl, aged twelve years. Characteristic facial expression caused by adenoid vegetation. (Hooper.)

these growths is sufficient to affect the nutrient supply of the sutures or edges of the bones where the expansive growth takes place (Fig. 6). If these conditions are not corrected, it may result in ill-developed bones of the face, narrow nasal chambers, deformed upper jaw, high palatine narrow dental arch, irregular positions of the teeth, misshaped chest walls, middle ear disease with deafness.

Usually the symptoms are sufficient for the diagnosis, but frequently there are complications which require a physical examination to be made, with a suitable mirror, or with the index-finger. Mayer* has called attention to the ready diagnosis of this affection by inspection of the pharynx. He finds, in all unoperated cases, the pharyngeal wall to be the seat of small follicles, identical with the follicular pharyngitis of adults, and their presence leads him invariably to a diagnosis, without the introduction of the finger, which is exceedingly annoying to a child.

It is noteworthy that the removal of the nasal obstruction improves the general health and bodily weight to a remarkable degree.

It is claimed by Frankenberger† that in deaf mutes there is a much larger percentage of adenoids than in the general run of children.

Frankel denies that the lymphoid tissue is more common with the high arch palate than with the normal.

The late Dr. F. H. Hooper, in 1888-89‡, called attention to the defective development of the upper maxilla associated with adenoid vegetations, especially to the high palatine arch, and stated that imperfect nasal respiration in the child means imperfect health and imperfect development, and that "the immediate and remote effects of adenoid vegetation depend chiefly upon the mechanical obstacle which they offer to the passage of air through the natural respiratory channels." He also referred to the necessity of their early removal on account of the injurious effects on the development of the bone and the general health of the child, and quoted as follows:

"Dr. Chatellier, of Paris, in 1886,§ called attention to the deformi-

---

* Mayer, Transactions American Laryngological Association, 1903.

† Frankenberger, Annals of Otology, Rhinology, and Laryngology, 1897, p. 395.

‡ Hooper, Boston Medical and Surgical Journal, March, 1888.

§ Chatellier, Des Tumeurs Adénoides du Pharynx, Paris, 1886.

ties of the head and face resulting from neglected adenoid growths. He pointed out that the air cavities, as the frontal, sphenoidal, and ethmoidal sinuses, and the antrum of Highmore, being normally in communication with the air, cease to develop when the circulation of air through the nose is interfered with, and alters the proportions of the face. The lower jaw, which follows its normal development, often protrudes over the upper jaw, which is contracted in front, the upper lip is drawn up, while the hard palate, from the constant atmospheric pressure within the mouth, is pushed upward, terminating in a sharp angle like the gothic arch. It does not seem at all unlikely that the many cases of deafness due to ankylosis of the ossicles, or other structural changes in the middle ear, and which are associated with the V-shaped palatine arch and contracted upper jaw, are the remains of these adenoid growths, which accomplished their destructive work early in life undiscovered and unsuspected."

Fig. 13.

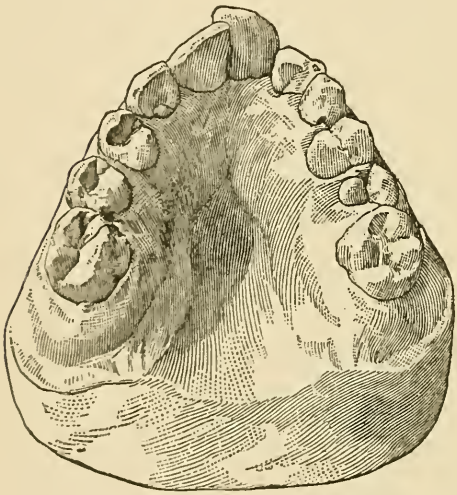

Contracted arch caused by adenoid vegetation. (Hooper.)

Figs. 11, 12 and 13, with others, were used by Dr. Hooper to illustrate the facial characteristics, the position of the teeth, and the shape of the jaws of special cases that were presented at the Throat Department of the Boston City Hospital.

Deflection of the Septum as a Cause of Nasal Obstruction.—The nasal septum is a thin vertical partition formed principally with the vomer, the perpendicular lamella of the ethmoid bone, and a cartilage of triangular shape, which separates the nasal fossæ from each other, and hence is spoken of as the cartilaginous and bony septum.

Delavan remarks, "The septum is destined to serve as a prop, pushing apart the upper maxilla from the base of the skull, and

when it is crowded upward by the hard palate until it can no longer resist the pressure brought to bear upon it, deflection results. . . . A diagnostic sign of an habitual mouth-breather is a high arch and a narrow, hard palate, associated with deflection of the nasal septum."* We also usually find in these cases a projecting forward of the nasal prominences of the upper maxillary bone.

Deflection of the nasal septum is important to us, because, first, it is considered a cause of mouth-breathing; secondly, it is generally associated with the saddle- and V-shaped arch. It is estimated that from thirty to fifty per cent. of the European races have more or less deviation of the septum. "In the examination of hundreds of specimens of the American Indian, it is difficult to find a case of marked deflection." However, in my examinations of a considerable number of skulls in museums, in those from the tribe known as the Flatheads a marked deflection was found; caused, probably, by the external mechanical downward pressure on the frontal and ethmoidal bones.

The septum is first seen deflected in about the seventh year, but the two lamellæ do not unite until about the age of puberty. Robertson examined one hundred and sixty children, from two to ten years of age, and found only seven deformities of the septum, four of these with a history of injury; but in a total of seventy-two children, between ten and twenty years of age, were found twenty-two deformities. In some districts a much larger percentage of children than this suffer with deformed nasal septi. There is no record in this report of the condition of the teeth and jaws, but it will be seen that the early deformity of the septum appears at about the time of the eruption of the permanent teeth. Delavan states, "Deflection of the nasal septum proper may be due either to trauma or improper nutrition, usually the latter," and "Palate deformities come from atmospheric pressure, from the occlusion of the nasal passages, creating in them, through the act of inspiration, a partial vacuum, and thus changing the equilibrium of the pressure upon the upper and lower aspects of the roof of the mouth." To this atmospheric pressure are also attributed many of the serious inflammations of the membranes of the nose, Eustachian tube, and inner ear.

Deflection of the septum, like the high vault of the superior max-

* Delavan, Transactions American Laryngological Association, 1887, p. 202.

illa, is more common in the highly civilized. It is readily diagnosed; there is usually much external deformity, the nostril on the affected side is occluded (for it is usually one-sided, though it may be double), and there is a corresponding concavity on the unaffected side. If the subject is directed to obstruct each of the nasal openings separately, and to blow, a free current of air will pour out of the cavity on the unaffected side, while a very thin current of air or none at all appears at the occluded side.

Ziem, of Germany, in his experiments on growing animals to determine the cause of nasal stenosis, obstructed one nasal orifice,

Fig. 14.

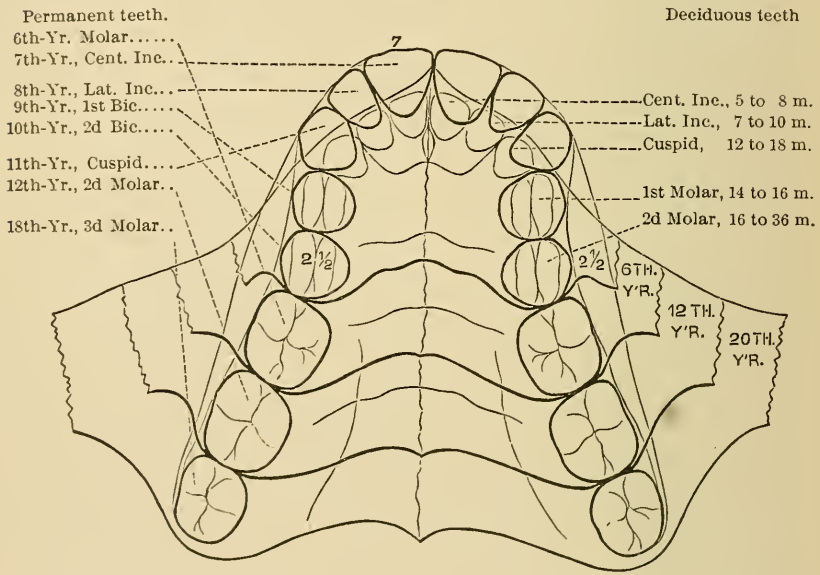

A drawing to illustrate the progressive normal development of the upper maxilla and that of the saddle- and V-shaped arch, the time and order of the eruption of the deciduous and permanent teeth, etc.

thus withdrawing the normal nutrition from that one, contrasting it with its fellow. As a result, which illustrates the effect of stenosis on the development of the bones, there was observed a deviation of the intermaxillary bone and the sagittal suture towards the occluded side, a shortening of the nasal bone, frontal bone, horizontal plate of the palate bone, flattening of the alveolar process, and a reduction of the distance between the auditory canal and the alveolar process, as well as between the zygomatic arch and the supra-orbital border.

Normal and Abnormal Dental Arch.*—The accompanying drawing, Fig. 14, is intended to guide the student to a clearer comprehension of the progressive stages of development of the maxillary bones, the time and order of the eruption of the teeth, and to a more definite understanding of the causes of the changes from the normal to the abnormal arch. To fully comprehend and fix the variations in mind, one should make a similar drawing, first outlining the normal shape of the arch of a child, and pencil successively the deciduous teeth in place in the order of their development, noting the average age at the time of the eruption of each as seen at the right of the drawing. On the left side, note the usual order and the approximate time of the eruption of the permanent teeth. The first permanent, or sixth-year molars are added to the drawing in their respective positions, and the lines representing the additional development of the anterior border of the malar processes of the superior maxilla are continued outward at the same angle. The lines to represent the posterior border of the palatal bones, malar processes, and sutures connecting the malar bones are then made. These lines represent the extent of the growth of the bones from the time of the eruption of the second deciduous molars, at about two and one-half years, to that of the first permanent molars, at about the sixth year.

The permanent central and lateral incisors are then sketched in position in advance of the deciduous ones, according to the lines of the arch which it is intended to represent,—either the normal, the the saddle-, or the V-shaped arch, or their variation. After this, the outlines of the first and second bicuspids are marked in place of the deciduous molars. These are followed by the insertion successively of the permanent cuspids, second and third molars, with the proper enlargement of the other portions of the drawing.

V-Shaped Arch; Anterior Protrusion of the Teeth.—The marked influence on the shape of the upper arch by the *intermaxillary* bone which supports the incisors, and the growth of which is normally active at the time of their eruption, should receive careful consideration. The development may be stimulated, or arrested by interference with its nutrition, which is common with nasal affections.

It will be observed that the anterior palatine fossa or canal at

---

* Jackson, Dental Cosmos, 1890, p. 292.

birth is just posterior to the central incisors, and, after all of the permanent teeth are erupted, it is found some distance from them. This change is accounted for by the anterior growth of the intermaxillary bone and the process. In specimens of the V-shaped arch, where

Fig. 15.

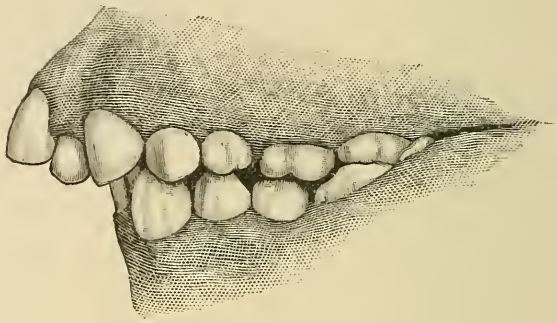

the upper incisors were much too prominent, the fossæ were found at a greater distance back of the teeth than in either the saddle- or normally shaped arch.

The lateral incisors in their alveoli occupy a position slightly posterior to the line of the central teeth, and erupt several months later. It often occurs that the time of the eruption of the laterals is delayed and they assume a position somewhat posterior to the centrals, which they force forward with the process (Fig. 15).

Fig. 16.

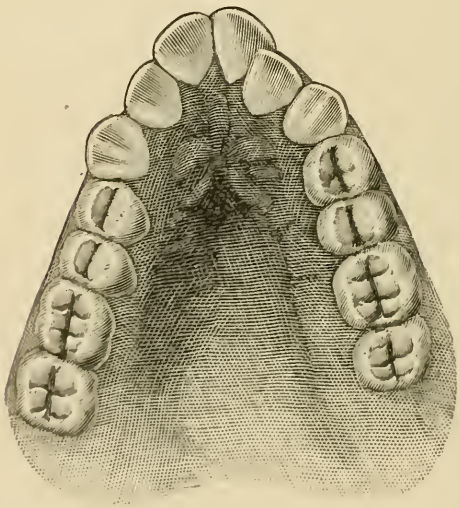

The incisors may take an imbricated position, one overlapping the other, or both of the centrals may be forced forward together, their mesial surfaces resting in contact near their incisive edge. This tends to rotate them outward, and when the permanent cuspids are erupted, they wedge their

way into place, causing the incisors and process to become still more prominent without a corresponding lateral development of the premaxillary. This usually results in a partial or complete V-shaped arch with high vault (Fig. 16).

The lower arch seldom assumes a V-shape. Fig. 17 illustrates a case with this condition, which was accompanied with a V-shaped upper arch.

Dr. J. Solis-Cohen has called attention to exostosis of the hard palate in connection with the arching of the roof of the mouth. This is often found more or less marked, and in some cases with a bony ridge on either side of the septum along the line of the suture. Generally these conditions are accompanied with stenosis.

Fig. 17.

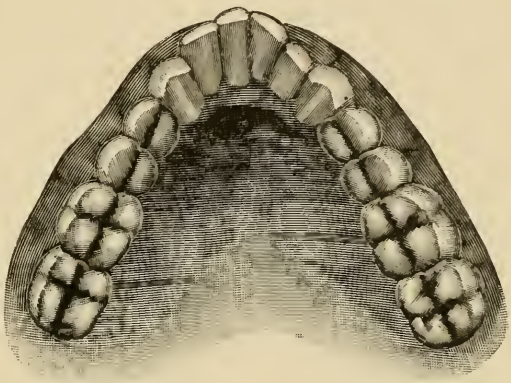

Anterior protrusion of the teeth may result from various influences.

The excessive development of the bone and process that support these teeth, as has been shown, may be the result of heredity, or of an acquired constitutional condition. Many references and suggestions regarding these conditions are found in other parts of this chapter.

Local Causes of Protrusion.—Under local causes of protrusion may be mentioned the too long retention of the deciduous superior incisors, causing the permanent incisors to erupt in front of them; and the injudicious extraction of the inferior deciduous or permanent molars, which interferes with the anterior development of the lower jaw, while the upper arch is allowed to attain its normal development, giving the effect of abnormal protrusion. Sucking or biting the lower lip, or the continued resting of the upper incisors on the lip, all have their influence in moving the upper incisors outward. The last is especially important, as the upper incisors are always gradually forced farther forward when the lower lip rests underneath them.

Saddle-Shaped Arch.—In the saddle-shaped arch, both the alveolar process and the teeth in the region of the bicuspids and first molars are pressed towards the median line, and in some instances one or more of the teeth are forced to erupt entirely inside of the circle, with the space closed as seen in Fig. 18. Generally the saddle-shaped arch is not apparent before the time of the eruption of the bicuspids. It may be the result of heredity, an acquired or a local influence.

I had recently under treatment a marked case of saddle-shaped lower arch with deciduous teeth, in a child aged seven years. He was a mouth-breather, due to enlarged tonsils and lymphoid vegetations.

The prominence of the malar process of the superior maxillary bone extends as far forward as the first deciduous molar, and in the adult it usually shades out opposite the second bicuspid. The downward traction of the masseter muscle on the zygomatic arch (Fig. 4, *D*), in connection with the action of the buccinator muscle, causes at the same time a lateral pressure towards the median line, and, especially when there is a lack of density of the bones from malnutrition, the malar process, which is of true bone, and therefore naturally harder than the alveolar structure, tends to press the teeth of this region with the alveolar process towards the median line of the arch. It is this prominence of true bone which remains in the edentulous after partial absorption of the alveolar process, and not uncommonly interferes with the wearing of artificial dentures. It sometimes complicates the operation of expanding the arch, as true bone is not absorbed so readily as the alveolar process, and the roots of the teeth are forced over it, which elongates them. The traction of the buccinator in connection with other muscles in mouth-breathing has an influence on the form of both the upper and lower arches. The origin and insertion of the buccinator muscle is, as we have seen, to

Fig. 18.

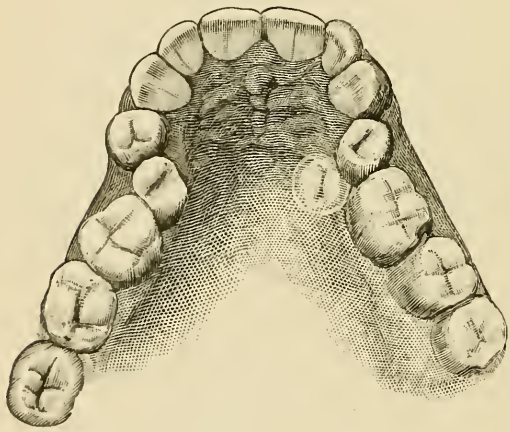

the outer border of the alveolar process opposite the bicuspid and molar teeth (Fig. 7). Its action when the jaws are separated in mouth-breathing sometimes tips these teeth inward and elevates them with the process. This is often especially noticeable at about the time of their eruption.

The saddle-shaped arch is more commonly seen in the upper than in the lower arch. It is usually accompanied with nasal obstruction and enlarged tonsils. When it is the result of a *local cause*, it is generally from the deciduous cuspids or molars having been lost prematurely, and the permanent cuspids taking their position before the eruption of the bicuspids. When it is time for the bicuspids to erupt, there is insufficient space, and they are crowded towards the median line or towards the cheek.

Sometimes the bicuspids are erupted in good line, and later one or more of them are forced towards the outer or inner side of the arch. These conditions are not infrequently met with in the lower arch, when, from lack of harmony of the jaws, the upper incisors cause excessive inward pressure on the lower incisors and cuspids, as is the case when teeth have been extracted on the sides of the upper arch, and none from the lower. Again, when excessive and continued mechanical force is applied, especially with an external apparatus, to reduce the prominence of the anterior upper arch, thus forcing the front teeth inward against those of the lower arch, the pressure is likely to induce a saddle-shape by crimping the line of the lower arch in the region of the bicuspids. Sometimes it causes crimping of the bicuspid teeth in the upper arch.

Prognathism.—Prognathism is an abnormal protrusion of the jaws. As generally applied in orthodontia, the term refers to abnormal protrusions of the lower jaw. The excessive development may be hereditary, or it may be brought about by acquired or local causes. It is progressive in development, and should usually be placed under treatment early in order to prevent the resultant facial deformity. In some instances it is observable before the eruption of the permanent teeth ; but it may not become apparent before the tenth or twelfth year, or even until later in life.

Heredity.—The tendency to prominence of the jaws is usually transmitted from the parent, the characteristic being traceable through two or more generations.

A marked prominence of the lower jaw of a child, Miss A., aged

five years, is shown in Fig. 19. The lower deciduous incisors closed in front of the line of the upper incisors. In taking the history, it was learned that each of the parents had a prominent lower jaw. An examination was made, and it was found that the child was suffering from both nasal and faucial obstruction. The case was referred to a rhinologist, with instructions to return with a report from the physician when he had completed his treatment. It was hoped that the improvement of the air-passages, permitting more free nasal breathing, would prevent any further excessive development of the lower jaw. Five years, however, elapsed before the patient returned. The parents had not had the obstructions removed as advised, and a pronounced protrusion of the lower jaw had taken place. This was accompanied by a partial arrest of development of the bones of the upper arch, and the permanent upper incisors had taken an irregular position. The parents were again advised to have the obstructions removed; the operation was performed; later, the upper incisors were regulated, and a chin-cap applied in the manner shown in Fig. 398, which reduced the prognathous condition.

Fig. 19.

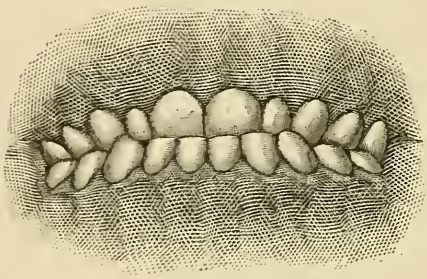

Acquired Prognathism.—The prominence of the lower jaw when not hereditary is termed acquired prognathism. It results usually from some faucial or nasal obstruction interfering with natural breathing, as enlargement of the faucial tonsils, adenoid hypertrophy, or other obstruction. When the tonsils are enlarged, they encroach on the natural air-passage, lessening its capacity. In difficult breathing in the early stages, before the habit of mouth-breathing is acquired, the patient usually makes an instinctive effort to improve the natural passage for the air by persistently forcing the lower jaw and tongue slightly forward; the jaws are somewhat separated, the lips closed, the tongue is in its natural position with the dorsum against the roof of the mouth, the apex curving downward and resting against the inner surface of the lower incisors or on their incisive edge. This position is more common during the hours of sleep. The jaw and

tongue held forward in this manner, while the tissues are still in the process of development, encourages protrusion of the lower jaw.

The more pronounced forms of acquired prognathism are usually accompanied with more or less obstruction in both the naso- and the oro-pharynx.

When there is a certain degree of nasal or faucial obstruction, or both, mouth-breathing results. The tongue is drawn from its natural position in the roof of the mouth, and settles in the lower arch sufficiently to form a free air-passage. The same condition exists when there is no especial nasal obstruction, but the faucial tonsils are enlarged. They obstruct the air-passage, and necessitate the pushing forward of the tongue, which sometimes protrudes between the teeth, especially at night, resting on the incisors and interfering with their natural eruption, or depressing them in their alveoli, thus causing lack of anterior occlusion of the teeth. In other instances the tongue rests back of the lower incisors and is forced farther downward to increase the opening for breathing through the mouth. When this is continued for any considerable time, prognathism results. In some cases, when the throat is large, hypertrophied tonsils may not interfere to this extent. Cases of receding lower jaw with enlarged tonsils are not uncommon. The contraction of the muscles to enlarge the air-passage sometimes draws backward on the jaw and prevents its anterior development. It is the desire to facilitate free breathing that prompts the child to throw the head far back during sleep, straightening the air-passage. The continued and combined action of some of the muscles which draw the lower jaw downward and forward, and the natural tonicity of others drawing upward at the region of the angle, tend to cause the angle of the jaw to become obtuse. I have seen several marked cases wherein the change had become so great that the angle was scarcely distinguishable. From these influences the jaw is often greatly lengthened; and sometimes its shape is so considerably changed that only the distal molar teeth occlude, causing in some extreme cases a separation between the upper and lower incisors of from one-fourth to three-fourths of an inch, and making it difficult to close the lips. An example of this is seen in Fig. 393.

In excessive protrusion of the lower jaw, the lower incisors are not infrequently tipped inward. This is generally caused by the backward pressure on them of the lower lip.

Unilateral prognathism may be brought about by a local cause; or an acquired, as an enlarged tonsil on one side. An enlarged tonsil, owing to its bulkiness and irritation, has a direct influence in forcing the jaw outward as well as obstructing the air-passage.

Local Causes of Prognathism.—Among local causes may be numbered malocclusion from injudicious extraction of permanent molar or bicuspid teeth. The extraction of molars or bicuspids on one side of the upper arch not infrequently causes *unilateral prognathism.* The injudicious extraction of the deciduous molar or cuspid teeth of the upper arch permits the permanent upper incisors in their process of eruption to assume a position back of the lower incisors. This form of occlusion encourages the anterior development of the lower jaw.

The improper eruption of the deciduous teeth as a result of sucking the upper lip may occasion prognathism (Fig. 35).

The sucking of the tongue is thought by some writers to be a cause. The tongue is doubled upon itself, causing a forward displacement of the lower jaw.

Detrimental effects of the forward and downward pressure on the jaw by the persistent sucking of the fingers have also been observed. When, in the adult, the upper incisors do not lap well in front of the lower incisors, sooner or later they may occlude on their incisive edge and become worn away, and finally they are worn to such an extent as to favor the lower incisors closing in front of the upper ones, causing protrusion of the lower jaw.

The contraction of scar tissue from a severe burn about the chin and neck has resulted in prognathism.*

Hypertrophy of the Tongue.—The undue enlargement of the tongue, as from hypertrophy or chronic congestion, causes the arch to expand, sometimes separating the teeth extensively, usually affecting only the lower arch, but the upper arch also may be involved with the teeth tipping outward. These conditions sometimes require the contraction of the arch. I have noted a number of marked cases resulting from this influence. The extent of the pressure on the inner circle of the arch from this condition is sometimes made apparent by the depressions on the lateral margins of the tongue,

---

* Tomes, Dental Surgery, 1887, p. 176.

which appear in congestion accompanying nervous disturbances in cases of derangement of the digestive tract.

Local Causes of Irregularity of the Teeth.—A thorough knowledge of the local causes of irregularities of the teeth is important, as many of these conditions are the result of neglect on the part of the patient or improper dental treatment.

The deciduous teeth seldom assume an irregular position. The germs from which they are developed are first symmetrically arranged in the dental groove, while those of the permanent teeth, which are larger and formed at about the same time, are necessarily located irregularly around the arch, and without proper development of the jaw they are inclined to erupt in an abnormal position.

Premature Extraction of Deciduous Teeth.—One of the principal local causes of irregularity is the premature extraction or loss of the deciduous teeth. The permanent incisors and cuspids are developed near to, or underneath, the roots of the deciduous ones. They are broader and larger in form, and in the normal process of eruption their position causes them to excite absorption of the roots of the deciduous teeth, and wedge their way into place, increasing the size of the anterior circle of the arch, and they are likely to be erupted in an irregular position, if not accompanied with an harmonious development of the maxillary bone and process.

The roots of the deciduous lateral incisors are occasionally absorbed, and the teeth become loosened earlier than they should through the development of the permanent central incisors. The fact that the latter are broader than their predecessors causes them to impinge on the roots of the deciduous laterals, inducing their absorption, and consequently the permanent centrals are permitted to take a position in the space previously occupied by two teeth, a deciduous central and a lateral. From this cause, at the eruption of the permanent lateral incisors, which are naturally located a little back of the centrals, they are made to assume an irregular position, usually being forced to rest inside of the circle of the arch.

In the same manner the deciduous cuspids are sometimes lost by absorption of their roots excited by the erupting lateral incisors or the first bicuspids. This permits the narrowing of the space that should be preserved for the permanent cuspids, and causes them to erupt in an abnormal position (Fig. 20).

The antero-posterior diameter of the crowns of the deciduous

molars is generally greater than that of their successors, the bicuspids. The combined measurement of the crowns of the deciduous cuspid and molars on one side of the arch is as much as or more than that of the permanent cuspid and the bicuspids, and if the deciduous teeth are preserved until the time of the eruption of the permanent ones, they usually have sufficient room for proper eruption in the circle.

Fig. 20.

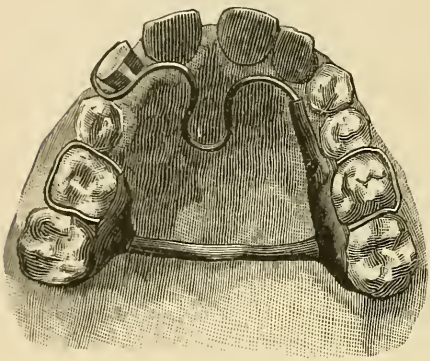

If either of the deciduous molars or cuspids are lost prematurely, the first permanent molar on that side moves forward in the line of the arch, and at the same time the permanent front teeth, instead of being pushed forward by their natural wedging during eruption, are crowded laterally backward into the space which should have been preserved for the proper eruption of the permanent cuspid and the bicuspids. When this occurs in the upper arch, the inward movement of the incisors generally permits them to take a position behind the lower ones. The taking up of the space on one side of the arch in this manner occasionally results in impaction of one or more of the bicuspids, either preventing their eruption or causing them to erupt on the buccal or lingual side of the line of the arch. When the deciduous cuspid is absent, and the permanent cuspid is not well advanced in the process of eruption, the bicuspids usually move forward, sometimes to the extent of closing the space. The mesial surface of the first bicuspid then rests in close proximity to the lateral incisor, interfering with the eruption of the permanent

Fig. 21.

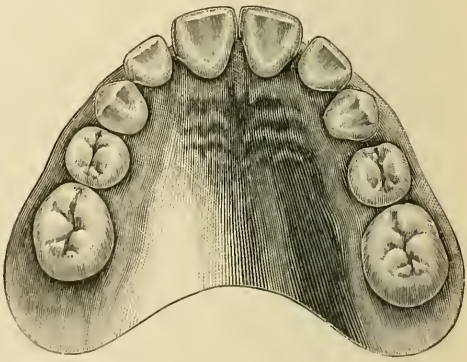

cuspid, and causes it to become too prominent, or to appear inside of the circle.

Fig. 21 illustrates a case in which the second upper deciduous molars were extracted too early. The second bicuspids not having erupted, the first permanent molars during their development gradually moved forward, taking up part of the space. When the upper incisors erupted, for lack of support on the lateral sides of the arch, they were not crowded forward as should be, but pressed the adjoining teeth backward somewhat into the spaces, which finally resulted in impaction of the second bicuspids. At the same time, from lack of the anterior development of the arch, the upper incisors closed back of the lower ones, causing the lower jaw to become prognathous.

Unwise Extraction of Permanent Teeth.—The inharmonious development of the jaws and teeth, as seen by the crowded position of the erupting permanent ones in young patients, often misleads the inexperienced practitioner, and prompts him to remove those teeth that should be preserved to complete the arch, and to cause a good occlusion and harmonize the features.

A permanent cuspid or a lateral incisor is not infrequently removed to lessen the crowded condition of the arch with the hope of correcting an irregularity. If a lateral be extracted for this purpose, it encourages the cuspid, which is of large size and conical form, to take its place next to the central incisor. The antero-posterior diameter of the cuspid is more than that of the lateral, and the articulation with the opposing lower teeth usually forces it to take a prominent position. Its shape, also, is unsuited for this location, and causes a conspicuous deformity. Therefore the lateral incisors should generally be preserved.

When the cuspid is too prominent, with insufficient space, or when it erupts inside of the circle of the arch, it is sometimes extracted with the intention of correcting the irregularity. The shape of the cuspid and the prominence of its root adds character to the face, and it should not be extracted when avoidable, as after its removal the process that covers the root becomes absorbed; this results, usually, in giving a flattened and unnatural expression to the features in the region of the canine eminence. When the teeth are crowded and the removal of a tooth in this location is necessary, it is usually the better practice to extract a bicuspid.

For lessening the prominent effect of the superior arch, occasionally

a molar or bicuspid is removed, and a year or more later it is found that the lower jaw has lengthened and broadened without a corresponding development of the upper jaw, causing the upper lip to have a sunken appearance difficult to deal with. It cannot be remedied except by contracting the size of the lower arch after extraction, or by the moving forward bodily of the incisors and cuspids of the upper arch. Again, the family type should be carefully considered before extracting, any undue prominence of the cheek-bones and the nose being noted. These parts do not come to complete development until the full age of maturity, and if the child inherits a large nose and prominent cheek-bones, and some of the teeth have been unwisely removed, the nose and cheeks will be likely to appear unduly conspicuous. Probably there is no part of the body which exhibits more strongly the influence of heredity than the nose, ears, and cheek-bones, but their characteristics are not fully shown until the time of maturity. The foregoing points cannot always be determined by a simple examination of the patient. However, if the prominence of the upper arch is known to be hereditary, the correction should be begun early. In such a case, when necessary, the first bicuspids are extracted. In some instances, to retard the anterior development, when there is tendency to extreme protrusion, the bicuspids should be extracted before they are fully developed, removing the first deciduous molars, and if necessary some of the alveolar process. On the other hand, the injudicious early extraction of the first lower *permanent* molars, before the eruption of all of the teeth of the arch, removes the lateral support of the jaw and interferes with its anterior development, while the normal growth of the upper arch continues, bringing about an apparent protrusion of the jaw, a condition that would not have existed had the lower molars been preserved.

It is not an uncommon practice among certain dentists to extract the first permanent molars with the intention of relieving a crowded condition, and lessening the tendency to decay among the remaining teeth, by permitting spaces to occur between them. This procedure usually proves to be a mistake; in but few instances are the conditions such as to require their removal. The first permanent molars are the most important of any of the grinding teeth, and should be preserved, as they help to secure the proper occlusion and relationship of the jaws. The poor structure and early decay of

these teeth sometimes necessitates their extraction, but when they are removed the anterior teeth do not usually separate and move backward into the spaces without mechanical interference; but rather the second, and later the third, molars tip forward, with only the distal part of their crowns touching their antagonists, bringing about an unnatural and objectionable occlusion. Again, the extraction of the first permanent molars before the eruption of all of the teeth interferes with the anterior development of the jaw, resulting in its shortening and the weakening of the support of adjoining teeth by the loss of the intervening alveoli.

Too Long Retention of Deciduous Teeth.—The permanent teeth in their process of eruption are occasionally directed into an abnormal position by deciduous teeth that have not become loosened by absorption and have been retained too long. The permanent incisors, cuspids, and bicuspids are sometimes thus made irregular, the absorption of the deciduous tooth in some instances evidently taking place on one side of the root only, while the pressure of the other or unabsorbed part is sufficient gradually to direct the erupting tooth inward or outward from the natural circle of the arch according to its location. This is especially apparent when the deciduous tooth has become devitalized, which retards its natural absorption. The simple removal of the unabsorbed portion of the root is usually sufficient to permit the permanent tooth to take a correct position, provided there is room for its eruption.

Supernumerary Teeth.—Teeth exceeding the usual number, and not properly belonging to either dentition, are classed as supernumerary teeth. Their crowns may be conical in form, or shaped so like the adjacent teeth as to make it impossible to determine which are the supernumerary. They may appear in different locations, sometimes erupting by the side, but most commonly between other teeth, especially between the central incisors. The excess of the normal number of teeth usually causes a crowded condition, interfering with the symmetry of the arch. When the intruder is conically shaped, the adjacent teeth are more liable to be deflected or rotated into irregular positions. When found with the molars or bicuspids they are generally small, and located on the buccal or lingual side, or back of the last molar. Supernumerary teeth are not uncommonly found with the deciduous set, principally among the lower incisors; and sometimes they coalesce.

Irregularities that arise from the presence of supernumerary teeth are generally improved by their extraction.

Fig. 22 illustrates the case of a boy, aged nine years, with two irregularly shaped supernumerary teeth back of and in the position

Fig. 22.

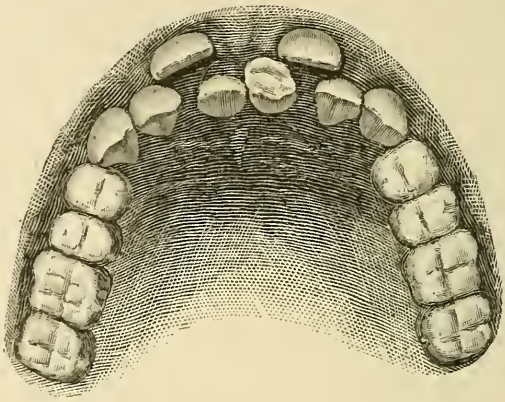

of the central incisors, forcing the incisors to take a very prominent position, with a broad space between them.

In Fig. 23 is seen a similar case, the two supernumerary teeth being in front of the central incisors, with the other teeth in the

Fig. 23.

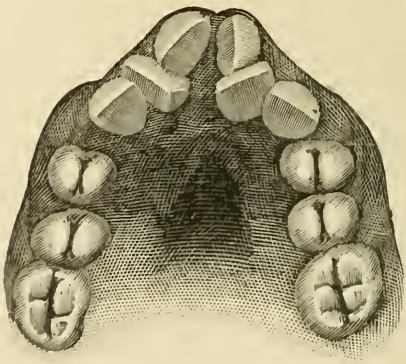

anterior part of the arch much crowded. The supernumerary teeth were extracted, and several months later the teeth of the arch had

assumed the position shown in Fig. 24, there being no mechanical interference.

Fig. 24.

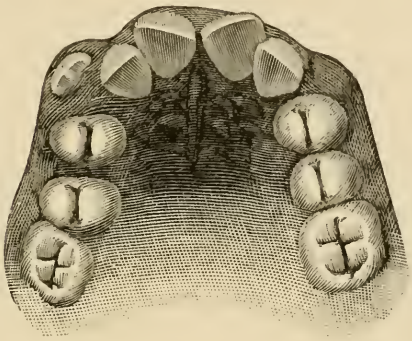

Fig. 25 shows an interesting case with four well-formed upper lateral incisors. An irregularity of the teeth was brought about by the presence of the supernumerary laterals, one having erupted in-

Fig. 25.

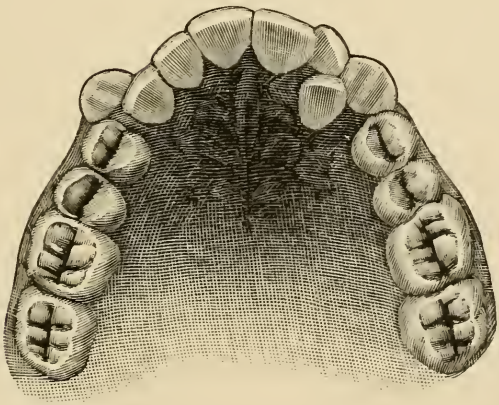

side of the natural alignment of the arch, and the other in the position of the right upper cuspid, causing it to become too prominent.

Anomalies.—In this connection several cuts will be presented showing anomalies which are not so uncommon as to require special comment, but are yet of interest.

Fig. 26 illustrates a case with the position of the permanent lateral incisors and cuspids reversed,—that is, the cuspids located next to

Fig. 26.

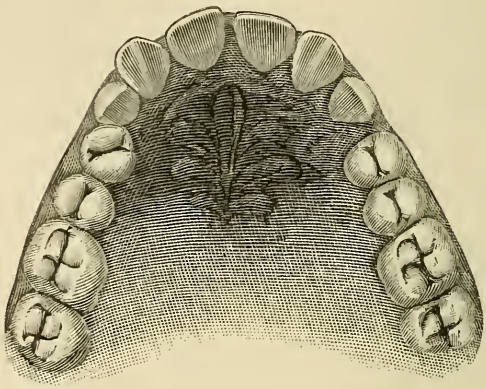

the central incisors, and the lateral incisors back of them and in front of the first bicuspids. The alignment of the teeth was good, but their appearance was marred by the transposition.

In Fig. 27 is seen the natural position of the first left superior bicuspid and cuspid reversed. The lateral incisors were not erupted.

Fig. 27.

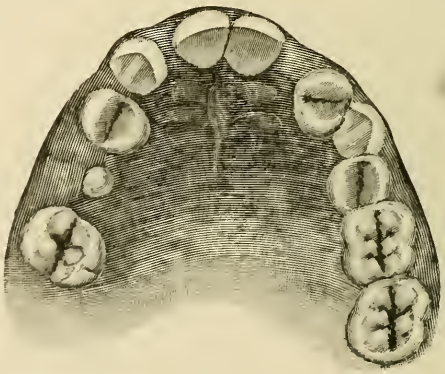

The right cuspid had taken a position near the central incisor, and the first left bicuspid had moved forward towards the incisor, with the cuspid between it and the second bicuspid.

Fig. 28 illustrates a lower arch in which there were only two incisors in place of four. They appeared like perfectly shaped upper

central incisors, and the two were broad enough to fill the natural space between the cuspids. The number of deciduous incisors was not ascertained.

Fig. 28.

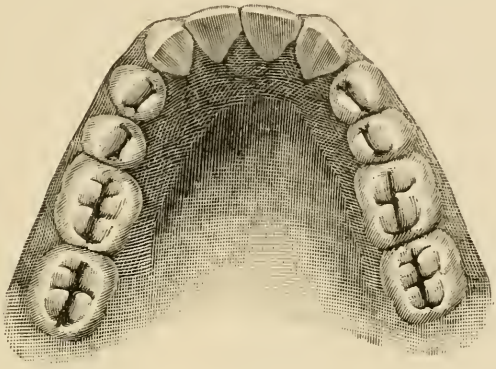

Irregularities caused by Accident.—The following cuts illustrate interesting cases resulting from accident. In Fig. 29 the alveolar

Fig. 29.

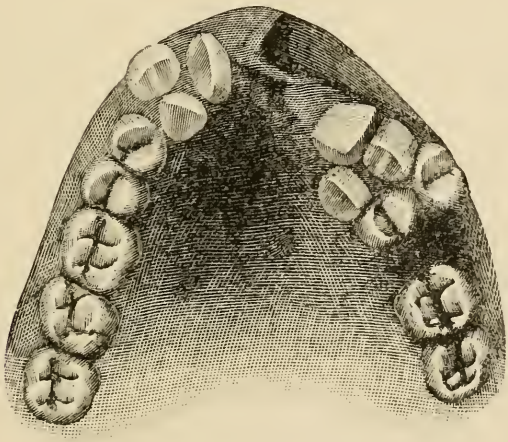

process was injured before the eruption of the permanent teeth, and when they appeared they were considerably separated from the median line. A central, lateral, cuspid. and the bicuspids were bunched together on the left side, and a central, lateral, and cuspid on the right side, the rest of the teeth being in their usual positions.

The process at the median line was full although irregular, there being no appearance of a cleft.

The three succeeding figures are cuts from models presented by a prominent practitioner, who considered the conditions the result of an accident, or of the premature extraction of the deciduous teeth. After the loss of the six anterior deciduous teeth, the permanent ones erupted as seen in Fig. 30. The roots of the central incisors

Fig. 30.

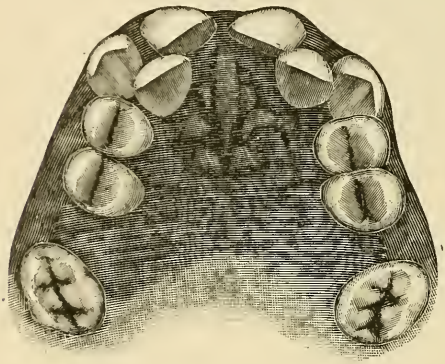

Fig. 31.

were diverging, causing a broad V-shaped space between their crowns, and the lateral incisors had taken a position back of them and inside of the circle of the arch. It was not thought advisable to attempt

Fig. 32.

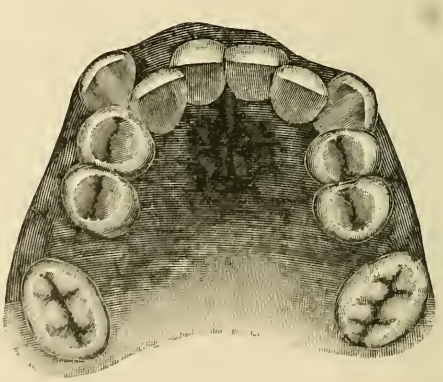

their regulation. Owing to the unpleasant appearance the central incisors were extracted, and the roots were found to be bent towards each other as seen in Fig. 31. About eight weeks after the extrac-

tion of these teeth, two supernumerary teeth with imperfect surfaces were erupted in place of the incisors, the other teeth remaining in the same position (Fig. 32).

Injurious Habits.—During the time of the eruption of the teeth the jaw and alveolar process are developing, and are easily changed in their contours. It is while the tissues are in this formative condition that the evil habit of sucking the thumb, finger, lips, tongue, or cheek is usually begun, and when continued, it is liable to cause a marked influence on the future shape of the jaws and position of the teeth. These habits, if not corrected, are in some instances continued after the eruption of the permanent teeth.

Sucking the Thumb.—The persistent pressure of the tongue against the thumb or the fingers as they are placed in the mouth imparts a corresponding pressure forward and upward against the inner part of the anterior superior arch or intermaxillary division, which gradually yields, bringing about an abnormal anterior development. The natural closure of the jaws against the thumb or fingers while they are placed in the mouth in this manner, induces additional pressure on the teeth, forcing the lower incisors inward, while at the same time the upper ones are moved outward. This often causes a considerable space to intervene between the upper and lower incisors, but the principal permanent irregularity that results from this habit is from its continuance after the eruption of the permanent teeth.

Fig. 33 illustrates the position of the deciduous teeth of a boy aged five years. The upper incisors had become so prominent that

Fig. 33.

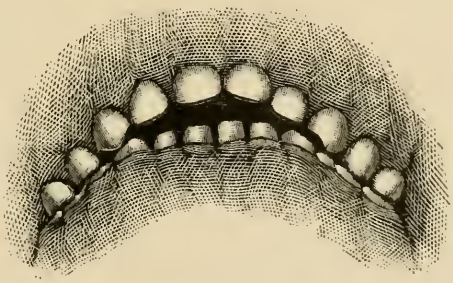

they projected outward over the lower lip, and the anterior line described by the lower incisors was very much flattened by being

pressed inward. The figure illustrates a typical irregularity, caused by sucking the two first fingers of the right hand.

Some time since I was called upon to prescribe for the breaking up of a persistent habit of thumb-sucking in a girl aged thirteen years. In this case the lower jaw receded and the upper incisors had become very prominent. The parents stated that they had not attempted to correct the habit until after the eruption of the anterior permanent teeth ; then, realizing that a deformity was being brought about, they had for several years sought professional aid, both from physicians and dentists, but none of the methods recommended had proved successful. The patient was unusually intelligent, but whenever she became absorbed in thought, either at home or on the street, she would resort to the habit, and it had become extremely embarrassing to her and to her people. (See Fig. 281.)

Sucking or biting the Lips.—The habit of sucking the lip is usually begun at about the time the child is being weaned, although in some instances it is taken up in early infancy and is generally continued after the eruption of the permanent teeth. The lower lip is the more frequently the sufferer; it is drawn upward over the lower incisors, tipping them backward, and in some cases these teeth are depressed in their sockets. At the same time the upper incisors through their forcible contact with the front of the lip, are pressed outward and may be lengthened. Fig. 34 shows the features of a girl aged twelve, who had practised the habit of sucking the lower lip at night and almost continuously during the day from infancy, causing the upper incisors to project considerably over the lower lip, those on the left side being especially prominent. On examination it was found that the deformity was caused by the lip being drawn more towards the left side in the process of sucking. The evil habit was overcome by moving the incisors inward to their proper position and by the special efforts of the patient to keep the lip in front of them.

Marked cases of irregularity resulting from sucking the upper lip have been presented, although the habit is not considered a common one. Fig. 35 shows the case of a girl, aged two years and ten months, in which an irregularity of the deciduous set was caused by this habit. The upper incisors and cuspids were made to close back of those in the lower arch. The irregularity was corrected as seen in Fig. 185.

The sucking of the upper lip at the time of the shedding of the

Fig. 34.

deciduous teeth and the eruption of the permanent ones is especially liable to cause irregularity of the incisors. The permanent upper teeth are directed inward by the pressure and are made to close back of those of the lower arch. This, and the curling in of the lips, sucking, or biting both of them at the same time, is not an uncommon cause of depression of the anterior teeth in their alveoli, producing lack of anterior occlusion.

Fig. 35.

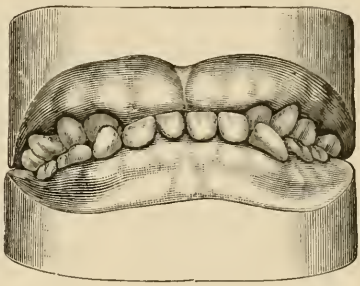

Tongue-Sucking.—When the tongue is sucked, it is generally doubled upon itself. This broadens it laterally, and, if the habit is continued, it may influence the position of the teeth by pressing them outward in the region of the middle and distal part of the arch. Sucking the cheeks has a reverse tendency, pressing the anterior molars and bicuspids inward, and sometimes depressing them in their alveoli, thus causing lack of lateral occlusion.

I am convinced that these habits, as deforming factors, are more common than is generally supposed, and deserve careful consideration.

Pyorrhœa Alveolaris causing Irregularity of the Teeth.—Irregularity resulting from pyorrhœa alveolaris is common. The alveolar process is usually more or less wasted away and the teeth elevated. Before the correction of the irregularity is attempted the disease should be stayed by removing the cause as far as may be, and when necessary by continuing with both systemic and local treatment to prevent its recurrence.

If the teeth have become elevated, they should not be pressed more deeply into their sockets, as that would aggravate the existing tendency to congestion by increasing the depth of the pockets. The occluding surfaces of the teeth should rather be dressed down by grinding with a corundum stone from time to time as required, destroying the pulp if necessary.

The application of a proper regulating appliance in these cases often improves the usefulness of the teeth, even in aggravated conditions, and without its application the irregularity is likely to increase. The regulating force should be applied gradually, and the teeth should

be well supported for a considerable length of time. In some cases a permanent retainer is required; in others, the retaining appliance can be worn at night only.

In practice it is sometimes difficult to classify satisfactorily the cause of an irregularity from the history obtainable and the examination of the case presented, as irregularities depend upon varied influences. A knowledge of the etiology of irregularities of the teeth is necessary to enable one to diagnose and to anticipate the conditions, to determine the advantages to be gained by an operation, and to be able to judge from the tendencies how long the teeth will need to be retained.

CHAPTER II

THE ALVEOLAR PROCESS

The alveolar processes are the dental margins of the jaws in which the teeth are set. They consist of an outer cortical layer or plate of bone, connected with a cancellate tissue, which is developed from the outer margins of the upper and lower maxilla, and follows their curves. They envelop the teeth and grow with them for their support. In addition to these cortical layers of the process, which are of dense material, there is a thin lamina of similar structure that surrounds the teeth and their roots as they develop, forming the alveoli. This contains many vascular openings for the vessels of nutrition and the nerves.

The cellular or cancellate tissue forms the major part of the alveolar process. It is built around the lamina of the alveoli, forming the septa which connect the bony plates and separate the teeth. (Owing to the great vascularity of these tissues, they are readily absorbed.)

As the teeth progress in their development, the thin covering of process over their crowns is absorbed, permitting their eruption, and when the teeth are fully erupted the process is developed around the necks of the teeth, and each alveolus is made to invest closely the fang contained within it, leaving space between the walls of the alveolus and the fang for the thin *peridental membrane* which connects them. This membrane is highly vascular, and furnishes nutrition for the tooth. At the neck and towards the apex of the root it is rich in nerve-tissue, and is the organ for the sense of touch for the tooth.

Teeth are developed from the mucous membrane of the mouth. The crypts are formed in the dental groove, which is of true bone and process. When the teeth are fully formed and erupted, the roots are surrounded with alveolar process, the alveoli extending into the jaw. The depth of this penetration is variable in different persons, and in different parts of the same jaw.

The purpose of the alveolar process is to protect the teeth through their formative stage, and later to support them. During the erup-

tion of the teeth the process follows and surrounds their roots in almost any position they may assume, and when the teeth are removed, there being no further use for it, it is gradually absorbed, leaving a smoothly contoured surface.

The application of force to the teeth, when continued and steady, causes absorption of the bone in advance of the moving tooth; while the space that is left by the movement on the opposite side of the tooth is gradually built in by a redeposit of bone.

The bone and process covering the roots of the teeth is much thicker in some parts of the arch than in others, and not uncommonly proves an annoying barrier in operations, such as expanding the upper arch. The malar process usually projects downward over the sides of the roots of the molars and bicuspids, causing them to be elongated as they are moved outward. The thickened process back of the upper and lower incisors adds to the difficulty of their inward movement.

CHAPTER III

OCCLUSION AND ARTICULATION

The occlusion of the teeth is the relative position of the upper and lower teeth as they naturally close together, with the cusps of the teeth of one arch resting in the sulci of those of the opposite arch, although the upper and lower teeth do not normally remain in contact even when the lips are closed.

Articulation is the closure of the upper and lower teeth together in any of the normal positions, as in general occlusion, or the placing of the upper and lower incisors edge to edge.

In cases presented for treatment, the manner of the occlusion of the teeth should be carefully noted by the operator, and mentally compared with the normal or ideal type of jaws.

In the correction of irregularities it is necessary to have an understanding of the accepted ideal type, and to imitate it as far as may be, adapting it to the special cast of features presented for the improvement of the occlusion and of facial contour.

Fig. 36.

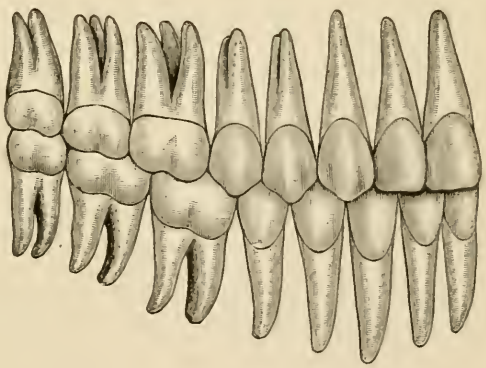

The shapes and arrangement of the teeth admirably adapt them for the purposes for which they were intended,—the incising and trituration of food,—while their various sizes, length, width, and contour, when symmetrically developed in the different types, give harmony and beauty to the features.

Fig. 36 is intended to illustrate a normal occlusion of the teeth. The natural arch forms a graceful curve, similar to a semi-ellipse, with the teeth symmetrically arranged one next the other. The part of the curve formed by the incisors and bicuspids is slightly flattened, with a corresponding prominence at the location of the cuspids.

The upper arch is slightly larger than the lower, especially in its anterior part; the incisors and cuspids are a little broader, and occlude in front of the lower teeth, covering about one-third of their crowns. While the anterior part of the lower arch is a little narrower than the upper, it bends outward in the region of the third and second molars, being broader than the upper arch, the teeth tipping slightly inward.

The upper central incisor is broader than the lower central incisor, and occludes with it and one-half of the lateral. This causes the upper lateral incisor to articulate with the lower lateral incisor and cuspid, and the morsal surface of the upper cuspid with that of the lower cuspid and first bicuspid, the cusps of the upper first bicuspid with the lower first and second bicuspids, the upper second bicuspid with the lower second bicuspid and first molar, the upper first molar with the lower first and second molars, the upper second molar with the lower second and third molars, and the upper third molar with the lower third molar, the crown of the upper third molar being usually smaller than the lower.

When all of the teeth of the upper and lower arch rest in occlusal contact, it is termed normal or full occlusion. When, as normally, the upper incisors close in front of the lower, the upper incisors are in a labial occlusion and the lower incisors in a lingual occlusion. When the upper incisors close back of the lower, they have a lingual occlusion and the lower incisors a labial occlusion. When only the incisors of the upper and the lower arch touch in occlusion, it is termed anterior occlusion, or lack of posterior occlusion. When only the distal upper and lower molars, or the molars and bicuspids, rest in contact, it is termed distal occlusion, or lack of anterior occlusion. When the upper and lower molars and bicuspids rest in contact only on one side of the arch, it is termed unilateral occlusion.

CHAPTER IV

EXAMINATION OF PATIENTS—RECORD OF CASES—IMPRESSIONS—MODELS OF TEETH—CAST OF FEATURES

The human face is said to be the mirror of the soul. It reflects the intelligence of the mind and betrays its passing impulses. The first thing that strikes us favorably in a face is exactness of proportion, then harmony of the features. When a case is presented for the regulation of the teeth, it is important that the contour of the features be studied before the mouth is examined or models are made. Careful note should be taken of the apparent changes required; these should accord with the type and temperament of the patient, whether well nourished or developed, the profile, including the size of the nose and the orifices, the width between the alæ nasi, the prominence of the cheek-bones, and the fulness or recession in the region of the upper lip. The relative position of the chin to the forehead should be noted to determine where the deformity is situated, and whether the upper or lower arch should be made more or less prominent. The features should be studied both in repose and when animated, especially when laughing. In extreme upper protrusion, the lower jaw sometimes rests forward in occlusion, and in laughing the contraction of the muscles forces the lower jaw backward again into the normal temporo-maxillary articulation. This change always causes the upper teeth to appear more conspicuous.

History of the Case.—It is essential that a correct diagnosis of the conditions should be arrived at before beginning an operation, and, if the case is a complicated one, it is usually necessary to have a knowledge of the hereditary proclivities. Such information should be gained from the parent or guardian. It should state the age; whether the patient has had any bad habits, such as sucking the cheek, tongue, lip, fingers, or thumb, and how long continued; if the patient is a mouth-breather, and whether continuously, or only during the hours of sleep, or when suffering from colds; and any other points that may seem to be necessary for obtaining a complete understanding of the case.

Physical Examination.—This consists of—

First, examination of the mouth, including the occlusion, position, and size of the teeth, the form of the arch, the form and size of the jaws, the size of the tongue.

Second, examination of the throat and posterior nares, to determine whether they are constricted, or if the tonsils are abnormally developed, and whether adenoid growths are present.

Third, examination of the nose, to determine the size of the apertures, condition of the septum, whether the vomer or cartilage is deflected, whether there is congestion of the mucous membrane or disease of the turbinated bones, or any asymmetry of the parts. To complete the examination, models of the teeth, made from impressions of both the upper and lower arch should be prepared for further study of the case.

Record.—When a case has been fully examined and considered, and an operation is decided on, a full record of the conditions should be made, its character depending much upon the changes that are to be brought about; for the more simple cases make only a written record, including the especial characteristics, the age and sex, and preserve models of the teeth. In cases where marked changes in the features are to be made, the record should be more complete, either by taking measurements of the face with a profilometer or goniometer or a record-card, traced from a soft wire shaped to the features; or by making a plaster cast of the features; or by taking a photograph—in special cases a skiagraph to show the position of the roots of the teeth. It is also advisable to preserve a written record and models of the teeth of cases where the regulation is not undertaken. They may prove of value at some future time.

Impressions.—The taking of impressions of the teeth is so generally understood that only some of the more important features will be described. For regulating purposes it is very necessary that an exact model of the teeth should be obtained, including the roof of the mouth and accurate markings of the rugæ and the contour of the gum. The materials adapted for this purpose are impression compositions, plaster of Paris, and modelling compound. Gutta-percha, wax, and clay have been used.

The process of taking the impressions should be sufficiently explained to the patient to relieve him of any fear, and the necessity of breathing forcibly and continuously through the nose with the

mouth open, to prevent any tendency to nausea or strangling, should be shown. Breathing through the mouth will increase the difficulty, excepting where the head is thrown far forward.

In order to take a good impression, the impression-tray should be well adapted to the arch, not bearing too heavily on any of the parts, and no more than a sufficient amount of the plastic material should be used.

In taking a plaster impression, it should be allowed to become rather hard before being removed from the mouth. If the impression is broken in removing, the parts should be carefully readjusted in the tray and united before running the model. Sometimes it is advisable to form a close-fitting impression-tray by first taking an impression in softened wax. After its removal the openings made by the teeth should be enlarged by cutting away some of the wax. The wax impression is then used as a tray, with which an impression is taken in the usual manner. With the latter method the plaster is generally more easily removed from the model.

Impressions of irregular teeth for the purpose of making regulating appliances should be taken in plaster of Paris, at least until one has, through trial, become sufficiently expert to take them accurately with some of the modelling compounds. When the impression is taken in compound, the surface of the model is generally smoother than when taken in plaster; it is quickly made, and the procedure is more agreeable to the patient. The impression should be held firmly in position, and hardened as quickly as possible by the application of ice-water, by means of napkins about two inches square, folded and moistened; or small pieces of ice folded in napkins may be used, or cold water applied by a syringe, tipping the head forward. Care should be exercised not to remove the impression until all of the compound is well hardened; the thicker parts cool more slowly.

When the teeth are long, and there is danger of the compound dragging while being removed, before inserting the impression material a quantity of French chalk should be hastily and thoroughly rubbed over its surface to prevent it from clinging to the teeth. If there are large undercuts between or cavities in the teeth that are of such shape as to cause the compound to drag while removing, they should be carefully filled with wax or other material. If the second or third molar inclines forward into the space formerly occupied by the

first molar to such an extent as to cause overhanging edges and prevent getting a good impression, the difficulty can be overcome either by placing a rounded piece of soft compound longitudinally between it and the tooth next in front, and allowing it to harden in such a shape that there will be no undercuts, or by shaping a small piece to the gum and mesial surface of the inclining tooth, to which it may be ligated with a thread when necessary. When well shaped and sufficiently hard, it can be covered with one or two layers of thin, moist paper to prevent it from adhering, and the rest of the impression can then be taken in plaster of Paris or modelling compound. When the impression is removed, the parts are carefully placed together before running the model.

Cases are not infrequently presented in which the arch is contracted and very deep, with undercuts, making it impracticable to remove the impression in one piece. To overcome this, a small amount of the compound should be pressed into the depression and properly shaped. When it has hardened, the surface should be rubbed with French chalk, or covered with moist tissue-paper, and the rest of the impression taken as usual. After the removal of the parts, they should be carefully placed together as described. When the upper teeth are protruding, it is sometimes advisable to make the impression in two parts.

Not infrequently a very accurate model of the lingual and labial surfaces of the teeth is needed, as in making regulating and retaining apparatus in cases affected with pyorrhœa. For this purpose I have devised impression-trays, having one shaped for use in the front and another for the distal part of the arch. They are made of rolled German silver, in two parts or lateral halves, for covering the outer and inner sides of the teeth and gum. To form a flange, each part or side of the tray is bent nearly to a right angle. These lateral halves are joined together by two bars, which are soldered to the flange on one side and made to pass through short cylinders that are soldered to the flange on the opposite side, and so arranged that as the two parts are pressed together in taking an impression the flanges slide by one another over the grinding surfaces of the teeth. For convenience in removing the tray, a small hook or eyelet is soldered to the outer side of each half.

The impression is taken by first placing a small amount of softened compound in each side of the impression-tray and rubbing the sur-

face thoroughly with soapstone. The tray is then placed over the teeth and the parts pressed gently together with the fingers or especially devised pliers. It is essential that the tray be held steadily in place until the modelling compound has become thoroughly hard. The parts of the impression are then separated and removed with pliers similar to those used for adjusting a rubber-dam clamp by inserting the points of the pliers into the hooks described. The parts are readjusted and a model made in the usual manner.

Water injected from a syringe under the lip at the median line when removing an impression will relieve the tendency to suction, and thus avoid drawing up of the compound in the centre, which so often spoils the impression. Forcing water under the lip in this manner when removing plaster impressions is an invaluable procedure, as it furnishes the moisture demanded by the hardening plaster, and causes it to separate easily from the mucous membrane. If an accurate impression cannot be obtained with modelling compound, it should be taken with plaster of Paris.

When an impression is made of a model with modelling compound, to make a duplicate, the surface of the model and the warm compound should both be well rubbed with French chalk.

I had occasion to take an impression of the upper and lower arch of a child, two years and ten months of age, for the purpose of correcting a malposition of the teeth and protrusion of the lower jaw. At the first trial it was found impracticable to use an impression-cup, and a piece of German silver wire, No. 12 Brown & Sharpe's standard wire gauge, was shaped to support a small amount of compound for its introduction into the mouth. The wire was formed into a short loop for a handle, with the width between the ends sufficient to pass outside of the arch of teeth. I gained the confidence of the child by first biting into a piece of the soft compound myself, and then introducing into the child's mouth a small amount of the compound with a minute piece of soft candy, saying nothing to her about the candy. After the second trial, the mouth was always ready and waiting for the impression-material. A sufficient amount of the compound was then prepared on the wire support with a little candy as before, and quickly placed in the mouth, and she was told to bite her teeth into the compound. She willingly held her jaws together, the tongue pushing the soft compound against the teeth and roof of the mouth, while the outer part was

pressed against the teeth and gum with the finger. The chin was held with gentle force, and the compound cooled in the usual manner.

Impression of the Chin.—Impressions of the chin are required in the construction of chin-caps and other apparatus. An impression-tray is made of thin sheet gutta-percha, or by bending into form a piece of soft material, as sheet lead, tin, paste-board, or the like. Sweet oil or vaseline is applied to the chin, and the impression is taken with plaster of Paris, from which a plaster model is made.

Preparing and carving Models.—Before plaster of Paris is run into an impression for making a model, it is well to examine the impression and correct any apparent imperfections. When a plate is to be constructed the plaster model should be carefully examined for any defects, especially at the necks of the teeth. The plaster should be dressed away slightly from around teeth that are only partially erupted, to allow the rubber to get a more thorough hold for anchorage.

The carving of a model for the adjustment of a spring-clasp attachment for anchorage should be done with great care.

When it is practicable, examine the natural teeth, and have the plaster form an exact reproduction. In some instances the anchorage is improved by over-carving the plaster of the teeth a very little at their necks. When the teeth are short, and not fully erupted, the gum portion at their necks should be carved, care being taken to preserve the natural form. Carving for this purpose is sometimes best done with a hoe-excavator, not dressing too much of the plaster away, but cutting a groove in the gum portion at the true neck of the tooth. A partial-clasp set in a groove in this manner will prevent the solder from thickening the part that is to project under the free margin of the gum. (See Partial-Clasp, p. 74.)

Coloring and mounting of Models.—From the beginning of my practice I have preserved records of cases of irregularities in the form of plaster models, colored and joined. The upper and lower models are united with a hinge made of brass screw-eyes. To the end of the screw is attached a small piece of sheet copper or zinc with soft solder to prevent it from rotating in the plaster. The screw-eyes have a section of the circular part cut out, thus making hooks of them. The hooks are placed in the upper half of the model, and screw-eyes to hinge with them are placed in the lower

Fig. 37.

Fig. 38.

part. A hole drilled in the plaster by the side of the screw-eye, and a piece of wood inserted in position, will prevent them from unhinging.

When the models are dry they are smoothed with fine sand-paper and soft cloth, after which they are usually colored with tube oil paints. The pink of the gum is simulated by mixing with the white a little rose madder, and just a tinge of burnt sienna and yellow, and the mixture thinned with turpentine. The borders are colored with burnt sienna. When the paint is dry a coat of thin white shellac is applied to give a hard finish. Too much paint or varnish should be avoided, as it is apt to turn yellow with age. The models of each case should be mounted on a board, arranged in the order in which they were taken.

In place of coloring the models with paint, after being dried they are sometimes placed in melted stearine and submitted to a gentle heat. The stearine strengthens the model and gives the surface an ivory appearance.

Profile Records.—A simple, accurate method of making a record card* for recording measurements and noting the extent of changes in the outline of the features is made by taking a piece of soft tin or lead wire, round or square, about one-eighth to three-sixteenths of an inch in diameter, and shaping it carefully with the fingers to the contour of the features at the median line from the forehead to the chin (Fig. 37). The wire should not be permitted to press unequally on any part. After the wire is shaped, it is well supported to prevent bending, and placed on strong card-board, several pins being stuck into the card-board close in front of it. Trace with a fine-pointed pencil, on the other side of the wire, the outlines formed; then cut the card-board, following the pencilled line, and, if the work is well done, the card will fit accurately to the profile of the features (Fig. 38).

Any other angle or surface measurement can be obtained in the same manner. The use of the wire and card is of advantage in making patterns for shaping many forms of external regulating apparatus, several examples of which will be mentioned.

A profilometer (Fig. 39) is an instrument for obtaining facial outlines for record. It is composed of sliding rods arranged side by

---

* Jackson, Transactions of the New York Odontological Society, 1895, p. 75.

side in a frame and held in the desired position with a clamp. The ends are adjusted to the contour of the features, and pencil markings are made from the outline secured.

Another instrument for measuring facial angles is a facial goniometer * (Fig. 40). Its application and register dial will be understood from the engraving.

Model of Face.—A model or cast of the face in plaster of Paris or wax is an excellent means of recording changes in facial expression brought about by the movement of the teeth and process and the bony framework underlying the integument. Dr. A. O. Hunt has described his method of making plaster casts of the face, which he has used for over twenty years. Two tubes, about two and one-half inches long, are prepared for the nostrils, made of

Fig. 39.

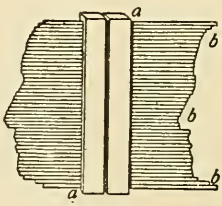

Profilometer.

Fig. 40.

Goniometer.

No. 60 tin-foil, usually wrapped about a lead-pencil. He places the patient in a horizontal position, being careful that he is comfortable, so that it will not be necessary to change his position until the operation is completed. He then coats the skin, where he wishes the plaster to come in contact, with a thin coating of the best olive oil, being careful not to leave any surplus of it in the wrinkles of the skin or about the fine hairs, as an excess of the oil will not permit of a well-defined surface of the cast. Whenever there is a moustache or beard, or when he desires to take an impression well up into the hair above the forehead, he uses a lather of soap, working it carefully into the hair. The tubes of tin-foil are then slightly flattened and inserted into the nostrils, after which the patient should close the mouth and breathe through the tubes until he can do so with ease and comfort. A bowl of plaster is then mixed to

* Goniometer as recognized by Cuvier, Standard Dictionary.

Fig. 41.

about the consistency of cream. Another bowl is to be made ready at the right time by an assistant. The patient is cautioned before the plaster has touched the face to hold perfectly still. The plaster is first applied over the face and lips, care being taken to have it run into all of the depressions, and then gradually over the parts that have been oiled, air-bubbles and creases being carefully avoided. The cast can be made to cover the neck, chin, and side of the face. If the ear is to be included, the deep depression should be closed with a little moist paper pulp, and something placed underneath the ear to prevent its position being changed by the weight of the plaster.

My method of making plaster casts of the face varies only in minute detail from the method described. In making the mask a shield is first placed around the neck and head to form the outline and prevent the plaster from flowing beyond the desired limit. The shield is shaped and applied as seen in Fig. 41. It is made of strong manilla card-board by cutting out a piece similar in shape to a horseshoe, the part passing underneath the chin being about two and one-half inches wide, and gradually narrowing until at the ends it is about one and one-half inches wide. The inner circle of the shield should be so shaped that when the ends are drawn together the outer edge will flare up a little, so as to more thoroughly retain the plaster which flows against it. The upper side of the shield is rubbed with vaseline to prevent the plaster from sticking to it. When a mask of only one side of the face is to be made, the shield should be adjusted to pass below the chin and ear on that side, and above or in front of the ear on the opposite side, the ends being tied together at the back of the head with tape.

After the shield has been properly adjusted, the patient is directed to close the eyes and not to open them until told to do so after the operation is completed. If these directions are observed no especial discomfort should be experienced. The face is thoroughly treated with a thin coat of olive oil or warmed vaseline, care being taken to supply a sufficient amount to the eyebrows and eyelashes. Apply the vaseline with a soft bristle brush, then rub the surface thoroughly with the hand, which results in giving the model a better skin effect. A wad of paper, softened in water, should be laid under the ear to support it and to prevent the plaster from running underneath; a small wad is placed in the opening of the ear and another

in the deep undercut. Moist modelling clay, worked into the hair, is used when there is a moustache or beard. In ordinary cases, if it is desired to have the mask extend over the hair, much time will be saved by using bibulous or tissue-paper (either dry or moist) over the hair, around the ear, and on the forehead. When the plaster is sufficiently hard the shield should be removed and the mask gently raised. In some instances the patient can assist in the removal by cautiously working the muscles of the face, but he should never separate the jaws. The impression should be painted over several times with a solution of green soap, or immersed in or painted with a solution of silicate of soda and water before pouring the plaster for the model. Olive oil has been used.

A plaster-of-Paris mask of the complete head of the living subject can be made in sections, using the card septum for dividing in the manner shown in Fig. 38. The process is equally applicable to other parts of the body.

Charts.—For illustrating methods of making regulating appliances, I devised a series of charts, which are particularly useful in describing new methods.*

The drawings are made on black cambric muslin, which is procured by the yard. Along one edge of the fabric small brass rings are sewed about six inches apart. A stout cord is passed through the rings, and the ends are tied to hooks in the wall in any convenient position. An easel, provided with a board, is placed back of the portion of the muslin to be painted. Thumb-tacks are pressed through the cloth into the board to hold the cloth smooth while painting the design. Paint is applied with flat bristle-brushes. If desired, an outline can first be made with chalk. Naturally the teeth are painted in white. The metals of the appliances are indicated in bright red. This strong contrast of color upon the dark ground is readily seen from the distant part of an ordinary hall or class-room. When the drawing is finished the thumb-tacks are removed, and the muslin is drawn along the cord until the proper space is obtained for another design. The drawings can be numbered by painting

* This system of charts is especially applicable to public lectures, class-room, and laboratory demonstrations for the illustration of models, appliances, instruments, anatomical and physiological specimens or drawings of any nature where the eye is called upon to assist the imagination.

the figures on separate pieces of cloth, sewing them to place, and the charts rearranged in any desired order by simply cutting them apart and sewing them together in the order desired.

When a duplicate drawing is wanted, a blank piece of muslin is placed smoothly across a freshly painted drawing, and the fold is pressed lightly with a large roll of cloth or other material. If care is exercised, three such reproductions can be made. Parts imperfectly copied should be touched up with fresh paint. The paint becomes dry in about three days, when the charts may be bundled together, so that a number of them can be strung on a comparatively short cord, but they should not be rolled in less than a week after painting.

CHAPTER V

AGE FOR REGULATION

Each irregular tooth should be aided to take a correct position in the circle of the arch while erupting, or as soon thereafter as practicable, not only in order to promote the proper development of the jaws, but because the teeth next to be erupted will be more likely to do so in proper position and order. Only a portion of the alveolar process that forms the sockets for the roots of the teeth is developed until the teeth are fully erupted. For this reason a slight pressure is sufficient to change their position. When the force is properly applied there is no danger of strangulation of the pulps of the teeth, and no pain or especial discomfort should be experienced. But if too much pressure is put on prominent teeth when adjoining ones are erupting, it is likely to wedge the erupting teeth to such an extent as to arrest their development.

There is a natural contraction of the alveolar process as one approaches maturity, and any tendency to irregularity, if not corrected, causes the irregularity to become confirmed, as the alveolar process at this time is taking on its normal density.

When the child has inherited the small jaw of one parent and the large teeth of the other, the conditions should be harmonized by the early and gradual expansion of the arch, thus encouraging the development of the bone and process. The suture of the premaxillary and of the maxillary bone is not fully united in early childhood, and at this time there is a greater disposition for the tissues to adapt themselves, the bone, and especially the alveolar process, being developed to follow the position of the teeth. At a later stage, when the tissues have become hardened with bony deposit, these changes are not so readily brought about, and the result of expansion or the movement of the teeth is generally less satisfactory.

Continuous pressure on any living animal tissue causes absorption; but the alveolar process contains more organic substance than tooth-structure, and, when force is applied to it, the process yields and allows the tooth to be moved without a corresponding absorption of the root.

The deciduous teeth usually erupt in good position, and their regulation is seldom required, except for the lateral expansion of the arch. Occasionally, however, the incisors and cuspids are malposed.

The age at which to regulate should be determined by the health and temperament of the patient, and by the question as to whether the irregularity is inherited. Delay on the part of the parent or guardian may also prove a factor. I was once consulted regarding the case of a child aged two years and ten months (Figs. 184–186), in which the deciduous incisors and cuspids of the lower arch had closed in front of the upper, occluding with the gum, causing the lower jaw to be extremely prognathous. If these conditions had been allowed to continue, even until the time of the eruption of the permanent teeth, the occlusion and the shape of the jaws would have become so considerably changed that there would have been an obstinate case of irregularity to contend with. Early regulating is frequently essential in cases where the deciduous molars have been extracted prematurely. The loss of the molars removes the natural support from the sides of the arch, and the anterior circle is not expanded and pushed forward. as it naturally should be, by the wedging of the permanent incisors; but in the process of eruption, the permanent incisors, which are broader than the deciduous ones, force the cuspids to take a position in the spaces caused by the extraction. Also, as a result of the extraction, the first permanent molars gradually move forward, usurping much or all of the remaining space intended for the bicuspids. An example of this condition will be seen in Fig. 159.

There are, however, early irregularities of the permanent teeth in the lower and upper arch that will gradually assume a good position when left to nature. Such are instanding laterals and slight torsion of the upper central incisors; each of these, in the majority of cases, will gradually take a correct position through the influence of occlusion and the pressure of the tongue and lips in connection with the progressive development of the jaw and process. Bearing this fact in view, the operator should carefully consider the probabilities of the case.

When the irregularity is inherited, the teeth will generally need to be retained after regulating much longer than otherwise, and in some cases it may be an advantage to delay the regulation until after the eruption of the second molars.

An objection made against the early correction of the position of the incisors, as from torsion, is that the retaining fixture might need to be worn for a considerable length of time to prevent the teeth returning to their original position, and this at an age when the child would not be likely to be attentive in the care of the teeth and appliance. The continued retention of the teeth in such a case is necessary, as the lateral pressure of the incisors is not usually lessened until long after the permanent cuspids have become fully erupted.

To correct the position of prominent incisors when there is insufficient room in the anterior arch, it is sometimes necessary to extract the first bicuspids. When the protrusion is extreme, and is known to be inherited, the regulating should be begun early, even by removing the deciduous first molars and the developed portions of the first bicuspids, sacrificing some of the process if need be, and immediately applying pressure to force the incisors backward to a proper position, closing the spaces. This early procedure, before the full eruption of the bicuspids, is necessary only in cases where the upper incisors are resting on or in front of the lower lip, as this influence alone, when continued, will cause the teeth to become more prominent.

In determining whether to correct the position of the teeth for mature patients, the age is not so much to be taken into consideration as is the permanent advantages to be gained by an operation,—namely, the improved occlusion and appearance of the teeth, the prevention of excessive wear on them, and the contour of the features. In the case of older patients, the health and firmness of the teeth in their sockets must naturally be considered, and whether they are affected with calcareous deposits or pyorrhœa alveolaris. I have been successful in the correction of many cases of irregularity in patients from forty to fifty years of age.

CHAPTER VI

EXTRACTION OF TEETH FOR RELIEVING IRREGULARITIES

The extraction of a deciduous lateral incisor to cause additional room for an erupting permanent incisor is sometimes improperly resorted to, and also the extraction of a deciduous cuspid to increase the space for an erupting lateral incisor. This procedure is objectionable. The adjoining deciduous teeth should be preserved, and the permanent teeth left to wedge their way into place and not allowed to encroach upon the space that should be preserved for the adjoining erupting permanent teeth.

When the teeth are crowded in the arch, and their regulation has been put off until all of the permanent ones have been erupted, the expansion of the arch to make room for the irregular teeth is not always effectual (Fig. 84); the extraction of a tooth on one or both sides of the arch will sometimes give a more desirable result.

I deprecate the loss of any of the permanent teeth, and avoid their extraction whenever possible, but in some cases a better result is attained by extraction, especially where the child has inherited larger teeth than the jaw will accommodate. The articulation and contour of the arch can sometimes be improved materially by early and judicious extraction. On the other hand, where it can be determined from the family history and from examination that the features are to be large, with prominent nose and cheek-bones, the early extraction of the permanent teeth should be avoided, even though the teeth are considerably crowded, as later it may be found that the development of the jaws will leave undesirable spaces between the teeth, and the result will be a sunken appearance at the location of the canine ridge, which is always undesirable.

In another chapter are described methods of expanding the narrow, contracted arch, either before or after the loss of the deciduous teeth, for the purpose of encouraging the permanent ones to take a normal position while erupting. If this has been neglected, and the teeth in the front of the arch have been allowed to assume irregular positions, they usually settle together and occupy less space in the circle than when in a normal line. This permits the teeth on the

sides of the arch to follow their natural inclination and move forward towards the front of the arch, and likewise, when the deciduous molars are lost earlier than should be, the permanent teeth on the sides of the arch gradually move forward. At this stage expansion would not relieve the difficulty. If either of these latter conditions exist it is necessary to move the teeth on the sides of the arch backward again, or to extract one or more of them to provide the required space for the correction of the irregular ones. Otherwise, the placing of the teeth of the front of the arch in position would enlarge the anterior circle and cause them to become too prominent.

Incisors.—The incisors give symmetry and beauty to the expression of the mouth, and their extraction should always be avoided, at least, until it is found by the most careful consideration that their removal is required. There are but few conditions presented to the practitioner wherein the extraction of a permanent incisor for the purpose of regulating is justifiable. In my practice I have not been obliged to resort to this extreme measure in the upper arch.

Occasionally a case is presented with an harmonious articulation of the teeth, except that the lower incisors overlap one another, with the distance between the cuspids too narrow for their proper accommodation. To broaden the space by moving the cuspids outward would interfere with the occlusion, and might require the teeth of the upper arch to be moved outward also. These conditions sometimes justify the extraction of the lower incisor that most aids their correction. By way of example, Fig. 202 illustrates a case in which a fairly satisfactory result was attained by extracting one of the lower incisors (one of the lower incisors having been extracted several years previous) and moving the two others forward. This procedure filled the space between the cuspids, and as these were in good position and of good structure, the removal of the incisor was considered the better practice. The cuspids were then dressed with a corundum stone so as to more nearly conform to the shape of the incisors.

When an incisor is decayed or fractured so that it cannot be utilized, it can be extracted and the adjoining teeth drawn together laterally to close the space, providing the contraction of the arch in this manner does not interfere with the occlusion. This, in some instances, is better than to supply an artificial tooth.

It is sometimes more satisfactory to remove a lateral incisor that

has erupted far inside of the circle of the arch, the cuspid having taken a position in front of it, than to extract a bicuspid or cuspid to make room for it (Fig. 42).

Cuspids.—The cuspids are among the strongest of the teeth. Owing to their character and shape, and to the prominence of their roots, their loss is generally detrimental to the contour of the features. The removal of a cuspid results in the absorption of the canine ridge, which should be preserved, as it gives character to the face and determines the outline of the wing of the nose and upper lip. When the cuspids are considerably prominent, or when their crowns are growing forward, the laterals and bicuspids being of good structure and in good position, the removal of a prominent cuspid often saves the necessity of regulating, and if the position and shape of the bicuspid is similar to the cuspid the loss is not usually noticeable, and therefore not especially objectionable.

Fig. 42.

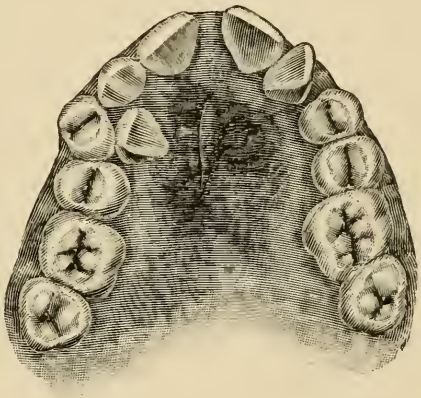

Fig. 200 illustrates the position of the teeth in the upper arch of Miss H. The buccal contour of the bicuspids is similar to the shape and contour of the cuspids. There was no space in the circle for the normal eruption of the cuspids, and they had taken a position in front of the lateral incisors. The cuspids were extracted, and the laterals moved outward, which gave a good result, as shown in Fig. 201.

Bicuspids.—The bicuspids are the teeth usually chosen to be extracted to gain space for the correction of the position of prominent incisors and cuspids, generally removing the first bicuspid on each side of the arch. If the second bicuspid is smaller and has poor occlusion, which is often the case, or if it is not as perfect a tooth as the first, it is preferable sometimes to remove the second bicuspid rather than the first. However, it is generally a mistake to remove the second bicuspids, as they, with the molars, form the anchorage for moving inward the six front teeth; and their extraction lessens the anchorage by one tooth on each side, and also adds one to the

number to be moved backward. (See description accompanying Fig. 467.) Again, in case the second bicuspid is extracted, the backward movement of the cuspid and first bicuspid sometimes causes the latter to pitch backward so as to take an unsightly angle.

When it is decided to extract a bicuspid in the upper arch the prominence of the lower arch should be examined also, and if the teeth are crowded the corresponding bicuspid should be extracted; otherwise, the inward pressure of the front teeth of the upper arch against those of the lower will generally cause them to crimp and become irregular.

Not infrequently, early in life, one jaw develops more rapidly than the other. When this is due to heredity the anterior growth of the jaw can sometimes be lessened by the extraction of the first deciduous molars and the undeveloped first bicuspids, care being taken not to interfere with the bony sockets surrounding the adjoining erupted or non-erupted teeth.

When the second deciduous molar is removed before the eruption of the first permanent molar, the latter moves forward, and when erupted it is almost sure to occupy the position belonging to the second bicuspid, so that when the bicuspid appears there is insufficient space for it, and it erupts either inside or outside of the normal line. If the bicuspid is driven far out of position, it is sometimes found more advisable to remove it than to force the molar backward to give it room.

Molars.—The first permanent molar is physiologically and mechanically the most important tooth for mastication in the arch. Its large crown-surface, situated where the strain of mastication is the greatest from first to last, admirably adapts it to bear the stress; but its early development, before six years of age, when there is insufficient nutrition owing to the great demand of other parts of the bony frame, causes it to be of weak structure and very liable to decay. In cases of irregularity these teeth are often found so broken down that it seems imperative that they should be the ones to be removed. When either the upper or lower arch is too prominent, and extraction is required, it is advisable to examine the jaw carefully before determining which tooth shall be removed, to see if there is likely to be sufficient room for the eruption of the wisdom-tooth. If not, it may be concluded that the jaw will become still more prominent

through the natural anterior development, and the sixth-year molars, if defective, may be removed.

Many practitioners still advise the extraction of the first permanent molars for relieving the crowded condition of the teeth, but the detrimental effects that arise from their early removal should prompt us to study means for their preservation.

A recent writer advises the extraction of the first permanent molars at about six months before the eruption of the twelfth-year molars. But the deciduous molars being lost a little before this time, and the bicuspids not being erupted sufficiently to articulate, the child would be left in a sad plight as regards mastication for a considerable length of time, until the second permanent molars were erupted, and then there would be only one molar tooth on each side of the jaw, which might not occlude well for mastication until the third molars were erupted. Again, the extraction of the first permanent molars in the lower arch, especially before the full form of the jaw has been attained, not uncommonly results in arresting its anterior development, causing recession of the lower jaw, with the lower incisors closing far back of the upper ones. The early extraction of the first molars is advisable in some forms of prognathous jaw.

The simple extraction of a molar or bicuspid, without mechanical interference, does not usually lessen the crowded condition of the teeth in the front part of the arch.

In cases where the lower arch is prominent, the teeth being crowded and the angle of the jaw obtuse, it is sometimes an advantage to remove the second or the third molar.

CHAPTER VII

ANCHORAGE AND APPLIANCES

The first essential of a regulating appliance is that it shall be well anchored, having fixed points of resistance from which force can be exerted for the correction of irregular teeth.

Anchorage is usually gained by attaching apparatus to the crowns of the bicuspids and molars, although when desirable other teeth are utilized.

When the teeth employed for anchorage are in an irregular position their correction should not be undertaken, nor should they be disturbed in their sockets until the positions of all other irregular teeth are corrected, as teeth which have once been moved are not as firm as before, and are more liable to be changed in their position by force applied to them as anchorage teeth.

Jackson System of Anchorage.—Attention is called to the method devised by me for anchoring appliances to the teeth with *spring-clasp attachments.* These are fitted to one or more of the molars or bicuspids on each side of the arch, in some cases depending entirely on them for anchorage; in other cases, using in conjunction with them *partial-clasps* on adjoining teeth. The appliance is made in such a manner that it can be removed and replaced when desired for cleansing or putting on more pressure.

Spring-Clasp Attachment.—This term is applied to the part of the device that clasps a tooth for anchorage. It is made usually of plate-metal and spring-wire united with solder.

The parts of the spring-clasp attachment are named *partial-clasp* and *spring-clasp.* They are made as follows:

Partial-Clasp.—A partial-clasp is a thin piece of plate-metal shaped to fit the side of a tooth, in thickness about No. 35 U. S. standard wire gauge (Brown & Sharpe). It is made of gold, gold-faced platinum, platinoid, German silver, or any suitable metal. Platinoid and German silver have been used extensively for this purpose, and have their advantages when soft solder is used, but preference is generally given to the precious metals, as they are less liable to oxidize.

A correct plaster model of the teeth is first prepared, and a piece of the plate-metal is hollowed to fit accurately one side of each of the teeth that are to be used for anchorage. It can be placed either on the lingual or buccal side, this being determined by the style of appliance to be adopted, but the partial-clasp is always arranged on the side of the tooth on which the base-wire or foundation of the appliance is to be attached. (The base-wire is described later in this chapter.)

When the shape of the tooth is unsuited for anchorage, and in some particular forms of apparatus, it is an advantage to have a partial-clasp on both the labial and lingual sides, but the partial-clasp to which the base-wire is to be attached is always to be made broad, to extend from the neck to the grinding surface, and the one on the opposite side of the tooth is usually made narrow and fitted accurately at the neck.

The partial-clasp is formed by hollowing or contouring a strip of metal of the desired width and length with *contouring pliers*. The pliers should have the side of one beak shaped into a small concave depression into which fits a contoured prominence on the corresponding beak, like the S. S. White contouring pliers (Fig. 43).

Fig. 43.

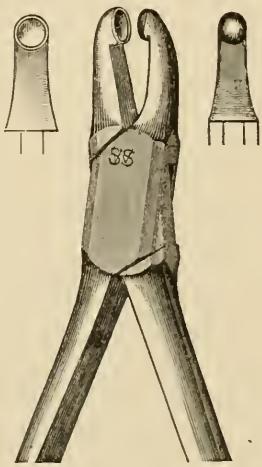

There are many varieties of pliers on the market, but I have found only this one with the concave depression and contoured prominence sufficiently small to be suitable for this work. The metal is placed between the beaks of the pliers and pressed repeatedly until it is evenly contoured. It is preferable that the metal be over- rather than under-contoured before it is applied to the tooth, which will allow for any inaccuracies that may have occurred from injury to the surface of the model. As the metal is being contoured, it should be dressed with scissors to the required form, shaped to press well up about the neck of the tooth, and at the same time curved sufficiently over the prominences towards the grinding surface to prevent the appliance when finished from pressing on the gum (Fig. 44).

Another method of contouring the metal is by placing it upon a

flat piece of lead and stamping it repeatedly with a small round-headed die until the desired form is obtained.

In fitting the partial-clasp to the plaster model it should not be burnished, but pressed into place usually with the finger, using the thumb-nail to bend the edges of the metal into the depressions of the tooth.

Fig. 44.

When the crown of the tooth to be clasped is short, not fully erupted, or of poor form for anchorage, the model should be carved more at the neck, not disturbing the natural shape of the tooth, and the partial-clasp made wide enough to extend up to the true neck of the tooth and over the prominences towards the grinding surface, with the ends shaped to extend around the approximal surfaces as far as is practicable, especially near the neck, to assist in retaining. The antero-posterior width of the tooth is less at this point than towards the grinding surface, and shaping the metal to this part will assist the anchorage of the appliance. If the gum is quite prominent and firm, it is occasionally advisable to make the partial-clasp of thicker metal, so that it will be sufficiently strong to project under the free margin of the gum without the usual addition of solder on that part. This will clasp the tooth equally well, and be less liable to irritate the gum.

Fig. 45.

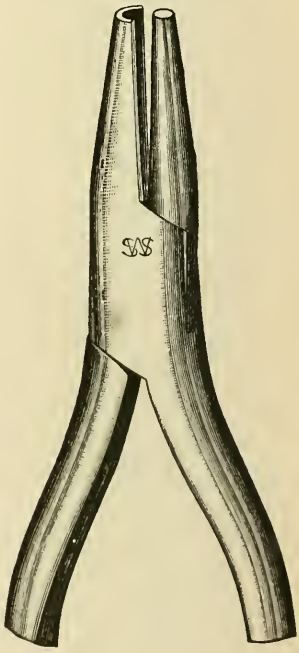

It is usually desirable to have adjoining teeth assist in the anchorage. Partial-clasps are fitted to each, and made to meet at their junction.

A *continuous partial-clasp* is made of one piece of metal resting on several teeth, either contoured with pliers or swaged to fit their surface.

Spring-Clasp.—The spring-clasp is formed with a *clasp-bender* similar to the one illustrated in Fig. 45. The clasp-bender should be of small size. Most of those on the market are rather large for the purposes required, as they do not make sufficiently short curves.

The round beak should be of about the same width near the joint as it is at the outer end.

The spring-clasp is made of a spring-wire of any suitable metal, usually of spring-gold, German silver, or platinoid (piano-wire has been employed), in size about No. 21 gauge, or a little larger, as the case may require. It is shaped to fit near the gum on the buccal or opposite side of the tooth from the partial-clasp described. Both ends pass over the arch, resting in the depressions at the junction with the adjoining teeth, and are curved about the lingual side near the gum line to rest on the partial-clasp; but the spring should fit loosely, so that it will not injure the plaster model in removing it (Fig. 46). The wire is most easily formed by first bending it twice

Fig. 46.

Fig. 47.

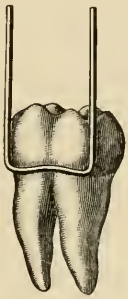

Fig. 48.

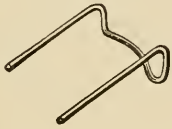

Fig. 49.

at right angles with the clasp-bender (bending it slowly to prevent breaking), having the width between the parallel sides of the wire equal to the antero-posterior width of the tooth to be clasped (Fig. 47). The part that is to clasp the neck of the tooth is then so curved with the clasp-bender that it will be perfectly adapted to the curve of the buccal side. This part of the shaping should always be done before bending the parallel wires downward. It is advisable to mark the wire where it is to be bent. Both of the wires are then marked and placed in the clasp-bender (or each one separately) at a proper distance from the curved portion, and bent nearly at a right angle to cause them to pass over the grinding surface at the junction with the adjoining teeth (Fig. 48), and again bent in a similar manner to extend towards the neck of the tooth, with the ends bent towards each other at the gum line, so that they will rest on the partial-clasp previously described (Fig. 49).

The principle of the clasping power of this attachment to the

sides and neck of the tooth is shown in Fig. 50. The contoured partial-clasp is located on one side, covering the prominences of that side of the tooth, with the ends at the gum line extending slightly around the tooth to grasp it antero-posteriorly. The spring-clasp extends from the partial-clasp in a semicircular form up over the grinding surface, at the junction with the adjoining teeth, and down on the opposite side to the gum line, where the wire crosses and rests on the full width of the tooth. The ends, when finally soldered to the partial-clasp, complete the spring-clasp attachment, which, in effect, grasps the tooth as does a rubber-dam clamp. The grasping power of this attachment depends much upon the elastic properties and strength of the metal used for the spring.

Fig. 50.

The spring-clasp passes over the arch at the junction of the teeth; the models of the upper and lower arch should necessarily be examined together, that the wire may be well located.

Base-Wire.—A base-wire is a curved metal bar forming the foundation of a regulating appliance.

The base-wire can be made of round, square, or flat metal, or by a combination of these forms. Round wire is usually preferred, as it can be reshaped by bending in any direction; while with the wire in any other form it is difficult to attain the same results.

The metals generally employed are spring-gold, platino-iridium, platinoid, or German silver.

Fig. 51.

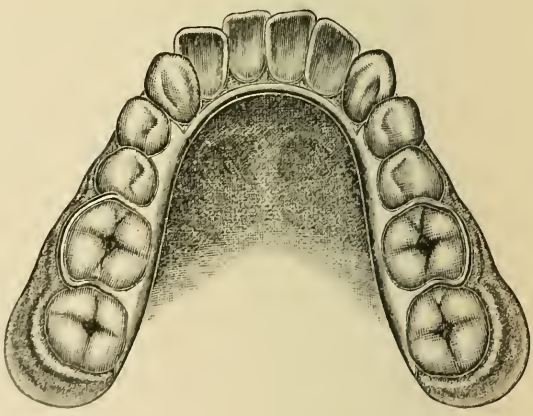

In making an appliance for either the upper or lower arch, the base-wire may be shaped in any form best suited for a foundation.

To assist in designing an apparatus, it is advisable to use tin or lead wire, which is very pliable, shaping it to the model, following the lines which it is intended that the metals of the appliance shall

occupy. In this manner the appearance and the effect of the device it is intended to make can be readily understood.

The bending of the base-wire is most easily accomplished with a large-sized clasp-bender, round-, or flat-nosed pliers.

There are two kinds of base-wire, the *rigid* and the *spring*.

Rigid Base-Wire.—A rigid base-wire is necessarily large; it should be stiff and unyielding to give a firm foundation, to which springs are attached for moving the teeth (Fig. 51). The size of the wire employed generally ranges from No. 12 to 14, B. & S. standard wire gauge, varying according to the strength and rigidity required.

Fig. 52.

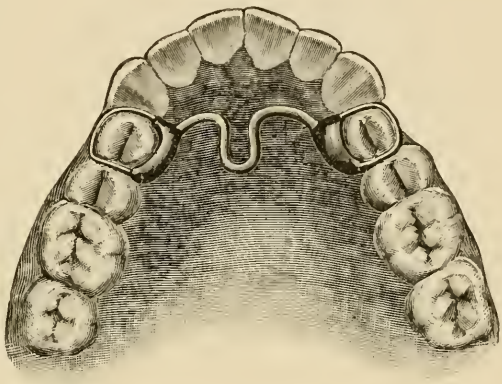

Spring Base-Wire.—A spring base-wire is one that serves both as a foundation and a spring. It is generally made of round metal, and is of a smaller size than the ordinary rigid base-wire, ranging from No. 15 to 12 gauge. Usually it is formed like the rigid base-wire, but when it is required to be more springy it is bent into one or more U-shaped loops (Fig. 52).

Fig. 53.

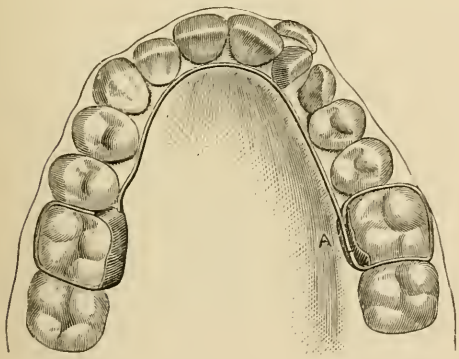

Forms of Base-Wire.—Three forms of base-wire will be described,—the *lingual*, *labio-buccal*, and *palatal* or *palatine*. They are named according to the location in the arch in which they are to rest.

Lingual Base-Wire.—The lingual base-wire is applied on the lingual side of the teeth of the lower or upper arch. It should generally be shaped to follow the line of the gum, with the ends

extending backward on either side, to cross one or more partial-clasps, to which it is soldered with the ends of a spring-clasp for anchorage (Fig. 53, A). The lingual base-wire is more generally used than other forms, especially for apparatus in the lower arch.

Fig. 54.

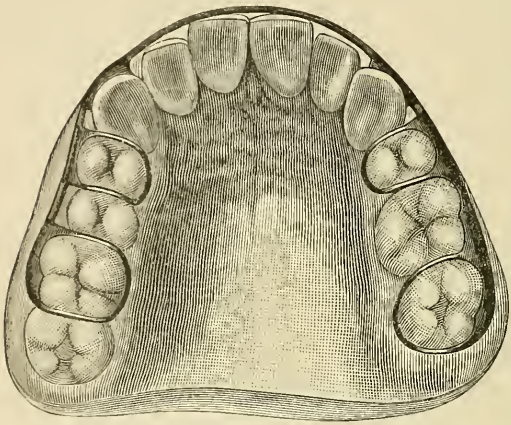

When increased rigidity of the apparatus is required, a smaller wire can be added, shaped to rest close to the teeth a little in front of the base-wire and united to it with solder, or a larger sized wire may be substituted.

To make the base-wire less prominent when the appliance is finished, the parts that cross the partial-clasps can be flattened on the inner side by dressing with a corundum stone or file before soldering.

Labio-Buccal Base-Wire.—A labio-buccal base-wire is shaped to cross the labial and buccal side of the teeth near the gum, with the ends extending backward and soldered to spring-clasp attachments for anchorage (Fig. 54).

Fig. 55.

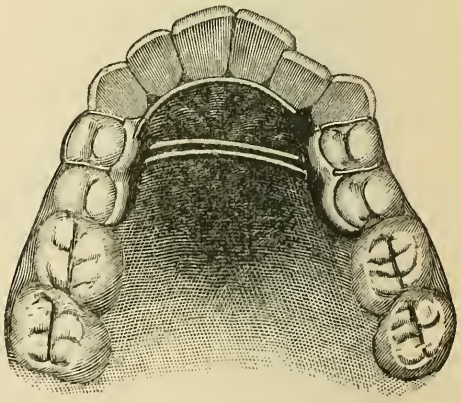

This form of base-wire is applicable in making apparatus for correcting certain conditions of the occlusion of the upper and lower teeth, and for the purpose of retaining them.

Palatal or Palatine Base-Wire.—A palatine base-wire is one that extends across the upper arch from the teeth to be used for anchorage on one side, following the palatine curve, to the teeth on the opposite side, with the ends usually bent at a

right angle and soldered to spring-clasp attachments for anchorage (Fig. 55).

The palatine base-wire is utilized in making many forms of appliances for the upper arch, on account of the convenience and comfort it affords the patient, as well as for increasing the rigidity of the apparatus. It can be used to especial advantage in case the lower incisors close near the gum on the palatal side of the upper incisors, when a lingual base-wire would interfere with the tongue in the pronunciation of the articulate sounds *t*, *d*, and *s*.

Usually sufficient rigidity is gained with one large wire, but at times, as when a long finger spring is used, it is an advantage to add to its stiffness. One or more wires, as required, may be formed to run parallel with the base-wire with a space between them, or to rest close together and be united with solder as illustrated. Any other part of an appliance can be stiffened in a similar manner. In uniting the wires, a more satisfactory result is occasionally obtained by fitting a thin piece of partial-clasp metal underneath them on the model before soldering. If three wires are to be used together, the two outer ones should be of smaller size and united with solder in the same manner; or the base-wire can be made of a piece of heavy flat metal.

The general rigidity of an apparatus is sometimes best attained by utilizing two forms of base-wire in conjunction, as a palatine base-wire crossing the distal part of the arch and a lingual base-wire following the palatal curve of the anterior teeth, with the ends of each shaped to cross the partial-clasps to which they are soldered for anchorage. The palatine base-wire and the labio-buccal base-wires can be used together, or the labio-buccal and the lingual base-wires can be utilized when the conditions require.

Not infrequently, after the front teeth have been regulated, it is found that the arch needs to be expanded laterally. When a lingual base-wire has been used, the simple bending outward of the sides of the base-wire may be effective. With a palatine base-wire, when only slight expansion of the upper arch is required, the base-wire can be straightened a little at a time, or a spring base-wire can be inserted, of the shape illustrated in Fig. 97. The rigid base-wire can be converted into a spring base-wire by removing a section from the median line and soldering to place a U-shaped loop of similar metal (Figs. 369, 370).

This change is most easily made by passing two narrow, short pieces of thin partial-clasp metal underneath the base-wire when the appliance is in position in the mouth, placing them a little either side of the median line. Then take an impression of the palatine part of the arch with the appliance and metal in place. Remove the impression and the appliance from the mouth together. Place the pieces of plate-metal in position in the impression, and run a model. Without removing the appliance from the model, saw a section from the centre of the base-wire and adjust a U-shaped loop of the same wire metal. Bend the thin pieces of metal around the ends of the loop and the base-wire and unite them with solder. The loop should be made narrower from side to side than the shape of the arch would indicate, to permit the opening of the loop for the necessary expansion of the arch without causing undue pressure on the soft tissues of the lateral sides of the vault.

Teeth best suited for Anchorage.—As a rule, the anchorage should include more teeth in number than those to be moved. In other words, the teeth for anchorage should be capable of resisting more force than that required for moving the irregular teeth.

Naturally, the teeth most firmly set in the arch are the ones chosen for anchorage, as the molars, bicuspids, and cuspids. Any of the teeth may be employed. The anchorage is always much more complete when several of the teeth are in contact. A molar, owing to its size and number of roots, when standing alone in the process is generally capable of resisting a force sufficient for the correction of one or more irregular incisors, but it might not be sufficient for the movement of a cuspid. The same is true of a bicuspid; it might be sufficient for the movement of one or more incisors, but it is not as firmly set in the process as the molar and is a less certain anchorage. The cuspid, owing to its increased length and the size of its root, is sometimes invaluable for the purpose of anchorage. An irregular cuspid has been known to resist a force applied from all of the other teeth in the arch, and finally, instead of itself yielding, to cause their movement.

From experience it is found that a spring-clasp attachment to one tooth on each side of the arch, in connection with partial-clasps on the adjoining teeth, is usually sufficient to retain and anchor an appliance.

In young patients, the second deciduous molar, when firm in the

arch, is generally utilized for anchorage because of its position and shape. The rounded contour of the crown is especially favorable for retaining with the spring-clasp attachment. The diverging roots, before they have become absorbed, afford a resistance for this form of anchorage equal to almost any of the permanent teeth. Its degree of resistance will be readily understood by those who have had occasion to extract one of these teeth while the roots were intact. From its position just in front of the first permanent molar it receives sufficient support to give a good anchorage for moving the incisors outward, etc., but partial-clasps should be adjusted to each of the adjoining teeth (Fig. 56). With this arrangement, although but one spring-clasp attachment is used on each side of the arch, the adjoining teeth are included, which strengthens the anchorage and steadies the apparatus. The latter is especially necessary when the arch is to be expanded. If the appliance is to draw prominent incisors into line, it is advisable to have the base-wire terminate in a curve on the distal surface of the first permanent molar, or, instead, to have a smaller wire extend from the base-wire back of the molar.

Fig. 56.

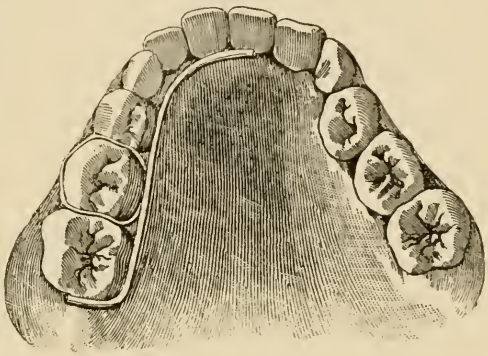

Fig. 57.

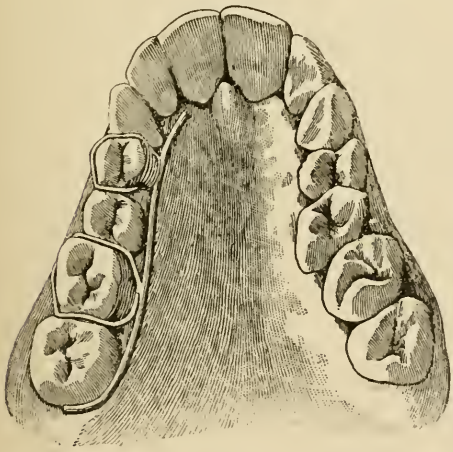

In an adult, where the bicuspids and the first and second molars are erupted (Fig. 57), the attachments for anchorage should be to those teeth most suitable by their shape and location, usually to one

of the bicuspids or the first molar on each side of the arch. If the second molar is well erupted, a stronger anchorage can be made by forming one spring-clasp attachment to it and another to the second bicuspid; or, as usually preferable, partial-clasps may be adjusted to all of the teeth to be used for anchorage, with spring-clasp attachments to the first bicuspid and first permanent molar, and the base-wire, or a smaller wire, made to extend beyond and terminate in a curve on the distal side of the second molar.

Teeth not fully erupted, or with a portion of the crown lost by decay, can be utilized for anchorage by soldering a thin piece of plate-metal to the anchorage portion, in position to pass between the teeth, and thus to secure a good attachment.

When a tooth that is not fully erupted is needed for anchorage, the gum can be pressed away from it in some instances, separating it sufficiently towards the neck for the application of a partial-clasp by forcing between the gum and the tooth a sterilized cord, or a small amount of sterilized cotton, or, when necessary, tying the cord around the tooth and allowing it to remain, and repeating the operation at intervals several times. Generally, however, the simple carving of the model will suffice. The partial-clasp used for this condition should be made of a thicker metal than that ordinarily used, and shaped to project under the margin of the gum. In soldering, the part that is to extend under the gum should be kept free from solder.

With the system described the base-wire can be anchored to the teeth in many ways. The principal method employed is with spring-clasp attachments.

In some cases partial-clasps are used independently, especially in the lower arch, or they may be used in conjunction with points of metal, shaped to project into the interdental spaces, usually on the sides of the arch; or the appliance may be retained with wire or with flat metal clasps passing around the teeth. Wire springs have been employed, passing from the partial-clasps and base-wire over the grinding surface at the junction of the teeth, and terminating in the form of hooks to rest in the buccal interdental spaces; or the ends of the springs may be left longer and shaped to clasp the surface of the teeth at the gum line for anchorage.

In some cases, when the anchorage is found insufficient, a hole can be drilled through the partial-clasp at the junction of two of the

teeth at an angle suitable for the introduction of a short screw, or of a wire soldered in place to extend into the interdental spaces near the necks of the teeth. Strips of plate-metal can be bent to hook over the incisive edge of the incisors and cuspids. In an emergency the appliance may be retained by cementing it to place with oxyphosphate, or by passing a ligature around the base-wire and between the teeth used for anchorage, with the ends tied tightly to the outer part of the spring-clasp at the gum line. Rather than continue the use of the ligature in any case, it is better to remake the appliance.

Fig. 58.

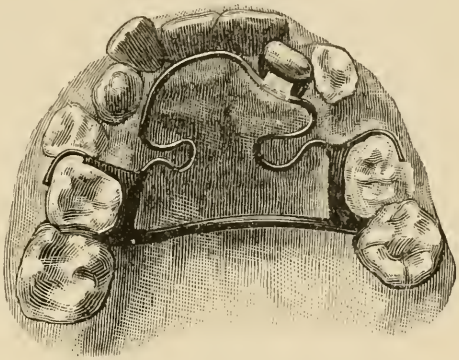

Fig. 58 illustrates an anchorage made by arranging partial-clasps on the palatal side of the second upper deciduous molars, and attaching to each a *wire-clasp*. When there are spaces between the teeth, the wire-clasps can pass directly around to the buccal side. If the teeth are close together, the wire-clasp may be curved to pass over the grinding surface at the junction of the teeth and bent to rest on the buccal surface of the tooth near the gum. The remainder of the appliance is made in the usual manner, with base-wire and spring, the parts being united with solder.

Fig. 59.

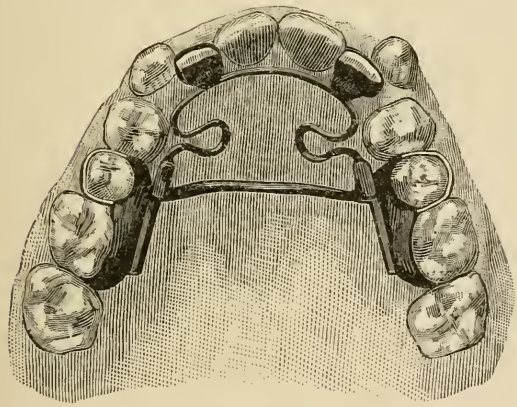

Another variation from the regular form of anchorage is shown in Fig. 59. When the device is adjusted, it admits of the removal of the spring without removing at the same time the body of the appa-

ratus. The latter is made with a palatine base-wire and spring-clasp attachments over the second bicuspids, with partial-clasps on the first molars and first bicuspids. A tube is soldered in the centre of the anchorage portion, on either side, the distal end of the tubes being closed; or a slight flange is placed on the spring to prevent it from entering the tube too far. A semicircular spring for moving the teeth is bent into two U-shaped loops, with the ends shaped to project slightly into the tubes described. Tubes, eyelets, or hooks soldered to the anchorage portion, base-wire, or to spring-clasps, are used.

When one is accustomed to the use of *collars* for anchorage, this system is utilized by anchoring a base-wire as follows: A collar, with a tube soldered on the lingual side, is cemented to a distal molar and to one of the bicuspids on each side of the arch. The tubes can be arranged to rest horizontally or perpendicularly. A heavy lingual or palatine base-wire is held in position by soldering to it a small strong wire in position to enter the tubes. Wires entering the tubes on the molars are sometimes arranged to hook into the tubes from the distal end, while similar wires are attached to the base-wire to enter either horizontal or perpendicular tubes on the bicuspids. When tubes are arranged perpendicularly on the collars, they are generally inclined a little either forward or backward to improve the anchorage, so that when force is applied the apparatus will not become dislodged. A labio-buccal base-wire is anchored in a similar manner. When desirable, all of the tubes can be arranged perpendicularly. The anchorage teeth are prevented from rotating, when extreme stress is put upon them, by soldering the tubes on the mesio-lingual or the disto-lingual surface of the collar, according to the strain to be applied.

Fig. 60.

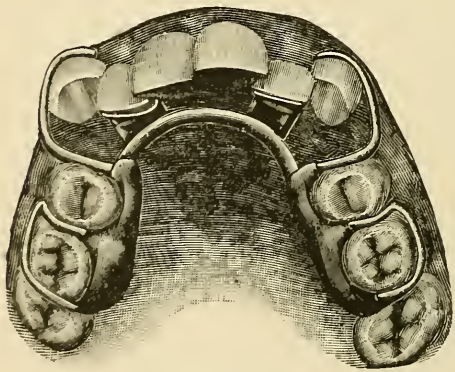

Fig. 60 illustrates a case in which a strong anchorage was necessary. The upper cuspids were very prominent, with insufficient

space for their correction, requiring the extraction of the first bicuspids to permit them to be moved into the circle. The lateral incisors were also irregular, needing to be moved outward and laterally. The points of resistance included the first molars and second bicuspids, re-enforced by the instanding lateral incisors. At that time the second molars were not sufficiently erupted to assist the anchorage. An appliance was made by forming a spring-clasp attachment to the first molar and a partial-clasp on the second bicuspid on either side, soldered to a lingual base-wire following the inner curve of the arch in the usual manner. The anchorage was fortified by shaping pieces of plate-metal to the palatal side of the lateral incisors and uniting them with solder to the base-wire near the gum. In this way a firm anchorage was obtained. The cuspids were moved to position with finger-springs attached to the partial-clasps and base-wire, one on either side of the arch, after which the projecting pieces of plate-metal, located back of the laterals, were again utilized. They were bent forward slightly from time to time, causing them to act as inclined planes on the laterals for moving them outward to line.

Fig. 61.

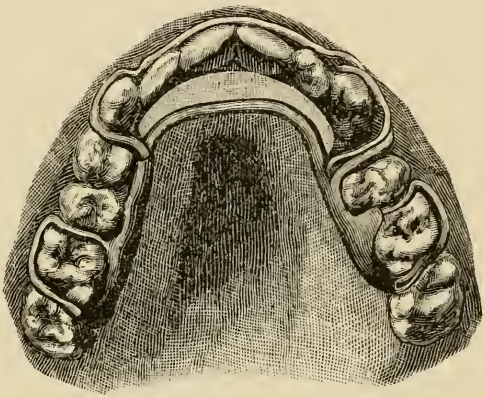

When desirable, the anchorage of similar appliances can be strengthened by cementing to one or more of the front teeth a collar with a narrow lug on the lingual side, in position to engage with the base-wire; or wire-clasps, shaped to encircle the second bicuspids and to rest on the buccal side, may be attached to the base-wire. In the same manner wire-clasps can be extended backward from the base-wire to clasp the second molars. If the latter are only partially erupted, the ends of the springs may be bent sharply upward to rest back of them near the neck. When upper incisors require to be rotated and the cuspids drawn backward, with the lower incisors impinging against the gum back of them, a device as illustrated in Fig. 61 is applicable. The base-wire is necessarily placed farther

back of the incisors than usual to prevent interference with the lower incisors in occlusion. When so arranged, the anchorage of the front part of the appliance can be made firm by fitting to the model a piece of plate-metal, shaped to extend from the lingual side of the incisors backward under the base-wire to which it is soldered. Swaging of the metal is not usually required. The distal part of the appliance should be well anchored with partial-clasps and spring-clasp attachments.

When a molar or bicuspid is absent the anchorage can be made with a spring-clasp attachment passing over a tooth on either side of the space. It is sometimes an advantage to fill the space with an artificial tooth or a block of metal, uniting them to the base-wire.

After the loss of a deciduous molar, a permanent molar, or a bicuspid, there is a tendency for the erupted and non-erupted back teeth to move forward and occupy some of the space. As these teeth move forward they do not usually move bodily. The crowns are broader near their grinding surface where they rest in contact, and when they are pressed upon by the erupting teeth back of them they are gradually tipped forward in the line of the arch, disarranging their harmonious occlusion with the antagonizing teeth. For this reason teeth should not be extracted for the purpose of making room for the correction of prominent front teeth until about the time when a regulating appliance is to be inserted. The open sockets after extraction also favor the rapid backward movement of the teeth in front, closing the spaces.

Fig. 62.

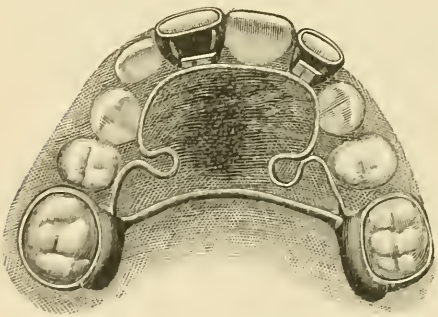

Fig. 62 illustrates the position of the teeth of a boy aged nine years. The deciduous molars were extracted too early. From lack of support the first permanent molars had moved forward, and the front part of the arch had not kept pace in anterior development with the lower arch, causing the upper incisors to close back of the lower ones. This required the outward movement of the upper incisors to articulate properly, and the backward movement of the molars to make room

for the erupting second bicuspids. Anchorage for their correction was gained by a spring-clasp attachment passing over each of the first permanent molars connected with a palatine base-wire. To this was attached a spring with a semicircular part arranged to rest on the palatal side of the incisor teeth near the gum, and two U-shaped loops about one-fourth of an inch long, one on either side of the arch pointing towards the median line, with the ends of the spring soldered to the partial-clasps and base-wire. The spring was anchored to the incisors by passing under a lug on a collar cemented to one of the laterals, and under another lug to one of the centrals. Opening the loops in the spring by bending caused the necessary

Fig. 63.

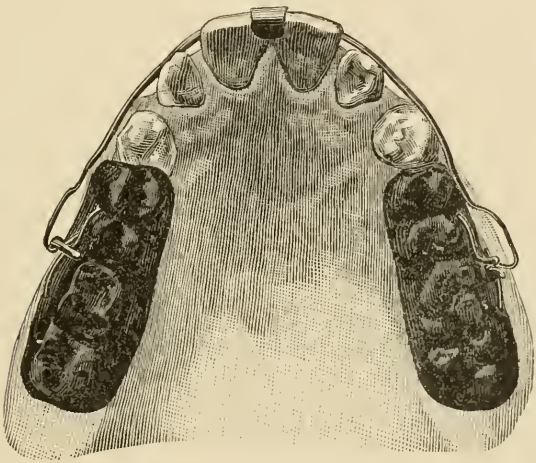

pressure for moving the incisors outward, and at the same time the molar teeth were gradually forced backward, providing space for the erupting second bicuspids.

Metal Caps.—The methods of anchorage described are usually sufficient, but sometimes, in special cases, there may be an advantage in the use of metal caps, one on either side of the arch, the cap being properly struck up to fit over the teeth used for anchorage and well cemented to them (Fig. 63). A continuous metal cap can be used when the conditions require. When partial caps are employed, they should cover as many teeth as practicable, with the edges extending to the gum on the buccal and lingual sides. The cap is stiffened to prevent warping by soldering to the edge a strip

of plate-metal or a small wire. The parts, after being fitted, can be held together for soldering with small binding-wire passing through small punch-holes provided in the cap. When there are spaces between the crowns of the teeth the cap can be further stiffened by soldering a septum of thin plate-metal or a wire across the inner side. Any suitable apparatus can be soldered directly to the cap, or attached by means of *eyelets*, *hooks of wire*, *tubes*, etc., soldered to the cap.

Cementing Caps.—When the cap is shallow the inner surface should be roughened or stippled with a sharp instrument to prevent its separating from the cement, but when the cap is deep, stippling is not required. In adjusting, the teeth should first be cleansed, made dry, and the cap held firmly in place until the cement is hard. When properly distributed, the cement is forced into the depressions and interdental spaces, covering the surfaces of the teeth, preventing injury from the secretions, and giving a strong anchorage.

The cap can sometimes be more strongly retained by passing one or more small wire ligatures between the teeth and through holes in the labial and lingual sides of it when cementing; the ends are to be fastened by twisting. The metal of the cap, if thin, does not interfere materially with the occlusion.

In the figure is seen a semicircular spring passing in front of prominent incisors for drawing them inward to line. The ends of the spring are bent into U-shaped loops, each terminating in a hook to engage with an eyelet soldered on the buccal side of the caps. The eyelets are usually made of wire with the ends extending at a right angle in opposite directions where they rest on the cap.

A metal cap for the anterior part of the arch is sometimes employed as anchorage for moving other teeth, for supporting teeth when being moved bodily, and for retaining teeth after regulation (Fig. 64).

Fig. 64.

Owing to the difficulty in swaging a cap for the incisors and cuspids, it is usually more satisfactory when made of two pieces of metal, first swaging with metal dies a piece of plate to cover the labial side of the teeth, with the metal shaped to project a little over the margin of the gum and the incisive edge of the teeth. The swaged part is then held in place on the plaster

model, while an accurate impression is taken of the palatal side of the teeth and edge of the metal. From this other dies are made, and the metal swaged as before; the edge of each part is trimmed to fit the other accurately, and held together with wax. The parts of the cap are then supported with plaster and sand, and soldered in the usual manner.

Improperly anchored regulating appliances sometimes cause undesirable tipping of the molars.

It is important that teeth used for anchorage should be so supported that they will remain in an upright position, and not be changed by the stress put upon them. To accomplish this, as many teeth should be engaged in the anchorage as can well be employed, even including, when necessary, some of the teeth that later are to be moved in the process of regulation. (See Fig. 60.)

Plates.—The following figures illustrate the use of plates for anchorage. The plate covers a considerable surface, and prevents irritation when severe upward or side pressure is applied. It has the advantage in anchorage gained by resting against the anterior palatine arch. It should be well retained, so that it will not move when resisting the force necessary in regulation.

Fig. 65.

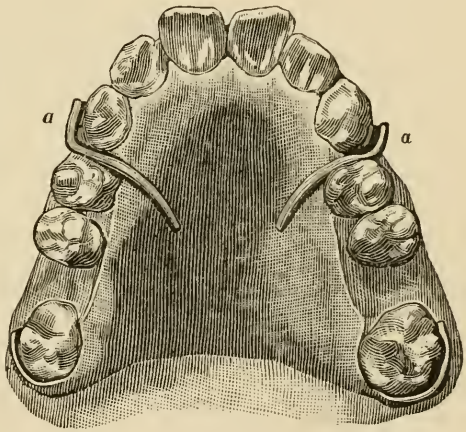

The plate for anchorage in moving bicuspids is illustrated in Fig. 65, the case of Miss M., aged fourteen years. The teeth were very prominent, with no spaces between them. The first permanent molars, being decayed, were extracted to accommodate the bicuspids, which were moved backward in the arch to cause room for the inward movement of the six front teeth. The plate covered the palatine arch, being retained by fitting well the necks of the incisors, cuspids, and second molars. To the latter it was further secured with wire-clasps. A curved metal spur projected from either side of the plate to rest back of the cuspids. The anchorage, therefore,

included the spurs, the attachment to the second molars, and the resting of the plate against the curve of the anterior palatine arch and the necks of the front teeth. This is usually effective in preventing the molars from moving forward. The bicuspids were forced backward with finger-springs located in the centre of the plate either side of the median line. The free ends extended laterally outward and rested in front of the bicuspids, passing to the buccal side, where they were bent forward as seen at *a*, *a*. The ends of the clasps and springs anchored in the plate were first flattened with hammer and anvil to retain and prevent them from rotating. Only a small portion of the end of the wire should be flattened, as it is found that it is not so easily broken in bending when embedded a considerable distance and left round where it emerges from the vulcanite. Swaged or cast metal plates can be employed.

In this case the bicuspids were large and their movement rather slow. To hasten the operation, supplemental force was applied by an external apparatus consisting of a cranial-cap and cross-bar device, which engaged with the free ends of the springs *a*, *a*. By this means, the bicuspids were moved backward to the required position as seen in Fig. 66 in a limited time. For further details of the case see page 398.

Fig. 66.

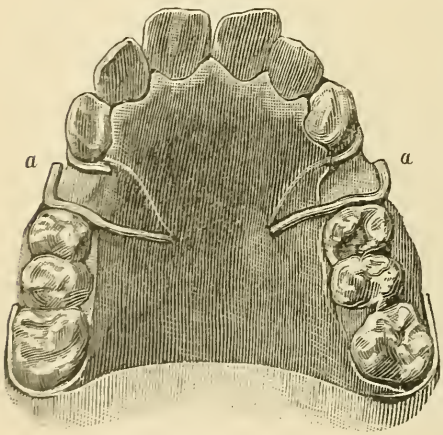

In Fig. 67 is shown a vulcanite palatine plate for anchorage that is suitable for moving backward six prominent upper teeth, or a less number.* The plate is retained by fitting well the necks of the anchorage teeth, and with wire-clasps about No. 19 gauge extending from it to pass around a molar and a bicuspid on each side of the arch, as seen in the figure; or it can be retained with spring-clasps of No. 20 or 21 gauge passing over the teeth, the clasps being shaped similar to those used in spring-clasp

* Jackson, Dental Cosmos, 1888, p. 510.

attachments. Clasps of the shape illustrated are usually preferred, as changes to fit the surface of the teeth are more readily made.

When the distal molars of the arch are not well erupted, and when the gum is quite prominent, the end of the wire-clasp may be bent upward to project under the gum towards the neck of the tooth, or it can be arranged to pass over the arch at the junction of the teeth to clasp the one next in front.

When the central incisors are more prominent than the laterals and cuspids, the irregular edge of the plate should be smoothed, and the portion just back of the centrals cut away a little to permit their inward movement. With this arrangement, the lateral incisors and cuspids assist the anchorage of the plate until at a later time,

Fig. 67.

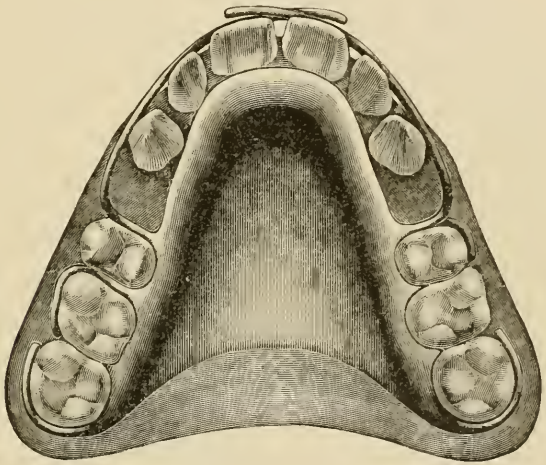

when the plate back of these teeth is also dressed away a little for their movement. The force for moving the incisors is supplied by finger-springs attached in the plate, one on either side of the arch. They are shaped to extend to the buccal side in front of the second bicuspids, and curved forward to rest on the labial surface of the incisors, each spring extending beyond the median line; thus they pass one another and serve as mutual support. Pressure applied in this manner on the central incisors alone forces them inward towards the plate, they acting as a wedge between the adjoining teeth, pressing them laterally and backward. By proceeding in this way

less force is required for starting all of the six front teeth in their movement.

In some forms of anchorage with the plate, where slight pressure is required, it can be held in position by suction, being fitted well to the necks of the teeth. In other cases one or more spring-clasps may be anchored in the plate on either side, shaped to extend over the arch at the junction of two of the teeth to the buccal side, and terminating in a hook to project into the interdental spaces. Or a collar with a lug attached can be cemented to a molar or bicuspid on either side of the arch, the lug being shaped to project slightly over the plate when pressed into place.

When the plate is used for retaining incisors that have been moved outward, it is often necessary to cement to each of them a collar with a strong lug on the palatal side, shaped to project over the edge of the plate for anchorage. The lug always should project at a right angle with the long axis of the tooth.

Fig. 68.

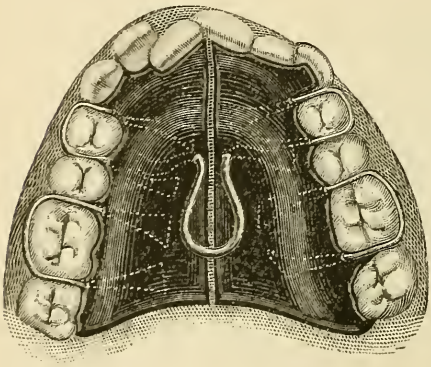

Fig. 68 illustrates a modified Coffin split plate, anchored with spring-clasps, passing over a first bicuspid and first molar on either side of the arch. Wire-clasps can be used when preferred. If the teeth are not well developed, the model should be carved to lengthen them, forming a groove as in the application of partial-clasps, the rubber being extended well up about the neck.

External Anchorage.—Anchorage secured by the attachment of apparatus to available teeth in the dental arch is sometimes not sufficient to resist the force necessary for correcting the position of irregular teeth in other parts of the arch. For instance, in correcting protrusion of the permanent upper incisors, before the eruption of the second permanent molars or the biscupids, with the deciduous molars absent, we have only the first permanent molars to serve as anchorage for moving inward all of the front teeth; again, when the first permanent molars are lost from decay, in the

Fig. 69.

Fig. 70.

correction of anterior protrusion, the second permanent molars are the only available teeth for anchorage.

The necessity of additional anchorage for moving the teeth in similar cases prompted Dr. Kingsley, in 1865,* to devise a method of utilizing the back of the head for anchorage with a cap, making the attachment to the teeth with a gold frame and external bars.

I employ a cap for anchorage, as seen in Fig. 69, which I term a *cranial-cap*. It is made of a heavy netting or with large silk twist, crocheted usually around a common centre, leaving meshes about one-half inch square. This is supported by a band of silk ribbon one and one-half inches wide, the ribbon being doubled upon itself to enclose the edge of the crocheted part to which it is sewed. The band should be sufficiently large to rest loosely about the head, letting all of the strain come on the netting when force is applied. If fitted tightly, it is liable to cause discomfort. To the band are sewed suspenders of the same ribbon material, usually four in number, one located just back of each ear and another considerably in front, the exact location of their attachment being determined by the direction of the traction required. The part of the suspender united to the band is broad, while the lower portion is narrow and of a uniform width to pass easily through a small buckle. To the buckles are attached hooks for supporting elastic bands. In attaching the hook, a rather stiff piece of plate-metal, usually of German silver, as wide as the buckle and about one inch long, is passed around the bar of the buckle and united to it with solder. To the back of the metal, resting towards the cheek, is soldered a large hook of wire, or a hook purchased in the market as "hooks and eyes." If preferred, the hook can be soldered directly to the buckle. When in use the elastic bands are stretched over knobs on a cross-bar device connected with the teeth. Thick rubber bands of pure gum, about five-eighths of an inch in the inner diameter, give the best satisfaction. Sections cut from pure gum tubing, inner diameter about one-fourth inch, have been satisfactorily employed.

The advantage of the use of the buckle in connection with rubber rings for making definite changes of pressure is apparent.

The cranial-cap is placed well back on the head when used for

* Kingsley's Oral Deformities, p. 134.

reducing anterior protrusion of the upper or lower incisors, for moving inward upper or lower cuspids, for moving cuspids, bicuspids, or molars backward in the line of the arch, and for the reduction of prognathism. It is to be placed forward on the head, thus drawing more upward, when used for depressing extruded upper incisors, for correcting lack of anterior occlusion, for improving the general occlusion of the teeth, and for preventing mouth-breathing.

Cross-Bar.—A cross-bar is a bar of metal curved to cross in front of the face, with the centre pivoted or hinged to apparatus passing over the teeth or to a chin-cap. It is used in connection with a cranial-cap for causing force in regulating. Each end of the bar is provided with one or two small knobs, over which are hooked rubber bands. Generally the cross-bar is made by uniting two bars in the centre, with the ends separated a little to improve the line of traction.

Fig. 69 illustrates a cross-bar of German silver spring-wire, about No. 8 B. & S. gauge. Any suitable material can be used. A tin or lead wire is first shaped approximately in the form of the cross-bar desired. Placing it before the face, note the length of the arms and the width between them, with the two arms near together at the centre or median line, diverging gradually to about one and one-half inches apart at either end, where it is formed into a shallow loop. Then place the wire on a paper and make a pencil tracing by marking either side of it, thus forming a pattern, over which the wire cross-bar can be shaped. The two ends of the wire are to be arranged to meet in the centre of the bar, and united with silver solder to a narrow piece of heavy German silver plate about one inch long. At the same time attach to the inner surface and centre of the plate a short piece of large wire, usually bent at a right angle and formed into a post about three-eighths of an inch long, flattened laterally, with a hole drilled near the free end for the passage of a pin for hinging it to a trough-shaped device passing over the incisor teeth. To the end of each of the arms on the corners of the cross-bar is soldered a metal knob three-eighths of an inch or more in diameter, and suitably formed for the attachment of rubber rings.

For changing the line of traction with the suspenders, the loop part of the wire at the ends of the cross-bar can be bent to draw the arms closer together or straightened to force the arms farther apart (Fig. 70).

The latter is also an advantage in preventing the suspender from resting against the ear.

Improved Cross-Bar.—An improved adjustable cross-bar is shown in Fig. 71. In making it, a piece of German silver about one inch long, one-half inch wide, and three-sixteenths of an inch thick, termed a centre-piece, is employed. In the centre of one side a threaded hole is cut for the adjustment of a post about three-eighths of an inch long (*a*), and two holes are drilled in each end for the

Fig. 71.

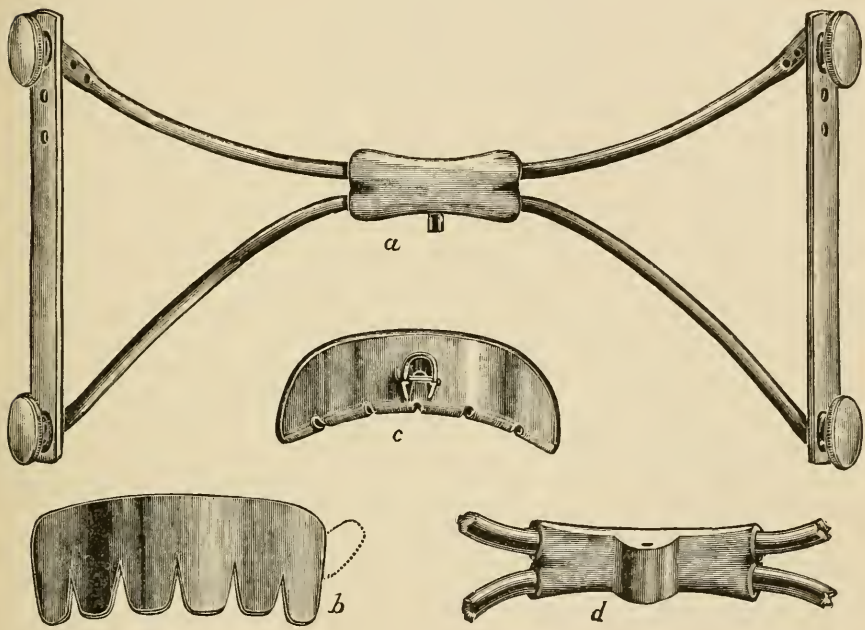

adjustment of arms of spring-wire, about No. 8 B. & S. gauge, and fastened with soft solder. The length of the arms is determined by shaping them to the face, leaving them sufficiently long to prevent pressure on the cheeks from suspenders extending from a cranial-cap. The arms diverge to about one and one-half to two and one-half inches at their outer ends, where they are flattened, and a threaded hole cut in each for the insertion of a screw supporting a knob. The ends of the arms are connected and made more rigid by a stay-piece, made of a bar of rather stiff plate-metal, about one-fourth of an inch wide, with a hole in either end,

through which the knobbed screws are passed when turned to place, clamping them to the arms. A longer or shorter stay-piece can be inserted for improving the lines of traction, or extra threaded holes can be made in the stay-pieces, or in one or both of the bars. The cross-bar is used in depressing the upper incisors and for moving them inward by hinging the post (*a*), as described, to apparatus, or to a removable trough-shaped device passing over the teeth (*c*). This device is made of a piece of stiff sheet-metal about three-fourths of an inch wide, and long enough to be curved and to cross the labial side of two or more of the incisors as desired, usually reaching on to the cuspids. One edge of the metal is arranged to rest near the gum. From the other edge, projecting below the incisors, are cut V-shaped pieces opposite the line of the junction of the teeth and reaching to the incisive edge, as shown at *b*. The remaining sections of the metal, corresponding to the teeth, are curved backward to pass over them and rest on the lingual side (*c*). To stiffen the metal a small wire is soldered around the upper edge and ends.

A socket is made by bending a narrow strip of plate-metal in the shape of a horseshoe, with the inner diameter a little more than that of the post.

On the inner side at the end is soldered a wire of small size to form a flange. The other end is attached with solder to the front of the device, near the lower edge at the median line. The post is held in place in the socket by a pin which is passed through holes in the lateral sides near the entrance, the ends of the hole through the post (*a*) being reamed to permit a rocking motion. The cross-bar, hinged in the centre in this way, acts like a whiffle-tree, always bearing in a direct line, even when one end of the bar is disturbed by the patient in sleeping on the side.

Dr. C. L. Goddard* constructs a cross-bar by making a vulcanite cap to pass over the teeth to be moved, fitted to the labial and to a part of their lingual surfaces, the vulcanite enclosing a bow-shaped wire bar, with each end curved into the form of a hook.

Chin-Cap.—A chin-cap (Fig. 72) is made as follows: An impression of the chin is first taken, as described in Chapter IV., Impressions, and a model made, from which a die and a counter-die are prepared.

---

* Goddard, American Text-Book of Dentistry, p. 624.

Fig. 72.

It is advisable to make a pattern a little larger than the chin-cap required.

A sheet of metal, usually of German silver, about No. 25 gauge, is shaped with the fingers to the front part of the die, with the centre at the prominence of the chin. Two cuts are then made in the projecting side, towards the centre, approaching one another within about three-fourths of an inch. The central separated part is then bent downward over the die to rest underneath the chin, and the parts on either side are bent backward to overlap the central portion, and also to rest under the chin. The projecting excess of metal is cut away, leaving a sufficient lap. It is then further shaped to the die, swaged, and soldered with silver or German silver solder.

To the front and lower portion of the cap, crossing it horizontally, are attached two curved wires No. 8 gauge, either square or round, about two and one-half inches long, and half an inch apart at the centre, with the ends diverging and soldered to the cap, for stiffening it and forming a hinge. The wires are best held for soldering by fastening them with binding-wire, passing it through small holes in the cap provided for the purpose. Through each of the curved wires a hole is drilled perpendicularly at the median line for the insertion of a pin in hinging the centre-piece of a cross-bar. A cross-bar, as in Fig. 71, is attached to the chin-cap, with the centre-piece made as illustrated at *d*, the inner side being thickened in the form of a ridge crosswise, through which a hole is drilled, and connected to the chin-cap with a pin.

The cross-bar attached to the chin-cap in this manner applies direct force at the point of the chin, and at the same time permits a rocking motion which is desirable, preventing interference or displacement of the cap when the patient is lying on the side.

When the chin-cap is used for reducing prognathous conditions, the cranial-cap is usually placed far back on the head to get the necessary line of traction, and the arms of the cross-bar are shaped accordingly; but when the chin-cap is used to correct lack of occlusion, improving the general occlusion of the teeth, or to prevent mouth-breathing, the traction should be more directly upward, and the cranial-cap is necessarily placed far forward on the head, being made sufficiently large, with the anterior suspenders attached well towards the front, and the posterior suspenders placed back of the ears. This changed direction of traction usually necessitates a

change in the shape of the arms of the cross-bar to prevent tipping of the chin-cap.

With the improved cross-bar, the change is made by removing the stay-pieces and replacing them after bending upward or downward the arms of the cross-bar, or by separating more the ends of the arms and introducing longer stay-pieces, clamping them with the knobbed screws as before. The chin-cap should be lined with chamois, cottonoid, linen, or other comfortable material.

Dr. George S. Allan, recommending the use of the chin-cap in 1878,* tells how to solder two arms across the cap, with the ends curved into hooks for the attachment of elastic ligatures, the arms being bent as desired.

External Supplemental Anchorage.—The cranial-cap, with a cross-bar as supplemental anchorage, in connection with apparatus in the mouth, is used for moving inward prominent upper or lower incisors to reduce anterior protrusion, moving inward prominent upper or lower cuspids, and moving cuspids, bicuspids, or molars backward in the line of the arch. *A chin-cap and wire-standards*, supported by a cranial-cap, are used for moving outward or inward the incisors and cuspids, moving the bicuspids and molars forward or backward in the line of the arch, and for elevating or depressing the teeth. Each of these operations is further referred to in future chapters.

External Independent Anchorage.—The cranial-cap, as independent anchorage, is used with a cross-bar for depressing extruded upper incisors; in connection with a chin-cap, for depressing extruded lower incisors; for the reduction of prognathism, the correction of lack of anterior occlusion, improving the general occlusion of the teeth, preventing mouth-breathing, etc. (For further reference, see chapters on these subjects.)

Springs.—Springs for moving the teeth should be made of a tenacious metal, capable of being bent many times without breaking. Spring gold, platinoid, German silver, or any springy metal can be used for this purpose, preference being given to the metals least liable to oxidation, and to those the temper of which is least affected by the heat required in soldering.

Platinoid and German silver wire as sold in the market vary in quality. Two grades of temper are generally kept in stock by the

* Allan, Transactions of the New York Odontological Society, 1878.

dealer, the springy and the soft. The spring-wire is made by drawing the softer wire through a draw-plate until it becomes of the desired hardness. If overdrawn, it becomes brittle, breaks easily, and is not suitable for making springs with sharp curves; therefore a medium hardness of wire should be used for springs that need to be bent many times, and when there is not sufficient spring, the wire can be redrawn or well burnished, which will make it of better temper or more springy. Piano-wire is very tenacious, and has superior spring properties. Springs of piano-wire have been used successfully in connection with vulcanite plates. It has been used for springs and spring-clasps in all metal appliances, but I have nearly abandoned its use for the latter owing to its tendency to corrode. It can, however, to some extent be protected from corrosion by dipping the spring, after making it of the desired shape, into a solution of muriate of zinc, and then into molten tin, which forms a coating. Electroplating steel wires with copper and gold has not proved satisfactory, as the plating is not impervious to the secretions. Plating or gilding on platinoid and German silver springs wears well in connection with rubber plates. When soft solder is used for uniting all metal appliances, in some cases the gold plating does not give good satisfaction, owing to the chemical action caused by acidity of the secretions.

The round spring-wire (Fig. 73) is usually preferred, as it can be bent at any angle, which as already said cannot be done with a wire in any other shape; also the round wire comes less in contact with the teeth, and does not retain the secretions like the flat or square wire. For some uses, however, the latter may be preferable.

Fig. 73.

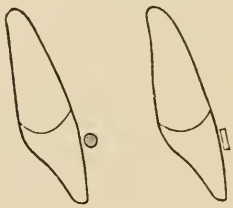

Size of Springs.—The size of the spring should vary according to the length and amount of force required. The numbers most commonly used for this purpose range from 17 to 22 B. & S. gauge. The bending is done with the clasp-bender, the round- or the flat-nosed pliers. When the metal is brittle, to prevent breaking it should be bent slowly, and not at an acute angle, but be shaped into gentle curves. Sometimes the metal can be softened in these parts with a low flame to prevent breaking, and not interfere detrimentally with the spring properties.

Form of Springs.—Springs can be made in any form desired; such as the long and short finger-spring, the curved finger-spring, and the semicircular spring with the U-shaped loops (Figs. 60, 62, 65, 67). Many other forms of springs will be described in this work.

Occasionally a secondary spring, flat or round, can be attached with advantage to the first spring, either for elongating it or extending at an angle from it for a special purpose. The elongation of a finger-spring in this manner, to keep pace with the movement of a tooth, is easily accomplished by soldering a piece on to the end of the spring; or the parts can be made adjustable, as seen in Fig. 142. This is done by soldering two rings of plate-metal, or short sections from a tube, to the end of a short piece of spring-wire, leaving a space between them, and so arranging them that they will slip over the end of the spring that is to be lengthened. The tubes should fit closely, or be bent together to prevent slipping.

A long spiral spring with the end shaped to engage with a tooth has been used to advantage in connection with a base-wire, attaching it at the side or passing the base-wire through it.

Springs can be made to extend either from a lingual or palatine base-wire or from a plate in any curve necessary for moving the teeth outward, or in any form desired to reach over, or through a space to the outer side of the arch for moving the teeth inward. The best form of spring can be determined by shaping soft tin, lead, or copper wire to the model. In some instances it is an advantage to trace with a pencil on card-board the form obtained with the lead wire, bending the spring in a similar shape.

The attachment of springs is usually made with solder to a base-wire or partial-clasp, but occasionally a spring is made more serviceable by being attached to a spring-clasp. (See Soldering.)

A base-wire spring is necessarily larger than the ordinary spring, as it serves as a base-wire to keep the appliance in form, and at the same time acts as a spring to move the teeth (Fig. 52).

The sizes most employed for base-wire springs range from 12 to 15 B. & S. gauge. These and other forms of springs will be described in connection with appliances.

In arranging the base-wire spring to cross the palatine arch for any purpose, it is essential that it be shaped to interfere as little as possible with the tongue in pronunciation, passing close to the in-

cisor teeth, or crossing the arch considerably back of them, following the palatine curve, thus avoiding the part that the tongue touches in making the sounds t, d, and s. When the spring is to have a twisting strain, the attachment for anchorage is strengthened in some instances by flattening the end before soldering, bending, or turning the end upon itself.

Generally it is an advantage to exert such force as will move the teeth slowly, although often no harm will result from a more rapid movement.

Attachment of Springs to Plates.—In attaching a round spring in a vulcanite plate, the end should first be flattened on an anvil with a hammer, to retain it firmly in the rubber and prevent it from twisting. The flattened portion of the spring should not reach to the surface of the vulcanite, as it is found to be much stronger if left round where it emerges from the plate.

An adjustable attachment of springs either to a metal or a vulcanite plate is occasionally an advantage. A convenient method is to square the end of a spring either by filing or by the addition of solder, and fitting carefully around its surface a thin piece of metal plate-material forming a ferrule, which can be placed in proper position in the try-plate to be vulcanized, or the ferrule may be soldered to the surface of a metal plate. The spring can then be fastened in the ferrule with shellac, which can again be easily softened by warming the spring and removing it for the necessary changes.

It frequently occurs, when regulating with rubber or metal plates, that an extra spring is needed temporarily to complete the work. A spring may be attached for this purpose by passing it through a hole in the side of the plate, the end flattened and formed to fit the surface, and fastened by drawing binding-wire through other holes in the plate either side of the flattened wire and twisting the ends together, or uniting them with solder. A spring can be attached directly to a metal plate with soft solder.

Another method is to solder a piece of metal to the end of a spring, as seen in Fig. 74, and rivet it to the plate. The wire is flattened on the end usually without drawing the temper, and a thin piece of German silver or other metal, about one-fourth of an inch or less in size, is contoured. The flattened end of the wire is then attached in the contoured portion with soft solder. The edge of the metal is trimmed to the desired form, and holes punched with the

plate punch or drilled in the sides for rivets, which are made to pass through the plate. The common pin, with the temper drawn, is a convenient rivet to fasten the springs, by riveting or soldering with soft solder. A method that has been used to advantage in an

Fig. 74.

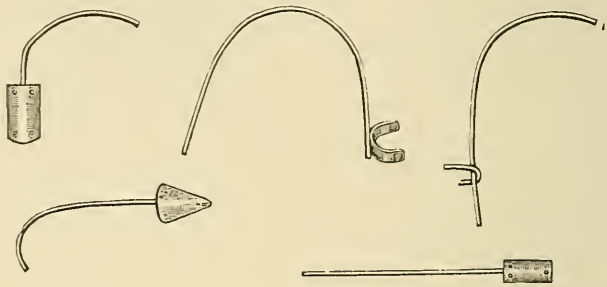

emergency is to flatten the end of a spring, fit it to the plate, and drill several holes either side of it, through which rivets or ordinary pins are passed; the heads of the rivets are counter-sunk in the opposite side of the plate, with the ends of the rivets bent over the flattened spring and attached with soft solder. A band or clasp of any suitable metal can be soldered to the free end of a spring to hold it in place on the tooth to be regulated, in the manner shown in the figure.

A simple means of keeping the spring-wire from pressing on the gum, or slipping off the teeth when regulating the molars or bicuspids, is to twist small wire around the end of a spring, tacking it with soft solder. It is usually applied by having one end shorter, to project into the interdental space, while the other end is a little longer, to rest on the grinding surface at the junction of the teeth. (For Action of Spring, see page 113.)

Collars.—A collar (band) is a thin piece of metal shaped to fit around a tooth, with the ends united. The earlier use of the collar, band, ferrule, or clasp was for the anchorage of long bands, plates, and inclined planes. Harris, in 1839, described a method of rotating incisors by means of a carefully adjusted gold band, which he stamped between a die and a counter-die. To the labial and palatal side of the band were attached hooks for ligatures, which extended back and were tied to the bicuspids. Delabarre used a gold cap with a ligature for this purpose; and in dental literature there are

many descriptions of collars with knobs, hooks, eyelets, bars, spurs, or tubes attached for supporting apparatus.

Dr. Thomas W. Evans, when he returned from Paris in 1853, on a visit to this country,* described a means of anchorage made by soldering a metal tube to the side of a collar, or by soldering a tube to the side of a yoke or skeleton cap, consisting of two nicely adjusted bands or rings that had been properly fitted to the teeth. Through the tubes, in some instances, he passed a hard-drawn wire, and to others were attached a rigid bar with screw and nut, or an elastic bar, to be "lengthened or shortened with screw-nuts." Since that time the tube soldered to a collar has been in general use for different purposes in regulating.

In 1871 Dr. W. E. Magill drew the attention of the profession to his method of attaching collars firmly to the teeth by cementing them with oxychloride of zinc. Later oxyphosphate cement was used.

This process of attaching collars to the teeth made it possible to do away with many of the cumbersome appliances that had been employed, and lessened the injury to tooth-structure and the gum that had been caused by the ligature and other insecure apparatus.

As a general means of anchorage, the use of collars on individual teeth seems objectionable, as it is usually necessary to separate the teeth by wedging for their adjustment, and when several collars are used together at the same time for anchorage, a considerable space is necessarily taken up by the combined thickness and contour of the metal, and this very often when it is desirable to lessen, rather than to increase, the circle of the arch. Again, the crowns of the teeth are larger near their grinding surface, making it quite impossible to contour the collars to fit closely the neck of the tooth when adjusted. This causes difficulty in properly cementing them.

Making Collars.—A collar adapted for anchorage is made of a strip of plate-metal about three-sixteenths of an inch wide, and about 36 gauge, or thinner, according to the stiffness of the metal. The metals most employed are gold-faced platinum, platinized gold, platino-iridium, gold, platinoid, and German silver. The two latter metals oxidize. This can be prevented in a measure by gilding or gold-plating them.

---

* Evans, Dental News Letter, 1853, p. 70.

The collar can be formed on a model, but the result is generally more satisfactory when it is shaped to the natural tooth. If the metal does not pass freely between the teeth, they may be wedged slightly. When much strain is to be put on it, the collar should be rather broad. It is generally formed with the ends lapping on the lingual side, crossing at an angle best suited to make a good adaptation to the tooth, and should be well fitted, but not so closely as to prevent its easy removal and replacement for cementing. For incisors or cuspids, the collar can be made in the usual manner, with the ends lapping by one another, and the points that project towards the gum on the palatal side trimmed off; or the metal can be stretched on one side, or cut into a curved strip, which will permit the ends to lap in good form. A method that leaves the lap of the collar smooth when finished, but narrower, is to cut a small V-shaped piece out of either end, adjusting it to the tooth, with the ends drawn together on the lingual surface and soldered.

When there is to be a projection from the collar on the distal or the mesial surface for the purpose of retaining a tooth that has been rotated, or to hold an appliance from slipping from the lingual surface of the incisors, it can easily be made in conjunction with the collar, by passing a strip of metal around the tooth, pressing the ends together, and soldering them, leaving them projecting at a right angle, forming a spur (Fig. 75).* The projecting ends can be ground or filed to any desired shape to serve as a lug. A spur of metal or a tube may be soldered to the collar for this purpose. Gold solder is applied to the joint and made to flow, by holding the parts in a flame with a small pair of pliers, using dry or moist pulverized borax as a flux.

Fig. 75.

Many varieties of pliers are offered by dealers for the purpose of supporting collars in soldering, and tubes and lugs in position on the collars while uniting them. The points of the pliers should be small, less heat being thus required.

In *cementing* the collar to the tooth, the inner surface should first be roughened or stippled by raising ridges with a sharp instrument, and the tooth polished with a fine grade of pumice, which will cause the cement to adhere more firmly to them. The cement should not be too thin; keep it free from moisture by the use of a rubber

* Jackson, International Dental Journal, 1890, p. 200.

dam, or napkins and spunk. In adjusting the collar, care should be exercised that the cement be so distributed as to fill all of the space underneath it. This will both insure strength to the attachment and protect the surface of the tooth from the secretions. The collar is most easily cemented by holding the point of the finger or a small piece of oiled paper over its lower opening, and placing the cement in it. The collar is then forced on the tooth, with the end covered in this manner, which presses the cement around the tooth in advance of the collar filling all of the undercuts.

Collars set with oxyphosphate cement for regulating purposes should be examined at least once in three months, passing an instrument along the edges to determine if the cement has become affected, as it is liable to waste away, and the surface of the tooth to be acted upon by the fluids of the mouth.

When it is found necessary to readjust a collar, it can generally be removed without cutting, by using a pointed instrument, similar in shape to a spatula, thin at the edges, and sufficiently thick in the centre to give it rigidity. The point of the instrument should be pressed underneath the edge of the collar and worked sideways back and forth, gradually stretching the metal and forcing the cement before it.

The spur, tube, and plain lug are the attachments to the collar most generally described in this book, although other forms are used and will be referred to in the description of special cases.

Tubes.—Tubes of any metal, thickness, or diameter suitable for the purpose of regulating can be procured in quantity of the dealer. The tube can be made by drawing a narrow strip of thin metal with a draw-plate, or by wrapping a thin piece of sheet metal around a wire with flat-nosed pliers and rolling it between two smooth pieces of wood or metal. The tube is then soldered to the collar, with the joint placed towards the collar, so that it will be united at the same time it is being joined (Fig. 76). To prevent the solder running into the tube, it is sometimes an advantage to paint the inside with whiting, close the tube with mouldine, or pass into the opening a lead like those used in adjustable pencils.

Fig. 76.

Lugs.—A lug is a small piece of metal projecting from a collar, for retaining the end of a spring or other portion of a regulating appliance. It is united to the collar, usually on the lingual side near the gum. A lug made of a piece of plate-metal is generally employed (Fig. 77).

The metal is bent at a right angle or an acute angle, is as long as the width of the tooth, and broad enough to retain the appliance. Before being soldered to the collar, it should be so bent that when the collar is adjusted it will rest at a right angle with the long axis of the tooth, or curved somewhat towards the neck, and not at an obtuse angle, as with the latter shape the tooth would be likely to gradually move forward and disengage the lug. A lug made of plate-metal in this manner gives a broad surface for the application of force, the tooth being less liable to become rotated during its movement than with a lug of other form. The broad lug is an advantage when the tooth is twisted, the application of properly directed force tending to correct its position. A wire, round or square, a tube (Fig. 78), or a cylinder with a section removed (Fig. 79) can be employed.

The metals used may be either gold, gold-faced platinum, platino-iridium, platinoid, or German silver, any of which can be united with 18-carat gold, or silver solder. If base-metals are used, care should be exercised not to overheat when soldering.

Soldering.—It is important that the spring temper of the metals used in making appliances should not be interfered with by overheating in the process of uniting them. For this reason, a solder that fuses at a low temperature should be employed when practicable.

Any of the metals used for springs can be soldered with soft solder or pure tin without injuring the elasticity when done carefully with the soldering iron. Three grades of soft solder are generally quoted,—fine solder, 2 parts of tin to 1 of lead; common solder, 1 part tin to 1 of lead; cheap solder, 1 part tin to 2 of lead. Jeweller's, or fine soft solder, is generally used for uniting platinoid or German silver appliances. Chemically pure tin requires a higher temperature and more care in soldering, but is considered less liable to oxidize.

The essentials in soft soldering are—

Clean and bright metals.

A *soft solder of good quality.*

A *flux*, chloride of zinc (sometimes called muriate of zinc), prepared by dissolving crystals of chloride of zinc in a small portion of water. (The crystals have an affinity for water, and when left exposed to the atmosphere they soon absorb moisture and

Fig. 77.

Fig. 78.

Fig. 79.

Fig. 80.

liquefy). Muriate of zinc is prepared by dissolving granules of pure zinc in hydrochloric acid, usually forming a saturated solution. When dissolved, and all effervescence has ceased, allow it to settle, then decant the clear solution from the sediment, and it is ready for use. If a small quantity of water is added to the mixture at this stage, say one-sixth, it will answer quite as well. For soldering steel, a very small portion of sal ammoniac added to the mixture is of advantage for giving toughness.

A *soldering iron*, about three-fourths of an inch square, by three inches long, made of pure copper with the point well tinned.

A *Bunsen or electric heater* of almost any form for heating the soldering iron.

The soldering can be done most easily when the iron is kept bright and in good condition. It should be very hot, but if overheated, it burns the tinning and the copper, and a greenish flame will be observed. To prevent the burning, the heat should not be excessive, and should usually be applied at the centre of the iron. A stronger attachment is made when the surfaces of the metals used are first tinned by rubbing them with the soldering iron.

In soldering, the partial-clasps, spring-clasps, base-wire, and spring should be placed in position on the model (see Figs. 53, 56, 57). The point of a pin is pressed into the plaster on the buccal surface of the teeth above each of the spring-clasps to prevent them from raising out of position while soldering (Fig. 80). The base-wire and other parts can be held in position with mouldine, as seen in the figure; or with a wad of cotton or paper held by the hand. When the iron is hot, pieces of solder sufficiently large are laid in contact with the metal, and the parts fluxed by touching them with chloride of zinc. The soldering iron is then passed over the solder, which flows, uniting all of the parts at once, and, if only sufficient solder is used, no dressing or polishing will be required.

Attachment of Springs with Solder.—A spring for moving the teeth can be attached with solder to the partial-clasp of an appliance at the time the spring-clasp and base-wire are united. Or the spring can be attached to any part of the base-wire with soft solder, by passing underneath the base-wire and spring, when on the model, a curved piece of partial-clasp metal, as wide as it is intended to have the soldered portion when finished; then solder with the soldering iron. A spring or hook can be attached to the spring-clasp in a

similar manner. A method of attaching springs that is considered stronger is to wind around the base-wire and the end of the spring to be joined a narrow strip of thin metal, as tinned platinoid or German silver, which have an affinity for the solder, and the soldering done with the soldering iron as before (Fig. 81).

Fig. 81.

Fig. 82.



If a piano-wire spring is to be employed, copper binding-wire wound about the springs for joining the wires, as seen in Fig. 82, has proved satisfactory.

Finishing and polishing an Appliance.—Any excess of metal or solder can be removed with a file, scraper, or coarse corundum stone, and the parts polished with any plate-polishing powder, or they can be burnished.

Gold and Silver Solder.—When any appliance is to be made of precious metals, gold solder should be employed. A solder of 18-, 14-, or a lower carat is applicable, according to the spring metals used. Appliances of platinoid or German silver can also be united with gold or silver solder. The model should be made of plaster or marble-dust, or their equivalents, and the apparatus soldered on the model; or the parts should be held in position on a plaster model and united with hard wax, after which they can be removed together and invested sufficiently with plaster and marble-dust to hold them in position while soldering. Use moistened borax as a flux, and proceed in the same manner as for attaching a clasp to a gold plate.

The springs should not be overheated, as this generally impairs their elasticity. The parts can be carefully burnished, however, which will to some extent restore the springiness of the metal.

Repairing Appliances.—The imperfect fit of an appliance may result from being made on an imperfect model, or from the careless adjustment of the partial-clasps or spring-clasps. In remaking or

repairing, when soft solder is used, unsolder the parts with a gentle heat, shake off the excess of solder, and readjust and solder them on an accurate model.

If the apparatus becomes broken or unsoldered, it can be re-soldered on the model, or new parts can be formed and added to the appliance in the manner described. Sometimes a spring can be added or other repairing done by supporting the parts of the appliance with mouldine or plaster of Paris for soldering. If a spring is to be attached to a soldered portion, a groove can be cut for it in the solder.

Appliances of gold are repaired in the same manner as in making.

Action of Spring.—Usually, when a new appliance is inserted in the mouth, it should not be removed for three days, that the patient may become accustomed to it before applying force. After that time the pressure may be changed slightly about once a week, or oftener if desired. Of course, much depends upon the character of the case. To save time and repetition, it will be explained here how the force of the spring is to be modified.

Pressure is increased by removing the appliance and bending the spring in the direction in which the force is desired. Thus, where a tooth is inside the normal line, the pressure of the spring is outward, and any increase of force is obtained by bending the spring accordingly. On the other hand, when a tooth is to be moved inward, the spring extended to rest on the outer surface is curved inward. When discomfort is caused by excessive force, it can generally be relieved by holding hot water in the mouth.

A system of graduated measurement of the changes of the springs should be adopted to insure a steady progressive movement. This can be done by placing the appliance on a card and marking its outlines with a sharp-pointed pencil, affixing the date; keeping the card as a permanent record. Each time that additional force is to be applied a new indication should be made with pencil on the card, noting the date and the distance it is desired to bend the spring. The spring is then bent slightly and verified until it conforms to the new marking. Comparison of the appliance with the markings on the card is made easier by always placing the appliance and card against a slight ledge when marking the outlines and changes.

These principles, involving systematic changes of force with the spring, apply to all the modifications of my appliances.

Résumé.—In completing the chapter on means of anchorage and making appliances, I would recapitulate the advantages of my system.

First. The simplicity and ease of construction of the apparatus.

Second. It is equally applicable for the regulation of the teeth of the child or the adult.

Third. It is suitable for all forms of irregularity, doing away with the use of a plate in a large majority of cases.

Fourth. It is well retained in apposition with the teeth, and when the appliance is properly made it causes no inconvenience. It does not interfere materially with speech or with the occlusion of the teeth, even when an apparatus is used in both the upper and the lower arch at the same time.

Fifth. While the anchorage is sufficiently firm for all practicable purposes, the appliance can usually be removed by the patient, thus favoring cleanliness.

Sixth. It can be so arranged that some of the teeth to be moved later in the process of regulating can be employed to assist the anchorage, thereby lessening the disturbance of the anchorage-teeth when extreme force is applied.

Seventh. The force caused by the appliance for moving the teeth is well under control, and requires less attention than with the apparatus generally used, thus saving the time both of the patient and the operator.

Eighth. The appliance can be made of almost any of the precious metals that are springy or of base metals. Those most usually employed are spring-gold, platinoid, German silver, wire, and plate. They are easily manipulated, and the two latter are inexpensive and easily obtained.

Ninth. The spring-clasp attachment, base-wire and spring-wire construction are simple and quickly prepared. Changes and additions to the apparatus are readily made.

Tenth. A part or the whole of an appliance can be made of the precious metals, when desired.

Eleventh. Gold or silver solder may be used for uniting the appliance, or the soldering simplified by the use of jeweller's soft solder. The latter interferes less with the spring properties of the metals, and changes in the apparatus by soldering and unsoldering are easily made.

Twelfth. Many of the springs described can be used to advantage

in combination with other means of anchorage, especially with a rubber or metal plate. The construction of the apparatus is suitable for the application of supplemental force, either with a cross-bar, a chin-cap, a supralabial, or an infralabial bar.

Thirteenth. Almost any of the appliances can be continued in use for retaining the teeth in position after completing their regulation.

Fourteenth. The models of each case are usually uninjured in making the appliance, and can be preserved for future reference and study.

Fifteenth. For record the models are mounted on boards, the models of the upper and lower arch being articulated. One series of models will thus show the position of the teeth before regulating, the progressive changes under treatment, the apparatus used, and, finally, the result of the successful treatment.

Early Methods.—Among the earlier methods of regulating are described the manipulation of the teeth with the fingers (see page 210), the movement of the teeth with cord ligatures, with long metal bands, inclined planes, etc.

Ligature.—The ligature was employed for moving irregular teeth by weaving it among them, so that it would pass in front of the prominent ones and back of those to be made more prominent. The ligature was then stretched, and the ends securely tied for anchorage to one or more of the teeth not to be moved.

Long Band and Inclined Plane.—Appliances, including the long band and metal inclined plane,* were tied with ligatures to suitable teeth for anchorage. An objectionable feature of this form of anchorage was the slipping of the ligature on the teeth, permitting movement of the apparatus and consequent injury to the gum. The difficulty was finally overcome by making the attachment to the teeth with bands, ferrules, or clasps.

Metal Plates.—The metal plate, fastened to the teeth with ligatures, bands, or clasps, has also been in use many years for regulating.† It is sometimes employed by the writer as an anchorage for metal springs soldered to its surface, the plate being retained with wire clasps or by suction.

---

* Fox and Harris, 1846, p. 100; Catalan, Journal Général de Médecine, de Chirurgie et de Pharmacie, January, 1814.

† Hunter, Natural History of the Human Teeth, 1778, p. 77.

Rubber Plates and Inclined Planes.—Since the introduction of vulcanite rubber in 1839 it has been used extensively for inclined planes, plates, and anchorage for screws, for expanding the arch and moving irregular teeth.

Later Methods.—At the International Medical Congress in London, 1881, W. H. Coffin presented a paper describing what he termed the "Expansion Method" that had been used in practice by his father and Dr. Headridge for many years. The method attracted general attention. It consists of anchoring vulcanite plates by extending the rubber over the molars and bicuspids. The plates are usually divided in the centre. In the rubber are attached piano-wire springs for spreading the arch and moving the irregular teeth. The principle in the construction of the apparatus is as follows: A wax try-plate is fitted to an accurate model covering the arch, extending over the bicuspid and molar teeth to the buccal side near the gum. Springs of piano-wire with the end flattened are embedded in the wax in the position desired, and the part flasked in the usual manner, the free ends of the springs being retained in the plaster. Rubber is then packed in place of the try-plate, and the plate vulcanized and polished. The fitting of the rubber about the teeth generally holds the plate quite firmly in position when made on an accurate model, and but little dressing is required. (A more detailed description of the Coffin method will be found in Chapter IX., Expansion of the Dental Arch.)

Drs. Farrar, Patrick, and Angle have each recommended a method of attaching apparatus to the crowns of teeth with open collars, provided with bolt and nut for drawing the free ends of the collars together. To the collars, in some instances, are soldered bars, tubes, spurs, or eyelets, to make suitable attachment for holding apparatus, screws, jack-screws, rubber bands, etc., for moving the teeth. Many examples of these procedures are found in their writings.

CHAPTER VIII

WEDGING—APPLICATION OF FORCE—MOVEMENTS OF THE TEETH—CARE OF THE TEETH AND APPLIANCES DURING REGULATION

Wedging.—The wedge is not employed, as formerly, as a force for the purpose of regulating teeth, but is now used principally for separating the teeth to permit of the adjustment of apparatus. Immediate wedging can be accomplished by the use of a metallic separator or a properly shaped wooden wedge. Soft rubber is used for wedging, but is liable to cause excessive soreness when allowed to remain between the teeth longer than from three to four hours. It is sometimes applied longer to cause congestion for assisting an apparatus to start the teeth in their movement.

When active congestion is not desired, sterilized cotton or tape for wedging is more acceptable. It can be introduced and held in position by first passing between the teeth two cords of waxed saddler's silk twist, or linen doubled upon itself, and left sufficiently long to tie well. One or more thicknesses of sterilized cotton tape well waxed are then drawn between the teeth and kept dry. The ends of the tape are clipped off close to the teeth, the twist drawn around the remaining part, packing it firmly between the teeth, drawn as tight as desired, and well tied with a square knot.

The ends of the cord are then removed with scissors and the knot rubbed down. If there are cavities, sterilized cotton pressed into place will often be more serviceable. This means of wedging is applicable for the molars or bicuspids as well as the incisors. A wedge inserted in this manner is acceptable to the patient, is not easily displaced, acts rapidly, causes little or no soreness, and is comfortably and easily applied. The twist used for wedging can be prevented from unwinding from the spool by passing the end through the hole in the centre and cutting a notch in the edge corresponding with the angle the cord takes when it passes over before entering the hole. After unwinding the desired amount, the spool is allowed to drop, the twist thus catching in the notch and preventing further unwinding.

The Application of Force.—It is not my intention here to discuss its principles, but to speak more especially of its means of

application as pertaining to orthodontia. There has been a diversity of opinion among writers within the last few years regarding the better means of applying force to cause the movement of irregular teeth, and especially whether the force shall be constant or intermittent. Some favor the action of a spring or constant pressure, and others the action of a screw or intermittent pressure; but all agree that in general, whether the force be constant or intermittent, it should be applied as near as possible at a right angle to the long axis of the tooth.

Dr. Farrar, in a series of papers in the *Dental Cosmos* (1876–78), and in his work on Irregularities, vol. i. p. 159, has given preference to the screw or intermittent pressure for regulating purposes. Its application he terms the "positive system," and enlarges on intermittent force as analogous to the law of "Labor and Rest." In considering this view from a physiological stand-point, in discussion, I made the following statement,* which has been verified in my practice: "The law of nature is, that alternating pressure and relief cause hypertrophy, increased growth, and hardening, while constant pressure causes atrophy or absorption. If you want absorption, you must keep up a constant pressure without intermission or rest. We want absorption of the alveolar process in cases of regulating."

The tissues involved in regulating are tolerant of any kind of direct moderate force, whether constant or intermittent, excepting a force that is vacillating,—that is, not having a definite fixed point of resistance and action,—as is common in insecurely anchored regulating appliances, wedging of the teeth with rubber, etc., which produce an objectionable inflammation. The force for moving the teeth should be applied in such a manner that the device will not impinge too heavily on the soft tissues. In my experience, the force of a spring generated with slight variations is more effective, more agreeable to the patient, and requires less attention than other means.

Movements of the Teeth.—Terms to describe the movements of the teeth should be few and concise. A chart (Fig. 83) has been prepared to indicate some of their more common movements during regulating.

A, incisors, to move outward, or labially; B, incisors, to move inward, or lingually; C, incisors, to move laterally; A′, cuspids,

* Jackson, Dental Cosmos, 1887, p. 385.

bicuspids, and molars, to move outward, or in a buccal direction; B′, cuspids, bicuspids, and molars, to move inward, or in a lingual direction; D, cuspids, bicuspids, and molars, to move forward in the line of the arch; E, cuspids, bicuspids, and molars, to move backward in the line of the arch; F, rotation of the teeth; G, depression of teeth in their alveoli; H, elevation of teeth in their alveoli.

Care of Teeth and Appliances during Regulation.—Thorough cleansing of the mouth and teeth is necessary at every time of life. Friction with a good powder and brush is the first essential. The

Fig. 83.

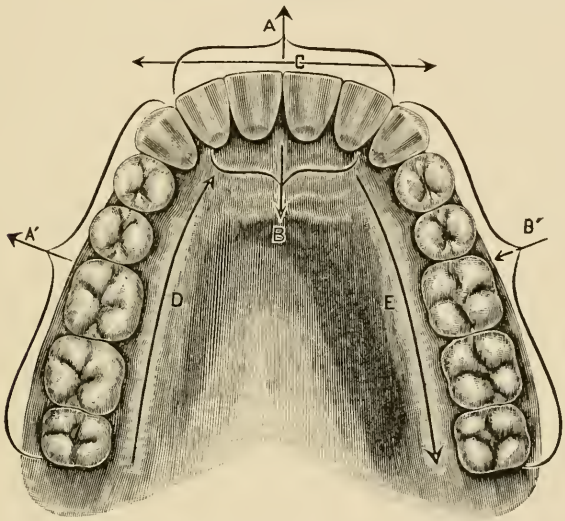

Movements of the Teeth.

A, incisors to move outward.
B, incisors, to move inward.
C, incisors, to move laterally.
A′, cuspids, bicuspids, and molars, outward.
B′, cuspids, bicuspids, and molars, inward.
D, cuspids, bicuspids, and molars, forward.
E, cuspids, bicuspids, and molars, backward.
F, rotation of the teeth.
G, depression of the teeth.
H, elevation of the teeth.

brush should have sufficient bristles, and should not be too stiff, as some of the bristles have to bend to permit others to reach between the teeth; nor should the bristles be too soft, as considerable stiffness is required to cause the necessary friction for removing tartar and other collections. These are irritants to the gum, and cause it to become congested and bleed easily. Benefit to the gum is derived from massage and friction if not too severe. Generally when the gums bleed the brushing should be more vigorous. In passing the brush

across the teeth, the bristles jump from one tooth to another and do not reach between them as they should, but in making the motion downward from the gum, or up and down, the bristles pass between the teeth, causing the desired friction on their approximal surfaces.

A suitable mouth-wash is useful as a disinfectant, but care should be exercised in its choice. A solution that will remove calcareous deposits from the teeth will usually affect the tooth-structure.

Fixed regulating appliances should be cleansed thoroughly with the teeth. Removable appliances should be taken from the mouth and the teeth and appliance cleansed at least twice a day, in the morning and at night. If neglected, the metal is liable to become tarnished and stain the teeth. Thorough brushing with a tooth-powder and brush is generally sufficient for cleansing appliances, but sometimes, owing usually to the condition of the secretions, a tarnish is formed on the metal which requires a more active powder, as powdered pumice. Some of the metal-polishing preparations on the market are even more efficacious. When the tarnish is not removed easily, first place the appliance for a few moments in alcohol or a weak alkaline solution; it is then readily brightened by brushing it with powder.

The deciduous, as well as the permanent teeth, should be preserved by thorough filling.

CHAPTER IX

EXPANSION OF THE DENTAL ARCH

Where the teeth are irregular, they are usually much crowded in the arch, but cases of irregularity with spaces between the teeth occur.

When the teeth are crowded, and some of them irregular, the dental arch is enlarged by forcing the irregular teeth into proper line, but the correction is generally facilitated by first expanding the arch.

Before increasing the circle of the arch in any case, it is necessary to study the family type and the features of the patient, and especially the occlusion of the teeth, in order to determine whether expansion will improve the contour of the features and the occlusion.

When there is not sufficient breadth of the arch, the incisors are usually too prominent, and need to be moved inward to line. To accomplish this without extraction, the sides of the arch should be moved laterally outward. This is necessary also when the incisors are rotated on their axes or overlap one another, but one arch should not be expanded to the detriment of the occlusion of the teeth with those of the opposite arch.

Much has been written upon expanding the arch to improve the occlusion and make room for irregular incisors. So many mistakes however, are made in expanding the arch laterally by moving outward the bicuspids and molars without moving the cuspids, with a view to increase the space for the incisors, that Fig. 84 has been prepared to illustrate the lines of movement of these teeth. It shows that the movement of the molars and bicuspids in a buccal direction, as illustrated by the lines *c*, *d*, *e*, and *f*, does not increase the size of the arch anterior to them, except by a slight dragging outward of the cuspids, permitted by the elasticity of the bony process, which movement of the cuspids in most cases is not appreciable. Therefore if more space is needed for correcting the position of the incisors, the cuspids should be moved outward with the bicuspids and molars. When more space is required for the accommodation of prominent cuspids, the movement outward of the bicuspids and molars would not improve the condition, as sufficient room for the

cuspids would not be gained without excessive expansion, interfering with the occlusion. If only slight additional room is required for the incisors, it can in some instances be gained by moving the cuspids outward without interfering with the bicuspids and molars, or by

Fig. 84.

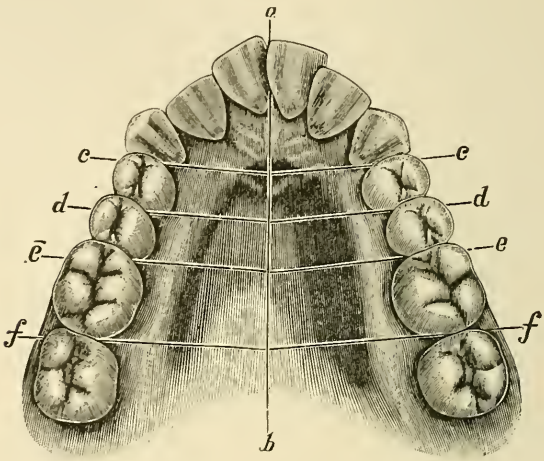

removing a little from the mesial and distal surfaces of the cuspids and bicuspids with a fine file, a polishing strip, or a diamond disk. In some cases it may be found practicable and excusable to polish the lateral surfaces of the incisors in the same manner rather than to extract a tooth to make the necessary room, but they should not be dressed to the extent of removing all of the enamel from any part.

In normal occlusion the teeth of the upper arch rest in contact with those of the lower, and, although many changes take place in the order of development of the deciduous and permanent teeth, a proper occlusion should be maintained. It is seldom expedient to expand the upper arch to make room for irregular teeth without a corresponding expansion of the lower arch, as without the support of and correct occlusion with the latter the upper arch will usually contract again and the teeth return to an irregular position. There should also be maintained the normal pressure of the tongue against the teeth of each arch, which is possible only in cases of nasal breathing. On the other hand, the very gradual expansion of the lower arch will generally cause the expansion of the upper arch through the influence of the occlusion. Especially is this true with

young patients. For this reason methods of expanding the lower arch will first be considered.

Lateral Expansion of the Lower Arch.—In expanding the lower arch the force should be applied gradually, as the purpose is to enlarge the circle without bending outward the body of the jaw. With the child, interstitial and general growth of the jaw is encouraged by expansive force on the teeth. It is obvious that an appliance for spreading the lower arch should not extend below the gum line, as the tissues, having been thoroughly protected by the tongue, are tender, and the pressure of a plate is not usually tolerated without more or less rebellion on the part of the patient, especially if the arch is to be much expanded.

There is no advantage in extending the appliance over the gum in any ordinary case, as the alveolar process will follow the movement of the teeth and surround them in their new position; but if the expansion of the arch be required at about the time of the eruption of the bicuspids, and the deciduous molars are still in position, it is occasionally advisable to have the appliance extend over the process to insure its steady movement outward with the erupting bicuspids. Again, the extension of the appliance is sometimes an advantage in securing anchorage for *unilateral expansion* of the lower arch. In this case the apparatus should extend below the margin of the gum on one side, thus strengthening the anchorage for the movement of the teeth on the opposite side.

Fig. 85.

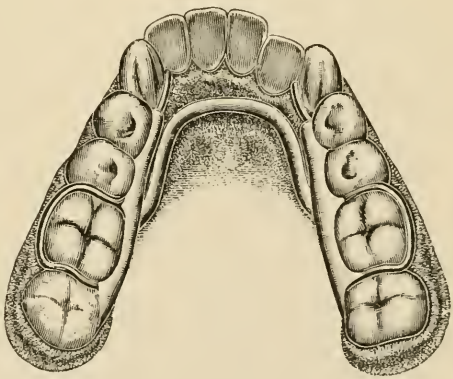

A simple form of appliance for expanding the lower arch laterally is constructed as shown in Fig. 85. Partial-clasps are fitted to the lingual side of each of the teeth to be moved, and a spring-clasp over one or two teeth on either side of the arch as required for anchorage. When the deciduous teeth are present the spring-clasp attachment may be made to pass over the second deciduous molars, and if the bicuspids are erupted, the spring-clasp attachments should pass over the first bicuspids and the first permanent molars. The two

sides of the appliance are connected with a lingual base-wire, about No. 13 Brown & Sharpe's standard wire gauge, formed to the circle of the arch and passing just back of the incisors. When the base-wire is short, a smaller size is sometimes employed to advantage. The base-wire can be formed to rest below the margin of the gum, but not too low, as it would interfere with the action of the tongue. With the base-wire in this position, pronunciation is not interfered with. The ends of the base-wire extend backward, and are attached with solder to the anchorage portion of the appliance, about midway from front to back. The attachment of the base-wire to the anchorage in this manner permits of its being shaped to give the required force for the general expansion of the arch, or for expanding the anterior or distal part of the arch as desired.

When the apparatus is properly fitted and inserted, the spring-clasps are shaped to clasp the teeth lightly for anchorage. No pressure should be caused by the appliance for three days after its adjustment, or until no discomfort is experienced from it.

The changes in the shape of the spring base-wire for applying force are generally made once or twice a week; in other cases, but once in two or three weeks. With this, as with all other apparatus, the force is to be increased gradually,—that is, the form of the spring should be changed only a little at a time. This can be managed by the aid of a carefully prepared tracing or chart.

Usually after the arch has been expanded the incisors gradually take a good line; but if not, a properly shaped spring, as a curved finger-spring, can be attached to the base-wire or to the anchorage portion on one or both sides, and can be made to extend forward and give force for their correction. After the expansion of the arch the same or a similar apparatus is used for retaining.

Fig. 86 illustrates an appliance that was used for broadening the lower arch in the case of Miss G., aged thirteen years.* It was constructed on a plaster model of the teeth by shaping, with the contouring pliers, partial-clasps of gold plate (No. 34 gauge) to fit the lingual sides of all of the teeth to be moved. Spring-clasps were then made to encircle the first bicuspids and the first molars, forming spring-clasp attachments for anchorage.

A spring base-wire, No. 14 gauge, was shaped so that about one-

* Jackson, Items of Interest, 1900, p. 674.

inch of the wire followed the lingual curve of the gum surface back of the lower teeth, considerably below the line of the margin of the gum, but not so low as to interfere with the action of the tongue. Each end of the wire was bent forward upon itself, and again backward,

Fig. 86.

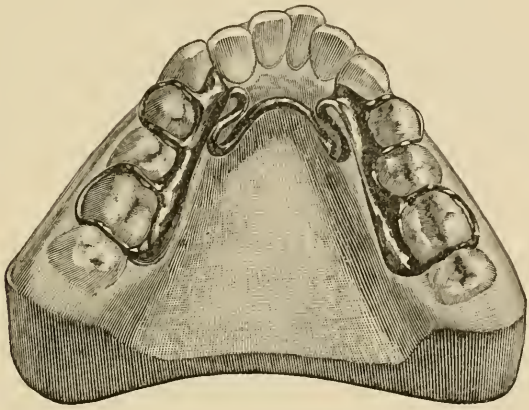

forming in close but gentle curves the shape of the letter S, as seen in the figure, with the distance between the ends of the loops in each of the S-shaped sections about one-half inch. The ends of the spring base-wire were then fitted to the partial-clasps with the ends of the spring-clasps on either side of the arch, and soldered with a high grade of soft solder.

The base-wire, shaped in this manner on each side of the median line, like a letter S, permits the necessary changes for broadening the arch to be made without warping the apparatus or interfering with the established relationship of the anchorage portions with the teeth that they are made to clasp. The appliance is not as easily made or manipulated as the one previously described, but it is effective.

The action is changed by bending outward from time to time the loops in the spring base-wire. This is done in the following manner: Hold the end of one of the lower loops firmly with flat-nosed pliers and bend the wire by pressing outward with the hand the anchorage portion. Then take the corresponding upper looped portion of the wire in the pliers and, holding firmly with the other hand the short central part of the wire that rests back of the front teeth, press it outward with the pliers a little to make this part correspond with the first. When it is desirable to increase the pressure,

the double loop on the opposite side of the median line should be bent as described. These changes should be made usually about once a week.

When the teeth of the lower arch are of good form for anchorage, an appliance for expansion like Fig. 87 will meet the requirements without the addition of spring-clasps. The model should be very accurate. The appliance is made by fitting partial-clasps to the model on the lingual side of each of the teeth to be moved. A spring base-wire with a loop in the centre pointing downward, and sufficiently large to cause the necessary expansion, is to be formed to follow the lingual sides of the teeth in contact with the partial-clasps to which it is soldered. The appliance is so shaped as not to impinge on the gum.

Fig. 87.

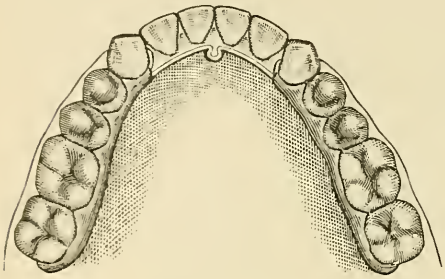

If at any time the anchorage proves insufficient, spring-clasps can readily be added.

The following case illustrates the possibilities and the advantages of early regulation of the teeth. Master S., aged seven years; all of the deciduous teeth in position excepting four of the incisors. Three permanent incisors and the four first permanent molars were erupting. The upper arch was unusually large; the lower arch was very much contracted, all of the teeth closing inside of the circle of those in the upper arch, with the lower incisors impinging on the gum. The child was unable to carry on any ordinary mastication, and was anæmic and very nervous. On April 9 a palatine plate, with an elevated ridge on the front and sides, was inserted in the upper arch, forming an occlusal surface for the lower teeth. This immediately provided means for natural mastication.

Fig. 88 illustrates the upper arch (natural size) with the plate in position. The dotted lines indicate the surface covered by the lower teeth in occlusion. Fig. 89 shows the lower arch (actual size), with an appliance inserted for its expansion. The deciduous teeth were very short, the gum covering about two-thirds of the crowns of the permanent molars. The appliance was made on the principle of the one shown in Fig. 85. Force was applied by bending outward the

Fig. 88.

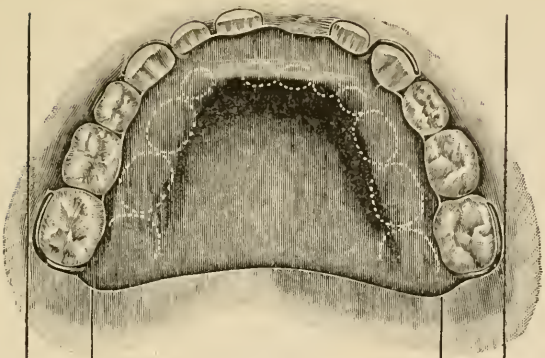

Fig. 89.

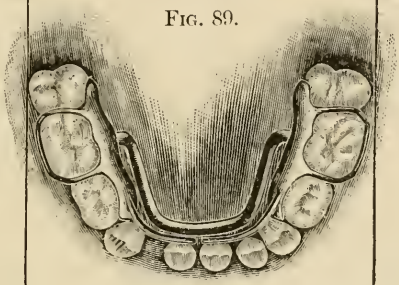

a b b a

Fig. 90.

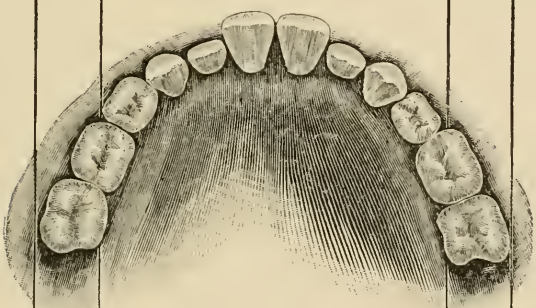

Fig. 91.

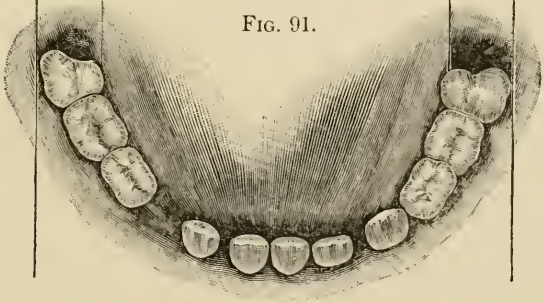

sides of the lingual base-wire at intervals, usually about once a week. The lower permanent lateral incisors erupted far back of the normal position. To move outward the laterals and the central incisors, after the arch was partially expanded laterally, a curved finger-spring, extending forward, was attached to the anchorage portion on either side.

Fig. 90 shows the upper arch with the advanced development of the permanent incisors on January 19. Fig. 91 illustrates the lower arch in its expanded condition (actual size) on March 20, the teeth having taken a natural occlusion with the upper teeth. The same form of appliance was continued in use as a retainer. The difference in the width of the arches and the extent of the expansion is indicated by the lines *a*, *a*, *b*, *b*. This extensive change was made with but little discomfort to the patient.

Fig. 92 illustrates an apparatus recommended by Dr. Norman W. Kingsley* for the lateral expansion of the lower arch. It is made of vulcanite, and is fitted to the lingual sides of the teeth like a partial plate. A jack-screw with a nut is inserted, the vulcanite being split with a saw in such a manner that the turning of the screw forces outward one part of the separated vulcanite, thus causing the movement of the teeth. The screw is turned once or twice daily. It can be adjusted for causing the outward movement of both sides of the arch, or for one side only, as illustrated.

Fig. 92.

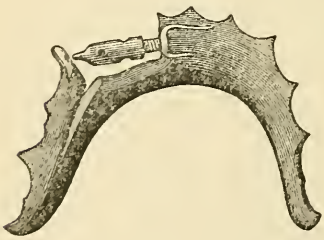

A method of expanding the upper or lower arch with a vulcanite divided plate connected with piano-wire springs (Figs. 93 and 104) was described by Mr. W. H. Coffin in a paper read before the International Medical Congress in London, August, 1881.† Mr. Coffin stated that the method had been in use by his father and himself for twenty-five years.

The plate is made of vulcanite, divided through the centre into lateral halves, which are connected with springs of piano-forte wire.

---

* Kingsley's Oral Deformities, p. 71.

† Coffin, Transactions Seventh International Medical Congress, London, 1881, vol. iii. p. 542.

The vulcanite usually extends from the lingual side over the grinding surface of the molars and bicuspids, covering the buccal side of the teeth so that when the plate is inserted it will clasp them sufficiently well to insure good anchorage. For the expansion of the lower arch, the lateral halves of the plate are connected with one or two curved piano-wire springs, having their ends flattened and embedded in the vulcanite opposite the bicuspids or molars. (See description of the method of making these appliances on page 136.)

Fig. 93.

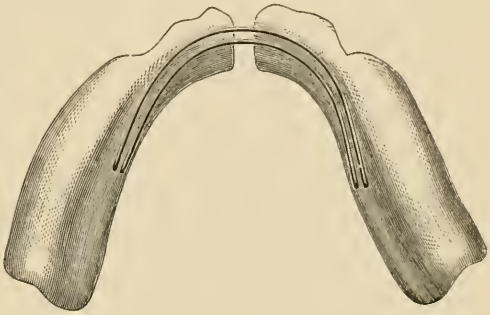

For anterior expansion of the lower arch see page 144.

Lateral Expansion of the Upper Arch.—A simple device for the lateral expansion of the upper arch is made as seen in Fig. 94. For anchorage, partial-clasps are fitted to the palatal surface of the teeth to be moved, with a spring-clasp on one or two teeth on each side. These are connected with a lingual base-wire, about No. 13 gauge, formed to the circle of the arch and passing just back of the incisors when the articulation will permit. The ends extend backward and are attached with solder to the centre of the anchorage portion.

Fig. 94.

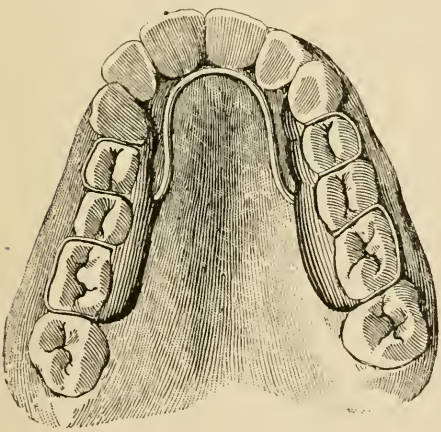

The necessary force is applied by removing the appliance from time to time, and bending outward a little the ends of the base-wire. If the anterior part of the arch needs to be expanded laterally more than the distal, or *vice versa*, the shape of the base-wire can be changed for that purpose by bending it near where it enters the anchorage portion.

The base-wire passing on the palatal side of the upper incisors in this manner occasionally interferes with the articulation of the sounds t, d, and s, as the tongue touches the gum at about that position. If the patient has trouble in this respect, or if the lower incisors close too near the gum to admit of the base-wire passing at this point, a palatine base-wire can be employed with a U-shaped loop formed in the centre (Fig. 95). The ends of the base-wire are soldered to the spring-clasp attachments on either side for anchorage. Force is produced by opening the loop in the base-wire from time to time.

Fig. 95.

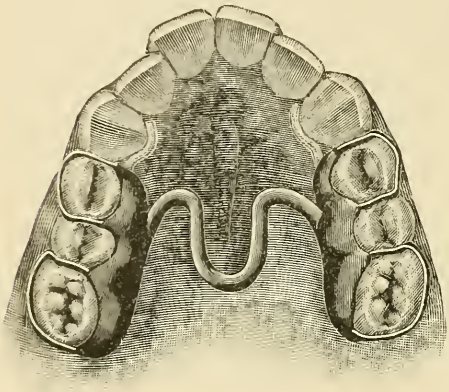

The palatal surface of the cuspid inclines outward in some cases to such an extent that the anterior part of the apparatus is not well retained. This is obviated by arranging a wire to extend forward from the anchorage portion of the apparatus, with the end curved to rest on the mesio-palatal surface of the cuspid encroaching on the gum. If it is not held in position by the shape of the cuspid, sometimes a narrow contoured partial-clasp fitted well under the free margin of the gum and soldered to the wire will improve the anchorage; or a collar with a suitably shaped lug can be cemented to the cuspid and the angle of the wire changed as desired to fit under the lug.

Although usually but slight persistent force is required for expanding the arch, two palatine base-wires are sometimes of advantage.

An effective appliance is made with one spring base-wire crossing the arch in line with the cuspids or bicuspids, and the other in the line of the molars. Each base-wire can have a loop formed in the centre, or the base-wire may be made without a definite loop, being bent backward opposite the median line. When force is required, they can be bent forward slightly at intervals to lengthen them.

The advantage of using the round spring base-wire is noticeable in these forms of appliance, as the spring can be bent in any direction for causing the necessary force without warping the ap-

pliance, which would occur if the spring were made of flat or square metal.

Generally, in expanding the arch it is found that the distal part is broad enough, and only the region of the cuspids, bicuspids, and first molars needs to be expanded (Fig. 96). In such a case a palatine base-wire should be arranged in the distal part of the arch, where it is already broad enough, with the ends attached in the anchorage.

Fig. 96.

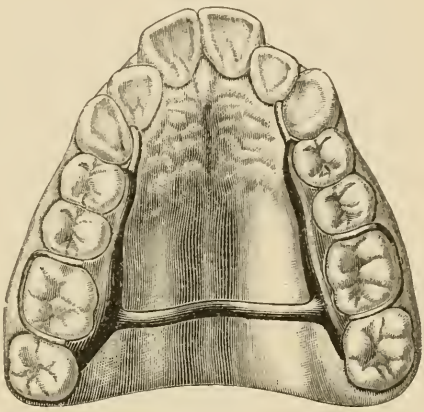

To the anterior part of the anchorage portion on each side is soldered a small wire, shaped to follow the lingual side of the cuspids, encroaching on the gum, the end being curved to engage with the mesio-palatal surface. Force for expansion is caused by pressing outward on the anterior arms of the anchorage, bending the base-wire.

With this style of device, when the distal part of the arch needs to be expanded also, the palatine base-wire should be arranged to

Fig. 97.

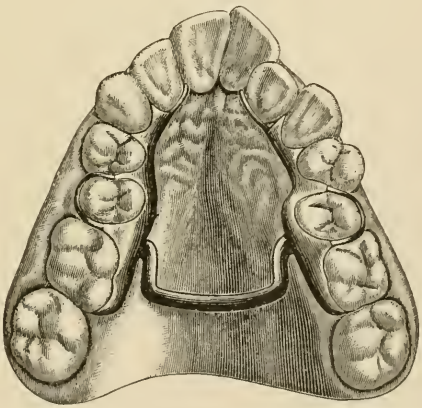

cross far back, with the ends curved forward, forming arms shaped to enter the anchorages opposite the second bicuspids or first molars (Fig. 97). Force is supplied by bending outward the arms of the

base-wire. The arch is held in the same relationship until sufficiently expanded, when the teeth are evened.

In expansion, when the teeth are moved to a considerable extent, it is sometimes difficult to harmonize the teeth of the upper arch with those of the lower to form a good and permanent occlusion. Fig. 98 illustrates an expanding and equalizing device in the upper

Fig. 98.

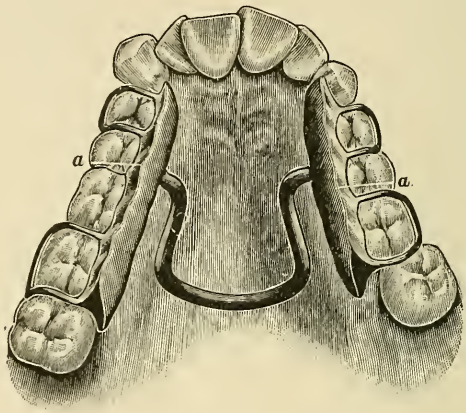

arch, with flanges attached projecting downward from the palatal surface on either side. The appliance is made with partial-clasps and spring-clasp attachments connected with one or two large palatine spring base-wires. Spurs are extended from the device on to the grinding surface of the upper teeth to prevent the apparatus from being pressed against the gum. The flanges (*a*, *a*) are made of plate-metal and shaped to project sufficiently on to the lingual surface of the lower molars, bicuspids, and cuspids in occlusion, to guide and cause them to articulate with the upper ones. In locating the flanges it is well to take a bite, as for making artificial teeth. Their general contour can be crimped to fit the lower teeth, or left smooth. The flanges should be thickened with solder and the edges rounded sufficiently to prevent irritation of the tongue. Bending outward the base-wire slightly from time to time broadens both the upper and lower arches. The flanges can be bent outward or inward as required to further adjust the occlusion. When desirable the flange can also be extended around the anterior part of the arch, as for correcting a receding lower jaw. For some conditions, the flanges may best be made to project in the form of flat metal

springs. The device is applicable in the lower arch by the use of a lingual base-wire.

Fig. 99 shows the position of the teeth of Miss A., aged sixteen years, when presented for treatment. Only one of the teeth in the upper arch, a back molar, articulated with those of the lower for mastication, the others closing inside of the line of the teeth of the lower arch. The patient had been a mouth-breather from infancy as a result of nasal stenosis caused by adenoid growths and thickening of the mucous membrane of the nose. She was advised to visit a rhinologist and have the abnormal conditions corrected to permit free nasal breathing, and later to have the upper arch expanded to cause the teeth to occlude with the lower ones.

Fig. 99.

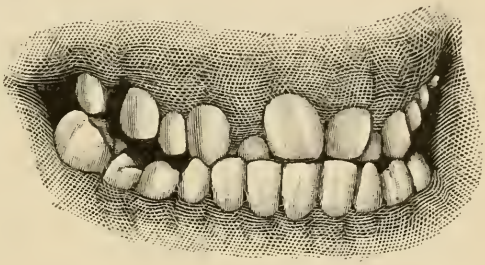

Fig. 100 is a view of the palatine arch before treatment. As the arch was to be much expanded, it was determined to force outward

Fig. 100.

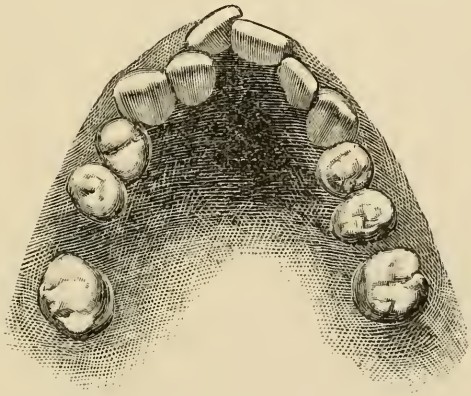

the bony process with the teeth. A vulcanite split plate connected with a U-shaped spring was made, anchored with wire-clasps extending from the plate around the upper bicuspids, and with platina-gold collars cemented to each of the central incisors and cuspids, with lugs on the palatal side shaped to project a little over the plate.

Fig. 101 illustrates the plate used and the extensive change made in the shape of the arch by moving the teeth and process bodily

Fig. 101.

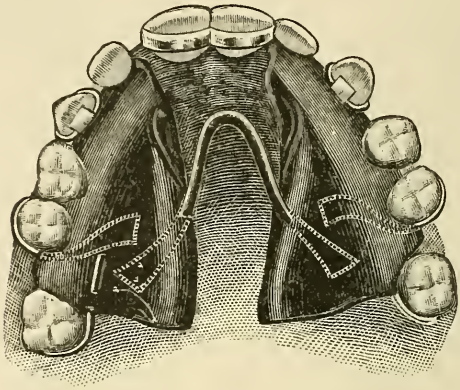

outward. As the expansion of the arch progressed the front edge of the plate pressed on the palato-distal side of the central incisors, and a small spring-wire was attached in each side of the plate to extend forward to the mesial and labial side to rotate them inward. When the incisors were rotated to proper position, they were retained by cementing to them platina-gold collars that had been fitted to the teeth and soldered together at the median line, as recommended by Dr. Guilford. When the upper arch was expanded the teeth articulated with those in the lower arch, as seen

Fig. 102.

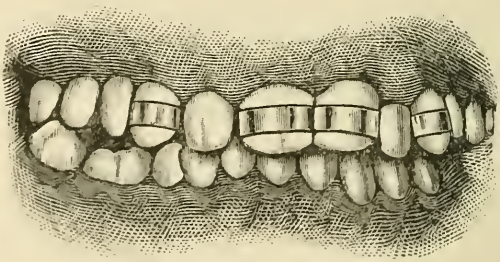

in Fig. 102. A retaining plate of thin vulcanite was then inserted and worn about two years, when the patient was instructed to leave it out during the day and insert it regularly before retiring.

Usually one medium-sized spring connecting the lateral halves of a plate, as illustrated, is sufficient for expanding the arch; but if it is found in the early stage of the operation that sufficient force is not being generated, a second spring may be bent into a U-shaped loop, with the ends curved outward and shaped to enter holes made in the plate for the purpose.

If from any cause the growth of the upper maxilla has been arrested, the early expansion of the arch encourages the development of the jaw and also broadens and increases the air-passage of the nares. The changes brought about by the expansion of the arch later in life are dependent principally upon the movement of the teeth and process.

After the formative stage of the jaw has passed, the rapid and forcible expansion of the arch, as by the use of a jack-screw, not infrequently separates the maxilla at the suture at the median line. This is thought by some practitioners not to be objectionable, but I have seen several cases accompanied with a degree of congestion that certainly did not encourage the desired bony deposit in those parts. This unpleasant result has not been observed to follow the use of gradual spring-pressure.

Jack-Screw.—The jack-screw for the correction of irregularities of the teeth is thought to have been introduced by Dr. William Dwinelle about the year 1849. He first made it of gold, but later used steel on account of its greater strength. He discovered that by placing a small amount of zinc in a hole in the end of the screw device its oxidation was prevented.

The jack-screw has been used successfully by many practitioners, and is still recommended in recent text-books and journals for expanding the arch and moving individual teeth. It is described as being attached to the teeth with cemented bands, ligatures, attached to plates, etc., and crossing the arch in many directions. It will be observed, however, for obvious reasons, that it is seldom recommended by its advocates for moving the teeth of the lower arch.

I have not found the jack-screw of especial value in any case, and, owing to its interference with the tongue in pronunciation and mastication, suggest that its use, both for pushing and pulling the teeth, be discontinued in favor of methods more agreeable to the patient. Realizing, however, that some operators employ it, my system of

anchorage for holding the jack-screw in position in almost any part of the mouth will be described, showing especially how to form the anchorage for expanding the arch with a jack-screw made of steel or other metal.

For this purpose partial-clasps and spring-clasp attachments should be arranged on the teeth chosen for anchorage (Fig. 103). The jack-screw is then placed in position across the arch, and soft solder flowed with the soldering iron over the end of it and the metal constituting the anchorage portion joining them. The nut that forms a portion of the jack-screw can thus be secured at either end in the position desired. This not only makes a firm anchorage, but permits the easy removal of the device for cleansing and making the necessary changes.

Fig. 103.

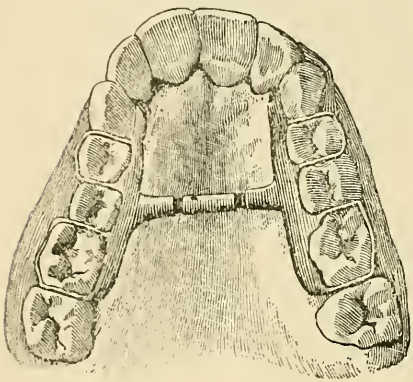

Coffin Plate (Fig. 104).—In making an apparatus after the Coffin method for expanding the upper arch, an accurate model is first made. A wax try-plate is formed on the model, in the shape desired for the plate. It should cover the palatine arch and extend over the grinding surface of the molars and bicuspids to the buccal side, enclosing them and fitting the necks of the teeth sufficiently well to insure good anchorage. The plate cannot be made to fit satisfactorily unless the model is a perfect one. The impression should usually be made with plaster of Paris. Mr. Coffin recommended for this purpose taking the impression with gutta-percha; making it very hot, then plunging it in cold water to cool the surface just before being pressed firmly into position in the mouth. If either the impression or the model is scraped or changed, the vulcanite plate

Fig. 104.

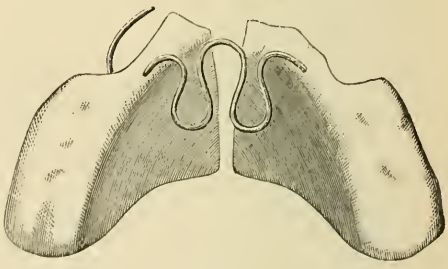

when finished will need to be dressed correspondingly; therefore they should not be interfered with more than is necessary to guard against excessive undercuts, etc., which always requires the dressing of the apparatus. Mr. Coffin suggests the use of small-sized spring-wire for regulating purposes and for spreading the arch, and recommends that the spring for connecting the lateral halves of the plate be made of piano-forte wire of a diameter between three-hundredths and four-hundredths of an inch, bent into a three- or five-curve serpentine figure like a rounded capital W, and shaped to conform to the surface of the plate; flattening the ends of the springs where they are to enter the vulcanite. When the spring is ready to be placed in position, a thick piece of tin-foil is spread smoothly on the try-plate underneath the spring portion, and the flattened end is embedded in the wax. The corners of the tin-foil are then bent up, so that when the plaster is poured into the flask it will run about the foil and hold it and the wire in position in the upper part of the flask when removed. The foil also insures a polished surface to the plate under the loops of the wire after the vulcanizing process.

This or other springs can be held in position in the flask by placing around them iron binding-wire and letting the ends extend into the plaster instead of the tin-foil, if preferred.

The plate when finished should be fitted to the mouth, then divided in half along the median line with a fine saw, and the edges smoothed carefully so as not to twist the spring. Expansive force is exerted by opening the loops from time to time. An appliance for the lower arch is made in a similar manner (Fig. 93).

Mr. Coffin recommends that the ends of the wire that are to be embedded in the vulcanite be tinned or coated with soft solder. The steel is most liable to corrode at the point where it enters the vulcanite, and the tin or lead covering may lessen this tendency. The central portion of the connection-spring can be made into a single loop if preferred, and other springs can be added for moving any especial teeth.

The part of the plate that forms the grinding surface should be shaped to make a good articulation with the teeth of the opposite arch. It has been recommended that the surface be roughened to assist mastication.

The writer has used the Coffin method with much satisfaction

since the introduction of the system into this country, but was early impressed with the following objections to covering the teeth with rubber:

First, on account of its interfering with the speech and comfort of the patient.

Second, it endangers the articulation of the bicuspids and molars, especially where the appliance is to be worn several months, sometimes producing detrimental changes in the occlusion that would not have taken place had the teeth of one arch been allowed to articulate with those of the other during their movement.

Third, the shape of the plate, having deep depressions on either side for the accommodation of the teeth, is unfavorable to cleanliness, it being difficult for the patient to keep it in an aseptic condition, and the teeth, therefore, being more liable to decay from the decomposition of the accumulating saliva and food particles.

Fourth, opening the bite assists the regulation of the teeth only in a limited number of cases.

For these reasons I have adopted a modified form of split plate,* which does not cover the teeth, the anchorage being gained either by wire-clasps, spring-clasps, or collars with lugs (Figs. 68 and 101); or by a wire-clasp extended directly over the arch at the junction of the teeth at any place the articulation will permit to rest on the buccal side, as seen in Fig. 112. It is an advantage in some instances to move the process with the teeth, and the separation of the palatine plate can be made in any direction most favorable for accomplishing the result desired (Fig. 199).

Unilateral Expansion.—With the narrow arch the articulation of the teeth is occasionally such as to make it desirable that only one side should be moved.

In the process of expansion this can be accomplished with an appliance made as seen in Fig. 105. It is applicable for the upper or lower arch. A spring base-wire is shaped to follow the lingual curve; one end is anchored by a spring-clasp attachment to a tooth that is to be moved, and the other end by spring-clasp attachments to one or more teeth on the opposite side of the arch. This portion of the anchorage can be forlified by extending rubber vulcanite or metal from it to cover more or less of the gum and process.

---

* Jackson, Dental Cosmos, 1890, p. 879.

When both sides of the arch require to be moved equally, and it is found that only one side is moving, this form of anchorage is applicable by attaching the metal or vulcanite to the appliance on the side that is moving too rapidly.

Fig. 105.

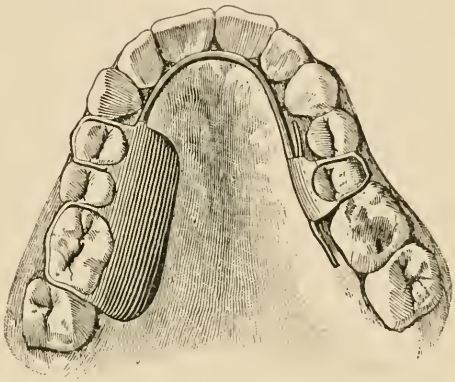

Metal can be added to an appliance at any time for this purpose by placing it on a model of the mouth in exact position and flowing soft solder over the parts with a soldering iron, shaping it in the form desired.

Metal gauze or plate-metal is sometimes employed. In this case it will be observed that all of the force was first exerted on but one tooth, the second left upper bicuspid, and later a small spring was engaged with the adjoining teeth for moving them outward.

Fig. 106 shows an appliance used to expand the upper arch laterally for Miss H., aged fourteen years. The condition of the articulation required that only one side should be moved.

Fig. 106.

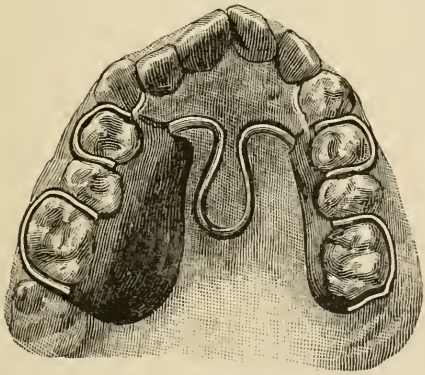

The appliance was made by arranging a palatine spring base-wire, No. 12 gauge, having a U-shaped loop about half an inch long pointing towards the palate, with the ends of the base-wire curved backward and anchored with a spring-clasp attachment over the first bicuspid and first molar on either side. The part of the appliance on the side that was not to be moved had the anchorage fortified by attaching to it with solder a swaged metal plate, extending upward from the spring-clasp attachments to cover a good portion of the side of the palatine arch. When con-

siderable force is to be exercised the plate portion should be quite broad, the loop in the base-wire being opened slightly from time to time as required.

Unilateral prognathism is not uncommonly met with. Fig. 107 illustrates a case that was brought about by the injudicious extraction of a left upper molar, causing an arrest of development on that side of the arch, the lower jaw continuing its normal development until finally all of the left lower teeth closed outside of the upper ones, at the same time drawing forward the right side of the lower jaw. The unilateral expansion of the upper arch and the application of a chin-cap was recommended.

Fig. 108 shows the position of the teeth of Mr. G., aged forty-one years.

The left upper cuspid and the lateral and central incisors closed far inside of the lower arch, the lower cuspid and incisors projecting near

Fig. 108.

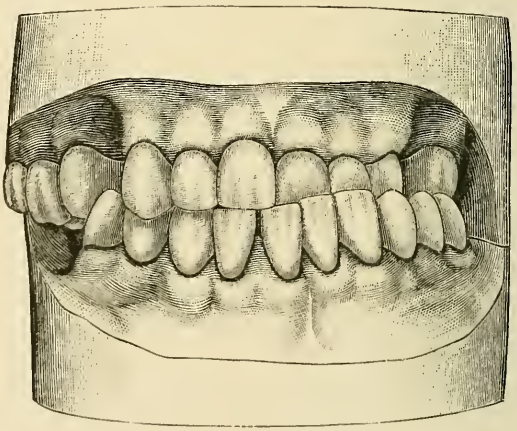

the upper gum in front of them, some of the teeth being considerably worn. Several molars and bicuspids of the upper and of the lower arch were absent, making it somewhat difficult to get a good anchorage for the correction of the irregular teeth. A device was arranged to open the bite to facilitate the movement, and at the same time to secure additional anchorage by making attachment to the upper incisors and cuspid on the opposite side of the arch. A spring-clasp attachment was arranged over the first left upper molar, the only remaining anchorage tooth on that side, and a spring-clasp attachment over the second right upper bicuspid, the first

Fig. 107.

bicuspid having been removed, with partial-clasps on the first molar, cuspid, lateral and central incisors (Fig. 109). Small short wires were shaped to pass over the incisive edge at the junction of the central incisors, lateral, and cuspid, resting on the partial-clasps, with the ends on the labial side extendingperpendicularly towards the gum to assist the anchorage and to prevent the appliance being dislodged in mastication. The sides of the device were connected by a palatine base-wire. A semicircular spring with two U-shaped loops was arranged with the ends extending to the anchorage portions. All of the parts were united with solder. The bite was opened by building additional solder onto the partial-clasps on the incisors and cuspid, and onto strips of plate-metal, one extending from the cuspid across the space and over the bicuspid, and the other over the molar on the opposite side of the arch. The bite being opened in this manner permitted the outward movement of the instanding teeth when force was applied with the looped spring. The anterior part of the spring was retained by a lug on a collar cemented to the cuspid. The regulating was completed in a limited time and with no especial discomfort to the patient. In Fig. 110 is seen the position of the teeth, with partial upper and lower plates inserted, which served for retaining and filled the vacancies.

Fig. 109.

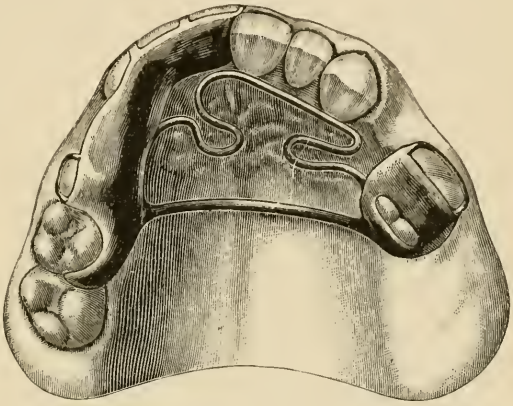

Fig. 110.

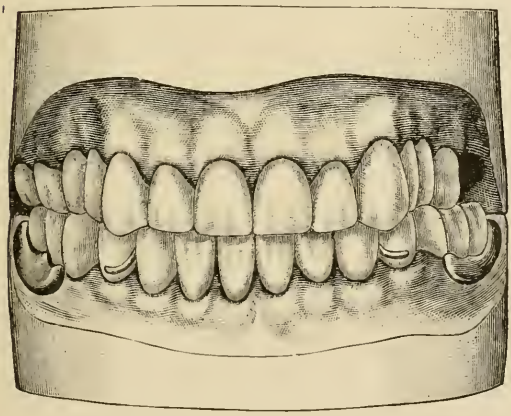

When the lower molars and bicuspids are absent it is sometimes difficult to adjust a partial plate so that it will be held firmly in place. The cuspids are tapering, and clasps extending forward from the plate in the usual manner to encircle the cuspids do not retain it well. In such a case flat clasps can be made to extend from the plate between the lateral incisors and cuspids to engage with the mesio-labial surface of the latter, or wire-clasps extended over the arch at the junction of the teeth in front of the cuspids to clasp their labial surface.

Fig. 111

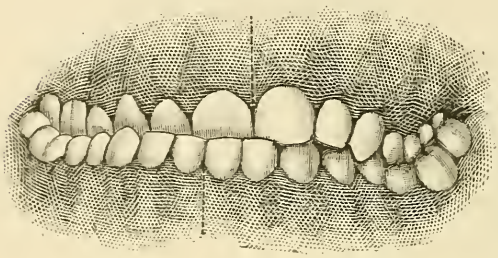

Fig. 111 illustrates the position of the teeth in the case of Miss B., aged twenty-six years, a teacher in the public school.

The lower jaw appeared very prominent on the right side, otherwise she was fine-looking and her features were quite regular. On examination it was found that the teeth on the right side of the upper arch closed inside of the line of the lower ones, the second right upper bicuspid having erupted inside of the arch, resting on the palato-mesial side of the first molar, with the first bicuspid in the place of the second and in contact with the molar. The median line of the lower arch was to the right of the median line of the upper arch more than the width of one of the teeth. This condition had existed since the teeth had erupted, and the incisive edge of the upper incisors had become worn where they crossed the arch of the lower ones. It was found, by measurement of the models made of the teeth, that if the first right upper bicuspid, cuspid, lateral and central incisors were moved forward and outward sufficiently to let the second bicuspid into its proper position, at the same time expanding the arch, the teeth could be made to articulate with those of the lower, and correct the appearance of the deformity without operating on the lower jaw.

A modified split plate of vulcanite rubber with springs was used to expand the arch and move the teeth into position (Fig. 112). It was anchored with wire-clasps and platina-gold collars with lugs on the palatal side cemented to the teeth. The appliance was made

by first obtaining an accurate impression of the irregular teeth. A try-plate was formed over the palatine portion of the upper model in the usual manner, and a scratch made across the surface of it at the median line to tell where to separate the vulcanite with the saw when the plate was finished. A German silver wire, No. 14 gauge, was then formed into a loop, the loop being about one-half inch long and fitted to the surface of the try-plate, crossing the centre, with the ends curved and embedded in the wax to connect the lateral halves of the plate. A portion of the ends of the wire that entered the vulcanite was first flattened with a hammer as shown by the dotted lines in the figure. When the spring is made of German silver or gold, the temper should be drawn from that part of the spring.

Fig. 112.

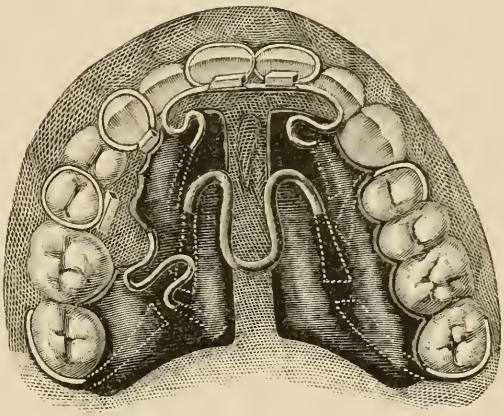

The second right bicuspid was moved forward and outward with a spring wire, No. 18 gauge, formed into the shape of a letter S and attached to the distal part of the plate. A platina-gold collar, with a lug on the palatal side, was finally cemented to the bicuspid to anchor the end of the spring. The ends of the wire-clasps, after being embedded in the wax in proper position for anchorage, were covered with plaster to hold them. The looped spring across the centre and the spring for moving the bicuspid had pieces of binding wire placed about them, their ends projecting upward to extend into the plaster, so as to hold the springs when the upper part of the flask was made and separated for the removal of the try-plate. The case was then packed with rubber, care being exercised to have the rubber extend well around the ends of the springs and clasps.

After the lateral expansion of the arch was somewhat advanced, a spring was attached for moving the front teeth outward. A platina-gold collar with a lug on the palatal side was cemented to each of the central incisors. A spring-wire was then formed to pass under

the lugs, following the palatal curve of the teeth to the cuspids, where the wire was bent back on itself and made to form the shape of the letter S, the ends, extending into holes made in the vulcanite on each side in such form that the spring could be taken out when desired.

The patient removed the appliance daily for cleansing. Slight additional pressure was put on the springs by bending open the loops about once in four days. Fig. 113 shows the condition of the occlusion after the regulating was completed.

Anterior Expansion of the Lower Arch.—The anterior expansion of the lower arch is not infrequently required in cases of arrested development of the jaw, the incisors needing to be moved outward so as to give proper form to the arch, or to make room for erupting laterals or cuspids.

Fig. 113.

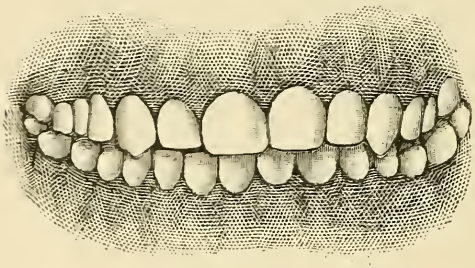

Fig. 114 shows the position of the teeth in the lower arch of Miss V., aged eight years, a marked case of arrested anterior development. The lateral incisors were considerably inside of the normal line, with the spaces much too narrow for their admission. An apparatus for the anterior expansion was made by arranging spring-clasp attachments on the second deciduous molars; the anchorage portions were connected with a lingual base-wire. The front part of the base-wire was bent downward as low as the tissues would permit without interfering with the action of the tongue. Two curved finger-springs were attached to the anchorage with the ends of the base-wire, one on either side, and shaped to extend forward, following the lingual curve back of the teeth to be moved. The free ends were left long to extend well over to the opposite side of the arch,

Fig. 114.

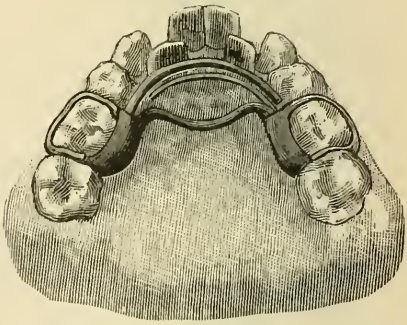

the springs parallel with one another and retained by passing under lugs on collars cemented to the laterals. Force was applied by slightly bending forward the finger-springs from time to time. Fig. 115 illustrates the appliance and the position of the teeth after the completion of the regulating, the same appliance being continued in use for retaining.

Fig. 115.

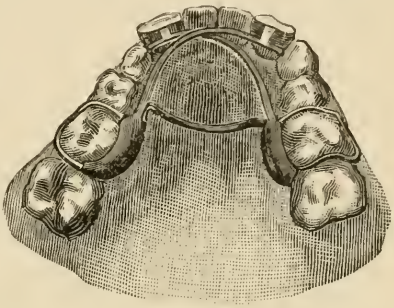

Another apparatus of convenient form for anterior expansion is shown in Fig. 116. One or more collars with lugs on the lingual side are cemented to the incisors. Spring-clasp attachments are arranged on the second deciduous molars with partial-clasps on the adjoining teeth; the sides are connected with a lingual base-wire bent downward as described, with a slight space left between it and the teeth on the sides of the arch just in front of the anchorage portions.

Fig. 116.

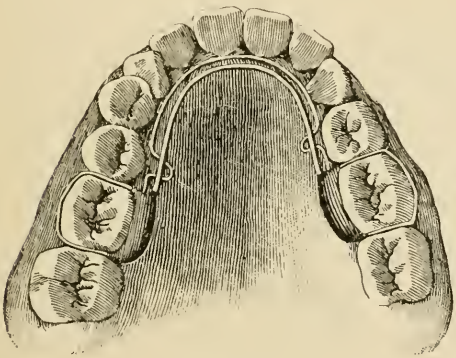

For the anterior expansion, a spring-wire, about No. 19 gauge, is made to follow the lingual curve of the teeth, and is formed into a U-shaped loop about two- to three-eighths of an inch long on each side of the arch, the loops being arranged a little in front of the anchorage portion to which the ends are soldered, with the loops resting between the base-wire and the teeth, projecting downward. The anterior part of the base-wire, bent downward in this manner, makes it easier for the operator to open the loops in the spring-wire in order to cause the desired pressure, and interferes less with the action of the tongue. After the arch has been expanded anteriorly, if desired, the sides of the base-wire and spring can be bent outward for the lateral expansion of the arch. A single loop in the spring arranged at the median line is sometimes applicable for moving outward instanding lateral incisors.

A method employed for expanding the lower arch anteriorly and laterally with springs attached in vulcanite is illustrated in Fig. 117.

The arch was much contracted, and the lateral incisors had erupted far back of their normal position. The space for the lateral on the right side was nearly closed, while on the left side it was much too narrow. An accurate model was prepared and an appliance made of vulcanite, arranged in lateral halves, one on each side of the arch, and connected by a spring base-wire. The centre of the base-wire was formed into a loop to rest between the instanding lateral incisors and near the gum back of the centrals, with the ends extending into the rubber. The parts of the appliance on each side were anchored to the teeth by a continuous spring-clasp, which was made by extending a platino-iridium wire from the rubber over the arch at the junction of the second deciduous and first permanent molars, across the buccal side of the deciduous molars and cuspid near the gum, and through the space in front of the cuspid to the lingual side, where it was attached to the rubber again.

Fig. 117.

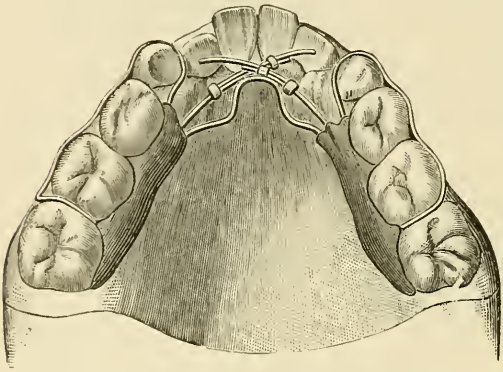

The continuous spring-clasps anchor the appliance, prevent it from pressing unduly on the gum, and do away with the necessity of extending the rubber on to the grinding surface of the teeth, which would interfere with the articulation.

The loop in the spring base-wire was opened from time to time by bending. This expanded the anterior part of the arch laterally and made room for the lateral incisors to take their positions.

The lateral incisors were moved outward by attaching spring-wires in the rubber, each extending forward in a curve to the lingual surface of the lateral on the opposite side. A more detailed description of this case, including the method of retaining, is given on page 164.

The advantage of this form of appliance, and especially of the clasp portion and looped spring base-wire, was described in a paper read before the New York Odontological Society in 1887.*

A metal device for causing anterior and lateral expansion of the arch is readily made by attaching curved finger-springs to an appliance like Fig. 85.

In some conditions for anterior expansion of the lower arch supplemental force is used to advantage. (See Fig. 144.)

Anterior Expansion of the Upper Arch.—The application of force to the upper incisors and cuspids for causing their outward movement is usually also sufficient to move forward the alveolar process that surrounds them, and in young patients, when the force is applied gradually, it not uncommonly forces forward the process and at the same time the bone of the intermaxillary region.

Fig. 118 shows a suitable appliance for expanding the anterior third of the arch. It is constructed with a palatine base-wire

Fig. 118.

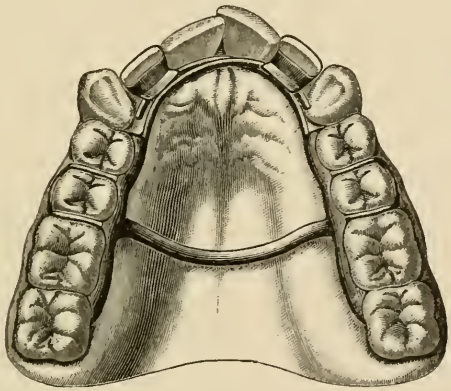

anchored with partial-clasps and spring-clasp attachments. A curved finger-spring is made to extend forward from each of the anchorage portions, following the gum line on the lingual side of the teeth, usually reaching to the opposite side of the arch. For retaining the ends of the springs, a collar with a lug is cemented to each of the laterals, central incisors, or cuspids.

* Jackson, Dental Cosmos, 1887, p. 376.

Force is applied to the teeth to be moved by bending outward the corresponding part of the springs.

Fig. 119 illustrates a combination expansion device for expanding the arch anteriorly, and also laterally when desirable. For lateral expansion, a palatine base-wire crosses the distal part of the arch, the ends extending forward to be attached in the anchorage. For the anterior movement, a semi-circular spring is fitted to the lingual side of the incisors near the gum, passing underneath lugs on collars cemented to two or more of them, beyond which two U-shaped loops are formed projecting well towards the median line, with the ends of the spring attached in the anchorage. Action is caused by opening the loops a little at a time.

Fig. 119.

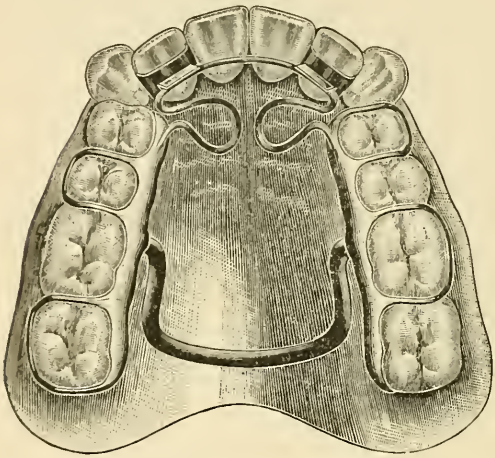

An apparatus, consisting of a modified Coffin plate and springs, for forcing outward the incisors with the bone and process of the intermaxillary region is shown in Fig. 120. It is made of vulcanite covering the palatine arch, with the anterior part separated approximately at a right angle with the median line opposite the cuspids, leaving it similar to the shape of the palatine outline of the intermaxillary bone. This is connected to the body of the plate with two springs of about No. 18 gauge formed into loops. The body of the plate is retained by wire-clasps or spring-clasps ex-

Fig. 120.

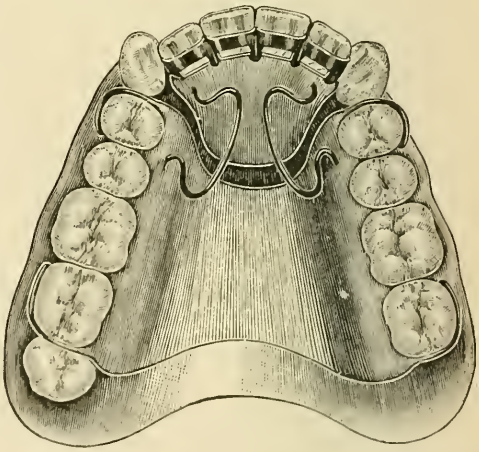

tending around a molar and bicuspid on each side, with the anterior part retained by lugs on collars cemented to the teeth to be moved.

For the unequal spreading of the maxilla, see Fig. 199.

Where the whole arch is contracted, it often occurs that the front teeth need to be moved considerably outward. Generally, in such cases, if much force is to be exerted, the operation for the lateral expansion should not be undertaken until the teeth in the front of the arch have been moved outward into line, as usually it is not practicable to utilize teeth for anchorage that have been moved. For these conditions, the apparatus for moving outward the upper incisors can be made with any desired form of spring attached in a plate, or with a rigid palatine base-wire. When ready to expand the arch laterally, the rigid base-wire can be separated in the centre and converted into a spring base-wire. (See Figs. 369–371.) This change is easily made, as described in Chapter VII., Anchorage and Appliances, page 83.

For description of other apparatus for anterior expansion, the reader is referred to Chapter XI., Incisors, to move Outward or Labially, including supplemental force (Fig. 373).

CHAPTER X

CONTRACTION OF THE DENTAL ARCH

Of the cases of irregularity presented, but a small percentage require the lateral contraction of the distal part of the arch, but occasionally the occlusion can be improved by moving the molars lingually (Fig. 482). The incisors, cuspids, and bicuspids are more frequently too prominent, and need to be moved inward to improve the occlusion and contour.

Contraction of the Lower Arch.—Fig. 121 shows the position, before regulation, of the teeth of Miss S., aged fourteen years; of nervous temperament.

Fig. 121.

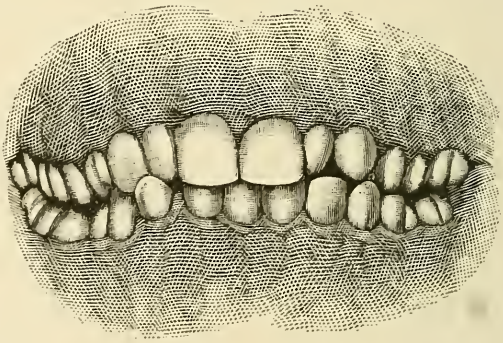

The right lower cuspid, left lower lateral incisor, cuspid, and first bicuspid closed outside of the teeth of the upper arch, with slight spaces between some of them, causing an unpleasant expression of the mouth. This form of irregularity is not commonly met with, and is considered difficult to correct with ordinary appliances.

Fig. 122 shows the form of device used. A stiff lingual base-wire was arranged to follow the inner curve of the arch, leaving sufficient space between it and the irregular teeth to allow them to be moved into position. The ends of the base-wire were anchored to the first molars by spring-clasp attachments. Wire-clasps bent to extend to the distal side of the second molars to assist the an-

chorage were soldered to the partial-clasps at the same time the base-wire was attached.

Fig. 122.

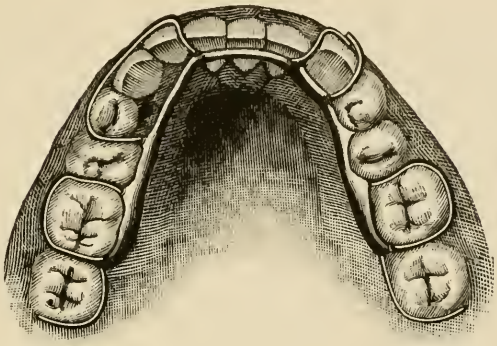

The right lower cuspid was moved into line by a spring shaped similar to a spring-clasp, made by bending a small-sized spring-wire twice at right angles, having the width between the parallel sides equal to the width of the cuspid. This portion of the spring was attached to the base-wire, and the arms bent to extend up and over the arch at the junction of the teeth either side of the cuspid to the gum line, the ends being curved towards one another to rest on the labial side of the tooth, leaving the ends free.

The left lower lateral, cuspid, and first bicuspid were moved into position by a continuous spring, shaped to cross their labio-buccal faces

Fig. 123.

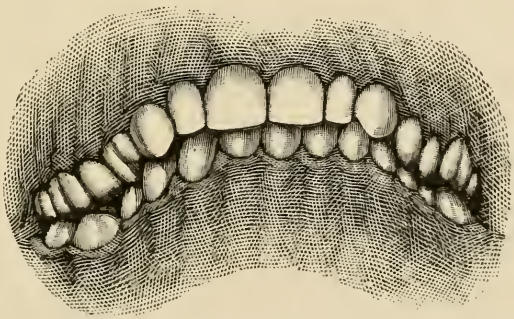

at the gum line. The ends of the spring extended over the arch at the junction with the adjoining teeth, and were soldered to the base-wire.

Force was exerted by removing the appliance and bending the springs a little at a time to rest nearer the base-wire. Fig. 123

illustrates the position of the teeth when the regulation was completed, the same appliance being used for retaining them.

Fig. 124.

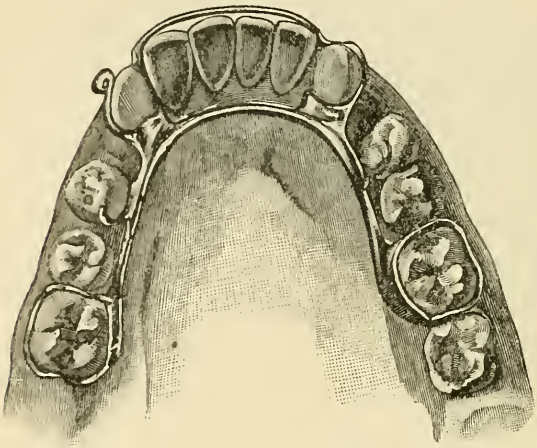

Many similar forms of apparatus have been devised for contracting different parts of the arch. Fig. 124 shows an appliance employed for contracting the anterior part of the arch by moving inward the lower incisors. A lingual base-wire was anchored by spring-clasp attachments to the molars and partial-clasps on the cuspids. A spring-wire, No. 19 guage, was shaped to follow the labial side of the incisors a little above the centre of their crowns. Near the cuspids the wire was curved downward towards the gum, and again upward, forming U-shaped loops. The ends were then curved backward to extend over the arch, passing near the incisive edge, to the lingual side, where they were united with solder to the partial-clasps and base-wire. Figure 125 illustrates the appearance of the appliance. Force on the incisors was caused by the labial spring, bending inward the inner half of each of the loops with flat-nosed pliers.

Fig. 125.

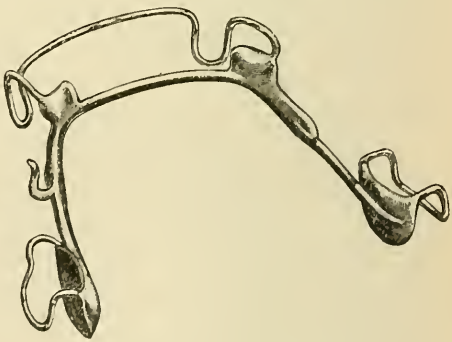

Contraction of the Upper Arch.—Cases are not infrequently presented with spaces between the teeth and an abnormal enlargement of the arch, resulting from hypertrophy or chronic congestion of the tongue. These conditions are accompanied with irritation of the digestive tract. In some cases of nervous irritation the tongue is thrust forcibly forward, causing excessive pressure on the teeth of

the anterior arch. Usually there are markings or deep indentations on the tip or lateral margins of the tongue, caused by its pressure against the teeth. If the physical condition be not corrected, the teeth when regulated will need to be retained by a device worn regularly at night.

The form of appliance presented in Fig. 126 is designed to contract the arch laterally, and, if desired, at the same time to move the

Fig. 126.

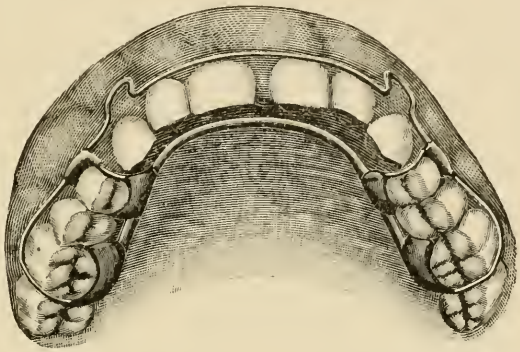

front teeth into line, closing the spaces. It can be used for either the upper or lower arch. The device is made by forming a spring base-wire to the palatal curve, leaving a space about one-eighth of an inch between it and the necks of the incisors and cuspids. The ends of the base-wire are anchored by forming partial-clasps to the molars and bicuspids that are to be moved, and extending a continuous spring-clasp on the buccal side of the teeth near the gum, with one end passing over the arch at the mesial side of the first bicuspid, to be soldered to the partial-clasp with the base-wire. The other end, extending over the arch at the junction of the molars, is to be attached to the partial-clasp in the distal part of the arch. A semicircular spring, with two U-shaped loops for moving the incisors and cuspids inward, is formed to cross the incisors at the gum line, with the loops located opposite the cuspids, pointing upward to follow the contour of the gum so as not to interfere with the action of the lip. The ends are to be soldered to the continuous spring-clasps.

The arch is contracted laterally by removing the appliance and bending the ends of the spring base-wire towards each other.

Force is applied on the fronts of the incisors and cuspids by closing the loops somewhat in the spring that crosses them.

To systematize the bending of the springs, a tracing is made by laying the appliance on a piece of card-board and marking its outlines with a sharp-pointed pencil. A mark is to be made, inside of the original tracing, for the distance it is desired to change the springs, and the wires then bent to compare with the new marking.

In Fig. 127 is seen an appliance for contracting the anterior part of the upper or lower arch when there are spaces between the

Fig. 127.

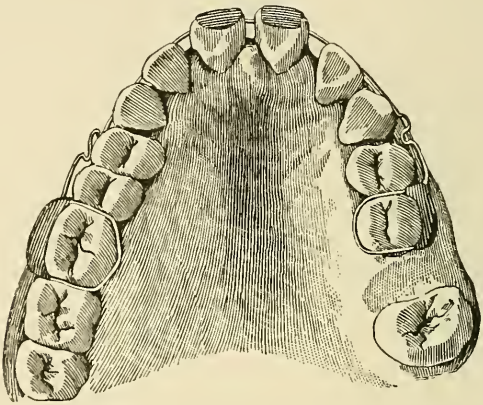

teeth. It is applicable in cases of close occlusion. The device is made by forming a spring-clasp attachment over one or more molars or bicuspids on each side of the arch for anchorage, with the partial-clasps arranged on the buccal side, and shaping a labio-buccal spring base-wire, about No. 19 gauge, to cross the front teeth, following the line of the gum to the first bicuspids. Here one or more loops or corrugations are formed in the wire on each side of the arch, the ends of the wire extending back to the anchorages to which they are soldered. The loops should be shaped to the contour of the gum so as not to interfere with the action of the lip. The spring is held in position on the incisors, by forming a thin piece of plate-metal to the labial side of one or more of them, with one end made to extend over the incisive edge and the other passing under the spring to which it is soldered. By removing the appliance and closing the loops somewhat, the teeth are forced inward, which in effect contracts the size of the arch.

When used for the upper arch, and when the occlusion will permit, the appliance will be more firmly retained by reversing the spring-

clasp attachments, having the partial-clasps on the palatal side, and the anchorage portions connected with a palatine base-wire. In such case the spring-wire should be shaped to extend over the arch at the junction of two of the teeth to the lingual side, where the ends should be attached to the base-wire.

The contraction of the arch laterally in the region of the bicuspids and molars has been accomplished with a device as shown in Fig. 465.

In the early eruption of the teeth it is occasionally desirable to lessen the prominence in the anterior part of the arch, especially when there are spaces between the teeth. A retainer should be worn for a considerable length of time to prevent over-development. Other methods of contracting the anterior part of the arch by moving the teeth lingually will be considered in Chapter XII., Incisors, to move Inward or Lingually.

CHAPTER XI

INCISORS, TO MOVE OUTWARD OR LABIALLY

Methods of correcting the position of incisors that are inside of the natural circle of the arch and need to be more prominent will now be considered, first describing the outward or labial movement of the lower incisors.

The difficulty experienced in regulating the teeth of the lower arch by the ordinary methods recommended often prompts the dentist to delay the operation from time to time, and more often even its consideration.

The lower incisors are erupted usually before the upper ones. When normally located they assist in guiding the upper incisors into a correct circle as the latter move downward in the process of eruption. When the lower incisors have taken an irregular position, the upper incisors generally assume an irregular position also. For this reason, if the permanent upper incisors are erupting, and the lower incisors are back of their normal circle, an appliance should be inserted to cause their outward movement, encouraging the development of the bone and process; and when the teeth are in a correct position they should be retained for a considerable length of time, or until the upper incisors are fully erupted. If the lower jaw is not developing as rapidly as the upper, pressure outward on the lower incisors will encourage its anterior development.

The permanent incisors may take an abnormal position from want of space caused by lack of development of the jaw. When the lower incisors are in good position and the upper incisors irregular, it is not always advisable to enlarge the anterior upper arch, prior to the loss of the deciduous molars, enough to admit the irregular teeth. The molars occupy more space than is required for the incoming bicuspids, and when the deciduous molars are lost the deciduous cuspids are permitted to move laterally backward, allowing more space for the incisors to take a correct position; and although the permanent incisors are broader than the deciduous ones, the permanent cuspids when erupted usually have room to take a good position if the deciduous cuspids are retained until about the time of the eruption of the permanent ones.

Lower Incisors, to move Outward.—When the lower incisors are irregular they are usually much crowded in the arch, and expansion is required to give them a normal position. Fig. 128 illustrates a simple device for increasing the space and moving outward an instanding central or lateral incisor.

Fig. 128.

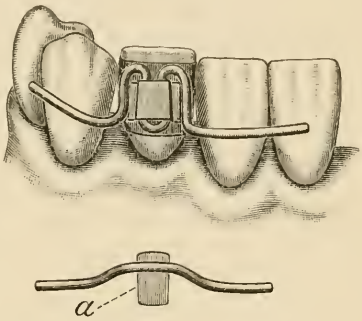

A thin, broad collar is fitted to the tooth, to which it is finally cemented. A piece of plate-metal, a little narrower than the width of the collar, is swaged with a form and soldered to the front, making approximately a box-shaped opening, the opening being a little broader towards the gum, and just large enough to admit a loop of small-sized spring-wire when bent rather closely upon itself. The ends of the spring are shaped to project downward and outward at a right angle to rest on the labial faces of the adjoining teeth. Force for moving the tooth is caused by bending the ends of the spring backward slightly from time to time and pressing the loop portion to place. In this and other similar devices described the force depends upon the twist of the spring.

When desired, instead of the loop-shaped spring, a narrow piece of plate-metal can be soldered to a wire-spring, as seen at *a*, the metal being of suitable width to fit tightly into the opening on the collar.

A device for moving outward or inward an irregular incisor is made as illustrated in Fig. 129. It was utilized to good advantage to regulate an instanding left lower lateral incisor for Miss E., aged twenty-three years.

Fig. 129.

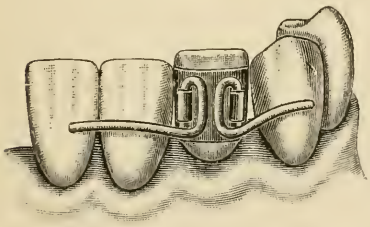

To the tooth to be moved is cemented a collar having attached two small perpendicular tubes, a little shorter than the width of the collar, each for retaining the end of a spring. When the tooth is to be moved outward one of the tubes should be located near the labio-distal, and the other near the labio-mesial surface. Each spring is formed into a loop with parallel arms,

one shorter than the other, the width of the loop being equal to the length of the tube. The shorter arm of the spring is then bent at a right angle towards the other arm to enter one of the tubes, usually from above downward, and the longer arm shaped to rest on the labial surface of the adjoining tooth. Force is supplied by bending forward the shorter arm of the spring and springing it backward to enter the tube. When both springs are adjusted the end of the loops should rest near in contact at the centre of the tooth. If the tooth is to be moved inward, the tubes should be attached to the lingual side of the collar.

In Fig. 130 is shown another form of device for moving an incisor outward. A broad collar with a short tube soldered per-

Fig. 130.

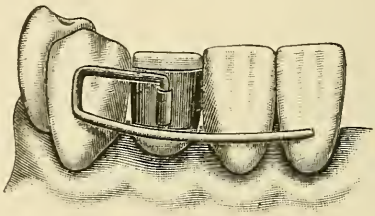

pendicularly to the labial side near the centre is cemented to the tooth to be moved. A small spring wire is bent into the form of a U-shaped loop, with the width between the parallel arms equal to the length of the tube. One arm is left short and bent at a right angle towards the other to enter the tube, usually from above downward. The loop is left sufficiently long to project well on to the adjoining tooth on one side when in position, and the longer arm shaped to extend across one or more teeth on the other side of the tooth being moved. Force is applied by bending outward the shorter arm of the spring, and in adjusting it is pressed backward to enter the tube.

The devices described are utilized for moving outward or inward the incisors or other teeth of the arch, and also for their rotation.

An appliance with a spring, termed a finger-spring, is used more often than any other for moving central or lateral incisors of either the upper or lower arch.

For moving lower incisors outward an appliance is made with a lingual base-wire, about No. 14 gauge, formed at the gum line,

extending backward on either side, the ends anchored with spring-clasp attachments to the deciduous molars, bicuspids, or permanent molars, the wire of the spring-clasp being of No. 20 or 21 gauge (Fig. 131). A finger-spring, about No. 18 gauge, bent into a curve, is

Fig. 131.

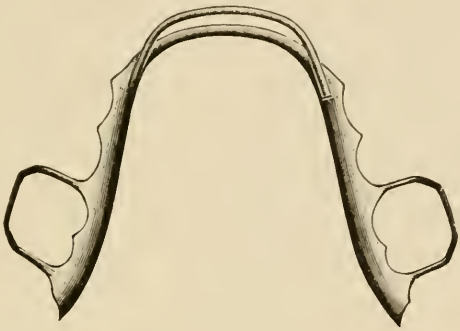

attached to the partial-clasp or base-wire near the anchorage portion, in position to extend forward and to the opposite side, crossing the teeth to be moved. The free end of the spring is held in position with a lug and collar cemented to one or more of the incisors.

Force is applied by bending the spring outward slightly from the base-wire. Owing to the length of the spring it continues its action for several days, and therefore it is not necessary to see the patient oftener than once or twice a week, or perhaps three times in two weeks, the appliance being removed daily for cleansing.

When one of the incisors has taken a position back of the natural circle of the arch, with the space too narrow for its admission, simple pressure on the lingual side is usually sufficient for moving it outward. In Fig. 132 is shown a device with the finger-spring curved forward, the end being held to the irregular incisor by a lug on a collar.

Fig. 132.

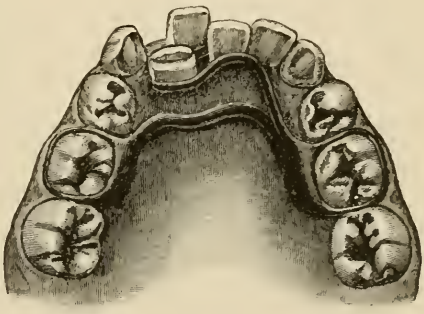

When the space is much too narrow, and no provision has been made for separating the adjoining teeth laterally, they are likely to be driven outward by force applied to the irregular tooth and to assume irregular positions. This can generally be avoided, and

space made for the admission of the incisor, by attaching an additional spring to the end of the finger-spring (Fig. 133). A small spring-wire is bent twice at right angles, the width between the parallel sides being equal to the width of the tooth to be moved, and attached with solder to the finger-spring, one end on either side being shaped to curve upward to the incisive edge and to pass over the arch to the gum line, where the ends are curved outward to rest on the labial side of the adjoining teeth.

Fig. 133.

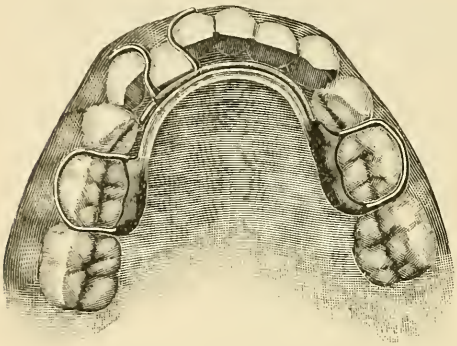

The action of the spring is caused by separating the lateral sides by bending, gradually increasing the space, while by bending the ends of the spring backward towards the finger-spring, pressure is exerted on the labial side of the adjoining teeth, assisting the finger-spring in moving the incisor into the circle. If required, a thin collar with a lug on the lingual side may be cemented to the incisor for retaining this part of the appliance, when it can be used independently or in connection with the finger-spring.

Cases are frequently presented with both of the lower or upper lateral incisors erupted inside of the proper line and considerably back of the line of the central incisors. Their position should be corrected early (Fig. 134).

Fig. 134.

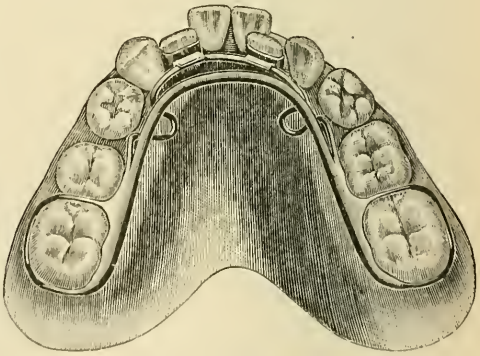

An appliance is made with a lingual base-wire, anchored with partial clasps and spring-clasp attachments to the deciduous or permanent teeth. The base-wire should be bent at an obtuse angle downward and forward just in front of the anchorage portion, leaving a space between it and the gum, and extended around the front part of the

arch as low as the tissues will permit without interfering with the action of the tongue. A spring-wire, about No. 19 gauge, is formed in a curve to cross the lingual side of the incisors, with a U-shaped loop about one-fourth of an inch long formed in the wire on either side opposite the deciduous molars or first bicuspids, to rest in the space between the base-wire and the gum. The ends of the spring are soldered to the partial-clasps with the base-wire. The anterior part of the spring is retained with lugs on collars cemented to the irregular teeth. Force for moving the laterals outward is applied by opening the loops or corrugations of the spring slightly, from time to time, with round-nosed pliers.

Fig. 135 illustrates the case of Master S., eight years of age. The permanent lower incisors were erupted in an irregular position and

Fig. 135.

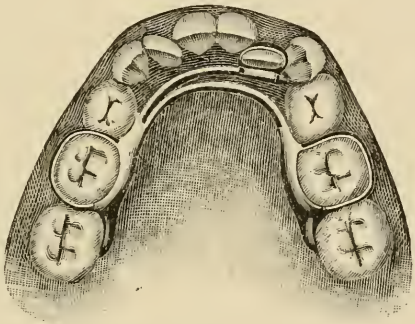

considerably back of the upper ones, which were also irregular and required to be moved outward. An appliance for their correction was made by forming a lingual base-wire to the inner curve of the arch, with the anterior portion of it bent downward to rest considerably below the necks of the teeth, making it more convenient for manipulation. The ends were anchored by spring-clasp attachments over the second deciduous molars, with partial-clasps on the adjoining teeth. A spring wire was then soldered to the base-wire near the anchorage portion and shaped to extend forward to cross the lingual side of the incisors. A collar with a lug was cemented to one of the laterals to hold the end of the spring in position. The incisors were gradually moved outward by bending the spring wire slightly at a time. When required, a longer spring was added to

follow their movement (Fig. 136). The base-wire did not interfere with the action of the tongue, and was not changed. As the lower incisors were moved outward they exerted force on the lingual side of the upper incisors, moving them outward to proper position. The same appliance was worn several months as a retainer until the teeth became firm in the process.

Fig. 136.

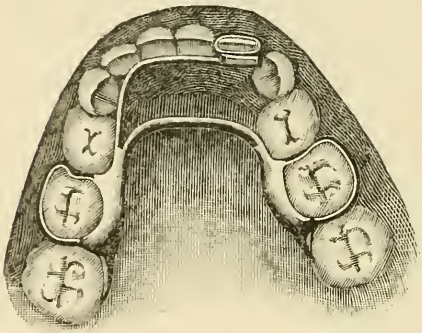

Fig. 137 represents the position of the teeth and the appliance used for their correction in the case of Miss K., aged eight years. The lateral incisors were erupted considerably back of the centrals, with insufficient space for them, requiring that the circle of the arch be enlarged, moving outward all of the incisors and the deciduous cuspids. The upper incisors were also irregular, and needed to be moved outward. The appliance was made by forming a lingual base-wire to follow the curve of the arch, having the front part bent considerably downward, and placed as low as could be without interfering with the action of

Fig. 137.

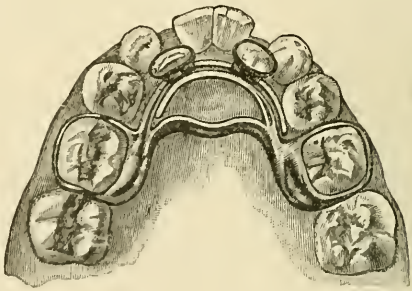

the tongue. The ends were anchored with spring-clasp attachments over the second deciduous molars. It is usually an advantage to have partial-clasps on one or more of the adjoining teeth. Two curved finger-springs were attached, one on either side, to the ends of the base-wire, each extending forward to the opposite side of the arch, where they rested on the lingual surface of the irregular teeth, one of them passing just below the other. The springs were retained

in position with lugs on collars cemented to the lateral incisors. Force was applied by bending the ends of the spring outward, gradually moving the teeth into proper position (Fig. 138). The same appliance completed the operation, which was done in about three months. The upper incisors were moved outward by the action of the lower ones against them in occlusion.

Fig. 138.

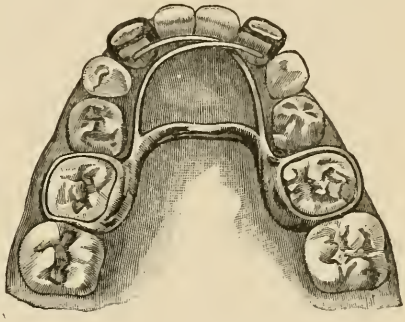

The upper incisors cannot always be moved in this manner without endangering the articulation or lap, and should not be attempted if the teeth have become firm in their sockets. It can be depended on only soon after their eruption, and in cases where the teeth of the upper arch lap well over those of the lower. Where an even expansion of the anterior part of the arch is required there is an advantage in having two springs extending forward, as they can be bent so as to exert force on any particular tooth, or to move all of them outward at the same time.

Fig. 139 shows an appliance for enlarging the circle of the arch, at the same time moving outward the incisors. In the case illustrated the cuspids were too prominent, with insufficient space for them. The arch was expanded laterally with a lingual spring base-wire, No. 14 gauge, having in it, at the median line, a U-shaped loop about one-fourth of an inch long pointing downward, the ends of the base-wire extending backward and soldered to the spring-clasp attachments for anchorage. The anterior part of the arch was expanded by two finger-springs, No. 19 gauge, attached one on either side with the base-wire. They extended forward, following the lingual curve, passing one another, with the free ends resting on the opposite side. The front of the appliance was retained by cementing to each of the

Fig. 139.

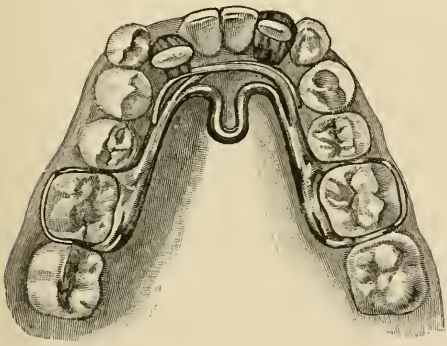

lateral incisors a collar with a lug. Force was applied by making slight changes in the shape of the springs from time to time.

In cases where the arch is to be much expanded the springs should be left long, otherwise they will need to be replaced with longer ones as the teeth are moved outward. The combined action of the springs arranged in this manner assists the base-wire in expanding the arch laterally.

Fig. 140.

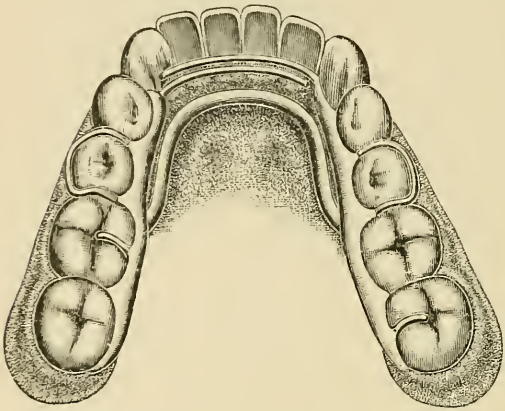

Fig. 140 illustrates another form of device with a lingual base-wire, for expanding the arch laterally and moving outward instanding lower incisors. The base-wire is arranged to follow the inner curve of the arch, resting as low as the tissues will permit; the ends are bent upward to be soldered to the centre of the anchorage portions, which include the cuspids, bicuspids, and molars. To the anterior part of the anchorage are attached two curved finger-springs, one on either side to pass back of the incisors. This connection of the base-wire to the centre of the anchorage prevents any warping of the appliance as the ends are bent outward for causing pressure.

Fig. 141.

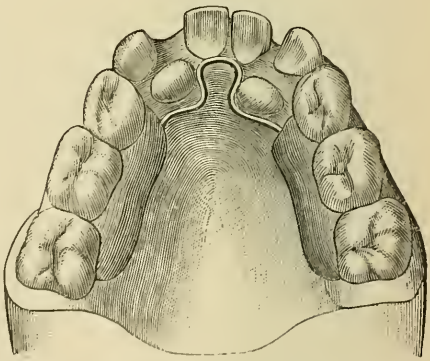

Fig. 141 shows the cast of the teeth of a boy aged nine years, with the lower arch much too narrow, each of the lateral incisors having erupted far back of the proper line.* The space for the lateral on the right was nearly closed, while on the left it needed to be broadened nearly the half of the width of the

* Jackson, Dental Cosmos, 1887, p. 375.

tooth. The deciduous molars, cuspids, and first permanent molars were in symmetrical line. For expanding the arch and making room for the laterals a vulcanite plate was made in two parts, arranged on the lingual side of the deciduous and permanent molars, extending a little over the gum. The latter is not often required (see page 123). The two sides were connected with a spring base-wire, No. 14 gauge, formed in a loop to rest between the laterals near the gum back of the central incisors, with the ends extending into the rubber on either side. (This form of plate can be made of cast metal in place of vulcanite, if preferred).

The plate was held in position by continuous spring-clasps of iridio-platinum wire formed to the buccal surface of the deciduous cuspids and molars, its ends extending in a curve over the arch to the lingual side and attached in the rubber (Fig. 142). The force

Fig. 142.

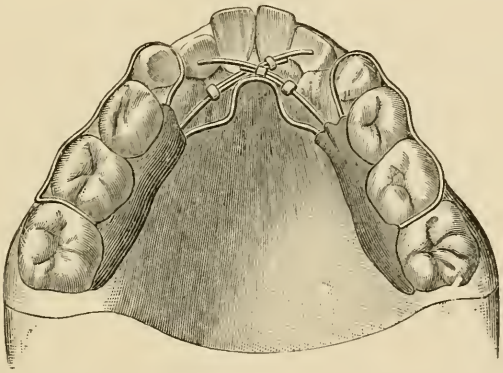

necessary for moving the lateral incisors outward was produced by finger-springs, one anchored in the vulcanite on either side of the arch, extending forward and crossing to the opposite side, where the free end was held in position on the lingual side of the lateral by a lug on a collar cemented to it.

The action of these springs not only moved the lateral incisors outward, but assisted the spring base-wire in expanding the arch. The loop in the centre was opened as often as necessary, and the finger-springs were at the same time bent forward. These soon had to be lengthened to follow the movement of the laterals. This was accomplished by using pieces of iridio-platinum wire, with two narrow rings of gold plate so attached with solder that they would pass over the ends of the springs. They were adjusted by slipping them

forward to attain the desired length. As the laterals moved outward the springs were necessarily bent to pass in front of the loop. The plate was inserted in September, and the following February the teeth were in position.

The appliance for regulating is easily made and adjusted, does not interfere with the articulation or mastication, and can readily be removed by the patient for cleansing. Any degree of force can be exerted that is desired; the front part of the arch can be expanded, and the distal part not changed, or *vice versa.*

For retaining, a wire device was applied as seen in Fig. 143, and worn for several months. (For description of making, see Chapter

Fig. 143.

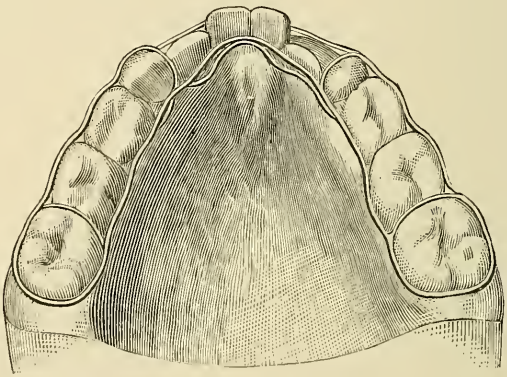

XXVIII., Retaining.) This device, with attachments, is also utilized for the regulation of the teeth. In the case illustrated the lateral incisors were but partially erupted, one of them projecting only a little above the margin of the gum. It was found advisable to attach an additional wire to the main bar passing on the palatal side, and bent to project downward in the form of a partial loop back of each of the lateral incisors for moving them farther outward, retaining them, and at the same time stiffening the appliance, the wire being attached with solder at the median line and at each end.

Pieces of plate-metal can be attached to the wire in this manner for moving or retaining teeth by soldering to it a spur of suitable shape to project upward or downward as required.

An appliance that is effective in some cases where the incisors need to be moved outward is made with springs extending from a base-wire or a plate to the labial side of those teeth. Finger-springs

are attached to the plate, one on either side, passing over the arch at the junction of two of the teeth, either in front or back of the first bicuspids, and curved forward to cross the necks of the teeth near the gum line, thus passing each other, the ends sometimes extending to the opposite side of the arch. Collars are cemented to the teeth to be moved, with hooks on the labial side to engage with the ends of the springs, or the springs can be secured to the teeth with ligatures. The latter method is not as cleanly, but is at times effectual. The force for the outward movement of the teeth is caused by bending outward the finger portion of the springs.

The same style of apparatus can be used for contracting the anterior part of the arch.

When there is insufficient anchorage for moving the lower incisors outward, as after the loss of some of the molar teeth or other cause, *external supplemental force* can be employed. A chin-cap, with wire standards supported by a cranial-cap, is carefully fitted to the lower jaw (Fig. 144). The standards are adjusted by forming and finally soldering to the chin-cap a heavy wire, about No. 8 gauge, projecting backward and then curved upward to rest a little in front of the ear on each side of the head, and to pass through short perpendicular tubes on the band of the cranial-cap. The latter is made of crocheted silk-twist attached to a heavy ribbon-band, as described on page 97 (Anchorage and Appliances). On the side of the ribbon-band, above and in front of the ear, is sewn a long strip of stiff plate-metal, a little narrower than the band and properly shaped, to which the eyelet for the passage of the standard and two hooks are soldered, one in front and the other back of it. To these hooks is attached a rubber band, which is drawn downward and passed over an adjustable knob with a screw on the standard. The knob is so located as to cause just sufficient tension on the band to sustain the device. A labial spring is attached to the chin-cap, shaped to project upward opposite the lips. It is generally made by bending a wire sharply on itself and extending parallel downward to the chin, the ends separated, shaped to the chin-cap, and soldered. The spring can be connected with the teeth in any convenient manner. When the apparatus in the mouth used for moving outward the incisors is retained with collars, a curved wire may extend from them or the apparatus over the lower lip to the labial spring, or an independent means of attachment may be made. If the curved wire

slips up or down, prevent it by notching the front of the spring, or by flowing onto it a little solder. Force is got by bending outward the end of the spring from time to time. It can be utilized in moving forward the cuspids, bicuspids, or molars on one or both sides of the arch; or for moving any of the teeth outward from the median line, as in lateral expansion of the arch, sometimes attaching two or more springs to the chin-cap.

For the correction of some conditions, an infralabial bar, made similar to Figs. 212–214 is preferable. It should be attached to the teeth, the arms curving over the lower lip, and a rubber band passed over each of the knobs on the arms and the adjustable knobs on the standards; or a bar similar to Fig. 373 may be applied, the metal loops being opened a very little at a time to cause force. By either of these arrangements the bar is held in a nearly constant relationship with the chin during the movements of the jaw.

A device arranged in the manner shown in Fig. 144 is suitable for the treatment of both simple and compound fractures of the lower jaw. In compound fractures the lateral body of the jaw is generally tipped inward and the lower end of the ramus drawn forward and outward. The chin-cap should first be formed in the shape that is desired for the jaw. It should extend beyond the fractured portion and be bent inward, or sufficiently padded to give the required force, or a spring should be attached for causing pressure at any point. Wires may be extended from splints arranged inside of the arch and pass over the lower lip, to be fastened to the chin-cap by passing into tubes (Fig. 380), or attached to the cap in any other suitable manner. The wires extending from the splints to the chin-cap are bent for drawing outward and supporting different portions of the jaw. When the jaw is fractured near the angle, the upward tension should be but slight.

Many variations from this form of apparatus have been devised. Some of the more important are described.

Upper Incisors, to move Outward.—In moving upper incisors outward, they should always be moved a little farther than it is intended they shall remain when the regulating is completed. Especially is this necessary when they are not long enough to lap well over the lower ones. In any case where the teeth are short and are not naturally well retained in their new position, a proper retaining device should be worn, made in such a manner as to encourage the

Fig. 144.

lengthening of the teeth that have been moved. Otherwise, when the jaw contracts, as is always the case when new deposit of bone takes place after the movement of the teeth, they are liable to draw backward in the line of the arch and rest in occlusion on the incisive edge of the lower ones. In no case should this condition be permitted to continue.

When articulating in this manner, the edges of the teeth are usually worn away, and as the surface becomes worn the lower incisors gradually take a position in front of the upper ones, encouraging the lower jaw to become prominent.

A simple device for moving outward an instanding upper incisor is seen in Fig. 145. A thin broad collar, with a tube soldered perpendicularly across the labial side near the centre, is cemented to the tooth to be moved, the tube being shorter than the width of the collar and just large enough to admit a suitably formed spring-wire. The spring is shaped by bending the end at a right angle to enter the tube and cross the labial surface of an adjoining tooth, where it is bent back on itself to extend in a labial curve and rest on the adjoining teeth on the opposite side. Force is applied by bending outward the shorter arm of the spring and pressing it into the tube on the collar, usually from above downward. The spring is arranged so that when the tooth is moved outward sufficiently the longer arm of the spring rests over the end of the tube, preventing its accidental displacement. The utility of this device is apparent; it is applicable also for moving other teeth, and for retaining.

Fig. 145.

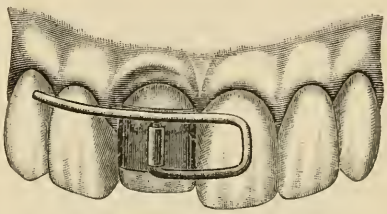

Fig. 146.

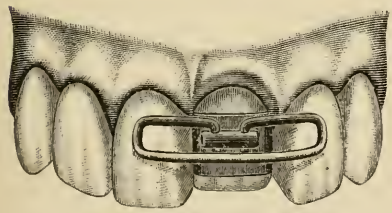

Fig. 146 illustrates a double arm spring device for moving outward an incisor. To the tooth to be moved is cemented a broad collar with a long tube attached horizontally across the front. Two holes are drilled through the sides of the tube, one near either end, parallel with the face of the collar. A small spring-wire is shaped to cross the labial side of the adjoining teeth, curved back upon itself,

with the ends bent at a right angle to enter the openings made in the tube. The lower portion of the spring should be made to pass close underneath the tube in order to hold it in place after regulation. Force is applied by bending forward the arms of the spring and pressing them backward to enter the holes in the tube. To support this style of spring, when it is desired, two short tubes can be soldered perpendicularly to the labial surface of the collar, in place of the horizontal tube, one near the mesial and the other near the distal side. When the tooth to be moved is twisted, for its correction, more force can be exerted on one of the arms.

When a tooth is to be moved but a short distance, a spring can sometimes be soldered directly to the collar, the ends being bent backward sufficiently to give the necessary force.

Fig. 147 shows a looped spring device for increasing space and moving outward an incisor. It was used to advantage for correcting

Fig. 147.

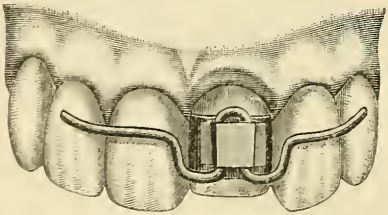

Fig. 148.

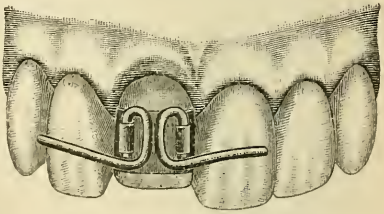

the position of an extreme instanding upper central for Master S., aged ten years.

To the tooth is cemented a broad collar with a narrow strip of plate-metal soldered to the labial surface, forming a box-shaped opening, as already described for moving outward a lower incisor. The opening should be a little broader at the top. Into it is fitted a small spring-wire, bent into the form of a loop. Just below the loop the ends are curved upward and at a right angle to rest on the labial faces of the adjoining teeth. The spring is held in place by separating a little the sides of the loop. Force for moving the tooth is procured by bending backward the arms of the spring before adjusting.

Sometimes the ends of the spring can be bent farther upward to advantage, but they should not rest higher than a line with the edge of the gum on the tooth being moved.

In Fig. 148 is shown a device with two independent springs for

moving outward an upper incisor, made as described in moving outward a lower incisor. A broad collar is cemented to the tooth with two perpendicular tubes a little shorter than the width of the collar soldered to the labial surface, one located near the mesial and the other near the distal side. The springs are formed into U-shaped loops as broad as the length of the tube, with one arm shorter than the other. Near the curved portion of the loop the short arm is bent at a right angle to enter the tube, usually from above downward. The end of the loop rests on the collar near the median line, with the long arm extending across the adjoining tooth. Force with the springs is produced by bending forward the short arms a little at a time and springing them back into the tubes.

A device for moving outward two incisors is shown in Fig. 149. A collar with a tube soldered horizontally or perpendicularly to the

Fig. 149.

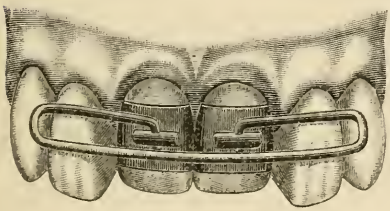

Fig. 150.

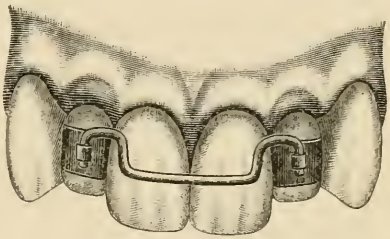

labial side is cemented to each. A medium-sized spring is shaped to the desired labial curve of the arch, extending across two of the teeth either side of those to be moved, and curved back on itself, running parallel with the ends bent at a right angle to enter holes in the tubes. The long portion of the spring can be stiffened if required by soldering to it, underneath, a wire or a narrow strip of thin plate-metal.

For moving two lateral incisors, when there is sufficient space and the centrals are in good position, a device as shown in Fig. 150 is sometimes efficient. A thin broad collar with an eyelet or short tube attached on the labial surface is cemented to each. A small spring is shaped to cross the labial side of the centrals. Near the distal surface of each the spring is curved upward a little into a loop with the free ends projecting downward to enter the eyelets or tubes described.

Force is applied by bending the ends of the loops forward and pressing them back into the eyelets.

For moving upper central and lateral incisors outward, an appliance is made by arranging spring-clasp attachments for anchorage over a molar or bicuspid on each side, with partial-clasps on the adjoining teeth, and forming a palatine base-wire, about No. 13 gauge, to cross the arch, with the ends bent nearly at a right angle to cross the partial-clasps (Fig. 151).* Usually a collar with a large lug on the palatal side should be cemented to each of the teeth to be moved outward. A spring-wire, about No. 18 gauge, is formed in a gentle curve to rest on the lingual side of the incisors passing underneath the lugs. A loop about one-half inch long is formed in the wire on each side opposite the first bicuspids, pointing towards the median line, and contoured to rest near the soft tissues, its ends extending across the partial-clasps, to which they are soldered in the anchorage portion. Force for moving the incisors is obtained by opening the loops in the spring-wire a little with round-nosed pliers or other instrument once in four or five days.

Fig. 151.

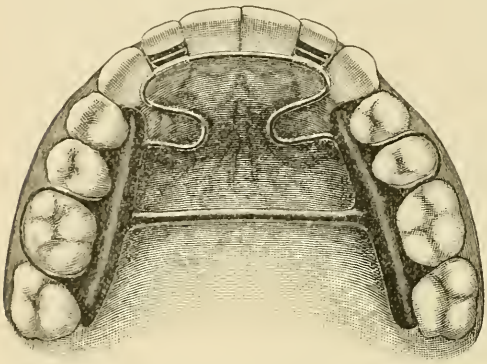

The base-wire can be made to follow the lingual curve of the arch, using a finger-spring, but it is more liable to interfere with pronunciation.

Moving outward an incisor in some difficult conditions of the occlusion of the teeth is accomplished by the device shown in Fig. 152. A spring base-wire is formed loosely to the labio-buccal side of the teeth, and following the gum line back on either side to a bicuspid or molar, to which it is anchored.

Fig. 152.

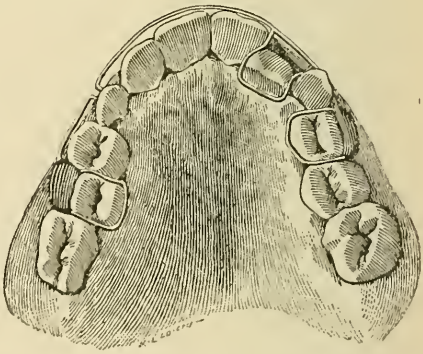

* Jackson, Transactions Columbian Dental Congress, vol. ii. p. 675.

It will be observed that if the teeth are crowded the arrangement of the base-wire passing on the labial side of the teeth would not permit them to separate sufficiently to allow the incisors to be moved into place. This difficulty is obviated by making a loop in the base-wire near one of the spring-clasp attachments, which can be opened sufficiently from time to time to enlarge the circle of the arch as desired. A small wire, about No. 20 gauge, is bent into the form of a spring-clasp for moving the incisor, crossing the lingual surface, the ends extending either side over the arch at the junction of the teeth, near the incisive edge, and soldered to the base-wire. The arms of the spring can be bent outward for broadening the space for the movement of the tooth, and the part that crosses the lingual side bent nearer the base-wire from time to time for forcing the tooth into position.

In some instances it is an advantage to have the spring reversed, with the free ends resting on the lingual side of the incisor and the part between the parallel arms united to the base-wire. In this case the parallel arms of the spring can be utilized for increasing the space as before, and the ends bent towards the base-wire for causing the outward movement of the tooth. If the spring is not well retained on the incisor, a thin collar with a small lug on the palatal side can be cemented to it.

Fig. 153.

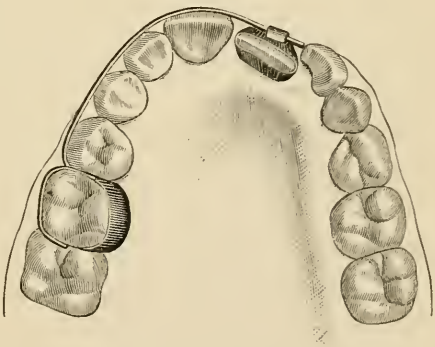

In Fig. 153 it will be seen that the right upper incisor is too prominent, and the left incisor not prominent enough and partially rotated.

The irregularity was corrected by a spring-clasp attachment made to the second right deciduous molar for anchorage, and extending forward from this a spring-wire following the labial surface of the teeth near the gum line, crossing the right incisor, and extending into a tube soldered to a collar cemented to the left incisor. A hook attached to the collar can be used in place of the tube if desired. By removing the appliance and straightening the end of the spring slightly, pressure was exerted on the right incisor, forcing it inward, while at the same time,

acting as a lever, it drew forward sufficiently to move the left incisor outward to line and to rotate it. A similar appliance has been used with marked success for rotating teeth. (See Chapter XIV., Incisors, to rotate.)

Fig. 154 shows the shape of a spring that was used for moving outward both of the upper lateral incisors, which had erupted con-

Fig. 154.

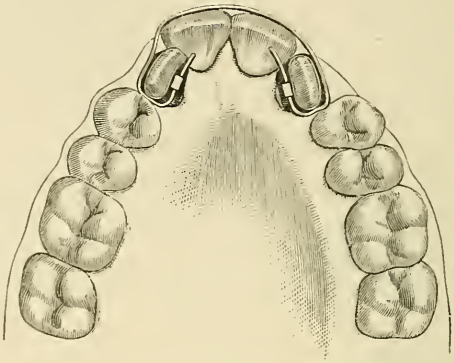

siderably inside of the circle of the arch, closing back of the lower teeth.

The spring was made to extend across the labial side of the incisors to the distal side of the laterals at the gum line. The ends were formed into loops to pass over the arch at the junction with the adjoining teeth to the lingual side, and bent again at a right angle to cross the lingual side of the laterals. If the central incisors are rotated, and their position needs correcting, the spring should extend on to the linguo-distal side of them. It is usually to be retained by cementing a collar with a lug on the lingual side on each of the lateral incisors. It will be seen that by removing the spring, straightening the main portion slightly, and replacing it, it will exert a pressure outward on the lateral incisors and a corresponding drawing inward on the mesial side of the centrals.

This style of appliance can be used for rotating the central incisors alone in the same manner.

In this case the cuspids had erupted in front of the lateral incisors. Their position being such as not to warrant their being moved to the position of the first bicuspids, they were extracted.

When one or two incisors are erupted posterior to the natural position in the line of the arch, with, as is often the case, the first

deciduous molars decayed or missing, causing a space, an appliance like Fig. 155 will sometimes be sufficient to correct the irregularity. It is made of spring-wire about No. 17 gauge. A loop is first formed to pass through the space, with one end following the lingual and the other the labial curve of the arch, extending to or a little beyond

Fig. 155.

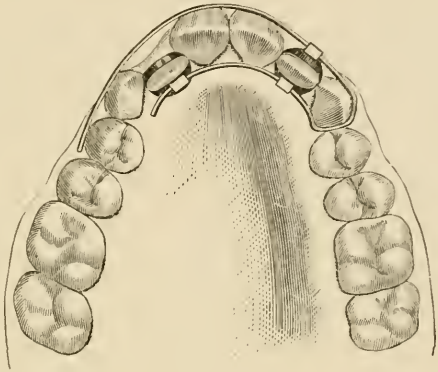

the teeth to be moved. The spring on the labial side is usually a little longer than the one on the lingual. The appliance is retained by placing a collar with a lug in suitable position on one or more teeth.

If the power of the spring is found to be insufficient, a wire of a larger size can be substituted, or a silk ligature may be passed between the teeth, looped around each wire near its end and tied to draw the springs together for causing additional pressure. If the permanent teeth are erupted, and there is no space for the looped part of the wire to pass from the labial to the lingual side, the appliance described can be made efficient by bending the end of the loop at a right angle with the springs, and shaping it to lie over the arch at the junction of two of the teeth. This is accomplished by placing the end of the loop in flat-nosed pliers or a vise, and bending at once to the required angle; being careful to have the loop so shaped as not to interfere with the closing of the teeth, and retaining the spring with collars and lugs on the teeth as previously described.

This method is only thoroughly applicable in a few cases, and for this reason I refer the reader to some of the following methods. The principle is utilized in the case next described.

Fig. 156 shows a device used for the correction of crowded incisors; some of them being too prominent, others needing to be moved outward and rotated. It is made by first bending a spring-wire into the form of a loop to pass on the labial and lingual faces of the irregular incisors at the gum line, the end of the loop being bent upward to pass over the arch at the junction of the lateral with the cuspid. A lingual spring base-wire is shaped to the inner curve of the arch, provided with a U-shaped loop or with corrugations opposite the bicuspids on either side, and the ends anchored with spring-clasp attachments over the first molars. The lingual arm of the looped spring is attached to the base-wire by winding about them a narrow strip of metal at the median line and uniting them with solder. A collar with a lug on the lingual side should be cemented to one or more of the incisors to assist in retaining the appliance. The loops in the base-wire are opened from time to time with round-nosed pliers, to give pressure for moving the irregular teeth outward until there is sufficient space in the circle for all of them, in corrected positions. As the incisors are being moved, the anterior arm of the looped spring is bent to assume a position nearer to the base-wire, thus exerting pressure on the labial and lingual sides of the teeth, moving them laterally into the curve prescribed by the form of the spring. The appliance is made more substantial by the addition of a palatine base-wire.

Fig. 156.

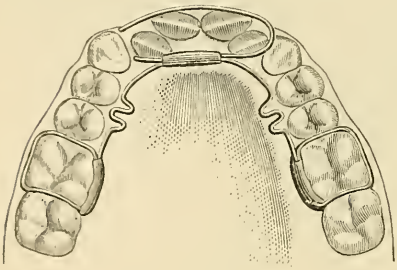

The practicability of using a simple spring-wire to correct an irregularity independent of spring-clasp attachments, collars, etc., for anchorage, was demonstrated many years since.*

Fig. 157.

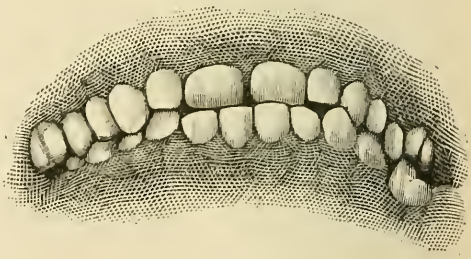

Fig. 157 shows the teeth of a girl eight years of age, with the upper

* Jackson, International Dental Journal, 1890, p. 202.

central incisors erupted inside of the circle of the lower ones. For their correction, a collar with a good-sized lug on the lingual side was cemented to each of the central incisors.

A semicircular spring-wire was shaped to the lingual contour of the arch, with a loop on either side terminating in the form of the letter S, and the end made to project into a hole drilled in a filling that had been inserted in each of the second deciduous molars (Fig. 158). The force was controlled by slightly opening the loops in the ends of the spring. It required but six changes to complete the regulating.

Fig. 158.

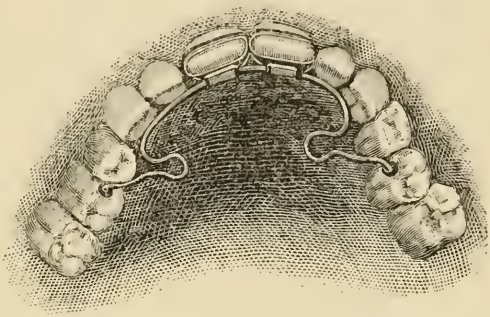

A spring-clasp attachment for anchorage is so easily made and retained on the second deciduous molars that its use is recommended in all cases, even though the teeth be badly decayed and are becoming loose.

The importance of the early treatment of instanding upper incisors is clearly shown in this case. If they are not moved outward early, they induce an unnatural prominence or prognathous condition of the lower jaw.

Fig. 159 is interesting as illustrating the imprudence of a too early extraction of the deciduous teeth. The patient was a boy nine years of age. When he came under treatment both of the second deciduous molars in the upper arch had long been removed, and the first permanent or sixth-year molars had moved forward, occupying much of the space that should have been reserved for the second bicuspids. Thus, owing to the lack of lateral support in the arch, caused by the loss of the deciduous molars, when the permanent incisors erupted they took a position back of the

Fig. 159.

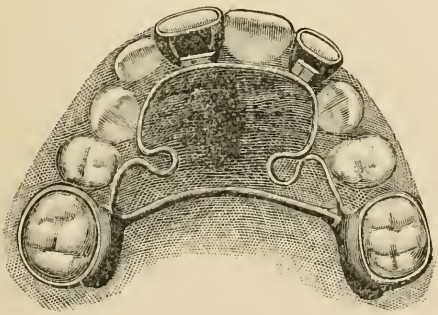

lower ones. They were broader than the deciduous incisors, and caused the adjoining teeth to move backward in the circle of the arch, which, with the forward movement of the molars, nearly closed the space between them and the first bicuspids which were erupted. These abnormal changes, entirely due to the early loss of the deciduous molars, made it quite impossible for the second bicuspids to erupt in their natural position in the circle of the arch, or for the upper incisors to gain their proper place in front of the lower ones without mechanical interference.

To move the incisors outward to a normal position, and to remedy the impacted state of the second bicuspids, an appliance was made by forming a spring-clasp attachment for anchorage over each of the first permanent molars, connected with a palatine base-wire. A collar with a lug on the lingual side was cemented to one of the central and one of the lateral incisors, for the purpose of retaining a semicircular spring-wire. The spring was bent to follow the lingual curve of the teeth, passing underneath the lugs, and formed into a U-shaped loop either side, about three-eighths of an inch long, pointing towards the median line, and resting near the gum opposite the first bicuspids, the ends of the spring crossing the partial-clasps, to which they were soldered with the base-wire. By slightly opening the loops in the spring once in three or four days, pressure was brought to bear that moved the incisors outward; while also the molars used for anchorage gradually yielded and moved backward, thus making room for the eruption of the second bicuspids.

This case illustrates the necessity of preserving the deciduous molars until about the time of the eruption of the bicuspids. When deciduous molars have been removed the case should be examined from time to time, and if the spaces for the bicuspids are being closed by the backward movement of the teeth in front of them, and by the forward movement of the first permanent molars, an apparatus should be inserted to move them to a correct position and to retain them until the eruption of the bicuspids.

Fig. 160 shows the appliance used for moving outward an upper central and lateral incisor that were closing back of the lower ones, with the cuspid erupting somewhat in front of the lateral. The patient was a boy aged eleven years. A spring-clasp attachment for anchoring the appliance was formed to clasp the left upper molar on one side and the bicuspid on the other; it was connected with a

palatine base-wire, having one end bent backward and the other forward to cross the partial-clasps. A spring-wire was then formed to the lingual curve of the incisors, crossing the ones to be moved, and a U-shaped loop made in either side, pointing towards the median line, its ends extending backward to cross the partial-clasps, to be united with solder to them and to the base-wire. To retain the spring a collar with a lug on the lingual side was cemented to the central incisor to be moved. A collar should also be cemented to the lateral. The regulating was completed in eleven visits.

Fig. 160.

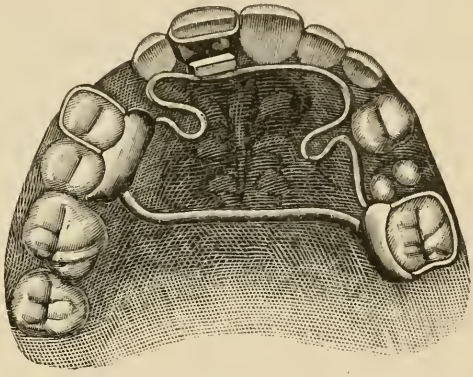

In some cases the spring made with a loop on each side of the arch acts more certainly than with the finger-spring, and the force is easily controlled by bending with round-nosed pliers; but the loop should be long to insure springiness.

Usually upper incisors that have a lingual occlusion and have been moved labially, when fully erupted are retained by their natural articulation. In this case, the incisors being shorter than usual, they did not close well over the lower teeth. The erupting cuspid was prominent, and therefore tended to wedge the lateral incisor inward towards its original position. To retain the lateral a platina-gold collar was fitted to it with a spur of thin, flat metal soldered to the lingual side, projecting a little below the incisive edge of the tooth in order to lengthen it and make it close in front of the lower incisors (Fig. 505).

Fig. 161.

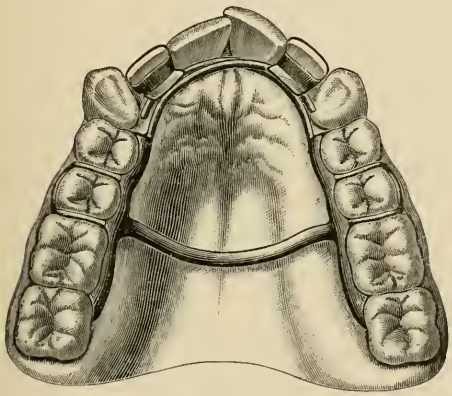

In Fig. 161 a convenient appliance is shown for moving outward the upper incisors. A spring-clasp attachment is formed over one of

the molars or bicuspids on either side of the arch, with partial-clasps on the adjoining teeth for anchorage, and connected with a palatine base-wire. To the partial-clasps on each side is soldered a long semicircular finger-spring, shaped to project forward following the lingual curve crossing the teeth to be moved; it terminated on the opposite side of the arch, the springs resting parallel one with the other. A collar with a rather broad lug on the lingual side is cemented to two or more of the teeth to be moved to retain the ends of the springs. Force is applied by bending the springs outward a little as required.

Sometimes in cases where there is a close articulation, the lower incisors biting against the gum back of the upper ones, it is difficult to arrange a device inside of the arch for moving outward an upper incisor without interfering with the occlusion. In such a case an appliance made as shown in Fig. 162 can be utilized. A palatine

Fig. 162.

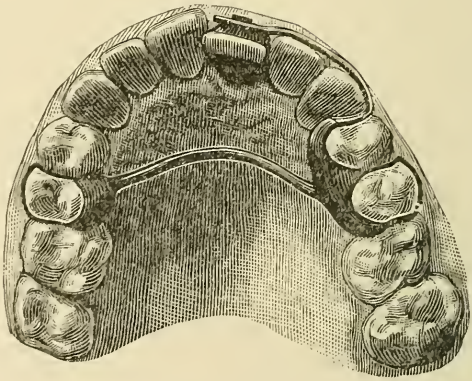

base-wire, about No. 13 gauge, is anchored with a spring-clasp attachment to a molar or bicuspid on either side. To the base-wire or partial-clasp is attached a spring-wire, No. 18 gauge, shaped to pass over at the junction of two of the teeth to the buccal side, and bent forward following the labial curve of the teeth crossing the incisor to be moved. To the incisor is cemented a collar with a hook to engage with the spring. Force for moving the irregular tooth is caused by bending outward the end of the spring from time to time. If required, two springs can be made to extend forward in the same manner, one from either side.

Fig. 163 exemplifies a method used to force into line a right upper lateral incisor that was far inside of the circle of the arch, and at

Fig. 163.

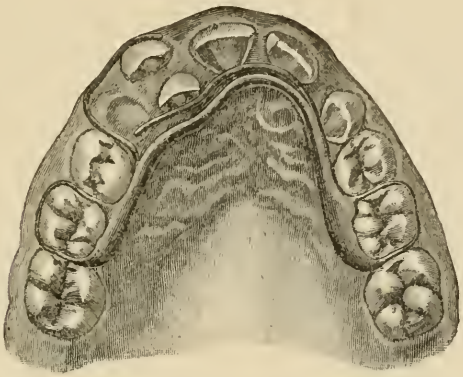

the same time to move backward a prominent cuspid that rested nearly in front of it, there being sufficient space for its correction. Partial-clasps and spring-clasp attachments were formed to the deciduous molars for anchorage and connected with a lingual base-wire.

A finger-spring for moving the lateral outward was then fastened in the anchorage portion on the left side and extended forward, passing underneath a lug on the lingual side of a collar cemented to the lateral. The cuspid was moved into position by a finger-spring attached in the anchorage portion on the right side. It extended over the arch just in front of the first deciduous molar and was bent

Fig. 164.

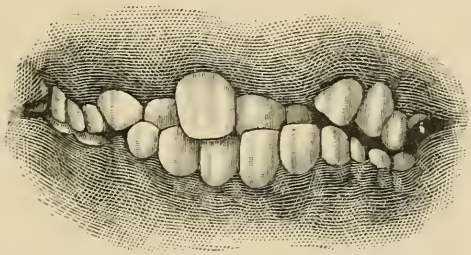

forward to clasp the labio-mesial surface of the cuspid. Force was applied by bending the springs slightly at a time. An appliance with a palatine base-wire and springs arranged in this manner is equally applicable.

A boy, thirteen years of age, was brought for treatment of the irregularity shown in Fig. 164. The left central and both lateral

incisors closed back of those of the lower arch. The patient was fitted with the appliance illustrated in Fig. 165. A lingual base-wire

Fig. 165.

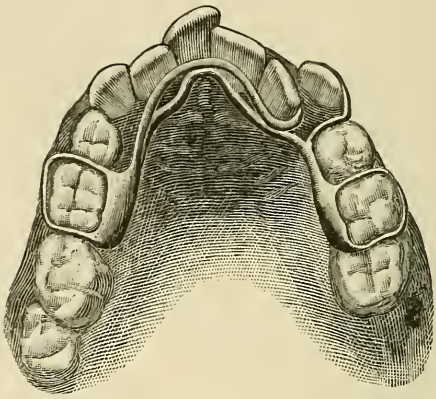

was shaped to follow the irregular line of the arch, with the ends anchored with spring-clasp attachments to the second deciduous molars and partial-clasps on the adjoining teeth. From the right anchorage a finger-spring was formed to extend forward, following the contour of the teeth, terminating on the distal side of the left lateral, the action of which was utilized for moving the incisors outward. Another spring, soldered to the base-wire on the left side, passed just in front of the first bicuspid and extended upward and forward, with the end resting on the mesio-labial surface of the cuspid near the gum line. The effect of this spring was to draw the cuspid backward towards the bicuspid and to assist in making

Fig. 166.

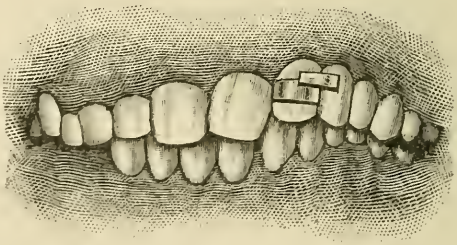

room for the incisors in a normal line. No collars were necessary on the laterals or cuspid for retaining the appliance.

It will be observed that as the left central and lateral were moved outward they were not rotated sufficiently to take a normal position.

An appliance, as shown in Fig. 299, was used to rotate the lateral. It was retained by placing a gold collar around it with a spur extending to the labial side of the cuspid, as seen in Fig. 166, after which the central incisor was rotated and retained in a similar manner.

Fig. 167 illustrates the case of Master T., aged twelve years. The lower central incisors rested in front of the upper ones. The upper central incisors and the right lateral incisor closed in front of the lower lateral incisors, and the left lateral closed back of the lower lateral and cuspid. The second deciduous molars of the upper arch were still in position and were utilized for anchorage, although they were badly decayed and somewhat loosened from absorption. The cavities were filled with gutta-percha, and an appliance for correcting the irregularity of the upper arch was made as follows: A collar with a broad lug on the lingual side was cemented to the left lateral incisor. A spring-clasp attachment for anchorage was formed to each of the second deciduous molars and connected with a palatine base-wire. A small semicircular spring was shaped to pass under the lug and a U-shaped loop made in the wire on either side just in front of the anchorage portion, pointing towards the centre of the arch, with the ends soldered to the partial-clasps (Fig. 168).

Fig. 167.

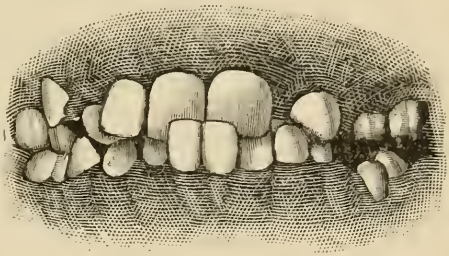

Fig. 168.

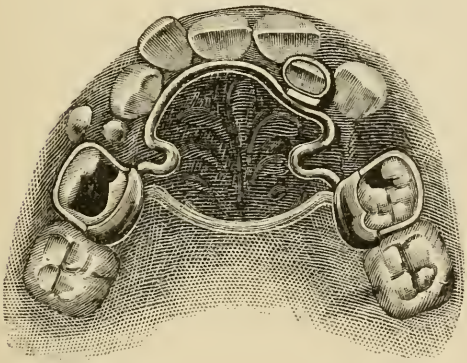

This is another illustration of the advantage of the spring-clasp attachment for anchorage. A deciduous molar that is beginning to become loose or badly decayed will often be a sufficient anchorage for completing the operation.

After the regulation of the upper incisors was begun an appliance, as seen in Fig. 134, was inserted to correct the position of the lower

incisors, the spring being retained with a collar on each of the laterals. Both appliances were worn at the same time. The action

Fig. 169.

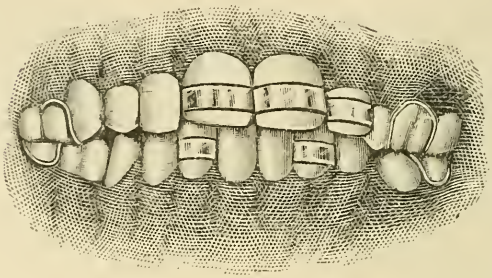

was controlled by opening the loops of the springs. Fig. 169 illustrates the completed case. The same appliances were used for retaining.

Fig. 170 shows the occlusion and position of the teeth of Master B., aged fourteen years. The left upper lateral incisor closed back

Fig. 170.

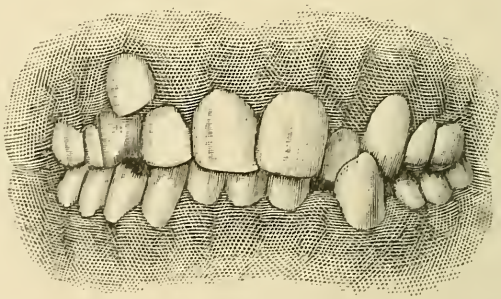

of the lower cuspid. The latter was considerably too prominent. The second left upper deciduous molar had injudiciously been removed early, and the permanent molar had tipped forward, causing impaction of the second bicuspid. There was insufficient space for the right upper cuspid, and it had assumed a position outside of the circle of the arch. The second right deciduous molar was still in position.

Fig. 171 illustrates a palatine view of the upper arch. It was determined to extract the second deciduous molar, it being a little broader than the erupting second bicuspid, and to move the first

bicuspid backward to provide space for the prominent cuspid. An appliance was constructed as seen in Fig. 172. A lingual base-wire,

Fig. 171.

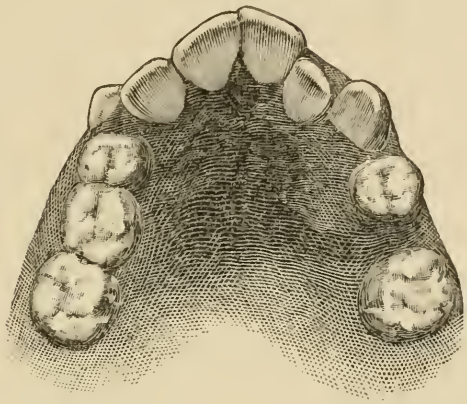

No. 14 gauge, was formed to the inner curve of the arch near the necks of the teeth and anchored with spring-clasp attachments to the

Fig. 172.

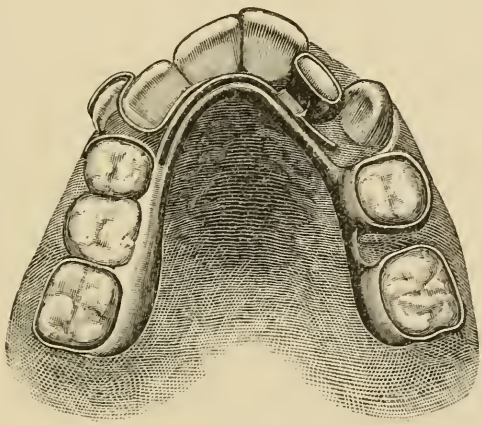

first permanent molars and the first left bicuspid. A curved spring was attached to the base-wire to pass in front of the right bicuspid for moving it backward. For further increasing the space and drawing the cuspid into line a double curved spring, No. 19 gauge, was soldered to the base-wire back of the central incisors. It passed through the space just back of the lateral and curved forward in front of the cuspid, its end bent backward to terminate on the labial

surface. The instanding lateral incisor was moved outward by a long curved finger-spring, No. 19 gauge. It was attached to the base-wire on the right side and followed the lingual curve to the left side, where it crossed the lateral and was retained with a lug on a

Fig. 173.

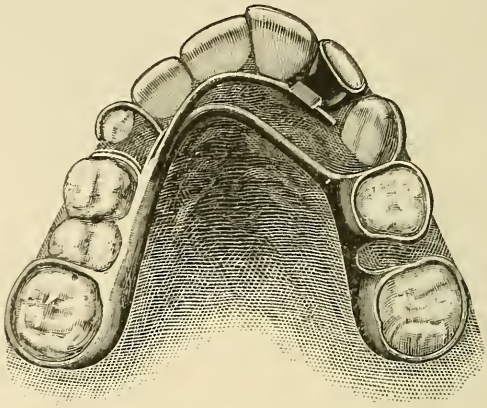

collar cemented to it. Another curved finger-spring was attached to the partial-clasp and base-wire on the left side, passing in front of the bicuspid, with the end shaped to rest on the labio-mesial surface of the cuspid to move it backward.

The appliance was inserted on April 5 and force applied with the springs. On July 25 the teeth had assumed the position seen in Fig. 173, the springs having been readjusted at intervals.

Fig. 174.

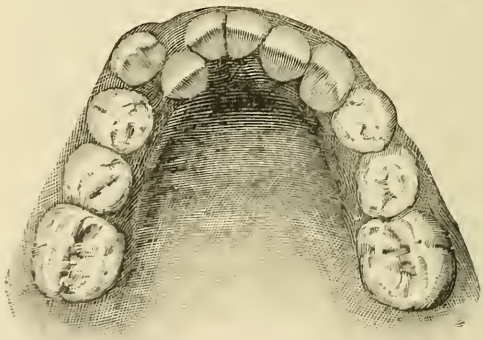

Fig. 174 illustrates the crowded condition of the teeth of the lower arch. The left lateral incisor stood considerably back of the

line of the left central incisor and cuspid. The latter was too prominent. For their correction, it was found advisable to extract the first left lower bicuspid and apply an apparatus as shown in Fig. 175. A lingual base-wire was formed to the inner curve of the arch and

Fig. 175.

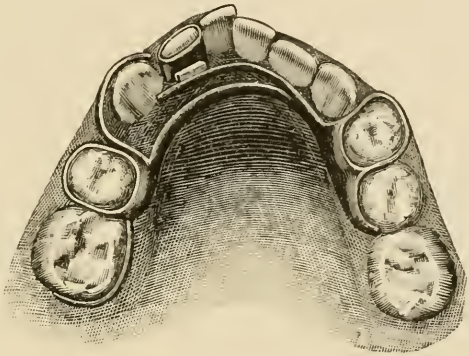

anchored to the second bicuspid and first molar on the left side, and to the bicuspids on the right. To provide space for the irregular lateral, the cuspid was first drawn backward by a curved finger-spring into the space caused by the removal of the bicuspid. It was attached to the base-wire next to the second bicuspid, and extended outward and forward to rest on the labio-mesial surface of the cuspid. The lateral incisor was moved outward by a finger-spring attached to the base-wire on the right side. It projected forward, following the lingual curve. The free end was retained by a lug on a collar cemented to the lateral.

Fig. 176.

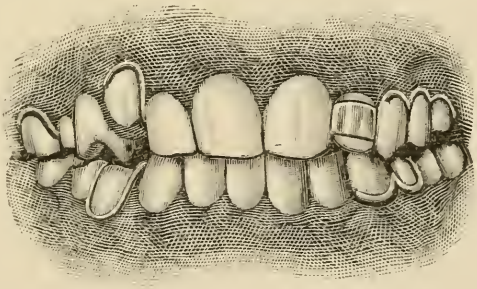

This appliance was inserted June 9, and the following July 25 the teeth had taken the position seen in Fig. 176.

The patient lived at some distance from the city, and owing to the inconvenience of travel only twelve visits were made up to this time. The mother was provided with a clasp-bender and instructed to make the necessary changes between visits. The second left upper bicuspid finally made its appearance, pointing into the palatine arch, there still being insufficient space for it to take a correct position. An appliance as seen in Fig. 177 was inserted for increasing the space and moving the bicuspid into line. A palatine base-wire was used, anchored with spring-clasp attachments on the first molar on the left side and the second bicuspid on the right. A spring-wire was made to follow the curve of the arch near the necks of the teeth; opposite the bicuspid to be moved it was bent into a U-shaped loop pointing towards the median line of the arch, its ends soldered in the anchorage portion with the ends of the base-wire. To the spring in front of the U-shaped loop on the left side was attached a secondary spring, which projected backward and outward to clasp the distal side of the first bicuspid, and a finger-spring extending forward from the partial-clasp to the lingual side of the bicuspid to be moved. The space was broadened by removing the appliance from time to time, and opening the loop by bending; bending outward also the finger-spring, which applied force to the bicuspid for moving it in a buccal direction. Two additional visits were required for the movement of the bicuspid and to complete the regulating.

Fig. 177.

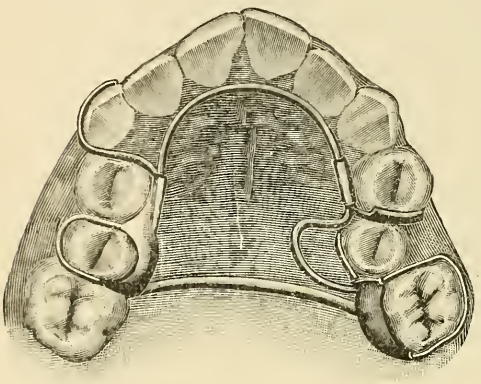

This case is interesting, as its correction included so many different movements.

Mrs. E. was referred to me in November, 1893, for advice regarding her teeth.* The following history was noted: Age, thirty-eight years. Lower jaw prognathous, the lower incisors closing in front of the upper ones, the other teeth articulating in nearly

* Jackson, Dental Cosmos, 1894, p. 900.

a normal position. Five teeth had been extracted, all of them molars.

In the upper arch there remained four molars, two on each side, and three in the lower arch, two on one side, and one on the other. The crowns of the first and second left upper bicuspids had been removed, and porcelain ones substituted. The crown of the first right upper bicuspid had also been removed, and an all-gold crown was in its place. The gum about the lower incisors had receded, and was diseased. The right lower central incisor was somewhat loose, and was moved outward by the upper incisors in occlusion. The labial faces of the upper incisors were considerably worn by the lower incisors, and appeared stubby. The upper lip was sunken, and the facial line was not good. Year by year the patient observed that the lower incisors were closing higher in front of the upper ones. An unsuccessful attempt to correct the irregularity had been made when the patient was about twenty-eight years of age.

With the assistance of the models (Fig. 178), it was determined that without interference the lower incisors would gradually be forced to take a more prominent position, and one or more of them would soon be so loose as to necessitate their removal. The lower jaw, meanwhile, would become more prominent, the upper lip more sunken, and the upper incisors more worn. On the other hand, several important advantages would be gained by correcting the irregularity. The wear on the labial faces of the upper incisors would be stopped. The corrected articulation would assist mastication, their use would improve the nutrition of the tissues about the loosened teeth, and the lower incisors would have more support by being pressed back into the arch, rather than outward as before. The profile would be improved by removing the sunken appearance of the upper lip, and the prominence of the lower jaw would be lessened.

Fig. 178.

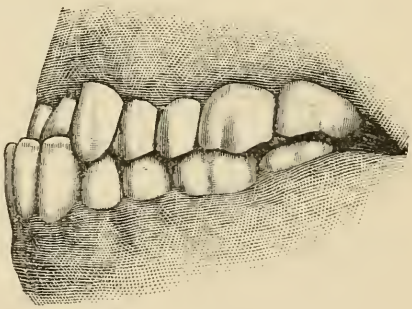

After carefully considering the many points involved, including the age, tendency to pyorrhœa, and the conditions enumerated, it

was recommended that the diseased gum and process be treated, and that the upper incisors be moved outward to close in front of the lower ones.

An appliance was made of German silver spring-wire, anchored with spring-clasp attachments to a tooth on either side of the arch (Fig. 179). The anchorage on the left side was to the first molar and on the right to the second bicuspid with a partial-clasp on the first molar. It will be observed that with this arrangement the anchorage did not come in contact with or interfere with the artificial bicuspid crowns.

Fig. 179.

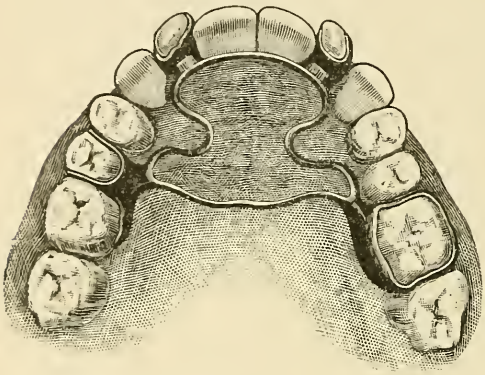

A palatine base-wire, No. 14 gauge, was bent to follow the contour of the arch from side to side, crossing at about the line of the mesial surface of the second bicuspids. One end of the base-wire was bent backward nearly to a right angle, and the other bent forward to rest on the partial-clasps described. A spring-wire, No. 19 gauge, was formed in a slight curve to rest on the lingual side of the incisors, reaching from the cuspid on one side of the arch to the cuspid on the other. The ends of the wire were then bent with a small-sized clasp-bender backward and again forward, forming U-shaped loops about three-eighths of an inch long, one on each side, opposite the first bicuspids. The loops were made to point towards the median line of the arch, the free ends of the spring extending backward to cross the partial-clasps with the ends of the base-wire. The different parts were then united to the partial-clasps with soft solder, laying a piece of solder on each of them large enough to do all the soldering at once, using muriate of zinc as a flux, and melting with a hot soldering iron. The parts were then smoothed with a carborundum stone and polished the same as a metal plate.

In this case, as in others previously described, the appliance was not arranged to open the bite to permit the instanding teeth to be moved outward. It is not necessary in some cases.

A platina-gold collar, No. 35 gauge, with a lug of plate-metal

soldered to the lingual side and resting near the gum, was cemented to each of the lateral incisors to retain the spring of the appliance, and when the regulating was about one-half completed a similar collar was cemented to one of the central incisors.

The action of the appliance was controlled by opening the loops in the spring-wire. The regulating was begun December 1, 1893, and after twenty-eight days the upper incisors had been moved outward to close in a normal position in front of the lower incisors, as seen in Fig. 180. The appliance, without change, was kept in position to retain the teeth until January 18, 1894, when it was removed.

Fig. 180.

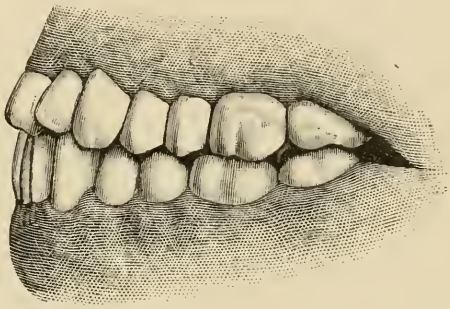

It will be remembered that the lower incisors were loose from pyorrhœa alveolaris, one of them especially so. After removing the appliance the upper incisors pressed inward on the lower incisors, causing them to crimp; that is, some of them took a position slightly in advance of others. This tendency was avoided by grooving longitudinally the approximal surfaces of the loose incisor and rounding the sides of the two adjoining teeth to fit into the grooves, and flattening slightly the approximal surfaces of some of the other incisors. By this arrangement both the upper and lower incisors were retained in position.

Fig. 181.

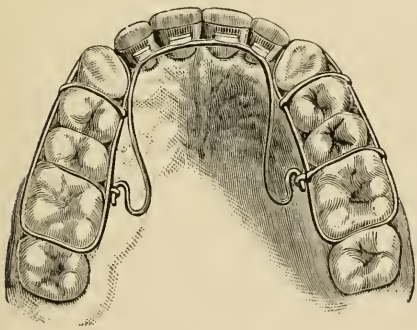

At this writing the upper incisors are firm. One of the lower incisors is supported with a retaining device.

Fig. 181 shows the form of an appliance that was used successfully several years since to correct an irregularity for a lady thirty-six years of age.* The upper incisors had a lingual occlusion. One lateral incisor, bicuspid, and

* Jackson, Dental Cosmos, 1890, p. 877.

three molars of the upper arch were missing, some of them having been extracted years before in the hope of correcting the irregularity, but the teeth had crowded together and the articulation become so changed as to give an unpleasant expression to the features. Besides this, the labial faces of the upper incisors were becoming worn. The difficulty that is experienced of moving nearly all of the oral teeth in one direction was very marked in this case.

An appliance was made with a continuous spring-clasp for each side of the arch to encircle the teeth back of the incisors; a slight separation was made by wedging in front of the cuspids and a round iridio-platinum wire flattened to pass into the space on either side, extending backward and following the line of the gum surrounding the cuspid, bicuspids, and first molar. This was supported and made to clasp the teeth firmly by connecting the two sides of the spring-clasps with wire bars passing over the articulating surface at the junction of the teeth. These served also to keep the appliance from pressing on the gum. A loop or eyelet was soldered to the spring-clasp opposite the lingual surface of the first molar on each side of the arch, and into these loops were hooked the ends of a piano-wire spring. The spring was semicircular in form and passed just back of the incisors, with the ends shaped like the letter S. On the incisors were placed gold collars with lugs soldered to their lingual surfaces, in order to hold that portion of the spring in position.

The figure shows the appliance in place on four incisors in another completed case of the same character. Force was exerted as needed by straightening the S-formed loops of the spring a little at a time. The incisors were moved rapidly outward. When sufficiently so the portion of the spring-clasp in front of each of the cuspids was removed and a piece of piano-wire soldered to the original spring-wire and extended to the distal side of the cuspids, by the application of which they were moved forward.

Another spring was then attached to the original one; the front part of the spring-clasp was cut away as before to move the bicuspids forward, and at the same time one of the cuspids was rotated by placing on it a collar with a tube soldered to its lingual surface to hold the end of a spring which extended to the opposite side of the arch and hooked into the loop in the spring-clasp.

The regulating was done in 1888, since which time the teeth have been examined semiannually, and are remaining in good position.

Inclined Plane.—The inclined plane for moving the teeth is numbered among the earlier methods of regulating. It was described by Catalan in 1814,* since which time it has been in general use, being modified and improved from time to time to meet the conditions.

Catalan recommended it principally for moving outward instanding teeth in the upper arch, fixing it to the teeth of the lower arch. The appliance was made by shaping a long narrow band of plate-metal, either gold or silver, to cross the labial side of the lower teeth, its ends extending back usually to the buccal side of the first molars, where short pieces of plate were soldered to the band and bent sharply to extend onto the grinding surface to prevent it from slipping towards the gum. Similar pieces of metal were soldered to the front of the band, extending upward and backward at an obtuse angle for forming an inclined plane, passing behind the incisive edge of each instanding upper tooth. As many pieces of metal were used as there were teeth to be moved. These formed smooth planes, descending downward and forward over the lower incisors in such a manner as to cause the upper ones to slide forward when pressure was caused on them in occlusion. The inner ends of these pieces of metal were sustained by leaving them long enough to be bent sharply downward and shaped to rest on the lingual side of the incisors. The band was fixed to the teeth with ligatures.

A popular and effective form of inclined plane was described a few years later, and it is still recommended, the anchorage being more complete. It is made by first striking up, with accurate dies, a metal cap, usually passing over all of the teeth in front of the second molars. When, however, the shapes of the teeth are favorable it may cover a less number. The inclined plane is made by bending a narrow strip of plate-metal into a V-shape, attaching it to the cap so that the instanding tooth will strike in front of the elevation in occlusion. There is generally a considerable pressure on the appliance, and the latter form, covering both sides of the teeth, is held more securely, and is less liable to move out of position.

In most instances the appliance can be removed by the patient, but it can be fixed to the teeth by passing ligatures between them and through holes on either side. After the introduction of rubber

* Fox and Harris, 1846, p. 100; Catalan, Journal Général de Médecine, de Chirurgie et de Pharmacie, January, 1814.

vulcanite, owing to its ease of manipulation and the close adaptation secured, it was extensively used for making inclined planes. In some cases, however, the rubber has proved too soft for the incline, becoming ineffective on account of the wear. When rubber is used the incline may be covered with plate-metal.

Devices for anchoring the inclined plane may be classed as the *removable* and the *fixed*. The first can be removed by the patient for cleansing. The fixed include those that are cemented to the teeth or kept in place by ligatures or otherwise. A form of fixed inclined plane that has been recommended in recent years for moving outward upper incisors is made by fitting a half-round wire to the labial side of the front teeth, with the ends encircling a bicuspid on either side in the form of a clasp (in cases where there is a space back of them), and soldering to the wire in the front part a piece of plate-metal, shaped to project upward and backward over the lower incisors. This forms a proper incline for moving the upper incisors outward. The inner end of this part of the metal should be bent downward upon itself and shaped to extend onto the lingual side of the lower incisors and the two parts soldered to form a saddle. It is desirable to have the saddle of the appliance rest on several teeth.

Dr. Guilford has described a form of fixed inclined plane that he devised for moving inward a prominent lower tooth, and at the same time moving outward an instanding upper one (Fig. 182).* A collar is first made of thin platinum-plate to encircle the lower incisor. A piece of gold-plate is then bent into a V-shape and attached to the collar in position to extend backward, forming an incline, with one arm of the metal resting on the labial side of the collar and the other on the lingual, to which they are strongly soldered. The device is cemented in position on the tooth with zinc phosphate, having the cement fill all of the space under the incline to strengthen it. When it is not intended to move the lower incisor, the doctor recommends that the appliance be made to include two or more teeth to increase the resistance.

Fig. 182.

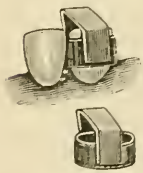

Fixed Plane. (Guilford.)

Several years since I devised an inclined plane of the form shown

* Guilford, Orthodontia, 1898, p. 118.

in Fig. 183. It is strongly retained, and can be removed by the operator or the patient for cleansing when desired. For moving outward an upper incisor a lingual base-wire is formed to the inner curve of the lower arch, its ends anchored by spring-clasp attachments to a second deciduous molar, or to one of the bicuspids or permanent molars on either side. A piece of plate-metal, usually about the width of three of the teeth, is fitted above the base-wire, extending from it to the incisive edge like a continuous partial-clasp, being located opposite the tooth to be moved. The incline is made with a heavy strip of plate-metal of the width and length required. It should be fitted close to the labial side of the teeth, with the part that projects above the incisive edge bent backward to the angle desired for the incline and attached with solder to the partial-clasp, at the same time attaching the partial-clasp to the base-wire, filling all the space under the incline with solder. With this construction the metal fits closely to the labial and lingual sides of the incisors, assisting the anchorage. The incline can readily be changed by dressing it away or by soldering to it plate-metal of a different form.

Fig. 183.

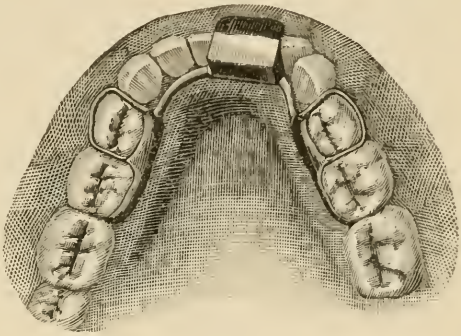

Some of the objections that have been made to the use of the inclined plane are the tenderness that is often engendered by the persistent effort in closing the teeth, sometimes causing severe inflammation; depression of the tooth in the socket; the lack of cleanliness when the appliance that covers the teeth is held with ligatures; and the non-occlusion of other teeth than those being operated on, permitting them to elongate when the apparatus is continued for any length of time.

There is no question but that the inclined plane for moving the teeth is superseded by better methods, although the application of the principle may be made serviceable in many combinations. (See Fig. 438.) The appliance was constructed for moving into line prominent cuspids, and moving outward lateral incisors that close considerably inside of the line and are interlocked by the centrals.

A base-wire was formed to the inner circle of the teeth, with the ends anchored to a molar on either side. The anchorage was strengthened by forming pieces of plate-metal to cover the lingual side of the lateral incisors, extending to the incisive edge, the ends being soldered to the base-wire near the gum. This arrangement gives the base-wire a very strong anchorage. The inner edges of the metals were curved somewhat over the mesial surface of the lateral incisors, to prevent them from being moved farther inward and mesially by the cuspids when pressure was caused on the labial side of them by the springs provided for correcting their position. After the prominent cuspids were moved nearly to place by the springs, the ends of the metals resting on the lateral incisors were bent forward, forming inclines, which acted like inclined planes for pressing the lateral incisors outward, and at the same time the inner edges of the metals were curved more in order to move them distally.

In Fig. 432 is illustrated a similar appliance constructed with inclined planes for moving outward instanding lateral incisors in a lower jaw, the inclines first serving to assist the anchorage for moving a prominent cuspid into line. It will readily be seen that the attachment of metal to a base-wire in this manner can be utilized in many cases for anchorage, and later serve as inclines for moving teeth outward, inward, or laterally, as may be desired.

When there is an inharmonious development of the jaws, with derangement of the normal occlusion, as when the cusps of the teeth of the lower jaw close considerably back of the proper line, the lower jaw can sometimes be held forward until the tissues adjust themselves by attaching a strong inclined plane to a heavy contoured gold collar or a crown, cemented to an upper molar on each side of the arch. When necessary an additional collar may be attached to include an adjoining tooth, according to the estimated pressure to be caused upon them. The incline should be made similar to the appliance described by Dr. Guilford, being rather sharp and projecting downward to close back of the last erupted lower molar, in order to hold the jaw forward and prevent the improper occlusion (Fig. 405).

If the lower molars are not sufficiently erupted to engage with the inclined planes, a plate covering the palatine arch, with a heavy metal or vulcanite incline attached to its anterior portion to project downward back of the lower incisors when in normal occlusion, will be

effective in most cases (Fig. 403). Or when a reverse condition exists, an appliance made as illustrated in Fig. 406 is sometimes applicable.

In the following case of instanding upper incisors and protrusion of the lower jaw an inclined plane proved very serviceable. Miss I.,

Fig. 184.

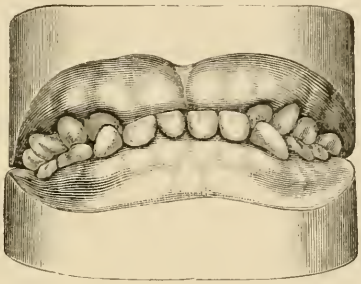

aged two years and ten months; prominent lower jaw, with the lower incisors and cuspids touching the gum in front of the upper incisors during occlusion (Fig. 184). I think this is the youngest case on record where an operation has been performed for the correction of a similar deformity.

Accurate impressions were taken as described on page 61. An inclined plane was made of two pieces of plate-metal (Fig. 185).

Fig. 185.

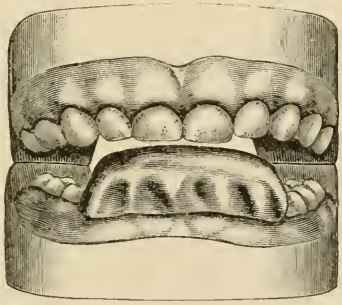

Wax was built onto the lingual side of a model of the lower incisors and cuspids, the upper surface of the wax being shaped to incline upward and backward from the incisive edge of these teeth to an extent and at an angle suitable for occlusion with the teeth of the upper arch. An impression with mouldine was then taken of the

labial side of the teeth and the upper surface of the wax. From this a metal die and counter-die was made, which was used to strike up a plate of gold to form the front part of the incline covering the labial side of the lower incisors and cuspids. The wax was then removed and the metal held in position on the model while another impression was taken with mouldine of the lingual side of the teeth and the projecting part of the inclined plane. From this impression another die and counter-die were made for striking up a plate to cover the lingual side of the teeth. These two pieces of metal were then waxed together and united with gold solder, forming a cap and inclined plane. There was a slight interdental space between the lower central incisors, and holes were made in each side of the cap part of the inclined plane near the edge corresponding with the space between the incisors, the holes being made on a line with the margin of the gum. A small copper wire was passed through the holes and the appliance cemented to the teeth with oxyphosphate. Before the cement had become hardened the wire ligature was drawn tight, the ends twisted and shaped so as not to irritate the lip.

Fig. 186.

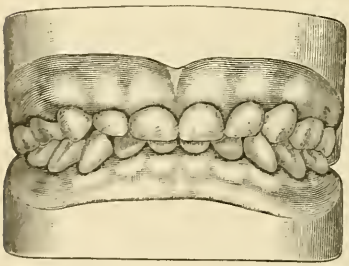

The device was applied February 10, and on May 7 it was removed, the teeth articulating, as seen in Fig. 186. No especial discomfort had been experienced by the patient and not a tear had been shed in the office. During the last seven years the teeth of the patient have been examined several times, and have been found in good position, with no undue prominence of the lower jaw.

Opening the Bite.—Of the cases of irregularity presented, only a small percentage require the appliance to be arranged to open the bite for their correction.

When the jaws are at rest the teeth are not in occlusion, the full occlusion of the teeth taking place only at the time of mastication of the food, during the act of swallowing, during extreme muscular or physical strain, while enduring pain, and at times during sleep when suffering from some nervous disorder. The opening of the bite in any manner with apparatus, if continued for a considerable time, is likely to prove detrimental to the occlusion.

Occasionally, when force is to be applied for the regulation of teeth,

it is necessary to open the bite, as where the upper incisors close deeply back of the lower ones, interlocking them; when an upper cuspid has erupted inside of the arch in such a manner that by opening the bite its movement can be more easily and quickly accomplished without the opposition of the antagonizing teeth; and to prevent interlocking of the teeth when a chin-cap or equalizing device is applied for correcting protrusion. In some cases of short bite, the lips are naturally pressed together, giving an appearance of double protrusion. This condition is usually corrected by opening the bite, either by the insertion of a full or a partial plate covering the teeth, or by adjusting artificial crowns to the teeth.

Opening the bite has been used to advantage in cases of pericemental inflammation, where the teeth were extruded and the closure of the jaws painful.

The older methods employed for moving the incisors outward by the use of the wedge, ligature, etc., for expansion, which were not so certain in causing their movement, made it more necessary that the bite be opened, and for this purpose blocks of gold or ivory, gold caps, and sometimes gold plates, were fastened to the occluding surfaces of the molars or bicuspids. Later, vulcanite was used for this purpose, which was made to extend over the grinding surfaces of the teeth, as illustrated in the Coffin method (Figs. 93 and 104).

Appliances.—In a case like the one shown in Fig. 187, where the upper incisors have a lingual occlusion, an appliance may be made to

Fig. 187.

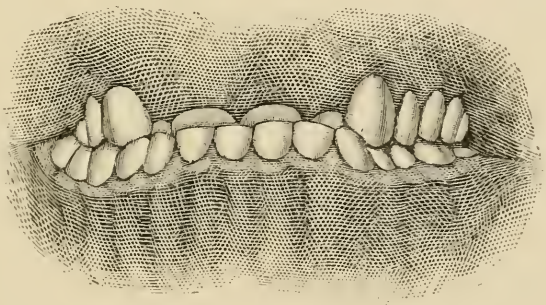

move them outward, and at the same time to open the bite and prevent the lower incisors from interfering with their movement, by first arranging a palatine base-wire to cross the arch from side to side, with the ends bent sharply backward to rest on the partial-clasps

(Fig. 188). Spring-clasp attachments are usually fitted to the first bicuspids and first molars. A spring-wire for moving the incisors

Fig. 188.

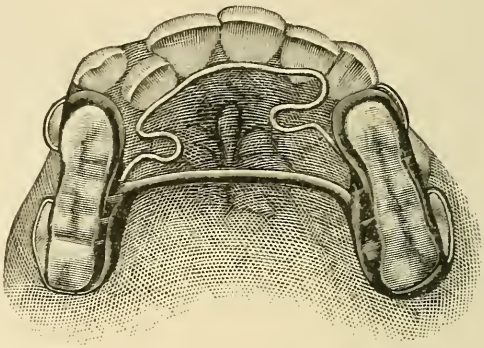

outward is formed to the lingual side of them, having a U-shaped loop arranged opposite the first bicuspid on either side of the arch, its ends extending backward to be attached with solder to the anchorage portion with the ends of the base-wire.

For opening the bite a thin strip of platinoid, German silver, or other suitable metal (Fig. 189) is placed on the model, across the grinding surface of the teeth used for anchorage, from front to back. It is to be fitted into the depressions as well as may be by pressing it with an instrument, narrowing the ends and passing one underneath and doubling it around the mesial wire of the spring-clasp on the bicuspid, and the other around the distal wire of the spring-clasp on the molar. Wax is then built up on this part and the appliance inserted in the mouth for the purpose of getting a bite, at the same time determining how much the upper and lower arch should be separated to permit the upper incisors to be moved over without interference. Then replace the appliance on the model, trim the edge of the wax smooth, and place mouldine over it to form a matrix. The mouldine is taken off to remove the wax and replaced, and a piece of block-tin, soft solder, or fusible alloy melted in an iron spoon and poured into the matrix. This forms a block of metal on the appliance in the form of the wax, causing a good articulation with the lower teeth. The raised part can be built up in a few moments with solder, using

Fig. 189.

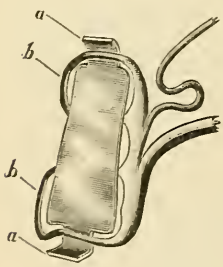

Fig. 190.

Fig. 191.

the soldering iron, or a bar of metal soldered on and dressed to form a good occlusion. The upper incisors are moved outward with the looped spring in the usual manner, and when they have passed sufficiently in front of the lower incisors the metal is dressed away from the grinding surface from time to time as much as the position of the incisors will warrant until it is all removed, which will leave the rest of the appliance like an ordinary one. The same appliance can be used for retaining when desired. When supplemental force is required for moving the incisors outward, an apparatus may be applied as illustrated in Fig. 373.

Fig. 190 shows the features, before regulation, of Miss B., aged fourteen years. The upper arch was much depressed, with the lip closing back of the line of the lower lip. An apparatus similar to the one described in Fig. 188 was utilized for opening the bite and moving the upper incisors outward. The improved contour of the features is shown in Fig. 191.

When there is but one spring-clasp attachment on either side of the arch for anchorage the bite may be opened by passing a piece of thin plate-metal, with the ends narrowed, underneath the distal and mesial arm of the spring-clasp, as shown in Fig. 192, and by flowing solder in a sufficient amount on the metal with the soldering iron. After this the solder is dressed to improve the articulation. The form of device illustrated in the figure can be utilized for opening the bite to prevent occlusion during treatment for pericemental inflammation. When a broader occlusal surface is required the ends of the metal should be left extending onto the adjoining teeth, and solder flowed over it as described.

Fig. 192.

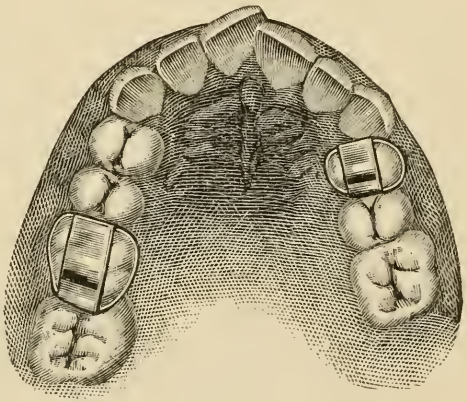

Fig. 109 illustrates an interesting case requiring the opening of the bite. Metal was built over the bicuspids, cuspid, and incisors on one side of the arch to favor the outward movement of instanding incisors and cuspid on the opposite side of the arch.

The practitioner is occasionally called upon to devise a method for preventing the wear or breakage of the teeth from gritting them at night. The apparatus illustrated in Fig. 193 was constructed for that purpose. It is made of vulcanite, passing from the labial to the

Fig. 193.

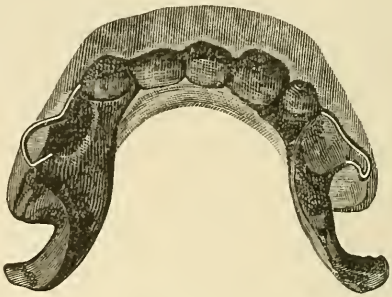

lingual side, over the teeth of the lower arch, and retained with spring-clasp attachments over the first bicuspids; the upper surface being left comparatively smooth, or slightly convex, for occlusion with the upper teeth. Sometimes the apparatus is applied to better advantage in the upper arch in the form of a palatine plate with a ledge passing over the occlusal surfaces of the teeth, but not covering the buccal or labial faces.

The following method was employed some few years ago for opening the bite and moving outward upper incisors that were locked in by the lower incisors (Fig. 194). The upper incisors closed back of

Fig. 194.

the lower incisors a considerable distance. The case was regulated with an old-style vulcanite plate, which would hardly be recommended now, but the history contains some important features, and will be described.*

* Jackson, Dental Cosmos, 1887, p. 377.

The plate was made of rubber extending over the molars and bicuspids to the gum line for anchorage, with silver screws inserted in the rubber back of the incisors (Fig. 195). The threaded holes in the rubber for the screws were made by drilling the holes a little smaller than the size of the screws to be used. A little wax was put into the holes; the screws were warmed and turned into the openings. The heat from the metal softened the rubber and made a good thread. As the teeth moved outward, leaving the screws long, they were bent so as to rest near the necks of the teeth, and the pressure was thus kept at the right point; a slight turn of the screws caused pressure at the distal or mesial edge, rotating the tooth as desired.

Fig. 195.

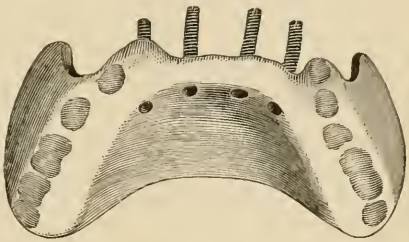

It was not difficult to bring the upper incisors into proper position, as seen in Fig. 196, but when the regulating seemed complete, and the teeth had been retained several weeks, a serious complication began to arise, and one that could not be corrected, as the patient would not submit to the treatment suggested. This complication is one that is often met with, though we hear very little about the real cause. The father of the patient had a very prominent lower jaw, and it was found that the lower jaw of the patient was constantly moving forward on the bite. At a later date the jaw was still continuing to grow forward. Contrary to the general rule, it was taking the form that is found at birth and extreme old age. In other words, there was no distinct angle, as at the age of puberty or on approaching adult life. The upper incisors were moved outward again, and there still being a constant forward growth of the lower jaw, all of the teeth in front of the second bicuspids were moved outward a third time by a system of wedging (Fig. 197). A plate was applied to retain the teeth, and still the lower jaw became more prominent, causing lack of anterior occlusion.

Fig. 196.

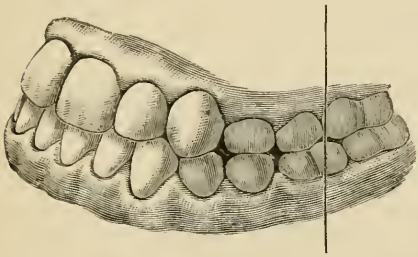

A chin-retractor was recommended early in this case, which would have arrested the advance of the lower jaw, but the parents were not willing to permit its use. At the present writing the upper incisors have retained their position well, with their edges above

Fig. 197.

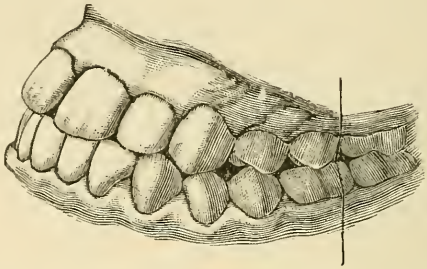

those of the lower, but the lower jaw has become very prominent, and the incisors are crimped and tip considerably backward. The latter change is due to the tension of the lower lip.

When there is a tendency for the lower jaw to advance in this manner, an equalizing device or a chin-cap should always be applied in the early stages, as these conditions are progressive, and its use persisted in as long as required.

Plates.—In Fig. 198 is presented the case of a boy aged nine years, whose right upper lateral incisor was erupted inside of the circle of

Fig. 198.

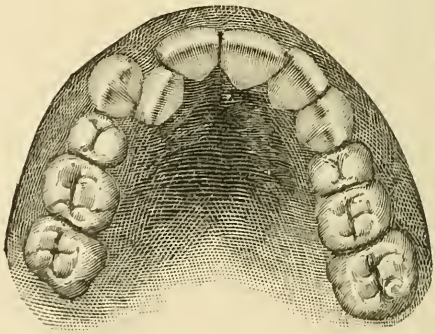

the arch back of the central incisor and deciduous cuspid, with the space nearly closed. The first bicuspids were erupted. The second deciduous molars were still in place.

The practice of extracting a deciduous cuspid to give room for a crowded permanent incisor is not a good one. The deciduous cuspid

should be retained to keep the space necessary for the eruption of the permanent cuspid in the circle. The permanent incisors are broader than the deciduous ones, and are likely to be erupted in an irregular position if not accompanied with harmonious development of the premaxillary bone. The antero-posterior diameter of the deciduous molars is greater than that of their successors, the bicuspids. The combined measurement of the deciduous molars and cuspid is as much as or more than that of the permanent cuspid and bicuspids, and if these deciduous teeth are preserved the permanent ones usually have sufficient room for proper eruption in the circle.

To force the malerupted lateral incisor into its proper place between the central incisor and deciduous cuspid it was necessary to expand the arch. A split vulcanite plate with springs was used, the lateral halves being joined by a U-shaped spring and the plate retained by wire-clasps (Fig. 199). The plate was separated by

Fig. 199.

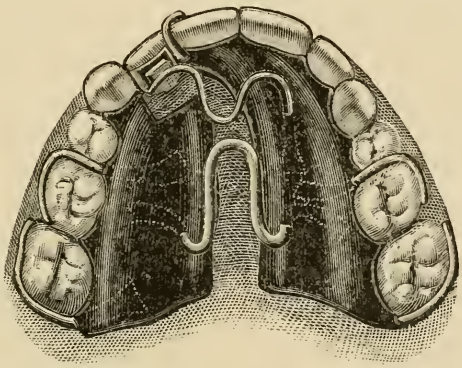

dividing it with a fine saw from where it came in contact with the irregular lateral in a curve backward along the median line. The advantage of this form of separation is apparent.

The part of the plate covering the left side of the palatine arch was attached to all of the teeth around to the irregular lateral incisor by the help of the wire-clasps, and acted as an anchorage for moving outward all of the teeth on the right side. One end of a spring-wire, in the form of three loops, was fixed to the left section of the plate, the other end resting under a lug on a collar cemented to the irregular lateral incisor. As the loops of the springs were opened it separated the sections of the plate, expanding the arch, and at the same

time the lateral incisor was moved outward to its proper place. After the regulating was completed the teeth were retained with the device illustrated in Fig. 496.

In Fig. 200 is shown the case of Miss H. The upper lateral incisors were erupted considerably inside of the circle of the arch, with the cuspids directly in front of them. The space between the central incisors and first bicuspids was only sufficiently broad to admit of one tooth on each side, either the cuspid or lateral incisor. The central incisors, bicuspids, and molars articulated properly with those of the lower arch. It was not practicable to expand the arch sufficiently to let the cuspids and lateral incisors into proper position. The cuspids could be moved into the spaces and the circle of the arch preserved, but the arch would then appear too narrow, owing to the points of the cuspids showing, with only two teeth between them, when naturally there are four.

Fig. 200.

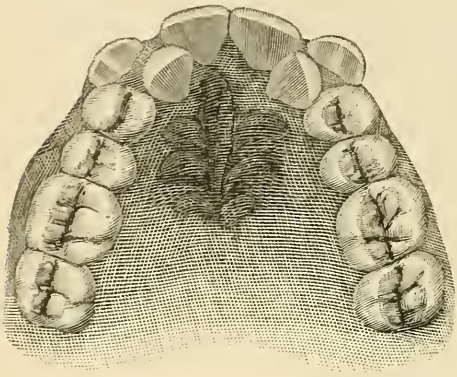

The important reasons for retaining the cuspids are their usual good structure, great strength, and the preservation of the canine ridge, which is lost by the absorption of the process when the root is removed; therefore the cuspid should always be preserved unless some condition necessitates its removal.

The loss of the canine ridge detracts materially from the character of the features. It is more important to be preserved in the case of a female than a male, as in the latter a defect in the contour of the lip can be covered by a moustache.

However, from careful examination in this case it was seen that the buccal and mesial faces of the first bicuspids closely imitated the appearance of the cuspids, and that the lateral incisors if moved outward would fill the spaces so thoroughly and improve the general effect that it was determined to sacrifice the cuspids and move the laterals outward, and thus maintain the circle of the arch (Fig. 201).

The cuspids were extracted and a platina-gold collar with a lug on the lingual side was cemented to each of the laterals for supporting the end of a spring. A vulcanite plate was formed covering the palatine arch, with a suction for anchorage. The arch was rather deep, the plate had a good fit, and no further retaining was necessary. The sides of the front part of the plate were dressed away to permit the free action of the springs. These were arranged in the distal part of the plate and extended forward in a double curve, one on either side, with the ends resting underneath the lugs. Force was caused by bending outward the ends of the springs. The result proved very satisfactory.

Fig. 201.

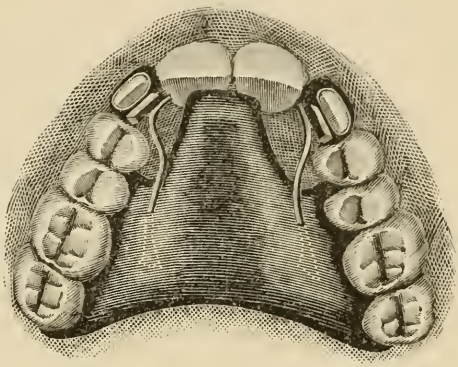

Fig. 202 illustrates the lower arch of the same case. One of the incisors had been removed and the three remaining ones were bunched together, the space between the cuspids being too narrow for their admission. Owing to the close occlusion, it was not considered practicable to increase the distance between the cuspids sufficiently to admit the irregular teeth. A moderately satisfactory result was attained by the extraction of one of the remaining incisors and moving the others forward, which filled the space between the cuspids. The cuspids were then dressed so as to conform more nearly to the shape of the incisors.

Fig. 202.

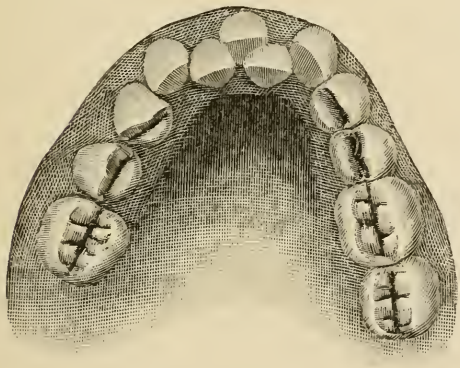

Fig. 203 represents the condition of the teeth of Miss S., aged fourteen years when presented for treatment. Within the year she had

worn a regulating appliance retained with ligatures for several months under the direction of another practitioner.

The upper central incisors closed in correct position over the lower ones, but the lateral incisors had receded considerably and closed inside of the lower arch. The cuspids were too prominent, with insufficient space for their admission. The pulps of both first permanent molars were dead and the crowns so badly decayed that it was decided to extract them.

Fig. 203.

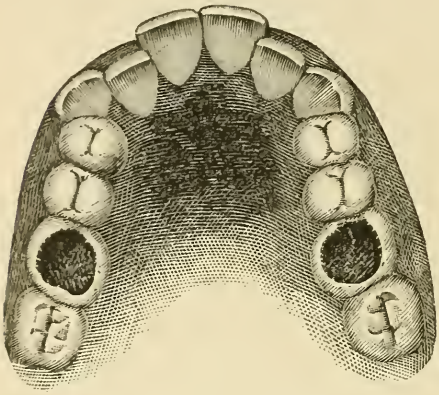

A plate as seen in Fig. 204 was inserted. It was made of vulcanite and retained with wire-clasps. Two of them extended from the distal part, one on either side to encircle each of the second molars, and two spring-wires shaped with a slight curve extended from the plate outward to rest on the mesial side of the first bicuspids. The latter assisted in retaining the plate and at the same time were utilized for moving the bicuspids backward. Two other springs for moving the lateral incisors outward were anchored in the front part of the plate just back of the central incisors, each extending forward in the form of a loop and then backward and outward in the shape of the letter S; the ends were made to pass under lugs on the lingual side of collars cemented to the laterals.

Fig. 204.

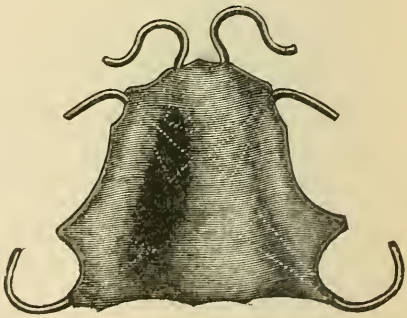

The regulation was begun by bending the ends of these springs forward and at the same time bending the side-springs slightly so as to cause pressure on the mesial surface of the bicuspids for moving them backward. The change of position of the latter increased the space for the cuspids.

Almost any form of spring that can be used with a base-wire device can be used to advantage when attached in a vulcanite plate.

Fig. 205 illustrates a method employed for moving outward incisors by a looped spring attached in a plate for anchorage. The spring-wire is formed to the lingual contour of the teeth, with a U-shaped loop formed in it on either side opposite the first bicuspids, pointing

Fig. 205.

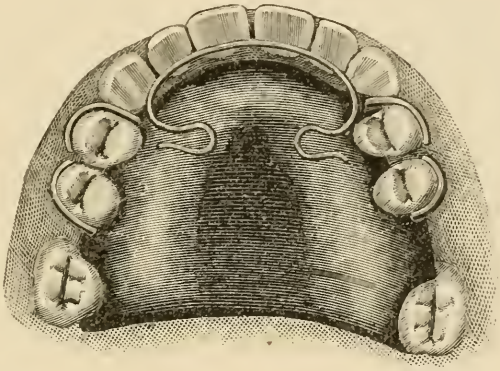

towards the median line, and the ends of the wire curved backward, flattened, and extended into the vulcanite. The wire is less liable to break at the surface of the plate if the end of the part of the spring that enters it is flattened, leaving the wire round where it emerges from the rubber. The plate should be retained with wire-clasps extending around one or more of the molars or bicuspids on either side. When there is no space between the teeth the wire-clasps can be extended over the arch and shaped to cross the buccal side.

In using the looped form of spring it is often advisable to cut away a portion of the rubber near the loops, so that they can be bent more easily for causing action. A collar with a lug on the lingual side can be cemented to two or more of the incisors for retaining the spring.

In making the plate the flattened ends of the springs and clasps should be embedded in a try-plate, and pieces of binding wire put around the looped spring in several places and twisted lightly, their ends separated and left projecting upward to hold the spring firmly in the plaster in the upper half of the flask when separated for packing.

A device that has been recommended for moving outward an in-standing incisor, is made by cementing to the incisor to be moved a collar having a screw-post projecting from the labial side of it, and arranging a curved piece of flat spring-metal with a hole in the centre

to pass over the post, shaping the ends to rest on the labial side of the adjoining teeth (Fig. 206). To give the desired pressure a threaded nut is then run on to the screw-post, with a watch-key fitted as a wrench to turn the nut. If the incisor is considerably back of the adjoining teeth, and space is insufficient, the curved bar should be reversed, having the convex side towards the incisor to be moved. Pressure caused by the bar in this position will tend to drive the adjoining teeth laterally, broadening the space and at the same time allowing the incisor to be moved outward, after which the bar should be changed, placing the concave side inward.

Fig. 206.

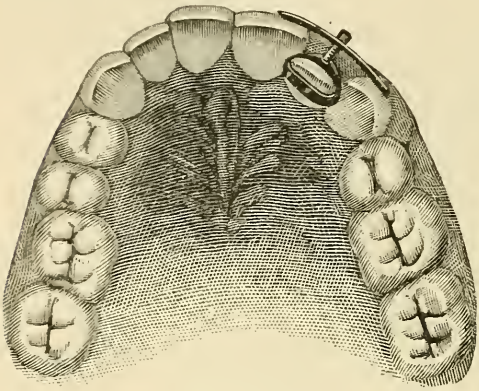

It has been suggested that two or more teeth can be moved outward in a similar manner. Dr. Eugene H. Smith* recommends in some cases that the screw-post be attached to the tooth without the use of a collar by soldering it to the centre of a piece of gold plate, the latter being fitted to the labial side of the irregular tooth and held in that position with a ligature wound around it from the neck to near the incisive edge.

Some operators, notably Dr. Byrnes,† have used a narrow strip of elastic metal, as spring-gold, or a small-sized clock-spring, for moving outward instanding incisors, passing the spring around the irregular tooth and shaping the ends to press on the labial sides of the adjoining ones. The tension of the spring tends to broaden the space and at the same time move the tooth outward.

In 1541 Egenolff explained that irregular teeth could be moved to correct position by pressure with the fingers.‡

Persistent force thus applied where the teeth are erupting will often prove efficacious in correcting their position, and in some cases even

* Smith, International Dental Journal, 1893, p. 846.

† Byrnes, Dental Cosmos, 1886, p. 278.

‡ Egenolff, Translation, Dental Cosmos, 1887, p. 3.

though they are considerably irregular. (See Figs. 290 and 291.) In occasional cases an incisor erupting considerably inside of the arch can be moved outward in this manner.

Later was described a method of moving upper incisors outward by the use of a thin piece of wood, placing it between the upper and lower incisors at an angle to cause an inclined plane, having the patient bite forcibly against it, and holding it in that position as much of the time as possible.* A thin piece of metal, similar to the blade of a narrow case-knife, is probably more effective.

As has been stated, Catalan recommended the use of the inclined plane in 1814.†

Another method was to fit a block of ivory to the roof of the mouth, tied to the side teeth,‡ the incisors being forced outward by placing wedges of wood or other material between them and the ivory; in some cases opening the bite to permit the instanding upper incisor to pass over the lower ones by attaching a block of ivory, gold, or wood between the upper and lower molars.

Many forms of long bars have been described for moving the incisors outward. The earlier ones were made with a strip of metal, shaped as nearly as might be into the curve it was desired the teeth should assume when regulated, passing on the labial side of the anterior teeth and crossing the buccal surface of the first and in some cases the second molars. The bar was sometimes punctured with holes, or had hooks attached in different parts to accommodate ligatures to pass from the bar around the teeth, both for the purpose of anchorage and for moving the irregular teeth into line. In more recent years half-round or round wire has been utilized for this purpose.

Several methods have been devised for anchoring the ends of the bar to the molars and bicuspids, the earlier procedure being the attachment of pieces of plate-metal to the bar, so shaped that when bent at a right angle they would rest on the grinding surface of the molars. Also the bar was attached to the teeth with metal clasps, and held in position with ligatures and bands extending over the teeth, and by soldering the ends of the bar to a metal plate.

In cases where the incisors were to be moved outward the ends of

---

* Sigmund, 1825, p. 17.

† Fox and Harris, 1846, p. 100.

‡ Tomes, American Journal of Dental Science, 1848, p. 52.

the bar were attached to clasps or bands for anchorage in position to permit the anterior portion of the bar to rest sufficiently in front of the incisors to allow them to be drawn outward into the circle by ligatures that were passed around them and the bar, the spring of the bar causing their movement.

Since the introduction in 1839 of rubber vulcanite for anchorage many forms of attachment have been recommended for holding the ends of metal bars shaped to pass in front of the incisors for the purpose of drawing them outward, they being attached to the bar with ligatures. Dr. Kingsley has described such an appliance in his work on Orthodontia, using the cord or rubber ligatures.

In some instances a rubber plate capping the back teeth with a vulcanite band extending in front of the incisors has been constructed, holes being made in the band opposite the incisors for ligatures made from rubber tubing.

A similar rubber plate without the band has been utilized for moving the upper incisors outward by a system of wedging, the plate forming the anchorage; the anterior part being made thick, sometimes shaped like a dovetail for holding wedges of soft rubber, etc. In other cases, holes are drilled for the insertion of wood points or metal screws. The latter appliances are effectual, but they are inclined to rest on the prominence of the incisors and to depress them, as by the action of an inclined plane.

Plates with long bands and screw-nuts are being used for moving outward and inward the incisor teeth. The bands are attached to the plate by passing through projections or staples on the buccal side, and the bands are ligated to the teeth.

Collars cemented or bolted to the molars or bicuspids for holding jack-screws, or with tubes attached for holding the ends of long bands, are also being used extensively; they are recommended especially by Drs. Farrar and Angle. The long bands are provided with thread and nut for drawing them forward or backward.

Improving the Contour of the Arch by the Use of Crowns.—Soon after the introduction of the crown constructed with the gold collar, post, and porcelain front, as described by Richmond, I utilized the method for a case of irregularity of an instanding incisor.

A gold crown was fitted to the tooth with a porcelain attached; this was placed far enough forward to form a good contour with the adjoining teeth. The space near the gum was filled in with gold;

leaving a sulcus back of the porcelain sufficiently deep to let the lower teeth occlude properly.

This method was adopted for improving the contour of the teeth in the case of Mrs. H., whose teeth were very irregular, several of them, including the incisors, cuspids, and bicuspids, closing considerably inside of the proper line. The teeth were defective, and not worth moving to correct position.

The patient at first wanted to have the incisors extracted and a plate inserted, but was pleased with the method suggested. There were in all five crowns inserted. One of the teeth was so far inside of the arch that the space between it and the porcelain front was more than the width of the tooth, the intervening space being spanned with a bar of gold next the gum. The crowns have been worn over twenty years, and are still doing good service.

Moving Roots for Crowning.—The improvement of the position of a malposed root for the attachment of an artificial crown is occasionally required.

Several methods have been devised for this purpose, most of them being dependent on a post placed in the root, anchored in the nerve-canal with cement phosphate; or by turning into it a screw-post, to which ligatures or rubber bands may be attached extending over the adjoining teeth for causing pressure to move the root laterally.

A spring in the form of a coil has been used to advantage for moving roots of teeth in different directions.

A simple method of attaching a spring has been described by Dr. Silleto.* He bends the wire into a coil of two or three turns of suitable size to pass over a post inserted in the root, the ends of the wire being shaped to press on the sides of the adjoining teeth in such position as to give the required pressure. A similar form of spring has been recommended by Dr. Siegfried † for moving teeth outward and inward in the arch by fastening the coil to the labial or lingual side of the teeth, its ends bearing on the adjoining ones.

---

* Silleto, Ohio Dental Journal, 1894, p. 2.

† Siegfried, Dental Cosmos, 1896, p. 497.

CHAPTER XII

INCISORS, TO MOVE INWARD OR LINGUALLY

Lower Incisors, to move Inward.—Cases requiring the inward movement of the lower incisors are comparatively few. The upper incisors, on the other hand, often take a position back of the lower ones in the process of eruption, necessitating their outward movement to get normal occlusion.

When the lower incisors are too prominent they are usually accompanied with a degree of prognathism or prominence of the lower jaw. If their irregularity is not very marked, requiring them only to be moved inward with the process, it can be easily accomplished by continued pressure on the labial side of the teeth, but when there is a prognathous jaw their correction is more difficult, and an equalizing device or a combined apparatus with chin-cap is employed. Where there is protrusion of the lower incisors, and they are crowded in the arch, space for their inward movement can be made only by lateral expansion or by the extraction of a tooth on either side; otherwise the movement of the whole arch of teeth backward with the process is required, or even the backward movement of the jaw proper.

Fig. 207.

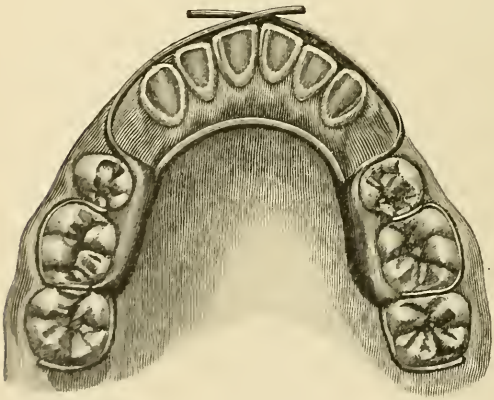

Fig. 207 shows the form of an appliance that has been used for moving inward the incisors and cuspids at one time, the first bicuspids having been extracted. The device is equally applicable for moving a less number of teeth. The anchorage consists of four molars and two bicuspids. When the wisdom-teeth are erupted they should be included in the anchorage. A lingual base-wire, about No. 13 gauge, is bent to conform to the inner curve of the arch, being placed

far enough back of the incisors to permit their movement, its ends anchored with spring-clasp attachments to the first molars, partial-clasps on the adjoining teeth, and wire-clasps extending backward to the distal side of the second molars. If all of the teeth are erupted, spring-clasp attachments should be placed over the second bicuspids and second molars.

Two long curved finger-springs are attached to the base-wire and partial-clasps, one on either side of the arch, extending through the space caused by extraction, just in front of the second bicuspids, to the buccal side, and bent forward, following the labial curve of the incisors and cuspids; they should pass each other at the median line. The variation of pressure is caused by shaping the springs to impinge upon the teeth it is desired to move, usually first causing force on those at the median line. When there is sufficient interdental space between the front teeth to permit of their backward movement extraction is not required, and this form of spring may be shaped to extend from the base-wire over the arch from the labial to the lingual side at the junction of two of the teeth, projecting forward in the same manner. When the teeth used for anchorage are inclined to move forward, or when more pressure is required, supplemental force, as with infralabial bar or a cross-bar, should be employed.

In Fig. 208 is shown another form of appliance for moving backward at one time the six anterior teeth. A lingual base-wire located

Fig. 208.

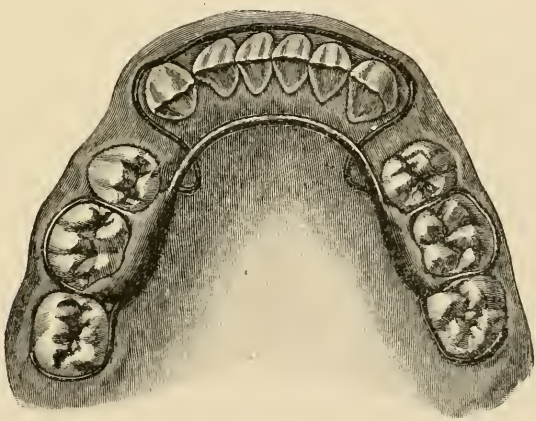

with a space between it and the teeth to be moved is anchored to the molars and bicuspids as described. A spring-wire, about No. 19

gauge, is bent into a semicircle, either end terminating in a U-shaped loop about one-fourth of an inch long, the spring conforming to the labial faces of the incisors and cuspids near the neck. Its loops pass back of the cuspids to the lingual side, resting between the base-wire and the gum; the ends are soldered to the anchorage portion with the ends of the base-wire and spring-clasps. The desired force is applied by closing the loops of the spring a little from time to time.

When there are no interdental spaces between the teeth to be moved the curve of the spring should be such as to leave a narrow space between it and the distal surface of the cuspids to prevent the teeth being wedged or crimped together during their movement. Closing the loops in the spring first causes more inward pressure on the cuspids than the incisors. The principal force being thus first applied to two teeth only, the amount of pressure required to change all of them, and consequently the strain, is lessened, and the danger of drawing forward the teeth used for anchorage is diminished. It will be understood that after teeth have begun to move less force is required to continue their movement.

A convenient appliance for moving the incisors or the incisors and cuspids inward is made as seen in Fig. 209. A heavy lingual base-wire, about No. 12 gauge, is arranged to follow the inner curve of the arch at the gum line, having a space between it and the incisors, its ends well anchored with partial-clasps and spring-clasp attachments. A wire, about No. 18 gauge, is formed to the labial side of the incisors, crossing them usually above the centre between the gum and incisive edge. Two U-shaped loops are formed in the wire, pointing downward and resting in front of the cuspids. The ends of the wire extend backward on a line with the part of the spring that crosses the incisors, and are again curved to pass over the arch at the junction of two of the teeth at either side. The ends are attached with solder to the base-wire.

Fig. 209.

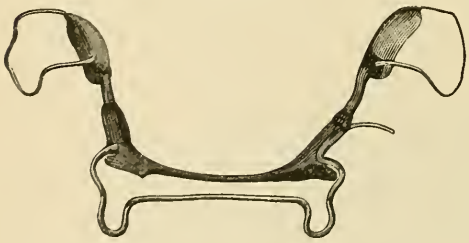

When the teeth are crowded, requiring the removal of a bicuspid on either side to get space for their movement, the loops of the spring should usually be arranged opposite the spaces, especially when it

is the intention to move all of the six front teeth inward at one time; the part of the spring that crosses the incisors extending also across the labial side of the cuspids. With the latter arrangement force is caused for their movement by closing the loops of the spring as required, but if only the incisors are to be moved in the manner illustrated force is applied by bending slightly inward with flat-nosed pliers the mesial side of each of the loops in front of the cuspids. The twisting of the wire in the loops gives the desired force for the movement. This arrangement of the spring is also suitable for moving one or two teeth.

Fig. 210 represents the case of Mr. S., aged thirty-eight years. The four lower incisors closed in front of the upper ones, causing a

Fig. 210.

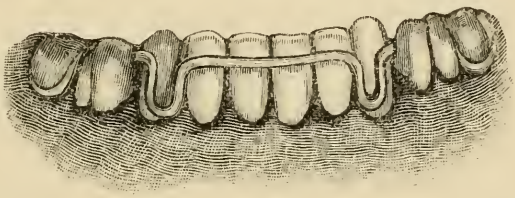

poor occlusion, the teeth being considerably worn. The conditions in this case were corrected by making the changes in the spring about once in two weeks, the patient being directed to remove the appliance regularly for cleansing. The regulating and retaining was accomplished in fifteen visits. The same form of appliance was used for correcting a similar irregularity for a daughter of Mr. S., aged sixteen years.

When the incisor and cuspid teeth lap considerably in front of the upper ones, their movement is facilitated by opening the bite (Fig. 188). But sometimes it is not necessary, and no provision is made for opening the bite to assist the movement of the incisors from the labial to the lingual side. With this form of device the loop can frequently be used to advantage for forcing backward a cuspid or other tooth, in either the upper or lower arch, by bending the end of the loop inward.

Fig. 211 shows a convenient method for moving inward all of the incisors, or any of the teeth in the lower arch. In this case it was utilized to move inward the first left lower bicuspid, cuspid, and lateral incisor, and the right cuspid. All of these were closing outside of the

upper arch, there being sufficient space to permit their movement. A lingual base-wire, No. 12 gauge, was formed and anchored in the usual manner. A spring for moving the teeth on the left side was shaped similar in form to a continuous spring-clasp, extend-

Fig. 211.

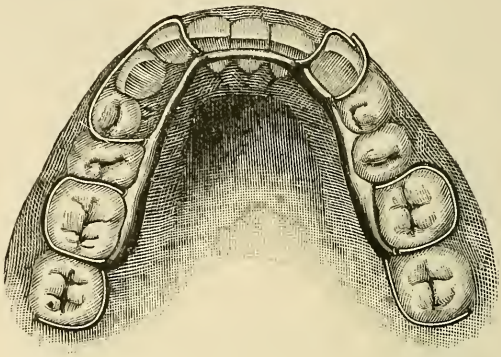

ing from the base-wire over the arch at the junction of the teeth to the labial side, crossing them at the gum-line, and the ends attached with solder to the base-wire. The cuspid on the right side was moved into line with a spring bent twice at right angles and attached to the base-wire in position so that the free ends would extend over the arch on either side of the cuspid, where they were bent towards one another to rest on the labial side near the gum. The action of the appliance was controlled by bending the labial part of the springs nearer to the base-wire from time to time, as required.

Figs. 121 and 123 illustrate the occlusion of the teeth before and after the operation.

Vulcanite rubber, in place of the base-wire, properly anchored with wire-clasps or spring-clasps, can be utilized for supporting the springs of the apparatus, but it is bulky, and not as strong as the appliances I have described.

Devices for moving outward the lower incisors (Figs. 128, 129, 130) are sometimes applicable for moving incisors inward. An inclined plane, arranged on the upper teeth, has been used for reducing prominence of the lower incisors where there were interdental spaces between them.

Fig. 212. When additional or *supplemental force* is required to move backward the lower incisors and cuspids or other teeth, and

Fig. 212.



for preventing anchorage teeth from moving forward, a cross-bar, or an apparatus as illustrated, may be worn continuously or at night. It consists of a chin-cap and wire-standards, supported by a cranial-cap. The attachment is made by a suspender and elastic from the cap to each standard, passing back of the ears; the standard passing through a short tube on the cap, connected with an elastic extending from a hook to pass over an adjustable knob on the standard in front of the ears. To the teeth to be moved is adjusted an *infralabial bar* (Fig. 213). It is usually made by fitting across the labial

Fig. 213.

faces of the teeth a narrow strip of thin plate-metal, and shaping a wire, No. 18 B. & S. gauge, to rest on the plate-metal near the lower edge, with the ends curved backward to pass over the arch at the junction of the teeth to rest on the lingual side of some of those to be moved. Another wire, No. 14 gauge, is shaped to rest on the plate-metal, close to the smaller wire. The ends are curved forward to pass over the lower lip, near the corners of the mouth, and again bent backward over the cheeks, forming arms. Both wires are then soldered to the plate-metal, and a small knob is attached near the end of each of the arms. In use, elastic bands of moderate tension are hooked over the knobs of the arms and knobs on the standards. The latter are provided with screws, and are adjustable for moving up and down on the standard to get a correct line of traction. When desirable the infralabial bar can be made as illustrated in Fig. 214. Narrow strips of plate-metal are bent to pass over and rest on

Fig. 214.

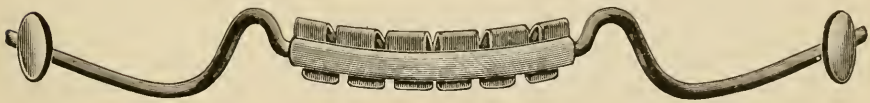

the labial and lingual sides of the teeth to be moved and attached to the bar as described. The lateral, or up-and-down movement of the jaw, does not interfere materially with the action of the apparatus. Bars of this character can be utilized in correcting the position of prominent teeth in the upper arch.

Upper Incisors, to move Inward.—The teeth of the upper arch are more important to the expression of the features than those of the lower arch. Great care should be exercised for their preservation and correction.

In the normal occlusion of the teeth the upper incisors lap some in front of the lower incisors and, when the lips are closed, the incisive edge of the upper incisors rests a little below the inner edge of the lower lip. The lower incisors are generally erupted first and guide the upper ones to position. As the permanent upper incisors descend they excite absorption of the roots of the deciduous incisors. The latter occasionally deflect them outward, and when fully erupted they assume a position considerably in advance of the lower ones, with spaces between them, sometimes resting on the outer edge of the lower lip. If allowed to remain in this position, the pressure caused on them by the lip will encourage them to become still more prominent. This undue protrusion should be corrected during or soon after the eruption of the teeth, unless moving them should prove detrimental by causing too much lateral pressure on other teeth that are erupting. Lateral pressure, when too severe, will in some cases arrest the eruption of the adjoining teeth, and especially is this the case with the lateral incisors.

When incisors outside of the correct circle of the arch are to be regulated the appliance should, if practicable, be adjusted inside of the arch. It is less conspicuous and more agreeable to the patient, but the occlusion of the teeth may be such as to require the appliance to be arranged on the labial side.

For correcting the position of prominent incisors, when it is desired to lessen the prominence of the process as well as of the teeth, it is well to keep in mind that the force should be applied near the gum line.

Fortunately but a small percentage of cases require the movement bodily of the teeth with the process. When the crowns of the teeth need to be tipped inward to improve the angle, the force should be applied nearer the edge.

When one of the incisors is too prominent, but has a sufficient space for it in the arch, as is often the case with young patients, and occasionally with the adult, the following procedure will usually prove effective.

The right upper incisor being the tooth to be moved, a spring-clasp

attachment for anchorage is formed to the second deciduous molar, bicuspid, or one of the permanent molars on the same side of the arch (Fig. 215), and a small spring-wire soldered in the anchorage portion on the lingual side, extending forward, following the contour of the palatine arch as nearly as practicable, and formed into a U-shaped loop opposite the cuspid, its end terminating in a slight hook made to fit into an eyelet on the lingual side of a collar in suitable position that has been cemented to the tooth to be moved.

Fig. 215.

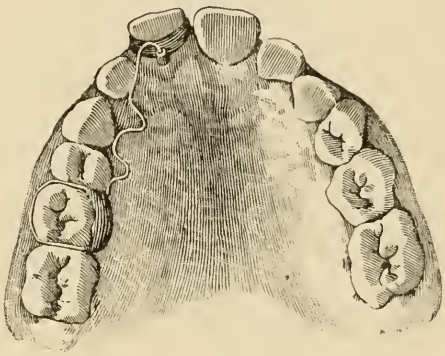

If the occlusion with the lower teeth is so close as to interfere with the collar or eyelet, the use of the collar can in some cases be dispensed with by making the end of the spring into the form of a loop similar to a spring-clasp, the end of the loop crossing the labial side of the incisor near the gum, with the sides extending over the arch at the junction of the incisor with the adjoining teeth, to the gum line, but in such a manner as not to interfere with the articulation. For young patients, when the conditions will permit, it is advisable to use a collar cemented to the tooth, there being less liability of the fixture becoming displaced. In favorable cases, in place of the collar, a wire with a small eyelet formed in the side for the hook of the spring can be passed around the tooth and the ends twisted together to hold it firm. Force for moving the incisor is applied by closing the loop in the spring slightly from time to time. If a single spring-clasp attachment to a molar is not sufficient for retaining the device, a palatine base-wire can be utilized, having it anchored with spring-clasp attachments on one or more teeth on each side of the arch.

When one of the incisors is too prominent, with insufficient space to admit it, with its companions, to the proper line, an appliance for its correction can be made as follows:

A lingual base-wire is formed, extending backward on either side, following the gum line and soldered to a spring-clasp attachment

passing over a molar or bicuspid for anchorage (Fig. 216). A small spring-wire should then be bent twice at right angles, the distance between the parallel arms being equal to the width of the tooth to be moved. The wire is formed on the model so that the parallel arms shall extend forward from the base-wire somewhat into the space between the adjoining teeth back of the incisor to be moved, one end passing either side, to broaden the space for the incisor without interfering with the articulation. The ends are then bent upward and forward to pass over the arch near the incisive edge at the junction of the incisor with the adjoining teeth. From this position the ends of the spring-wire are bent to the gum line, then towards each other to pass across the labial surface of the tooth for causing pressure. The spring is then soldered to the base-wire.

Fig. 216.

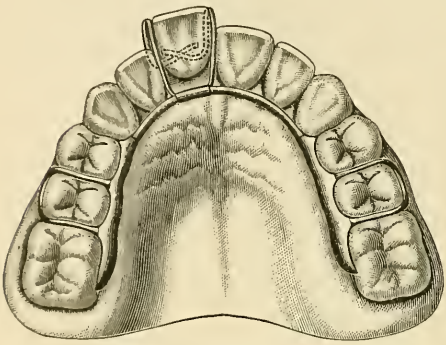

In some cases a spring-wire can be formed like the one used for a spring-clasp attachment, with the curved portion of the spring crossing the labial side of the tooth, the ends extending up to the edge and again to the base-wire, where they should be soldered. Fig. 152 shows this form of spring attached to a labio-buccal base-wire.

Fig. 217.

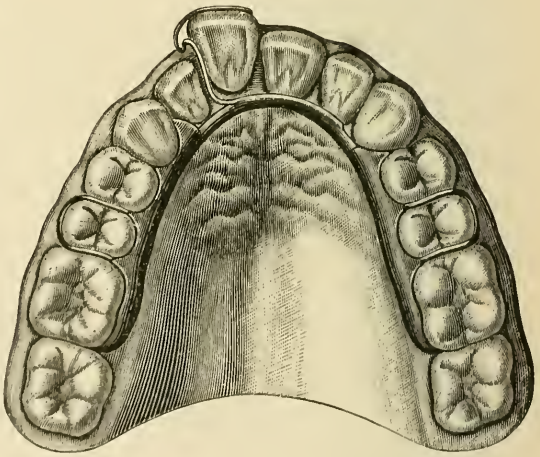

Fig. 217 illustrates a device with but one spring. It has been used successfully for correcting prominent teeth, moving them inward and, when required, rotating them at the same time.

In the case illustrated, the position of the right upper incisor was to be corrected. To a lingual base-wire, well anchored to the bicuspids and molars, was attached, opposite the tooth to be moved, one end of a spring-wire, the spring being shaped to extend over the arch near the incisive edge, where it was bent at a right angle to rest on the labial face of the incisor near the gum. When but one spring is to extend over the arch in this manner, if desired, a short one may be formed to extend from the base-wire to assist in broadening the space or for the rotation of the tooth. Force was applied by bending the front part of the spring nearer to the base-wire.

Fig. 218.

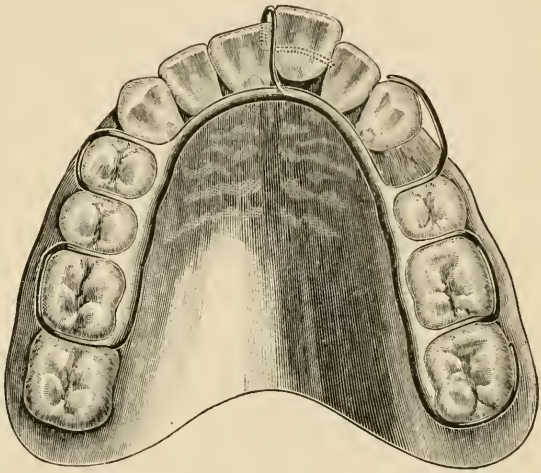

Fig. 218 shows a similar device for moving left incisors inward and laterally, and at the same time moving a cuspid backward to provide space.

Fig. 219.

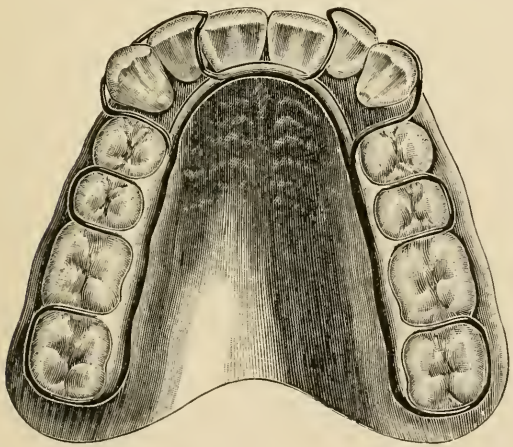

In Fig. 219 is seen an appliance for moving inward two prominent upper lateral incisors and cuspids. A lingual base-wire is anchored with spring-clasp attachments over the second bicuspids and second molars, with partial-clasps on the adjoining teeth. A spring is attached with solder to the base-wire back of the central incisors; the ends are curved to extend over the arch at their junction with the lateral incisors, crossing them near the

gum, for moving them inward. Finger-springs are soldered to the partial-clasps with the base-wire, one on either side of the arch, extending to the buccal side close in front of the bicuspids, and are curved to rest on the mesio-labial surfaee of the cuspids for moving them backward and inward. A continuous spring-clasp can be used in place of the finger-springs described for moving a lateral and cuspid inward, by arranging it to pass from the base-wire to the buccal side of the teeth as shown on the right side.

In the arch illustrated in Fig. 220 the left upper incisor had rotated, lapping considerably in front of the incisor on the right side.

Fig. 220.

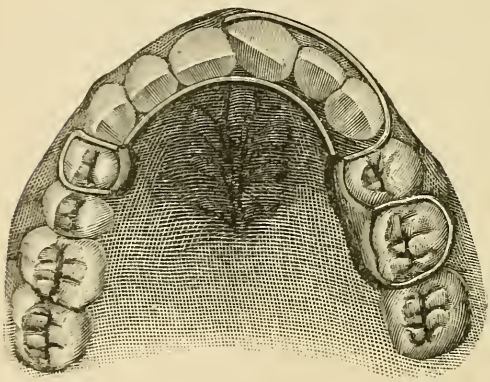

It was found by measurement that the incisor could not be moved into the circle without expanding the arch detrimentally to the occlusion with the lower teeth. Accordingly, the first left upper bicuspid was extracted, and an appliance made for moving the incisors and cuspid backward. A lingual base-wire was arranged to rest against the incisors and cuspid not to be moved; its ends were well anchored. A finger-spring was extended from the base-wire and partial-clasp through the space caused by the extraction, next to the second bicuspid near the gum line, with the end reaching in a curve to the mesio-labial side of the irregular incisor. Force was applied by curving the end of the finger-spring and bending it nearer the base-wire, which moved the central incisor inward, at the same time rotating it, and forcing the others backward until the cuspid occupied the space caused by the extraction.

The teeth were retained with the appliance until they had become firm in the process, when a gold collar was cemented to the central incisor, with a spur extending from it to rest on the lingual surface of the adjoining incisor.

A secondary spring can be added when necessary for causing additional force for rotating or evening the teeth.

When the lower incisors impinge on the gum back of the upper

incisors, interfering with the application of the lingual base-wire, it can be set back a little and a thin piece of metal shaped to rest in contact with the lingual side of the teeth and soldered to it (Fig. 221).

Fig. 221.

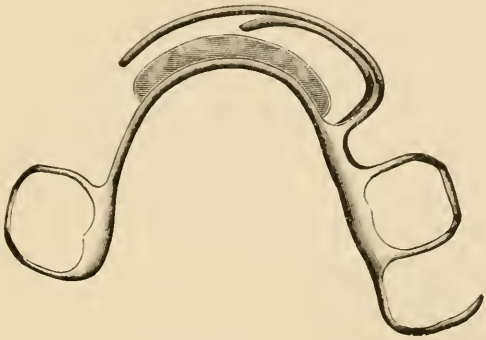

Fig. 222 shows an appliance that was utilized to correct the position of two upper central incisors that were too prominent and rotated

Fig. 222.

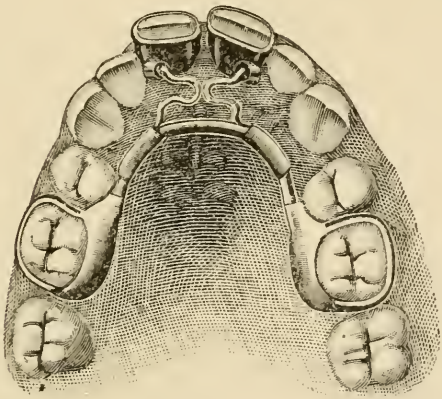

mesio-lingually. The first bicuspids had been removed some years previously to reduce the prominence. The appliance was made by arranging a lingual base-wire to pass some distance back of the incisors, with the ends anchored to a molar on each side. Two small spring-wires, bent into U-shaped loops pointing towards the median line were soldered to the base-wire, one on either side. The free ends of the springs hooked into eyelets that were soldered near the gum on the disto-lingual side of collars that had been cemented to the incisors.

The action of the spring-wires was increased by removing the apparatus and closing the loops, which rotated and drew the incisors nearer to the base-wire. After the central incisors were moved inward they were retained by passing through the eyelets a wire that was slightly curved and of proper length, its ends resting on the lingual side of the lateral incisors.

One or more prominent incisors can readily be moved into position with an appliance made as illustrated in Fig. 223. A lingual base-wire is extended considerably back of the teeth to be moved, formed into a desirable curve and anchored with partial-clasps and spring-clasp attachments. Spring-wires are then attached to the base-wire, one on either side, in form to extend over the arch at the junction of the central and lateral incisor to the gum line, where they are bent at an angle to cross the labial faces of the teeth to be moved. The necessary strain is caused by bending the end of the springs nearer to the base-wire.

Fig. 223.

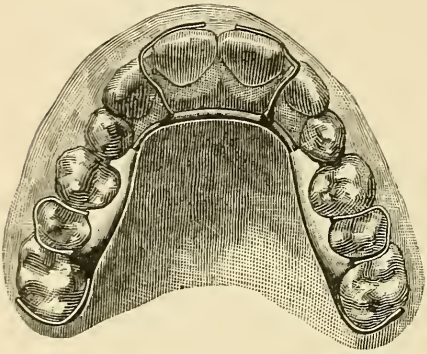

If the teeth move easily, and there is sufficient space, usually one spring will cause enough force for the movement of two teeth. It is advisable to make only slight changes at a time in the shape of the springs, and not oftener than once in from three to seven days.

An efficient device that is equally applicable for the movement inward or the rotation of one or more of the incisors is shown in Fig. 224. It is made with a lingual base-wire following the curve of the arch far enough back of the teeth to permit them to be moved; its ends are fixed with partial-clasps and spring-clasp attachments to the molars and adjoining teeth.

Fig. 224.

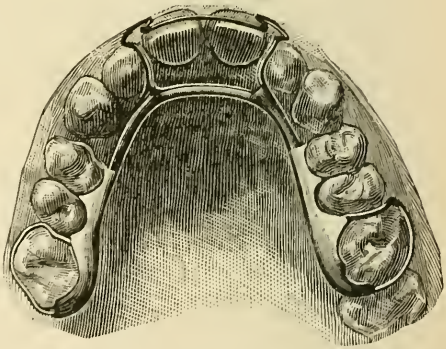

A spring-wire, about No. 19 gauge, is shaped to cross the labial faces of the incisors to be moved rather near their incisive edge (Fig. 225). An oblong loop is formed in the wire on either side extending towards the gum; the free ends of the loop are shaped to pass over

Fig. 225.

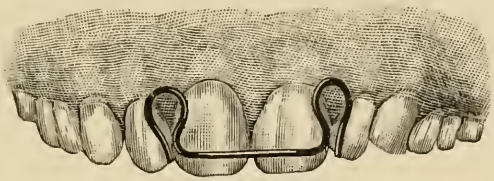

the arch at the junction of the central and lateral incisors to be soldered to the base-wire.

The action of the spring is induced by bending backward the part that crosses the labial side of the incisors a little from time to time with flat-nosed pliers, causing it to rest nearer the base-wire. The arms of the spring that pass over the arch should not be permitted to press hard against the lateral incisors excepting where it is desired to move them laterally outward for increasing the space. If the lingual base-wire interferes with the tongue in pronunciation, and rotation of the teeth is not required, the space back of the incisors can be left free by using a palatine base-wire.

In Fig. 226 is seen a device made similar to those previously described that was utilized for moving inward and rotating two upper

Fig. 226.

central incisors for Miss M., aged sixteen years, and also used as a retainer. The patient had a fall when about nine years of age, fracturing the edges of each of the central incisors, and causing the death of their pulps. The teeth had assumed a prominent position, and were twisted outward.

The device was constructed with a lingual base-wire, anchored with partial-clasps and spring-clasp attachments. The spring of the

appliance was formed into three U-shaped loops, crossing the labial faces of the incisors to be moved, the two outer loops pointing towards the gum. The ends of the spring passed over to the lingual side of the arch at the junction of the central and lateral incisors on either side, to be attached to the base-wire. The centre loop extended downward to cause pressure on the mesial and labial surface of each of the incisors near their edge. Additional force was applied by bending the loops of the appliance backward towards the base-wire, adjusting them so that the centre loop would cause stress for rotating.

Care should be exercised so to shape the wires that they will not cause pressure upward where they pass over at the junction of the teeth, as slight pressure at this point is liable to separate them.

When both of the upper central incisors are too prominent, as a result of pyorrhœa or other cause, an appliance can be made for their correction by first cementing to each of them a platina-gold collar, provided with an eyelet on the lingual side made of wire, parallel with and near the gum (Fig. 227). When desirable the eyelets can

Fig. 227.

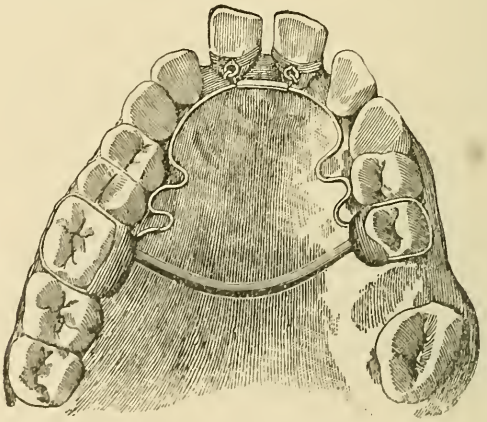

be cemented into pits in the teeth. A palatine base-wire is anchored with spring-clasp attachments to the molars and partial-clasps on the adjoining teeth. A semicircular spring of suitable size is arranged to rest in contact with the irregular incisors, following the contour of the teeth at the gum line, and bent into a loop on either side, the ends extending backward to be fastened in the anchorage. A small

wire hook is formed to pass into each of the eyelets and soldered to the spring near the median line. By closing the loops a little and readjusting the appliance, force is exerted to draw the incisors inward.

For the correction of the position of prominent incisors with spaces between them, a device made similar to that seen in Fig. 228 is

Fig. 228.

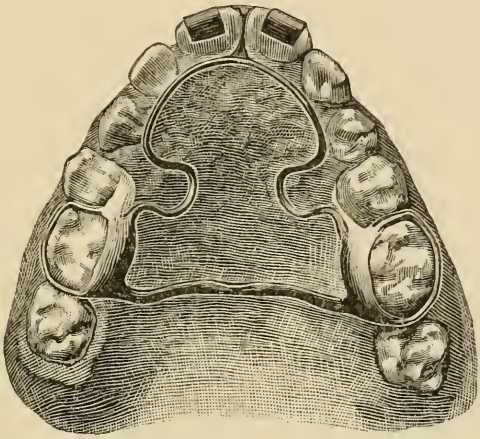

generally convenient and effective. The anchorage consists of a spring-clasp attachment over a molar on either side. In addition, partial-clasps are fitted to the adjoining teeth, with a wire-clasp extending to the distal surface of the last molar and the anchorage portions connected with a palatine base-wire. A spring-wire is bent into a curve or semicircle to rest near the lingual surface of the incisors, extending backward on either side and formed into a U-shaped loop, the loops being located just anterior to the anchorage portion, pointing towards the median line. The ends of the spring are soldered to the partial-clasps with the ends of the base-wire.

A T-piece is made from plate-metal, slightly curved backward and shaped like a bar to cross the fronts of the incisors, with the ends projecting at right angles and bent into hooks to pass over the edge of the teeth to prevent the bar from pressing towards the gum when force is applied. To complete the T, another piece of plate-metal is soldered to the centre of the bar in shape to pass between the incisors and united to the spring. The action of the appliance

is caused by closing the U-shaped loops in the spring, making only slight changes at a time, as too much force is not desirable.

Fig. 229 illustrates a device with a palatine spring base-wire, and a double looped spring for moving inward four upper incisors. It is anchored in the usual manner, with one or more spring-clasp attachments and partial-clasps on each side of the arch. The spring is

Fig. 229.

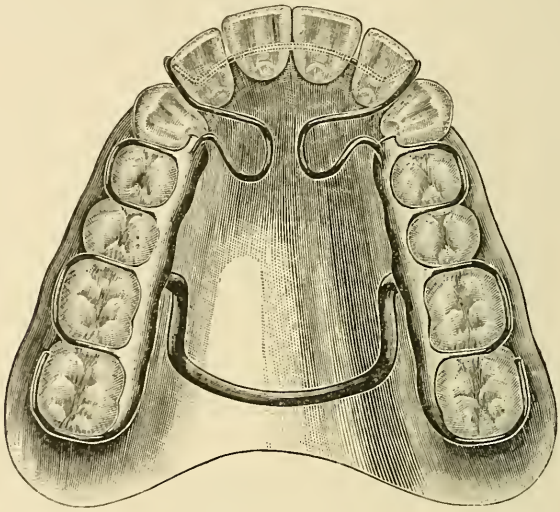

arranged to cross the labial faces of the teeth to be moved and to extend over the arch near the incisive edge at the junction of the lateral incisors and cuspids, where a U-shaped loop is formed and the ends are extended to be attached in the anchorage with the ends of the base-wire. Force is exerted by closing the loops. When required, the spring base-wire is utilized for expanding the arch laterally.

When all of the incisors in either the upper or lower arch are too prominent, with spaces between them, and need to be moved inward to proper line, an appliance as represented in Fig. 230 will usually be found adequate. A lingual base-wire is formed to follow the curve of the arch a little back of the circle it is desired the incisors shall assume when regulated; the ends extending on either side and anchored by partial-clasps and spring-clasp attachments to the teeth in the distal part of the arch. A small spring-wire is soldered to the base-wire at the junction of the right cuspid and lateral, extending forward to the distal surface of the lateral near the incisive

edge, being formed so that it will not interfere with the occlusion. The spring-wire is next bent to extend near the gum line and curved to cross the labial faces of the incisors to the distal surface of the lateral on the opposite side, where it is bent in a similar form to extend over the arch to be united to the base-wire. The portion of the spring passing from the base-wire to the labial side should always extend to the edge of the incisors and thus over the arch, not passing between the teeth, even though there be room for it, as this curve necessarily makes the spring of suitable shape to act on the incisors to move them into line. When force is required, the appliance is removed and the arm of the spring that passes from the base-wire is bent more acutely, causing the labial part of the spring to assume a position closer to the base-wire. If there are spaces be-

Fig. 230.

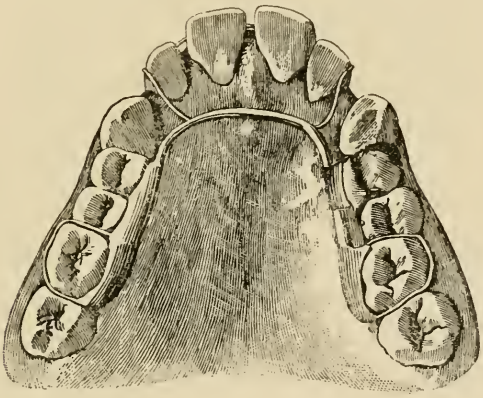

tween the incisors it will be found that as the teeth are moved inward the part of the spring that crosses the labial side will become too long to reach from the distal surface of one lateral to that of the other, on account of their moving towards the median line, closing the spaces. This condition is corrected by making a slight loop in the wire at the median line, which shortens it; or a ring can be made at the gum line in the end of one of the arms that pass over the arch, through which the end of the wire that crosses the labial surface can pass.

In many cases presented for treatment the cuspids need to be moved outward, and the incisors are too prominent, with spaces between them.

Fig. 231 shows an appliance used for the correction of these conditions for Master K., aged thirteen years.

The upper incisors projected forward and closed over the lower lip. A palatine base-wire was formed to cross the arch, the ends

Fig. 231.

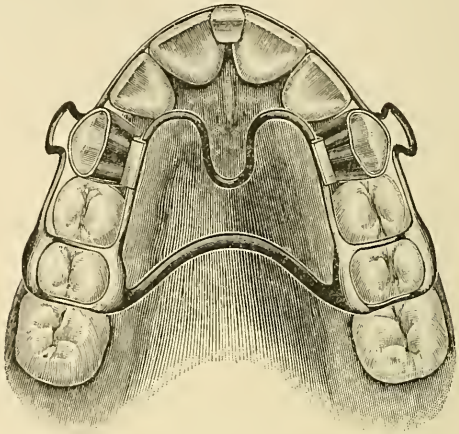

held with spring-clasp attachments over the second bicuspids. For moving the cuspids outward a spring-wire, No. 17 gauge, was bent into three U-shaped loops, the middle loop pointing backward at the median line. The outer sides of the other loops passed under a lug attached to a collar cemented to each of the cuspids. The ends of the spring were attached to the partial-clasps beside the ends of the base-wire. The incisors were moved into line by a semicircular spring shaped to the labial side of them, having a large U-shaped loop formed in it opposite the cuspid on either side, projecting upward under the lip. The free ends extended backward and were attached with solder to the spring-clasps. These attachments were made strong by passing a thin piece of plate-metal under the spring-clasp and spring before soldering. The spring was prevented from slipping upward on the teeth by soldering to it at the median line a thin piece of metal about one-eighth of an inch wide, bent into the form of a hook, to hook over the edge of the central incisors. Both springs were made to act at the same time, opening the loops gradually for moving outward the cuspids, and closing the loops in the semicircular spring slightly, to apply force to the labial side of the incisors for moving them inward. After the teeth

were in position the same appliance was worn several months for retaining them.

When a regulating appliance is continued in use for retaining, the springs should not be allowed to rest heavily, as the slightest pressure would cause movement and final crimping of the teeth.

Fig. 232 represents an appliance used in the case of Master C., aged thirteen years, for moving prominent front teeth inward, and later

Fig. 232.

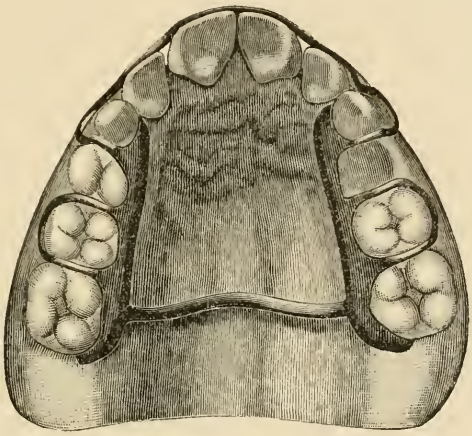

expanding laterally the anterior part of the arch for their continued movement. A strong anchorage was made by forming spring-clasp attachments to the second deciduous molars and partial-clasps on the adjoining teeth, the sides connected with a palatine base-wire. The base-wire crossed rather far back where the arch was sufficiently broad. A semicircular spring with two U-shaped loops was formed to the labial faces of the incisors and cuspids, the loops being shaped somewhat to the contour of the gum under the lip; the distal part passed over the arch at the junction of the cuspids with the first bicuspids, and was joined to the partial-clasps in the anchorage. The arch was expanded laterally by bending outward slightly at intervals the front part of the anchorage portions and at the same time closing the loops in the spring for moving the incisors inward.

An appliance used for regulating a V-shaped arch, expanding it at the position of the bicuspids and flattening the anterior part by moving the incisors inward,* and which has been used for expand-

* Jackson, Dental Cosmos, 1891, p. 1077.

ing the whole arch laterally or for moving outward individual teeth, is illustrated in Fig. 233. It is made by arranging a lingual spring base-wire to follow the inner curve of the arch at the gum line, the ends being united by a spring-clasp attachment for anchorage to one or more teeth on each side. From each anchorage a small wire is shaped to extend over the arch at the junction of the teeth at any desirable location, with the end bent into the form of a hook or eyelet. A straight spring-wire is arranged to cross the labial side of the incisors; its ends are sprung back to the buccal side of the bicuspids, and held in that position by the eyelets or hooks. The arch is expanded laterally by bending outward the ends of the base-wire, and the tendency to straighten of the wire that is sprung around the front of the arch applies force to the labial side of the incisors to move them inward, and at the same time assists the action of the base-wire. If the spring is not well retained on the fronts of the incisors, a piece of partial-clasp metal or wire should be shaped to extend into the depressions underneath it and over the edge, causing pressure on the points desired, and attached to the spring with solder.

Fig. 233.

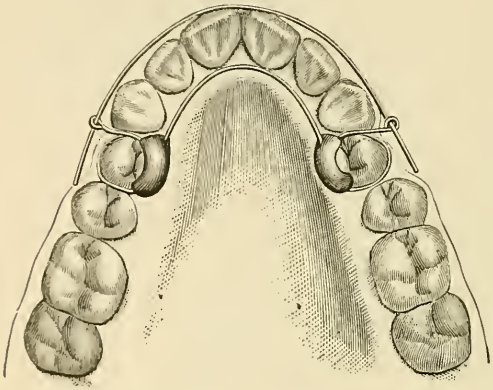

Fig. 234.

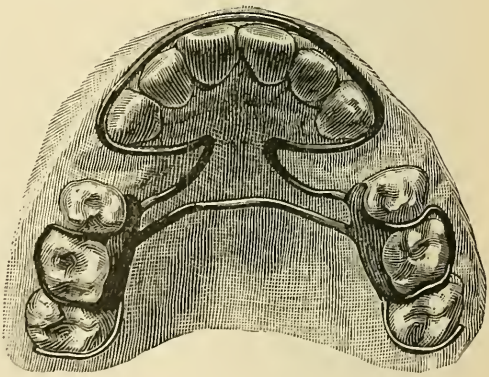

An apparatus that has been used for moving the six front teeth inward at one time, closing the spaces caused by the extraction of the first bicuspids, is depicted in Fig. 234. A palatine base-wire is formed to cross the arch. The ends are anchored with partial-

clasps and spring-clasp attachments, and a wire-clasp on each side extends backward from the partial-clasps to the distal side of the second molars, the latter being applied to advantage for strengthening the anchorage when teeth are only partially erupted.

For moving the incisors and cuspids inward a small-sized spring is formed into a semicircle to cross the labial surface near the gum, then shaped to pass through the spaces back of the cuspids, but not fitting close to them, and formed into a large U-shaped loop on either side, pointing towards the median line, with the ends bent backward to cross the partial-clasps and soldered with the ends of the base-wire.

It will be observed in this case that there are two molars and one bicuspid on each side utilized for anchorage, which in most cases is sufficient, but it is not uncommon for the teeth used for anchorage to be moved forward somewhat when force is applied for moving the six front teeth inward at one time. Usually, therefore, it is the wiser plan to begin the operation by first causing pressure on the central incisors, straightening slightly the semicircular spring at the median line. The pressure on the incisors alone causes them to act as a wedge between the adjoining ones, and less strain is required to actuate all of them, consequently less liability to move forward the teeth used for anchorage.

Two finger springs extending to the labial side of the teeth, one from either side, as illustrated in Fig. 207, is sometimes more easily manipulated. When necessary, to prevent the disturbance of the anchorage teeth, additional anchorage can be gained by the use of a palatine plate, or by supplemental force applied with a cross-bar.

In Fig. 235 is shown a profile view of the features of Master P., aged twelve years, taken from a plaster model. The patient was a mouth-breather, for the relief of which the tonsils and adenoid growths were removed. The upper incisors were very prominent, closing considerably in front of the lower lip and with spaces between them. For their correction, an appliance was first made as seen in Fig. 236, with a palatine base-wire crossing the arch. Spring-clasps were passed over the first molars, and partial clasps on the molars and bicuspids, with wire-clasps extending backward to encircle the second molars for retaining. A spring-wire, No. 19 gauge, for moving the incisors inward was bent into a semicircle to cross the labial side of them near the gum, with a large U-shaped loop formed in

the wire opposite the cuspid on either side. This extended up under the lip and reached from the mesial side of the cuspid to the mesial side of the first bicuspid, where the end passed over at the junction of the teeth to the inner side of the arch to be attached to the partial clasps. This part of the spring should always be curved sufficiently downward to permit it to pass over the arch without causing an upward pressure on the teeth, which would act as a wedge, and would eventually separate them if they were close together; while if there were spaces between the teeth, and the spring was not curved downward enough, it would prevent the teeth being moved entirely together. The loops were closed to give the required force.

Fig. 236.

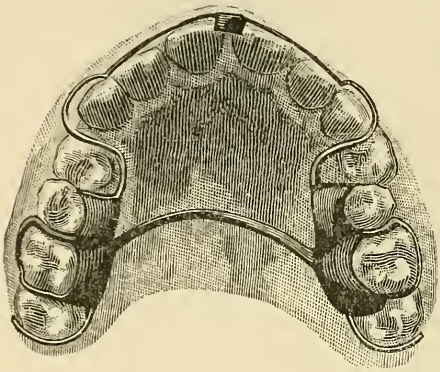

In this case, after the incisors were moved inward, closing the spaces between them, a careful measurement was made with accurate models, and it was found that if the first bicuspids were extracted, there would be just enough space to permit the incisors to be moved inward sufficiently to give a proper occlusion, and to give the features a good contour. Accordingly the first bicuspids were extracted, and the same form of appliance was utilized for continuing the movement of the incisors and cuspids inward. To prevent the teeth used for anchorage from moving forward under the pressure required, supplemental force was applied by the adjustment of a cross-bar and cranial-cap as seen in Fig. 237. (For details of making, see page 97.) The teeth and process were gradually forced inward, causing a good occlusion and permitting the lips to close normally. Fig. 238 shows a model of the improved features of the patient taken within a year from the commencement of the regulation.

Anterior protrusion is usually the result of excessive development. (See Etiology.) When there is a lack of harmony in the prominence or size of the upper and lower arches, they should be equalized. (See Chapter XIX., Receding Lower Jaw.) If it is determined that the arch can be enlarged sufficiently to properly admit the irregular

Fig. 235.

Fig. 238.

Fig. 237.

Fig. 239.

Fig. 240.

teeth, apparatus should be employed as described in Chapter IX., Expansion of the Dental Arch. But when it is found from a careful study of the case that equalizing the arches or expansion is not advisable, space for the correction should be gained by the extraction of one or more teeth, as the first bicuspids. All of the space caused by the extraction is frequently required to reduce the unpleasant prominence. Otherwise, when all of the teeth are retained, the arch is unduly crowded, the contour of the features marred, and the lips drawn, interfering with speech and encouraging mouth-breathing. In this chapter a number of cases are cited in which extraction was employed to good advantage, as verified by the results.

Fig. 239, Master G., aged nine years, shows a case of anterior protrusion with inability to close the lips. There were spaces between the teeth. The incisors and cuspids were moved inward with a metal device made similar to Fig. 236.

In Fig. 240 is illustrated an apparatus for causing supplemental force that is superior in reducing some forms of anterior protrusion. It is usually worn at night. A chin-cap with wire standards supported by a cranial-cap is made as described on page 218. To the teeth to be moved is adjusted a *supralabial bar* hinged to a metal device passing over the teeth (Fig. 241). (See description of making,

Fig. 241.

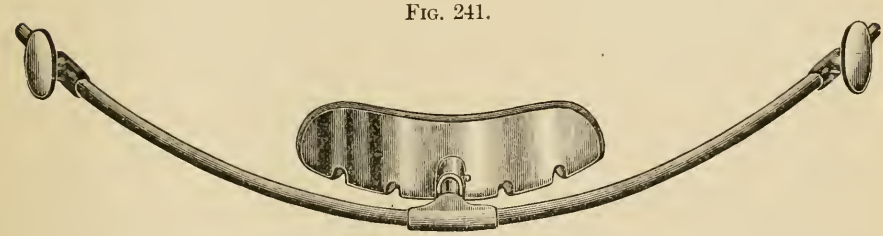

on page 100.) Force is given by small rubber bands passing over the knobs of the bar and knobs of the wire standards. The latter are adjustable for changing the line of traction.

An appliance made by attaching springs in a rubber plate for reducing upper anterior protrusion has its advantages. I have suggested some objections to the anchoring of fixtures with a rubber plate by extending the rubber over the grinding surface of the molar and bicuspid teeth, a method which endangers the occlusion, etc. But there is no doubt that a rubber plate covering the roof of the mouth assists the anchorage for moving incisors and cuspids inward

by the additional resistance it offers in resting against the anterior palatine arch while traction is being caused. The plate is easily removed by the patient for cleansing.

Fig. 242 illustrates a vulcanite plate with finger-springs. I first described this appliance in 1888,* having used it for several years.

Fig. 242.

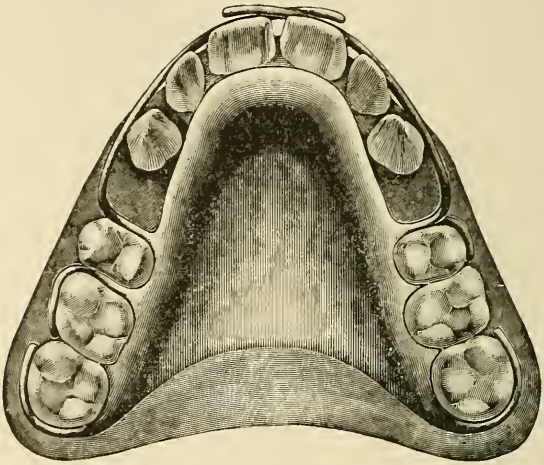

The plate is fitted well to the necks of the teeth, and retained by wire-clasps extending from the rubber around the last erupted molar teeth and by others passing through spaces and around the second bicuspids. When the anchorage is to include molars that are not fully erupted the model back of the molars should be carved, relieving some of the gum portion for the accommodation of the wire-clasps. Sometimes it is an advantage to use a small wire for the clasp, as it can be curved to fit the tooth more accurately, and when required bent upward at a right angle, projecting under the gum to the neck of the tooth. When this anchorage is not sufficient a carefully fitted partial-clasp can be soldered to project under the gum, first bending the wire backward a little. A finger-spring, about No. 18 gauge, is shaped to extend from the plate on either side of the arch, passing close to the mesial surface of the second bicuspid, to the buccal side; it is then bent to follow the gum line across the labial faces of the incisors and cuspids, and left long in order to reach somewhat beyond the median line to mutually support one another.

* Jackson, Dental Cosmos, 1888, p. 510.

The spring-wire for this purpose should be rather stiff, owing to its length, but not too stiff, as a slight pressure will accomplish more than would naturally be supposed by those who have not used spring pressure. A portion of the wire that enters the plate should be flattened to add strength to the anchorage, but the part that extends from the plate should always be round, which permits of changes of form by bending that could not be accomplished by the use of the half-round, square, or flat wire. The anterior edge of the plate opposite the teeth to be moved should be dressed away from time to time sufficiently to let them take a good alignment, and very gradual force applied with the springs. When the teeth are to be moved inward a considerable distance with this form of appliance, the plate should be dressed away only a little at a time, otherwise some of the teeth would be likely to move inward before others, and to take a crimped or rotated position.

The gum does not absorb as readily as alveolar process, and accordingly when the teeth are moved rapidly towards the plate it causes the gum to bulge; occasionally it becomes congested and protrudes below the edge of the plate. Either the regulation should proceed more slowly or the gum be snipped away with curved scissors.

Fig. 243.

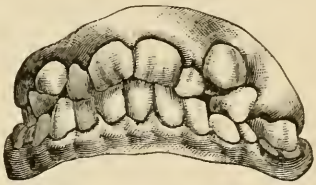

Fig. 243 illustrates the position of the teeth of a boy aged twelve years. The incisors and cuspids in the upper arch were much too prominent and so crowded as to require the extraction of the first bicuspids to permit the teeth to be moved to articulate with those of the lower arch (Fig. 244). A model was made and trimmed accurately at the necks of the molars and second bicuspids that were used for anchorage. A vulcanite plate with finger-springs was employed. Fig. 245 shows the position of the springs of the appliance and the occlusion of the teeth when the regulation was nearly completed. The same apparatus was used for retaining, the finger-springs being shaped to rest very lightly against the teeth.

It is seldom necessary to make any attachment to the ends of the springs to hold them in a given position on the labial side of the incisors. In beginning the operation, when the incisors incline considerably forward, the springs are sometimes caused to slide towards the gum. In such a case a narrow piece of plate-metal bent into

an S-shape, with one end passed over the edge of the incisors and the other above the springs, will hold them in proper position. Its use is generally required for a short time only, but the metal can be soldered to one of the springs if desired.

Fig. 244.

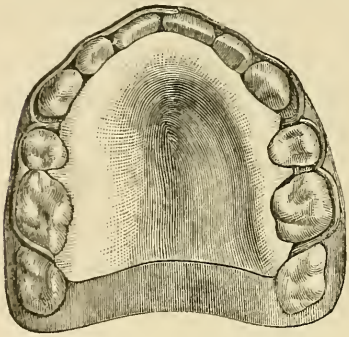

Fig. 245.

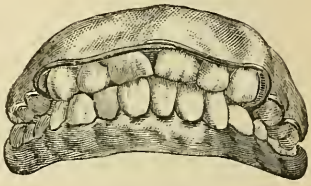

If the spring presses too hard on any particular tooth, it can be remedied by changing its shape. The pressure of the springs should be relieved when the teeth are in good alignment, as at this stage of the regulation it requires but the slightest force to continue movement. If force is continued with the springs, the teeth will be pressed

Fig. 246.

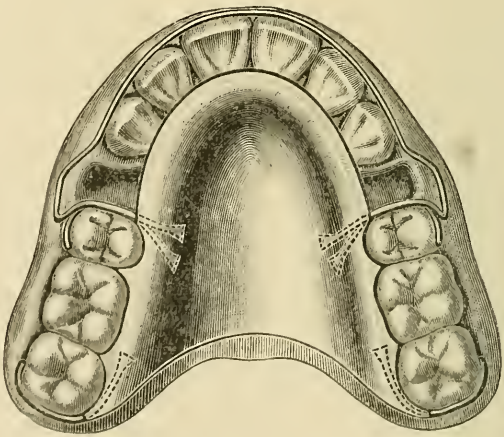

against the rubber on their lingual side, and being somewhat wedge-shaped, they would be depressed in their alveoli, shortening them.

These suggestions are also applicable when a single spring is used in this manner or when a semicircular spring with U-shaped loops similar to Fig. 246 is employed. The latter is often preferred in

correcting anterior protrusion. The plate is anchored with wire-clasps. To the sides are attached the ends of a looped semicircular spring. The spring is shaped to rest on the labial side of the teeth to be moved, the loops being arranged to project upward under the lip opposite the cuspids or first bicuspids. Force is exerted by closing the loops slightly at a time. Usually the ends of the spring are attached in the rubber, but when desired the ends can be bent into hooks and hinged either to the plate, to a base-wire, to spring-clasps, or to wire-clasps.

When the lateral incisors are too prominent and overlap the central incisors, it is sometimes necessary to make space for their correction. Fig. 247 shows an appliance for moving inward

Fig. 247.

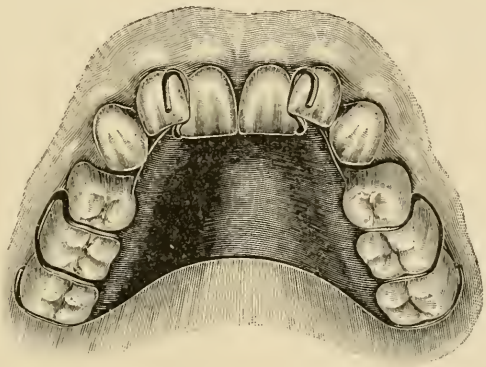

and rotating lateral incisors. In the case illustrated the first bicuspids were extracted and the cuspids moved backward into the spaces by the force applied to the laterals. A palatine plate is well anchored to the distal molars. Spring-wires are arranged in the anterior part of the plate to extend over the arch at the edge and junction of the central and lateral incisors to reach near the gum, where each of the springs is bent back on itself, forming a loop with the ends terminating on the mesio-labial side of the laterals. Force is caused by bending the loop portion of the springs laterally backward from time to time. An appliance with springs formed in this manner can be used for retaining the incisors, moving them laterally, or rotating them by bending the free end of the springs as required.

The following illustrate a few typical cases of anterior upper protrusion before and after correction.

Fig. 248. Miss R., aged fourteen years. Case of hereditary prominence of the upper arch and history of thumb-sucking. The first upper bicuspids were extracted and a palatine plate with a semicircular spring was inserted for reducing the prominence. The lower incisors and cuspids needed to be depressed in their alveoli, and a plate thickened in its anterior portion similar to Fig. 338 was employed. This depressed the lower incisors, and at the same time the upper incisors were moved inward by closing the U-shaped loops in the semicircular spring, dressing away the anterior part of the plate from time to time. For additional force, a cross-bar like Fig. 237 was worn at night for about six weeks. Fig. 249 illustrates the improvement in the features in five months.

Fig. 250. Miss S, aged fourteen years. Excessive anterior upper protrusion. Affected with nasal stenosis since childhood. An operation by a rhinologist improved the breathing. The first upper bicuspids were extracted, and a palatine plate with a semicircular spring was employed for moving the incisors and cuspids inward (Fig. 246). The movement was assisted by the application of a cross-bar at night. Fig. 251 represents the change in the features in seven months.

Generally, in cases of mouth-breathing, the lips are thick; and after a rhinological operation to correct the breathing, and orthopædic treatment for the correction of the prominence, it sometimes takes a few months for the lips to settle against the teeth and to give a pleasing expression.

Fig. 252. Miss N., aged fourteen years. The first upper bicuspids were removed and a palatine plate (Fig. 246) employed. Supplemental force with a cross-bar (Fig. 237) was applied at night. Fig. 253 illustrates the improved features in three months.

Fig. 254. Master H., aged thirteen years. The first bicuspids were extracted, and the irregularity corrected by a palatine plate and finger-springs like Fig. 242. Supplemental force with the cross-bar was not required. In Fig. 255 is seen the resultant improvement in the features.

Fig. 256. Miss B., aged eleven years. The upper incisors were prominent, resting on the lower lip with no spaces between the teeth. The first bicuspids were extracted and the incisors and cuspids moved inward by a palatine plate and finger-springs. Fig. 257 shows the improved condition in three months.

Fig. 248.

Fig. 249.

Fig. 250.

Fig. 251.

Fig. 252.

Fig. 253.

Fig. 254.

Fig. 255.

Fig. 256.

Fig. 257.

Fig. 258.

Fig. 259.

Fig. 260.

Fig. 261.

Fig. 262.

Fig. 263.

Fig. 264.

Fig. 265.

Fig. 266.

Fig. 267.

Fig. 258. Miss G., aged fourteen years. Anterior protrusion. The first bicuspids were removed and the irregularity was corrected by a palatine plate and semicircular spring. In Fig. 259 is shown the change in the features in five months.

Fig. 260. Mr. C., aged seventeen years. Mouth-breather. Case of marked anterior protrusion. Irregularity corrected with a palatine plate similar to Fig. 246. Fig. 261 shows the improved features.

Fig. 262. Miss P., aged fourteen years. The first bicuspids were removed, and the protrusion reduced with a palatine plate and semicircular spring, as illustrated in Fig. 246, supplemental force being given by a cross-bar. Fig. 263 illustrates the improved condition of the features in five months.

Fig. 264. Master W., aged twelve years. Spaces between the teeth. Extreme protrusion, with inability to close the lips. The irregularity was corrected by a palatine plate with a semicircular spring. In Fig. 265 is shown a cast of the features taken within four months.

Fig. 266. Master N., aged twelve years. Upper arch prominent with receding lower arch. The lower incisors were depressed and moved outward by means of a thickened palatine plate, as shown in Fig. 337, after which the upper incisors were moved inward by a plate and semicircular spring (Fig. 246). Supplemental force was applied by a cross-bar.

Fig. 267. Miss S., aged eight years. Mouth-breather with nasal stenosis. Extreme prominence of upper arch. In occlusion, the distance from the lingual side of the upper incisors to the labial side of the lower incisors measured five-eighths of an inch. The breathing was improved by a rhinological operation. In correcting the irregularity, the first deciduous molars and the unerupted bicuspids were extracted. Force was exerted by a semicircular spring attached in a thickened palatine plate similar to Fig. 338. Supplemental force with a cross-bar was applied at night and several hours during the day.

Fig. 268. A boy aged fourteen years. This case was presented with models and appliances before the Brooklyn Dental Society in 1889. The teeth in the upper arch were very much crowded, and protruded far beyond those of the lower, with the lateral incisors projecting farther than the centrals, and all of them needing to be rotated. The teeth in the lower arch were regular in their labial

curve, but the incisors were on a much higher plane than the cuspids and bicuspids, and impinged upon the soft tissues of the upper arch.

The teeth being much crowded, the first upper bicuspids were extracted, which gave room for moving the cuspids and incisors inward, to articulate with the lower ones.

Fig. 268.

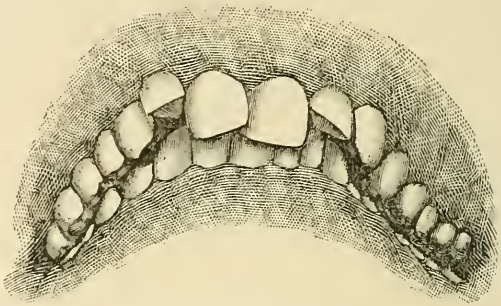

Fig. 269. On June 19 a vulcanite palatine plate was inserted, thickened in its anterior portion, and fitting well the necks of the molars and bicuspids. The plate was anchored with wire-clasps, the ends of which were flattened to retain them in the vulcanite.

Fig. 269.

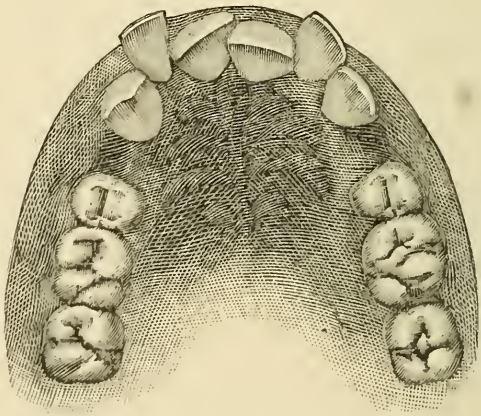

The free ends were shaped to clasp a molar and bicuspid on each side of the arch, with the anterior edge of the plate shaped into a smooth semicircle somewhat back of the incisors. Two finger-springs of German silver extended from the plate, one just in front

of each of the second bicuspids, to the buccal side, where the ends of both were bent forward to follow the gum, terminating on the mesio-labial surface of the prominent lateral incisors. The ends of the springs were curved inward towards the plate to give pressure

Fig. 270.

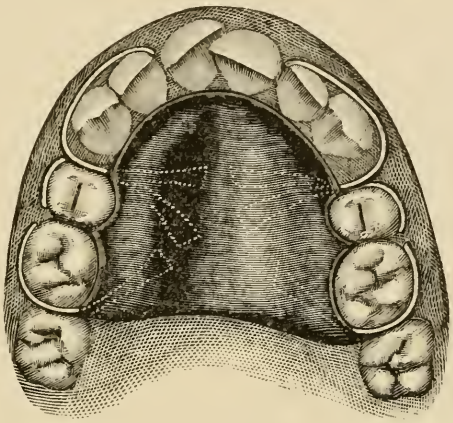

for moving the lateral incisors and cuspids backward in the circle. Fig. 270 represents the plate and the extent of the movement of the teeth on July 8. A similar plate anchored to all of the molars and the bicuspids, with longer finger-springs extending to the front of the

Fig. 271.

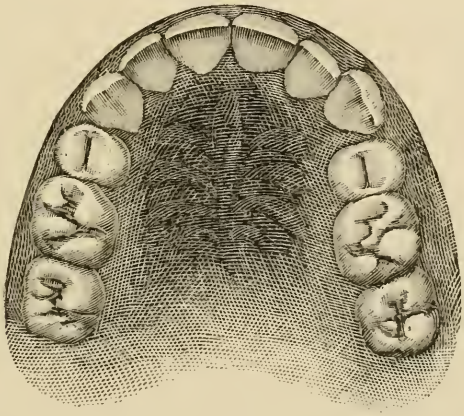

arch, lapping by one another as seen in Fig. 242, was inserted on July 22, and the teeth were moved to the position seen in Fig. 271 on December 19. The force of the springs on the labial side of the

incisors moved them inward; at the same time they were pressed against the edge of the plate, which rotated and evened them. The plate was dressed away from time to time sufficiently to admit of their inward movement.

The teeth were retained with a bar of half-round gold wire, shaped to cross the labial faces of the incisors and cuspids, with the ends of the bar anchored to the second bicuspids, as shown in Fig. 511. Each of the teeth rotated was held firmly to the bar by passing a small silver wire either side of it, through the interdental space to the lingual side, and back again on the opposite side of the tooth, where it was fastened to the bar.

Fig. 272 illustrates the case of a young man eighteen years of age, whose upper arch was inclined to be V-shaped, with the teeth protruding about one-half inch beyond the lower ones.* The projecting teeth were only partially covered by the upper lip, giving an unpleasant expression.

Fig. 272.

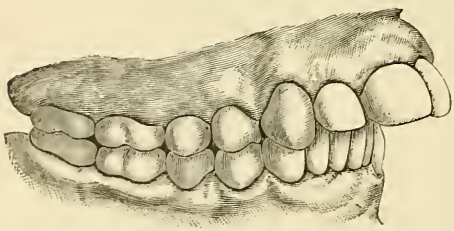

The first upper bicuspids were extracted, and a vulcanite plate with finger-springs inserted. The plate (Fig. 273) was anchored with wire-clasps to the molars and bicuspids. For moving the incisors and cuspids inward, two curved finger-springs extended from the plate, one on either side to the front of the arch, with the ends passing each other as far as the width of one of the incisors. As the teeth did not require to be rotated, a portion of the anterior part of the vulcanite was dressed away, but not so much as to interfere with the anchorage. Constant force was exerted on the teeth by bending the ends of the springs nearer to

Fig. 273.

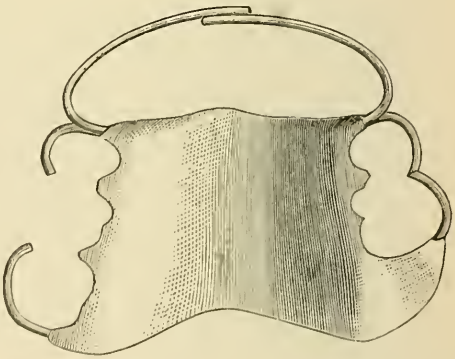

* Wadsworth, Dental Cosmos, 1891, p. 29.

the plate, the increase being made about twice a week. The teeth were moved to articulate with the lower ones, as seen in Fig. 274, in about three and one-half months.

The space between the cuspid and second bicuspid in this case was not fully closed, which illustrates the necessity of caution as to the removal of a first bicuspid where it is found from measurement that after regulation the cuspid will occupy only a portion of the space. However, the removal of the first bicuspid is usually recommended. If the remaining space be excessive, the second bicuspid should be moved forward and retained, and the molar teeth generally follow.

Fig. 274.

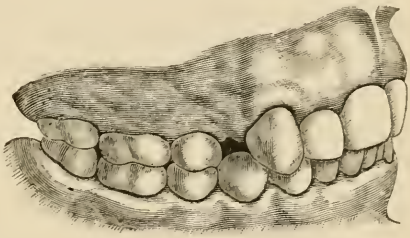

I do not usually encourage the extraction of the second bicuspids or the first molars where it can be avoided, even though the conditions indicate it, as when either of the latter are removed it is more difficult to secure sufficient anchorage for moving the front teeth inward. Fig. 467 illustrates a case in which an operator extracted the second upper bicuspids with the intention of lessening an anterior protrusion of the arch. The conditions were not improved by the extraction, for the molars gradually moved forward in the circle, taking up much of the space.

In correcting these conditions it was found advisable to first move backward the cuspids and first bicuspids, and later to move the incisors inward. The anchorage was gained with a vulcanite plate covering the palatine arch, fitting well to the incisor and molar teeth, with wire-clasps passing around the second molars. The lateral side of the plate opposite the bicuspids and cuspids was smoothed to permit their movement. Finger-springs were anchored in the plate, one on either side; they were shaped to extend close to the first molars near the grinding surface, through the space to the buccal side, and bent forward, terminating in a curve on the mesio-labial surface of the cuspids. The action of these springs curved towards the plate gradually moved the cuspids and bicuspids backward, causing the latter to rest in contact with the molars.

After these teeth were in position a similar plate was employed with finger-springs extending to the front of the arch for moving the

incisors inward. The springs passed from the plate to the labial side just in front of the cuspids. Owing to the recent moving of the cuspids and bicuspids, it was considered advisable to assist the anchorage with a cross bar and cranial-cap, as shown in Fig. 237, it being worn regularly at night.

When on account of decay or other cause it is found necessary to extract the first molars in cases of anterior protrusion in either arch, it becomes necessary to move backward both bicuspids on each side before moving inward the anterior teeth. This can be accomplished with apparatus as illustrated in Figs. 470–475.

Fig. 275 illustrates the case of Mr. K., aged twenty-two years. The upper incisors projected forward of the lower ones five-eighths

Fig. 275.

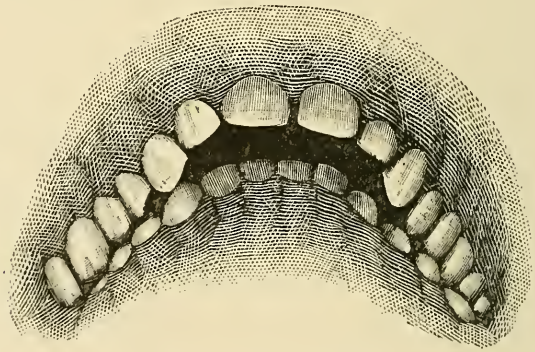

of an inch by measurement. The distance was determined by passing between the upper central incisors a thin piece of metal with the end pressed against the labial side of the lower incisors. The metal was then marked even with the lingual surface of the upper ones. The upper incisors closed in front of the lower lip, which gave the effect of extreme prominence of the upper jaw and recession of the lower. The plane of the lower incisors was much higher than that of the bicuspids and molars, and in occlusion they impinged against the soft tissues of the upper arch. This condition is common, and should be corrected by depressing the lower incisors, usually before moving the upper incisors. For this purpose a plate covering the palatine arch, anchored with wire-clasps and thickened in the anterior portion, is employed (Fig. 338). The pressure caused on the lower incisors by the natural action of the jaws in mastication and swallowing gradually forces them more

deeply into their alveolar sockets, and at the same time the molars and bicuspids, being relieved from the pressure of occlusion, become elevated. Generally the plate is required to be worn several months for this purpose. When the lower incisors are depressed sufficiently the upper ones are forced inward with the labial spring.

In this case it was found that if the lower incisors were depressed and moved outward somewhat it would improve the contour of the features, and the extraction of but one bicuspid in the upper arch would be required. Accordingly a first left upper bicuspid was removed, and an appliance with an inclined plane and springs inserted. The incline was made rather steep to force the lower incisors outward and at the same time to depress them. In place of the semicircular spring, two curved finger-springs extended to the anterior part of the arch. One of the springs passed through the space caused by the extraction of the first bicuspid, and the other extended from the plate on the opposite side over the arch at the junction of the cuspid and first bicuspid. Slight changes only at a time should be made in the shape of the spring, the too rapid movement of the teeth being objectionable.

Fig. 276 illustrates the general appearance of the teeth after the regulation was completed. They were retained several months by

Fig. 276.

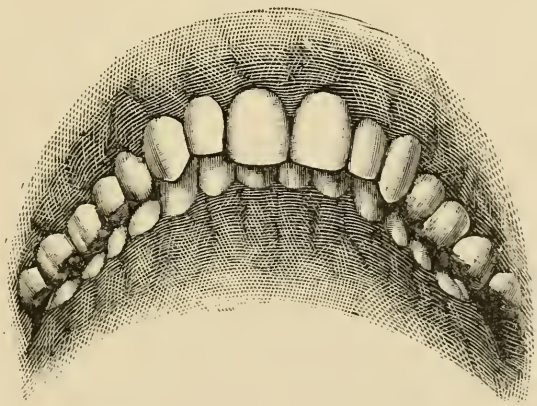

a gold retaining device, made by forming a round wire to follow the labio-buccal surface of the teeth near the gum line. The ends were attached by a spring-clasp attachment for anchorage to the second bicuspids (Fig. 485).

When upper or lower incisors appear too long, they can be depressed in their sockets (see Chapter XV., Incisors, To depress), or dressed with a carborundum stone. (See Shaping the Teeth, page 297.)

Fig. 277 illustrates the case of a young man sixteen years of age, as presented for treatment. A first right upper bicuspid had been

Fig. 277.

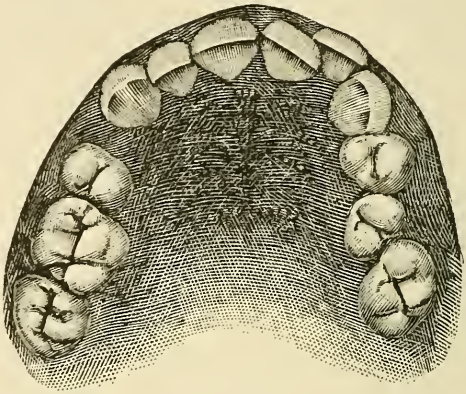

injudiciously removed to relieve over-crowded incisors. The left upper lateral still remained very prominent, with insufficient space, and required either the removal of a bicuspid on the left side of the arch, or the movement of the incisors and cuspid towards the right

Fig. 278.

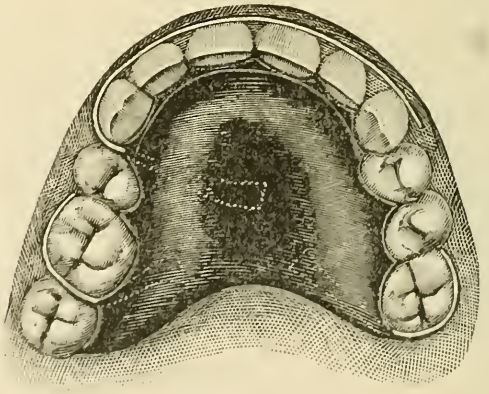

to admit it in the circle. The latter method was adopted, as it would save the extraction of a tooth, and the slight change in the median line would not be especially noticeable.

A vulcanite plate was made (Fig. 278) covering the palatine arch, fitting well to the necks of the teeth, and a German-silver wire was carried from it on each side to surround a molar to assist the anchorage. One end of a semicircular spring was anchored in the vulcanite. It extended through the space to the buccal side close to the mesial surface of the second right bicuspid, and was then bent forward to follow the labial faces of the incisors at the gum line and to cross the cuspid on the opposite side of the arch. It was so shaped as to exert pressure on the prominent lateral. The front edge of the vulcanite was dressed away to correspond with the position the teeth were to assume when regulated. The action of the appliance was controlled by bending the end of the spring closer to the plate from time to time. This procedure wedged the lateral into place, forcing the incisors and cuspid to the opposite side of the arch, and filling the space of the absent bicuspid.

The patient was a student in a college at some distance, and would not return under three or four months. He was instructed

Fig. 279.

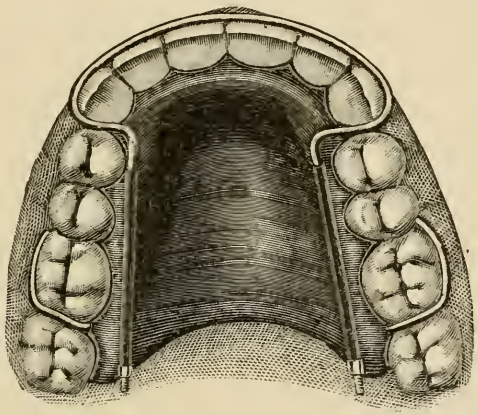

to readjust the spring by bending it a very little, not oftener than once in ten days or two weeks.

The teeth were moved to the position as seen in the figure in a limited time. The same device was continued in use as a retainer, the pressure of the spring being relieved.

Fig. 279 shows an appliance that is serviceable in some cases for moving inward the upper incisors. It is made by fitting a palatine vulcanite plate to the necks of the molars and bicuspids, to which it

is anchored with wire-clasps. The front edge of the plate is formed into a semicircle. A tube of German silver or other metal is roughened and arranged in the plate on either side of the arch, extending from the first bicuspid, and following the lingual side of the teeth to the back part of the vulcanite. A small spring-wire is then fitted to the labial side of the teeth to be moved; its ends are curved to extend over to the lingual side, back of the cuspids, where they are again bent nearly to a right angle, so as to pass through the tubes in the plate. The ends of the spring are provided with a thread and nut, which are turned to adjust the appliance. The anterior edge of the plate is dressed away from time to time to conform to the desired movement. A removable spring in connection with a plate has been used in many combinations.

Fig. 280 illustrates a case with the upper incisors too prominent, and a narrow arch, which required expansion to admit the incisors

Fig. 280.

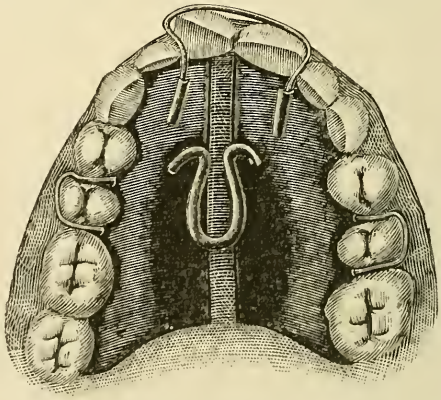

to proper line. The appliance used for expanding the arch was a vulcanite split plate covering the palatine contour; it was connected with a U-shaped spring, the plate being anchored with spring-clasps over a bicuspid on each side. In the front of each of the lateral halves of the plate a small tube was attached, resting longitudinally, for the purpose of supporting a spring. The tubes were made of a narrow piece of thin plate-metal; the ends were left one or two lines in length, and bent outward to strengthen their attachment in the vulcanite. A small-sized spring-wire was formed to cross the labial side of the incisors passing near the gum, extending to the distal side of those to be moved. The ends were bent to pass over the arch

Fig. 281.

Fig. 282.

Fig. 283.

Fig. 284.

at the junction of the teeth near the edge, extending backward, following the contour of the plate, and bent sharply forward opposite the distal end of the tubes, so as to hook into them. Sometimes it is preferable to cement the ends of the springs in the tubes, having them enter from the front. When the arch was expanded laterally, force was applied to move the incisors inward, bending the side-arms of the spring more acutely where it passed over the arch.

The length of the arms of the spring can be shortened at any time by rebending the ends that enter the tubes, or recementing them.

Thumb-Sucking a Cause of Upper Protrusion.—The habit of sucking the thumb or fingers is begun early and is sometimes continued after the eruption of the permanent teeth, producing upper anterior protrusion. This habit is occasionally practised until the age of maturity.

The writer treated an interesting case for an intelligent girl, aged thirteen years. The habit had become extremely embarrassing to the patient and her parents, as she was accustomed to resort to it unconsciously at any time. The upper incisors had become very prominent, and the lower jaw receded. Many methods had been employed to break up the habit, but none were effectual. With the full agreement of the patient, a heavy leather thumb-cot, with a serrated leather strip attached, was applied to the thumb and held in place with a lock-chain bracelet, as seen in Fig. 281, and the key carried by the mother. By this arrangement the habit was soon broken, and the teeth were regulated in the usual manner.

Similar cots can be used on the fingers when required, or an entire glove worn. With young patients the habit can generally be broken by bandaging the hand, or by bitter applications to the fingers or thumb involved.

Double Protrusion or True Prognathism.—In double protrusion both the upper and lower arches are too prominent. An apparent double protrusion is brought about in some instances by too short a bite, the back teeth being depressed in their sockets to such an extent as to cause the lips to pout. This is usually corrected by opening the bite.

In Fig. 282 is illustrated the case of Miss K., aged twelve years, in which both the upper and lower arches were unusually prominent. The upper incisors rested on the lower lip, the lips being closed with difficulty. To improve the facial line and permit the natural

closure of the lips required the inward movement of the incisors and cuspids with the process.

To get space for their correction the first upper and lower bicuspids were extracted. A palatine plate with curved finger-springs (Fig. 242) was inserted in the upper arch, and a metal appliance with similar springs (Fig. 207) adapted to the lower arch. Continued pressure was exerted on the labial faces of the incisors and cuspids with the springs. Supplemental force was applied to the teeth of the upper arch by means of a cross-bar device, as shown in Fig. 283. The latter was worn regularly at night, and as many hours as convenient during the day. As the upper incisors were forced inward they came in contact in occlusion with the lower incisors, giving additional pressure, which assisted in moving them inward. The movement of the teeth and process in this manner improved the facial line and produced a pleasing expression (Fig. 284).

In double protrusion, when the incisors project beyond the lips, it generally becomes necessary to depress them in their alveoli. Fig. 285 shows the features of Master A., aged eleven years,—a case requiring the depression of the incisors and the reduction of the extreme prominence. (See Chapter XV., Incisors, To depress.)

To get space for the reduction of anterior protrusion, extraction of some of the teeth is generally required. Usually the bicuspids are chosen ; but sometimes, owing to the poor structure of the first molars, it is advisable that they be removed rather than either the first or second bicuspids, even though the extraction of the molars lessens the anchorage and makes the regulating more difficult. In Fig. 469 is illustrated a case of double protrusion. The first upper and lower molars, being defective, were extracted. The incisors, cuspids, and bicuspids were forced backward closing the spaces. Owing to the weakened anchorage from the loss of the first molars, special apparatus was necessarily devised for reducing the prominence of each arch. (See description accompanying Figs. 469–476.)

Double protrusion is not infrequently accompanied with a prominent lower jaw and thick lips, as in the case of Miss D., aged ten years. The incisors protruded beyond the lips, which were closed with difficulty, and the lower jaw was gradually becoming more prognathous. A rhinological operation improved the breathing. In addition to appliances in the mouth for reducing the promi-

Fig. 285.

Fig. 286.

nence of the teeth and process it was found necessary to employ supplemental force.

In Fig. 286 is illustrated the apparatus used for this purpose,—a chin-cap, a supralabial, and an infralabial bar.

The chin-cap and wire standards, supported by a cranial-cap, is made as described on page 167. To the metal on the band of the cap on each side is fastened one end of a long tube extending downward in front of the ear into which the wire standard is made to pass. Near the lower end of the tube is attached an adjustable knob opposite the lobe of the ear for the attachment of the supralabial bar; two others are adjusted to the standard, one a little below the end of the tube for the attachment of the infralabial bar, and the other at the angle of the standard, for the attachment of an elastic from a suspender passing below the ear to the back part of the cranial-cap. Over this knob and the knob on the tube is attached another elastic. The force of these elastics causes upward and backward tension on the jaw. The infralabial bar is made as illustrated in Figs. 213 and 214. The supralabial bar is made in a similar manner by fitting to each of the teeth to be moved a narrow strip of plate-metal, bending it over the edge and shaping it to rest on the labial and lingual sides. On the labial side of the teeth the metals may be curved to pass over the spring of the apparatus worn in the mouth, or left straight to pass underneath it. After the strips of metal are arranged on each of the teeth on the model as desired, a wire, No. 12 gauge, is curved to cross the metals on the labial side near the gum, with the ends bent downward and forward to pass between the lips near the corners of the mouth, and again bent upward and backward to rest over the cheeks, forming arms. The wire is then soldered to the strips of metal, and a knob or button is attached to each of the arms. If preferred, the supralabial bar can be made as illustrated in Fig. 241, with a cap passing over the teeth (see description in connection with 71, *c*), to which the bar is pivoted.

For causing force, rubber bands of suitable tension are hooked over the knobs on the bars and the adjustable knobs on the standards.

When the upper teeth lap well over the lower ones, force with a supralabial bar is sufficient for moving inward both the upper and lower teeth if there is space for their movement.

CHAPTER XIII

INCISORS, TO MOVE LATERALLY

The lateral movement of teeth is required to close interdental spaces, to improve occlusion, to cause space for erupting teeth, or space for the regulation of teeth. When there are abnormal spaces between the incisors, it mars the personal appearance and interferes with pronunciation; and the malposition of the incisors sometimes prevents the eruption of the adjoining teeth.

In Fig. 287 is illustrated the case of a girl seven years of age. The permanent upper central incisors were erupted with a broad space between them, occupying nearly the position of the deciduous laterals, the roots of which had become absorbed, so that the crowns came away at about the same time as the deciduous central incisors. In such a case it is generally essential that the permanent incisors be moved to proper position before being fully erupted, and retained, as the alveolar sockets are then large, and the process of bone not being deposited around the necks of the teeth, they can be brought together more easily. Their movement at this time is less liable to move the ends of the roots in an opposite direction, which would interfere with the progress of the already crowded non-erupted permanent lateral incisors. By drawing the central incisors together, the laterals would have the necessary space for eruption, and be more likely to take a regular position in the circle of the arch.

Fig. 287.

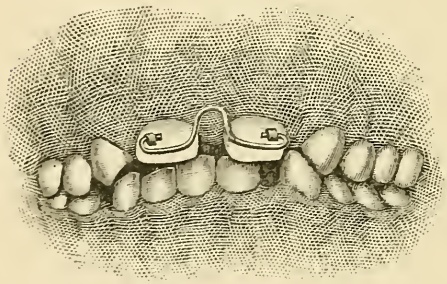

At this stage of the eruption, the teeth can be moved so easily, that there is an inclination on the part of the operator to move them more rapidly than is wise. A simple device for their correction is made by cementing to each of the incisors a collar with an eyelet, short tube, or pin, soldered in suitable position on the labial surface, usually near the distal side. A small spring-wire is bent into

a U-shaped loop, arranged to point upward and rest at the median line between the gum and the lip. The width of the loop is made a little broader than the space between the teeth to be moved. The ends of the spring are bent outward to a horizontal line to pass beneath and to the outer side of the eyelets soldered to the collars, where the ends of the wire are again bent upward and back on itself to hook into the eyelets or tubes, or encircle the pins described. It will be seen from the figure, that by removing the spring and closing the central U-shaped loop slightly from time to time, steady force will be caused for moving the incisors together.

The same device can be continued in use for retaining, or a small wire can be passed through the tubes or eyelets, with the ends bent downward. When pins are used in place of eyelets on the collars, a small wire ligature can be passed about them.

In the present case the teeth were retained by fitting to each of them a narrow platina-gold collar, united at the median line (Fig. 501) and well cemented to the teeth, which was worn until the lateral incisors were erupted. The device I have described is also used for separating or rotating the central and lateral incisors by changing the form of the ends of the spring.

When the incisors are twisted inward the tubes or eyelets can be attached to the collars near the median line, and the ends of the spring lengthened to pass through them. Change the spring from time to time by bending the ends outward to cause pressure. For other forms of springs and their attachment suitable for the lateral movement of teeth, see Figs. 305–309, 329, etc.

Dr. W. H. Jackson utilizes a very small-sized spring-wire for drawing together and rotating upper incisors, forming the wire into a U-shaped loop to rest over the interdental space as illustrated in the figure, and shaping the ends of the spring to cross the labial side and to pass around the incisors near the gum, once or more than once to grasp them. The spring is removed and the central loop closed from time to time for applying force.

Fig. 288 shows the form of an appliance that I used in the case of a girl aged seven years, for forcing together two upper central incisors with a broad space between them, at the same time causing room for a crowded erupting lateral incisor that was rotated inward.

A second deciduous molar on each side was chosen to anchor the ends of a lingual base-wire. Just back of the space between the

central incisors a small spring-wire was soldered to the base-wire, its ends extending to the distal and labial sides of the incisors in the form of arms. From time to time the shape of the arms were changed by bending them to move the incisors together, thus closing the space and giving abundant room for the proper eruption of the lateral incisors. The spring did not clasp the fronts of the teeth firmly, because, the incisors being of wedge shape, this would have a tendency to depress them in their sockets.

Fig. 288.

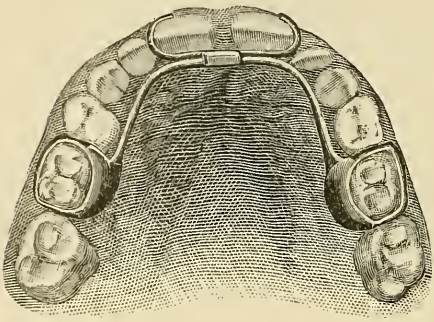

If the permanent lateral incisors are erupted, the arms of the spring-wire described should be bent in the form of a loop to extend over to the labial side, at the junction of the central and lateral incisors near their edge, as illustrated in Fig. 230. With this style of appliance it is not necessary to cement collars to the teeth to retain the spring.

When the incisors are too prominent, with spaces between them, it is sometimes an advantage to construct an appliance with the body of the spring on the labial side, as shown in Fig. 477.

The device illustrated in Fig. 289 was used for correcting the position of the teeth in the upper arch for a young lady aged twenty-three years. The lateral incisors had never made their appearance and the cuspids had assumed a rather prominent position, with a broad space between them and the central incisors. A lingual base-wire, No. 14 gauge, was formed and anchored in the usual manner. A spring-wire was united to the base-wire at the median line and curved backward, with the ends extending to the labial side of the cuspids in the form of arms, the action of which moved the cuspids into the position of the lateral

Fig. 289.

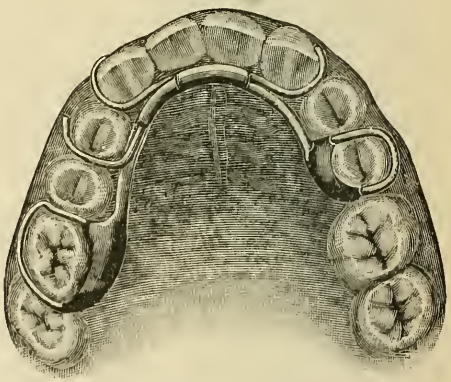

incisors. Another spring in the form of an arm was attached to the base-wire and extended to the distal and buccal side of the first right bicuspid for moving it forward and inward. The same appliance was used several months for retaining.

Not infrequently cases are presented for correction—either the child or adult—where from the history it is learned that the incisors are gradually moving farther apart. This may result from an abnormal developing frænum, excessive or continued intermaxillary development, hypertrophy of the tongue, or from an erupted or non-erupted supernumerary tooth. When from the latter, it should be removed early; if from an over-developed frænum, with its attachment extending through the interdental space at the median line, the frænum should be operated upon.

In this, as in some other forms of irregularity described, retaining the teeth is of more importance than the method of moving them; as, if the same influences exist after the teeth are regulated, and they are not permanently retained, they are likely to return to their former position.

Dr. Tomes and other writers have described methods of moving irregular teeth with the fingers by constantly pressing on them in the direction it is desired they shall move. It is difficult to estimate

Fig. 290.

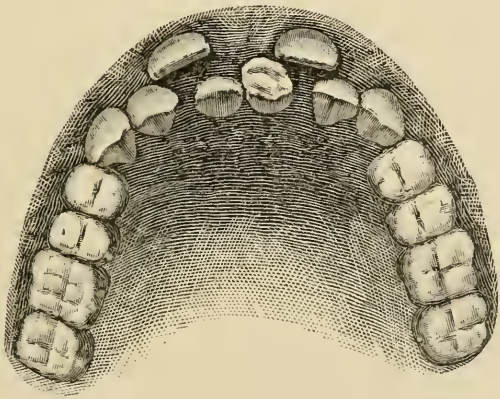

the value of finger manipulation in any especial case of irregularity, but it is remarkable what results can be obtained by perseverance.

Fig. 290 illustrates an irregularity that was corrected with finger-pressure in the case of a boy aged fifteen years. Two large super-

numerary teeth occupied the position of the upper central incisors. The lateral incisors were in their normal position; the central incisors were in front of them, with a space about one-fourth of an inch between them, and lapping somewhat on to the supernumerary teeth.

The supernumerary teeth were removed, and the lad was instructed to press together and inward continuously with the thumb and

Fig. 291.

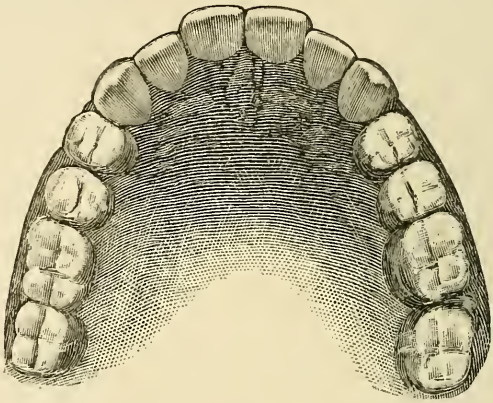

finger on the distal sides of the centrals. In about twenty months, when he was seen again, they were moved to the position shown in Fig. 291.

Several methods of forcing the roots of the teeth towards each other at the same time the crowns were being moved have been

Fig. 292.

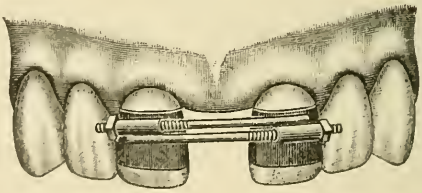

described. I have found this to be necessary in but a few of the many cases corrected.

Fig. 292 illustrates a device for causing the lateral bodily movement of the incisors. To the incisors are cemented broad collars. Two threaded bolts with nuts are attached on the labial side, one to each of the collars, arranged to run parallel and to pass through a

tube on the opposite collar. The nuts are adjusted and turned a little at regular intervals for causing the required force. For further details in making, see Chapter XVII. (Incisors, to move Bodily).

Fig. 293 shows the result, in the case of Miss F., of the too early extraction of the first right upper deciduous molar by an injudicious

Fig. 293.

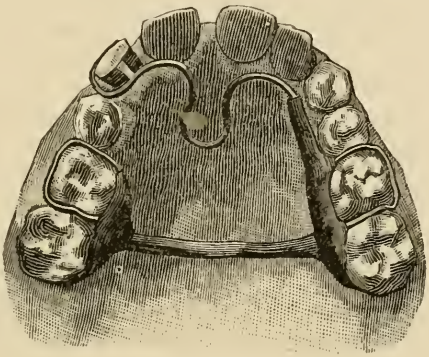

operator. In consequence of the extraction the right deciduous cuspid had moved backward in contact with the second deciduous molar, with the permanent central and lateral incisors erupted considerably to the right of the median line, with spaces between them. The lateral being in contact with the deciduous cuspid left no space for the proper eruption of the permanent cuspid. After carefully considering the case it was determined to move the central and lateral incisors towards the median line, thus correcting their position and giving space for the permanent cuspid. A palatine base-wire was anchored with spring-clasp attachments to the second deciduous molars with partial-clasps on the adjoining teeth. To the lateral on the right side was cemented a collar with a lug. A spring-wire for moving the teeth was attached to the partial-clasps on the left side; it extended forward, following the lingual curve of the teeth, being formed into a U-shaped loop projecting backward at the median line. The end of the spring was curved backward to pass under the lug and terminate in a hook on the distal face of the lateral. The incisors were moved towards the median line by closing the U-shaped loop and bending the end of the spring forward, thus giving the desired space for the permanent cuspid. The same appliance was used for retaining. A base-wire device or a

palatine plate, with springs shaped as illustrated in Fig. 247 can be utilized for moving upper incisors laterally.

In Fig. 294 is illustrated an appliance that was used for correcting the position of crowded lower incisors, the first bicuspids having been removed to cause spaces for their accommodation.

A lingual base-wire was shaped to the line the teeth should assume when regulated, and anchored with partial-clasps and spring-clasp

Fig. 294.

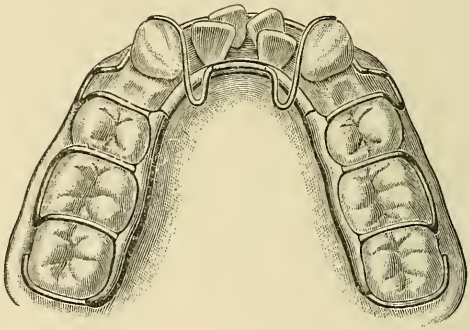

attachments. A semicircular spring with two U-shaped loops was arranged to cross the labial side of the incisors and cuspids near the gum and project to the mesial surface of the bicuspids, where the ends of the spring passed to the lingual side to be united to the partial-clasps with the base-wire, the loops resting between the gum and the lip opposite the spaces. Another spring with two U-shaped loops was attached to the front part of the base-wire just back of the incisors, the free ends being shaped to project over the arch to rest on the mesio-labial surface of the cuspids for forcing them backward. When sufficient space was caused, slight pressure was applied on the labial faces of the incisors by closing the loops in the semicircular spring. The inward pressure forced the teeth against the base-wire, wedging them laterally and backward along the curved enclosure.

Fig. 295 illustrates an appliance that was utilized in the case of Miss P., aged twelve years, for moving laterally towards the right the lower incisors and both cuspids. The cuspids occluded in front of the upper teeth. There was insufficient room for them to take a normal position in the arch. Space was gained by the extraction of a first right bicuspid. The appliance was constructed with a lingual

base-wire, its ends anchored by partial clasps to the remaining bicuspids, and by spring-clasp attachments to the first molars. The right cuspid was moved backward into the space caused by the extraction, by means of a finger-spring attached to the base-wire. The spring was

Fig. 295.

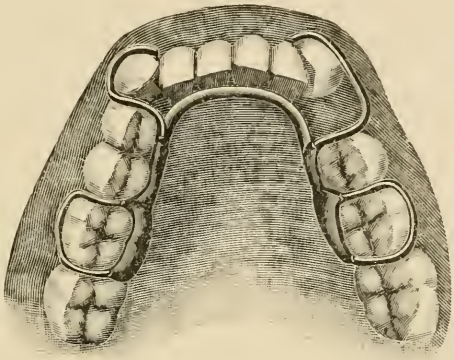

shaped to pass through the space just in front of the second bicuspid to the buccal side of the arch, and then forward in a curve, the end resting on the mesio-labial surface of the cuspid. Pressure was caused by bending the end of the spring backward and towards the base-wire. By means of another spring, attached to the base-wire and partial-clasps on the left side, all of the incisors and the left cuspid were moved laterally towards the right, the spring being shaped to extend over the arch at the junction of the cuspid and bicuspid, and curved forward to rest on the labial side of the cuspid near the gum. The necessary force for moving the teeth was applied by bending the spring so that it would rest nearer the base-wire. This applied force to each of the teeth successively, moving them laterally to the right, and brought about an excellent occlusion in a short time. When the incisors in either the upper or lower arch need to be moved laterally to range them properly at the median line, or for other purpose, generally lateral pressure on one of them, if sufficiently gradual, and when there is sufficient space, will move the others without crimping them, especially if they were not originally in an irregular line.

CHAPTER XIV

INCISORS, TO ROTATE

The earlier procedure for rotating teeth in their sockets to improve their appearance and the occlusion was the application of a cord ligature, tying it firmly about the tooth to be moved, and causing traction in the right direction by fastening the ends securely to one or more other teeth in the arch. Later the elastic ligature was used to advantage in connection with the cord, having adjustable collars over the teeth to be moved, with spurs in the form of posts, hooks, or tubes soldered to them for the attachment of the ligatures. A properly fitted collar with a tube attached for the introduction of a spring bar has been used many years for rotating,* and since

Fig. 296.

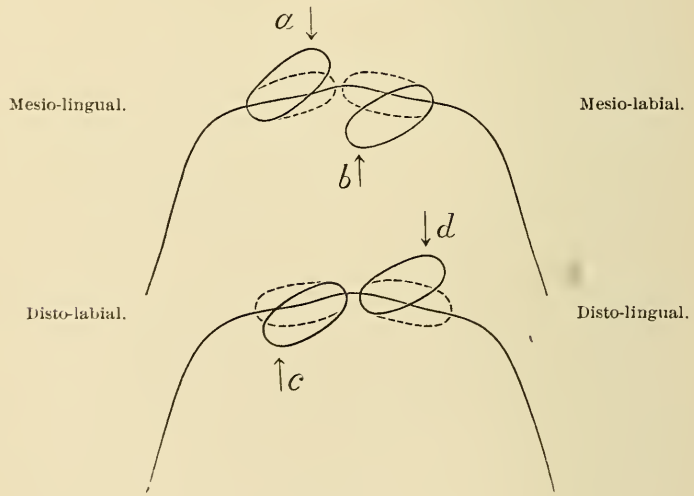

Movements in rotation of incisors.

Dr. Magill introduced the method of cementing collars to the teeth, in 1871, the collar with the tube and spring has been almost universally adopted.

In the process of rotating an incisor, especially when the teeth

* Evans, Dental News Letter, 1853, page 70.

are crowded, it is inclined to become too prominent. This tendency is usually counteracted by attaching to the lingual side of the collar a round or flat metal spur, to project back of one of the adjoining teeth, and applying the force gradually.

In the rotation of the incisors there are four principal movements to be considered. They are referred to as the *mesio-lingual* (rotating an incisor inward), the *mesio-labial* (rotating an incisor outward), the *disto-labial*, and *disto-lingual* rotation (Fig. 296).

Rotation of Incisors Mesio-Lingually or Disto-Labially.—When the mesio-labial surface of the right upper central incisor is considerably in advance of the left central, with nearly space enough for it in the arch (Fig. 297), its position can be corrected by cementing to it a collar with a short tube or eyelet soldered perpendicularly on the disto-labial surface, and a spur attached on the lingual side in position to project back of the lateral, to prevent the distal part of the incisor from moving outward too far during rotation. A spring-clasp attachment for supporting a spring-wire is made for a molar or bicuspid on the left side. The partial-clasp is arranged on the buccal surface, the end of the spring is soldered to it and shaped to extend forward, following the labial curve of the arch to the tooth to be rotated, where the free end of the spring is formed into a U-shaped loop projecting towards the gum, with the end passing downward through the tube on the incisor, as shown at *a*, *b*. The spring can enter the tube from either above or below. The tension for rotating is caused by removing the appliance and bending the end of the looped spring outward slightly and pressing it into the tube. When the incisor is to be rotated in an opposite direction, the spring can be arranged on the other side of the arch. For an obvious reason, the shape of the spring should not be changed between the loop and the anchorage portion (Fig. 298). Were the spring left straight, as from *a* to *b*, with one end entering the tube at *c*, and the other sprung back and fastened to an anchorage tooth at *d*,

Fig. 297.

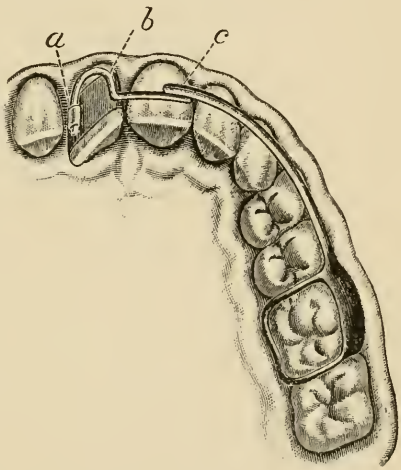

as is often recommended, the spring would not cease its action until it had become straight again. Therefore, if from any cause the spring was not removed at the proper time, both the incisor that was being rotated, and the tooth used for anchorage would be likely to be

Fig. 298.

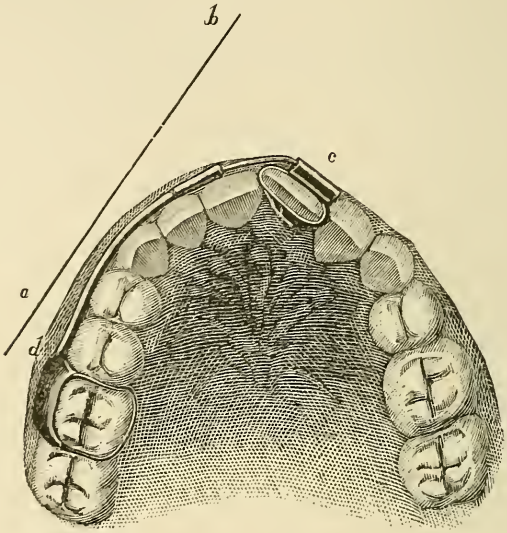

moved far out of the desired position, and the outer curve of the arch would be flattened by its pressure on the teeth between them.

To lessen the tendency of the appliance to move the teeth out of the natural curve of the arch while being rotated, the following device is sometimes adopted. In rotating the left upper central incisor a collar with a tube soldered horizontally on the labial side should be cemented to it, the collar being provided with a spur on the lingual side to project on to the lateral incisor as described. A spring-clasp attachment is fitted to a molar or bicuspid on the right side of the arch, with the partial-clasp on the buccal surface. To this is soldered a short labio-buccal base-wire, about No. 19 gauge, or large enough not to be springy. It is shaped to extend forward, following the curve of the arch to the right central incisor, to the end of which is attached a small spring-wire shaped to enter the tube on the collar, as seen in the figure. The spring is made of any springy metal desired, and is joined to the end of the base-wire with solder, usually first wrapping about them a narrow, thin piece of suitable plate-

metal; or a short piece of metal tubing can be soldered to the side or end of the base-wire to hold the end of the spring. The force for the rotation is caused by reshaping the spring, it being seldom necessary to reshape the base-wire.

When the conditions will permit it is preferable to have the appliance for rotating arranged inside of the circle of the arch. The form of device shown in Fig. 299 has some advantages over the one

Fig. 299.

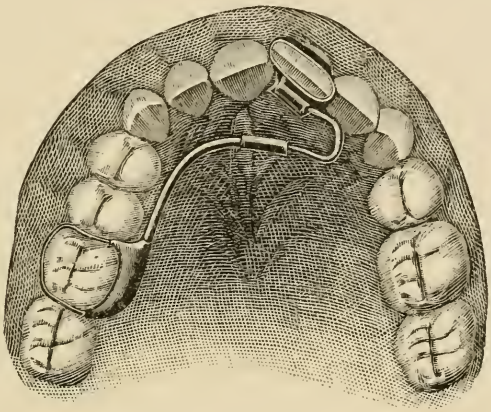

previously described, but it requires more skill in manipulation. It is not as unsightly, may be worn with less discomfort to the patient, and while in the process of rotation the tooth can be moved inward or outward as desired, to conform with the line of other teeth in the arch. With this appliance, as in the rotating appliances arranged on the labial side of the arch, it is an advantage to use a base-wire in connection with the spring.

When the left upper incisor is twisted outward, with the mesial surface much more prominent than the right upper incisor, which is in proper position, a spring-clasp attachment for anchorage is made for the first or second right bicuspid or first molar, with the partial-clasp arranged on the lingual side. To it is soldered a base-wire, shaped to extend forward from the anchorage, following the lingual curve and terminating near the incisor to be moved. To the end is attached with solder, or by means of a tube, a spring-wire in the form of a loop, with the free end of the spring shaped to enter a tube or eyelet on the lingual side of a collar cemented to the incisor to be rotated.

With this, as with all appliances of this description, when at rest, the end of the spring-wire that is to cause the tension in rotating should be on a plane with the tube on the collar that it is to enter. To determine this the appliance should be adjusted in the mouth, with the spring by the side of the tube; we thus know in each instance that the end of the spring and the tube are on the same plane. At the same time it can be determined by the position of the spring whether the end is of proper distance from the anchorage tooth to prevent the incisor from being moved outward or inward from the circle. If not, it can be controlled by slightly curving the looped portion of the spring to shorten the distance from the anchorage; or the base-wire can be straightened to lengthen it. It is essential that this procedure be observed. The force for rotating is caused by bending backward the end of the spring close where it enters the tube.

In the case illustrated the left lateral incisor was also twisted, and had been rotated to position with an appliance like the one described, although anchored on the opposite side of the arch. At the same time an additional spring moved the lateral and cuspid back into the space previously occupied by the first bicuspid. The lateral incisor was retained by cementing to it a collar having a spur projecting from the labial side on to the cuspid, and when the central incisor was rotated to position a similar collar was cemented to it, with a spur on the mesio-lingual side projecting on to the adjoining incisor, and a spur on the labial side which projected on to the lateral incisor that had been moved. (See Fig. 500.)

Fig. 300.

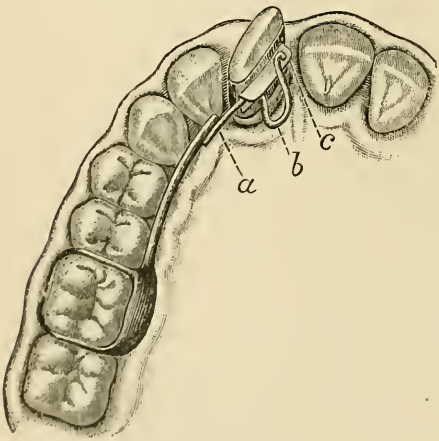

An easily manipulated device for causing mesio-lingual rotation is illustrated in Fig. 300. When a right upper incisor is to be rotated, a collar with a horizontal tube or lug soldered on the lingual side near the gum is cemented to it. Through the side of the tube or lug near the mesial end a hole is drilled for the accommodation of a looped spring. A spring-clasp attachment is

fitted to a right molar or bicuspid. To this is attached a short lingual base-wire, extending forward and following the curve of the arch to the lateral incisor (*a*), where it is joined with solder to a small-sized spring which passes under the end of the lug, and is bent into the form of a U-shaped loop projecting backward and resting over the gum (*b*). The free end of the looped spring is bent at an acute angle, forming a hook to enter the hole in the lug (*c*). Force is applied by reshaping the looped spring, bending the free end backward a little, then hooking it to place.

If at any time the incisor needs to be rotated farther disto-labially, the part of the spring that passes under the lug is shaped to press outward.

When the lower incisors close near the gum back of the upper incisors in such a manner as to interfere with the use of a collar with a tube or lug on the lingual side for rotating, a bar or arm can be made of a narrow strip of plate-metal, about one-half inch long, with one end bent at an obtuse angle and soldered to the collar. The other end should project backward, following the contour of the gum and having a hole in the end for the attachment of a spring (Fig. 301). A spring-clasp attachment is applied to one or more molars

Fig. 301.

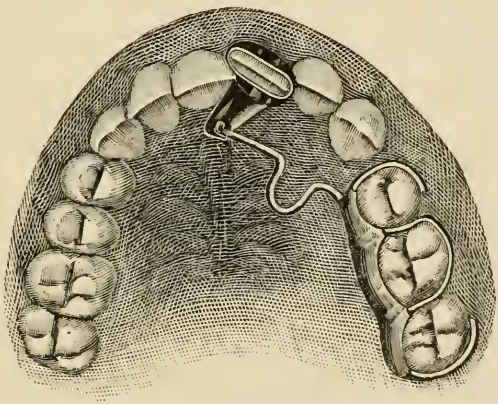

for anchorage, and a small spring-wire made to project from it in the form of a U-shaped loop, with a slight hook made in the free end for hooking into the bar. Closing the loop in the spring causes traction on the end of the bar, gradually rotating the tooth into position.

The mesio-lingual rotation of two incisors at one time can be ac-

complished by attaching to each a collar with an arm on the lingual side in this manner, having the arms projecting backward and running parallel one with the other. The force for moving them is given by a simple looped spring, the ends of which are bent at right angles and notched to enter the holes in the arms. When one tooth requires less force for its movement than the other, an additional hole can be made in the arm closer to the collar, shortening the purchase, the looped wire being shaped so that one side is longer than the other, so as to hook into the arm and to correspond with the change in the length of the arms.

In a case in which I corrected a similar irregularity several years ago, owing to the conical form of the tooth the cement would break, allowing the collar to slip. An arm with a screw was applied, and proved effective in retaining the collar on the tooth. The lingual side of an ordinary collar was thickened sufficiently to form a nut; through it a hole was drilled near the gum line and a thread cut, into which was turned a good-sized bar provided with a thread. The free end of the bar was flattened and a hook made to hold a rubber band or cord that extended from it around a bicuspid for causing traction. The collar was set with oxyphosphate of zinc, and the screw turned as tight as practicable before the cement had time to harden. The hole in the collar should be made at an angle to hold the end of the arm well up in the palatine arch, otherwise the bar must be bent.

Fig. 302.

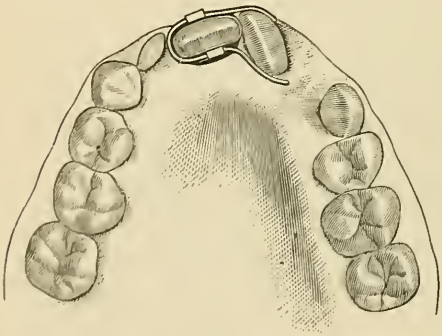

This patient was about twenty-two years of age, and the tooth moved very hard.

A removable retaining device, made as seen in Fig. 493, was worn at night for about four years.

A simple and effective method of rotating into proper line central incisors that are partly or fully erupted is illustrated in Fig. 302. On one or both incisors a collar is placed with lugs attached to hold a U-shaped spring-wire, with one arm of the wire passing across the labial side of the teeth, ending in a curve in shape to press on the mesio-labial surface of the incisor to be rotated. This

form also keeps the spring from slipping laterally. The end of the other arm on the lingual side is curved back from the centre, and reaches a little beyond the distal side of the tooth to be moved. The case illustrated was that of a girl aged seven years. When the laterals are present, the looped end of the wire should be bent upward at a right angle, to pass over the arch at the junction of the lateral and central incisor.

The action of the appliance is controlled by removing the spring and bending the ends towards one another.

In cases where there is insufficient space it is often hard to rotate the teeth into proper position. Usually the operation is facilitated by arranging an appliance to cause pressure on both the labial and lingual sides.

Fig. 303 illustrates a device made by forming a simple spring wire to pass around the first molar and second bicuspid at the gum line for anchorage; the ends extend forward, conforming to the shape of the gum, and terminate in a slight hook, one on the labial and the other on the lingual side of the tooth to be moved. The lateral sides of the spring are connected with two bars of wire formed to extend over the arch at the junction of two of the anchorage teeth, with the ends flattened, curved around the wire, and soldered. Partial-clasps should usually be applied to improve the anchorage.

Fig. 303.

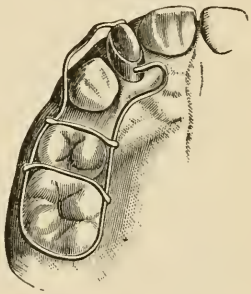

A collar with small depressions or sockets near the mesio-labial and disto-lingual sides to engage the ends of the spring is cemented to the tooth to be rotated. The depressions or sockets on the collar are generally made by soldering to it a U-shaped piece of small wire. Force for rotating is caused by curving the ends of the spring to proper form to be sprung into the sockets.

When the teeth are crowded, and especially when the lateral incisor is to be rotated at the time of the eruption of the cuspid, it is usually well to rotate the lateral farther than its appearance would seem to require, and to retain it in that position for a considerable length of time. This allows the cuspid to shrink farther into the arch, where the shape of its root and that of the lateral favors a better approximation.

Fig. 304 shows a device applicable for the rotation of any of the teeth. The principle was utilized for the mesio-lingual rotation of a crowded right upper lateral incisor for Mr. K., aged twenty-four years. A collar was fitted to the lateral; to the lingual side of the

Fig. 304.

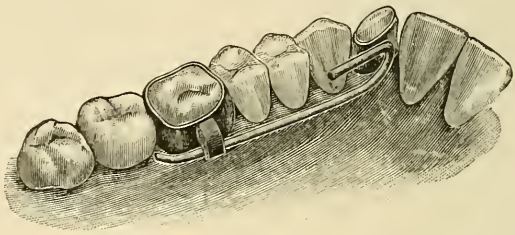

collar was attached a small spring-wire bent into a narrow U-shaped loop having a long and a short arm. The short arm was shaped to pass just back of the cuspid. The long arm followed the lingual curve of the same side of the arch, extending backward as far as the second molar, and was anchored with a hook on a collar cemented to the first molar. The necessary force for rotating was given by unhooking the long arm of the spring, bending it outward near where it was soldered to the collar, and springing the end back again under the hook of the anchorage. Only a few visits were required to complete the rotation.

In connection with the methods mentioned for the rotation of individual teeth will be described some of the more important methods I have devised for the rotation of two teeth at one time. Fig. 305 illustrates a device for the disto-labial rotation of two upper

Fig. 305.

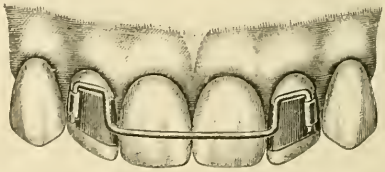

lateral incisors. To each of the laterals is cemented a collar with a short tube or eyelet attached across it near the disto-labial surface. A small spring of suitable length is shaped to fit the labial side of the incisors, with each end terminating in a U-shaped loop, resting on the lateral, usually projecting upward, the ends or outer part of

the loops being parallel with and made to enter the tubes on the collars from above downward. Force is caused by bending forward the outer arms or sides of the loops of the spring before inserting the ends into the tubes, having them parallel, changes being made as required.

When only one incisor is to be rotated, the device can be arranged in the same manner, excepting that the tube should be attached to the centre of the collar on the tooth used for anchorage. This principle is applicable to any similar device.

For preventing the spring from slipping out of the tubes in this and in some of the following devices, the part that enters the tube can be curved slightly before being forced into the tube, the spring notched on the side that is to be pressed outward, in such a manner as to catch below the end of the tube, or the tube compressed a little.

Fig. 306 represents a device that was utilized for rotating two incisors and at the same time causing lateral traction for closing a broad interdental space in the case of Miss T., aged eleven years. A collar was adjusted to each of the incisors, with an eyelet or a very short tube soldered to it, arranged perpendicularly, and located near the disto-labial surface of the tooth when the collar was cemented to place. A small spring-wire was formed into three successive U-shaped loops, the ends shaped to rest parallel with the tubes and enter them from above downward. The force was applied from time to time by removing the spring and bending the ends forward a little. The space between the teeth was closed by narrowing slightly the centre loop of the spring.

Fig. 306.

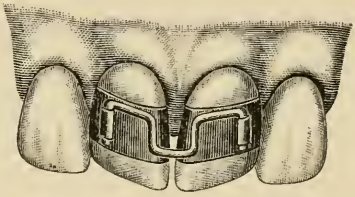

If tubes are used for this purpose they should be short, and the ends of the spring when at rest made parallel with them. When one tooth is longer than the adjoining one, this device can be utilized for harmonizing their length, by having the tubes on the collars rather long, and properly shaping the spring by bending both ends towards the right a little, keeping them parallel, or towards the left as required, and pressing them into the tubes. Force applied in this manner elevates one tooth and depresses the other.

When, in the process of rotation, the incisors are inclined to move

outward, it can be prevented by soldering to the lingual side of each of the collars a spur projecting back of the laterals.

Fig. 307 illustrates a similar device for rotating disto-labially two upper central incisors. It is made by cementing to each of the

Fig. 307.

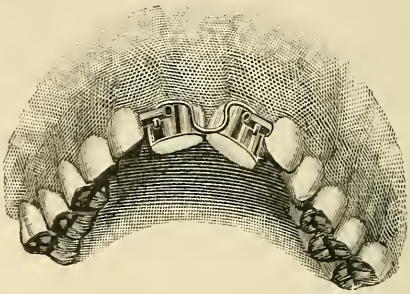

incisors a collar with a small tube attached horizontally on the labial side, having one end of the tube even with the distal surface of the tooth. A hole is drilled through the sides of each of the tubes from below upward, the location of the holes being near the distal end of the tubes. A small wire is bent as described into three U-shaped loops; their ends are left parallel, at the proper distance apart to enter the holes drilled in the tubes. The width of the centre loop in the wire should be broad enough to reach on to the mesio-labial surface of each of the incisors, with the end of the loop rather near the incisive edge, and the sides extending upward near the gum. The ends of the spring should usually be passed through the holes in the tube from above downward and left long to prevent accidental removal. Any tendency of the spring to slip out of the tubes is prevented, when necessary, by cutting slight notches in the side of the wire where it passes through the tubes, or by bending the ends of the spring slightly outward or towards each other. The necessary force for rotating the teeth is given by removing the spring and bending the ends of the outer loops forward. When the teeth are in correct position, a slightly curved bar can be passed through the tubes for retaining.

In Fig. 308 is shown a double rotating device that has the advantage of a spring with a longer loop projecting up under the lip. It is more springy and does not need to be changed as frequently as a shorter one. It also admits of the lateral movement required for hooking into or around the end of the tubes.

To each of the incisors is cemented a collar having a tube soldered horizontally on the labial side, with a notch cut in the distal end near the laterals. The spring-wire, formed into a U-shaped loop, is made to rest underneath the lip at the median line. The ends extending downward are bent outward at a right angle to cross the front of the incisors, parallel with and below the tubes. Each end is then bent back on itself, terminating in a hook-shape to catch into the notches and rest above the tubes, or the ends of the spring can be made to hook slightly into the tubes when preferred. Force for the rotation is applied by bending the ends of the spring outward a little at a time before its adjustment.

Fig. 308.

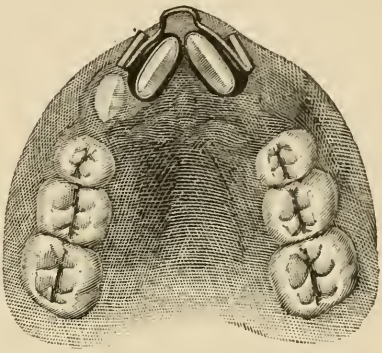

This form of device can be utilized also for drawing the teeth together, for separating them, or for equalizing the length of the incisors when one appears longer than the other. For the latter purpose it is usually advisable to leave the ends of the hooked portion of the spring rather long, causing the hooks to pass either side of the tubes, and adjusting the lateral arms in a manner to draw slightly upward on one tooth and downward on the other. I have attained a certain degree of success with this device in moving incisors bodily together.

Fig. 309 illustrates a simple appliance for double rotation of the incisors mesio-lingually. It is made by fitting to each of them a broad collar, to the labial side of which is soldered a narrow strip of plate-metal, made on a form, and bent approximately to a rectangular shape, thus making an opening crosswise of the collar, and a little narrower at the lower edge. Each end of a small spring-wire of suitable length is bent into a U-shaped loop to enter the openings. The part of the spring between the loops is slightly curved or corrugated to meet the changes in rotation. Force is applied by bending forward the looped portions, they being retained in the openings by slightly bending the ends outward.

Fig. 309.

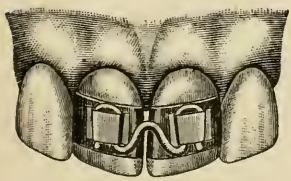

If the incisors are inclined to move outward, it can be prevented by soldering to the lingual side of each of the collars a spur to project back of the laterals.

When the upper central incisors have taken the position commonly found in the V-shaped arch, with their mesial surfaces projecting outward and with insufficient space, the device seen in Fig. 310 is generally effective for causing their rotation and preventing them from being driven forward of the lateral incisors. It is made by fitting a thin, broad collar to each of the incisors, to which they are finally cemented, having a wire spur soldered to the front of each, reaching across the median line, one above the other. An eyelet made of wire or a short section of tube is soldered on the disto-lingual side of the collars near the gum, through which a spring-wire is passed, leaving the ends of the spring long to prevent the distal side of the incisors from moving outward beyond the laterals. A silk or elastic ligature is passed between the incisors and around the spurs on the labial side and the spring on the lingual side once or more than once, according to the force required, and fastened.

Fig. 310.

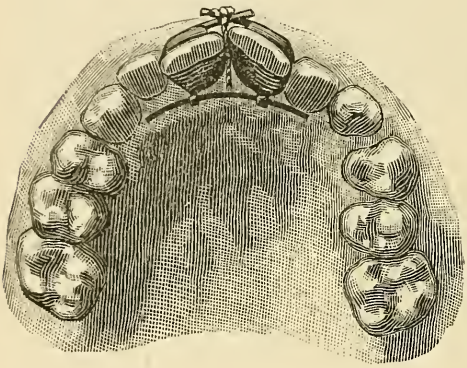

Fig. 311 shows a fixed device for causing double rotation, and at the same time wedging the upper central incisors between the laterals when there is insufficient space. It is made with a broad collar fitted to each of the teeth to be moved. An elbow-shaped small spring-wire is attached with solder to the lingual side of each collar near the gum. One end of each wire is made to extend outward to rest on the lateral incisor; the other end extends backward about half an inch at the median line, more or less, follow-

Fig. 311.

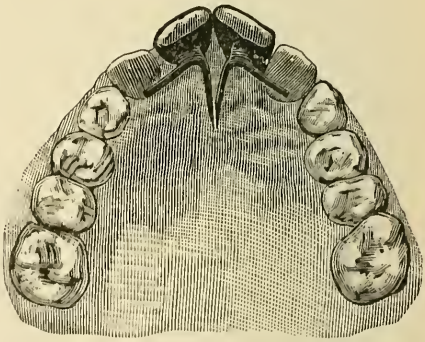

ing the contour of the gum, running parallel with the spring projecting from the opposite collar and resting one against the other. The surface of the spring arms should be flattened a little near the end where they rest together, or one of them grooved to prevent their passing by one another.

Force for the rotation of the teeth is produced by springing one of the arms below the other, bending them towards the opposite side of the arch a little, and springing them back again to rest in contact.

Fig. 312 illustrates the case of Master B., aged eleven years, in which both upper lateral incisors had erupted with their lingual faces

Fig. 312.

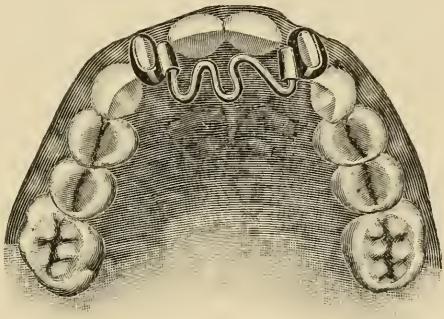

towards one another, and their edge crossing the lower arch, resting between the lateral incisors and cuspids.

Their position was corrected by rotating them into the proper circle with a device as shown in the figure. A collar was cemented to each of the laterals, having a tube soldered near the gum on the lingual side. A spring-wire was then bent into several corrugations or loops about one-fourth of an inch long, the ends of two of the loops pointing forward near the central incisors. The ends of the spring were also bent forward and left long enough to reach through the tubes attached to the teeth to be rotated. Force was caused by removing the spring from the tubes from time to time, opening slightly with round-nosed pliers each of the two loops that pointed forward, and replacing the spring. It will be observed that the distance between the distal faces of the lateral incisors increased as they were rotated more nearly to a correct position. By opening the loops in the spring as described, its length was correspondingly increased, at the same time giving the required force. When the

rotation of the lateral incisors was nearly completed it became necessary to still further lengthen the spring, which was accomplished by opening the central loop, pointing backward at the median line. When the teeth were in correct position, the wire had assumed the shape seen in Fig. 313, the same spring being used to complete the

Fig. 313.

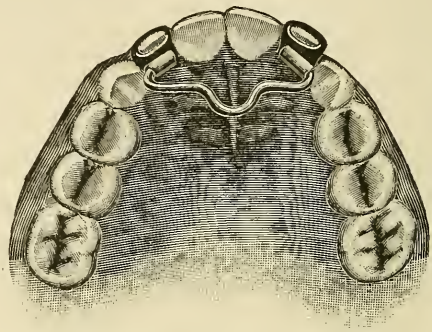

double rotation. As the size of the wire was small, its elasticity permitted its easy removal and replacement in the tubes. For retaining, a slightly curved wire was passed through both of the tubes and worn for several months. In the mean time, through an accident, the patient fractured the crown of one of the central incisors at the junction of the lower third of its length, and an apparatus as seen in Fig. 355 was constructed to elevate it to compare in length with the adjoining incisors.

Generally less skill is required in the manipulation when two springs are employed for rotating, as shown in Fig. 314. Each spring has a short arm to enter the tube on the collar, and a long arm to extend across the median line, resting beside the long arm of the opposite spring, and held to it by a hook; this is made by soldering to the long end of each of the springs a narrow strip of plate-metal,

Fig. 314.

Fig. 315.

shaped to hook freely around the other, through which it can slide. The short arms of the spring are bent towards one another from time to time for causing the desired movement and readjusted. Two springs united in this manner are suitable for rotating teeth in the opposite direction (Fig. 315), and can be made to enter tubes arranged on either the labial or lingual side of the teeth.

In Fig. 316 is shown the form of an appliance employed for rotating and moving inward to line projecting upper incisors. At the same time both cuspids, that were very prominent and not fully erupted, were moved backward into spaces provided by the extraction

Fig. 316.

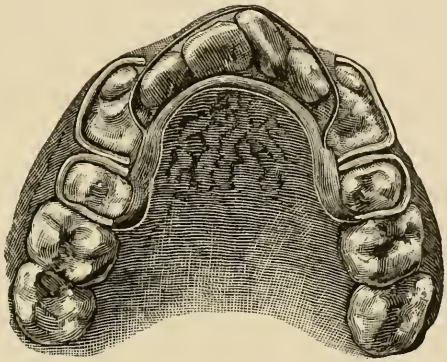

of the first bicuspids. The central and lateral incisors lapped over one another, as is frequently seen in the V-shaped arch.

The appliance was constructed by first arranging a lingual base-wire back of the incisors, shaping it in the circle it was desired they should assume when regulated. The ends were anchored with spring-clasp attachments in the usual manner. The cuspids were moved backward with finger-springs which passed from the partial-clasps to the buccal side, through the spaces just in front of the second bicuspids, and extended forward, terminating in the form of a slight hook on the labio-mesial surface of the erupting cuspids. Force was caused by curving the ends of the springs inward towards the base-wire, and shortening them as the teeth were moved backward. The position of the incisors was corrected by a semicircular spring, shaped to press on the labial side at about midway between their incisive edge and the gum. The ends of the spring passed through the spaces caused by the removal of the first bicuspids and were attached to the base-wire with the other springs.

In designing the appliance, the width of the incisors should first be obtained with dividers, and spaced off on the model in front of the circle to be occupied by the base-wire. In this manner the proper location for the attachment of the ends of the semicircular spring to the base-wire can be easily obtained, it being necessary to leave

spaces between the distal side of the laterals and the attachment of the ends of the spring, to permit the teeth to be moved in contact with the base-wire. The force for moving the incisors inward and rotating them is caused by straightening, a little at a time, the part of the spring that rests on the mesial and labial surface of the incisors, and at the same time curving a little more the part of the spring that passes beyond the laterals. If there is any excess in the length of the spring, it can be taken up by curving this part downward, or forming a partial loop in the anterior part. The continued pressure of the spring on the labial side and the base-wire on the lingual side of the teeth in this manner smooths out their irregularity and forces them into a correct circle. The cuspids should be moved a little in advance of the incisors.

In this case the regulating was begun on February 1, and on April 6 the teeth were in the position shown in Fig. 317, there having

Fig. 317.

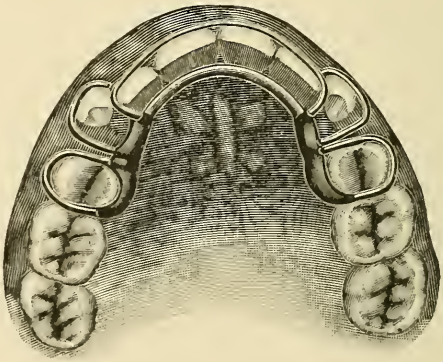

been eight visits. The position of the cuspids was improved, and the appliance was worn to retain the teeth until November 23, when a retaining device (Fig. 486) was inserted, the patient being directed to wear the retainer for two years, and to remove and cleanse it and the teeth regularly at least once a day.

When the incisors are in a rotated position similar to those shown in this case, and need to be made more prominent to form a proper circle, in some instances a labio-buccal base-wire can be used to advantage. It should be suitably curved, and its ends anchored with spring-clasp attachments, with one or more finger-springs attached in a manner to extend to the lingual side of the incisors, so

as to force them outward in contact with the base-wire. Many examples of rotation of the teeth by means of force applied to the labial and lingual side will be found in other chapters.

In Fig. 318 is shown the form of an appliance that has been used for moving inward prominent upper incisors, and at the same time

Fig. 318.

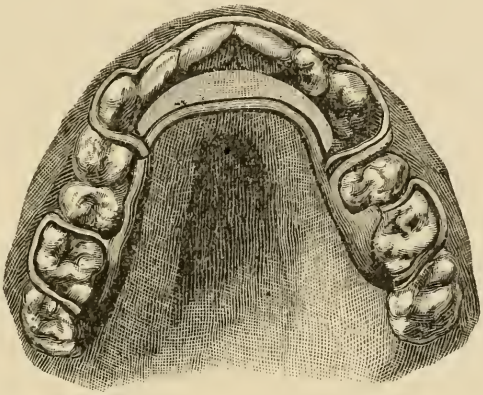

rotating them, in cases where the lower incisors close against the gum. Owing to this occlusion of the teeth, there is no room for a base-wire in its usual position near the lingual side of the incisors. It should therefore be placed far enough back to permit the lower incisors to close in front of it, and a thin piece of metal to be soldered to the base-wire resting on the gum and projecting to the lingual side of the teeth, first having the outer edge of the metal shaped into the circle it is intended the teeth shall form. The ends of the base wire are held with spring-clasp attachments, being anchored to all of the available teeth. In this case, there being no spaces between the teeth, room for their correction was gained by the extraction of the left upper first bicuspid; and all of the incisors and the cuspids were moved towards that side. The left cuspid was first moved backward with a finger-spring; this extended from the base-wire through to the buccal side, next to the second bicuspid, and passed forward ending in a curve on the mesio-labial surface of the cuspid, the end being bent inward towards the base-wire to produce the pressure. A long semicircular spring was shaped in a suitable curve to cross the labial side of all of the incisors about midway between their edge and the gum. It had a loop opposite the cuspid on either side, projecting up under the lip; on the left the loop passed over

the canine ridge considerably above the line of the gum, and was made broad to reach from the distal side of the lateral to the mesial side of the second bicuspid, where the end passed through the space and was attached to the base-wire. The loop on the right side was made smaller, and projected upward only to the margin of the gum, reaching from the distal side of the lateral to the mesial side of the first bicuspid, where it passed over the arch at the junction of the bicuspid with the cuspid, to be attached to the base-wire. The necessary force for moving the teeth was applied by occasionally closing slightly, with flat-nosed pliers, the larger loop in the circular spring that crossed the labial side of them. This forced the teeth inward against the metal on the lingual side, and the squeezing pressure quickly rotated them into a correct circle. The right cuspid was pressed into line by bending inward the end of the loop as desired.

Rotation of Incisors Mesio-Labially or Disto-Lingually.—The rotation of the incisors outward or mesio-labially with the ordinary appliance is not so easily accomplished as their movement in the opposite direction.

Fig. 319 illustrates a device adjusted for the rotation of a right upper central incisor. A broad collar, with a spur on the lingual

Fig. 319.

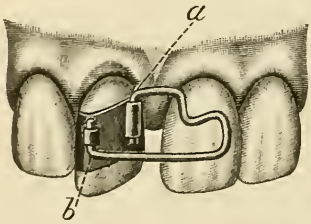

Fig. 320.

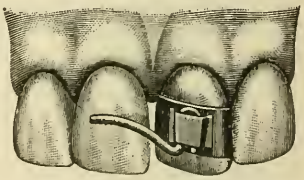

side projecting back of the lateral, and with two short tubes, one located near the disto-labial and the other near the mesial surface, is cemented to the irregular tooth. A small spring-wire is shaped into a long, narrow loop with one arm shorter than the other. The looped part is arranged to cross an adjoining tooth, and each end bent at a right angle towards the other to enter the tubes; the distance between these ends should be a little less than the distance between the openings in the tubes. The short arm is bent upward and again downward at a right angle to enter the tube at *a*, causing the arm to extend on a line with the centre of the tube, or lower,

which is an advantage in adjusting the device. The long arm extends in a slight outward curve across the teeth and enters the distal tube from below (*b*). The force of the spring is caused by bending outward a little the shorter arm and inward the longer arm. When the spring is in action the short arm draws outward on the mesial surface and the long arm forces inward the disto-labial side of the tooth, producing its rotation.

Usually a spur should be attached to the mesio-lingual or disto-lingual surface of the collar to project back of the adjoining incisor, to prevent the tooth being moved out of the circle. This device and others described are also applicable for retaining.

In Fig. 320 is shown a simple appliance for rotating an incisor mesio-labially. (It is also used for the rotation of two incisors. See Fig. 309.) A collar is cemented to the tooth. It has a spur on the lingual side and a narrow strip of plate-metal, made on a form and bent approximately to a rectangular shape, soldered to the labial side, giving an opening from above downward and a little narrower at the lower edge. The opening is sufficiently broad to admit of a small U-shaped loop of spring-wire, the wire being bent back on itself, forming a short curve, with the depth of the opening just the thickness of the wire. One end of the spring is left long and bent at a right angle to rest on an adjoining tooth. The required force is applied by bending the free end of the wire backward a little at a time, holding the looped portion with flat-nosed pliers. Before adjusting the spring the loop should be broadened slightly by bending, to cause it to be well retained. If the spring is to be left in position for a considerable length of time, the side of the looped portion of the arm can be notched or the spring made secure with low-heat gutta-percha or other material.

Fig. 321 shows an active device that is suitable for the rotation of any of the teeth, and which has marked advantages for the rotation of the incisors in special cases. To the tooth to be moved is cemented a collar having a spur on the lingual side and a tube soldered on the labial side in a perpendicular position, the tube being a little shorter than the collar. It is located near the mesial or distal surface according to the direction the tooth is to be moved, usually being placed near the side that is to be moved outward. A small-sized spring-wire is bent into a long loop, with one arm a little shorter than the other, curved upward and again downward at a

right angle towards the other arm, forming a small narrow loop. The free end is made to enter the tube on the collar usually from above downward (*a*). The larger loop is arranged to rest on the adjoining incisor that is not to be moved, with the long arm extending below the line of the tube to the disto-labial surface of the irregular tooth (*b*). Force is caused by bending forward the end of the shorter arm of the spring from time to time and adjusting it in the tube, which draws outward on the mesio-labial side of the incisor being rotated, while the long arm presses inward on the distal side.

Fig. 322 illustrates a similar device. A collar with a spur on the lingual side to rest back of an adjoining tooth and a tube located on

Fig. 321.

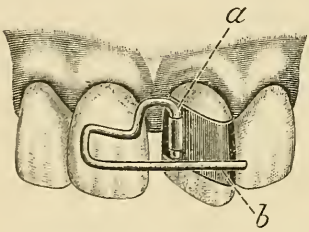

Fig. 322.

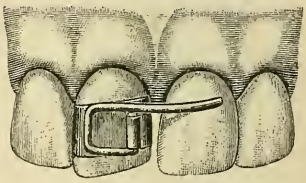

the mesio-labial surface is cemented to the incisor to be moved. A small-sized spring-wire is bent into the form of a loop, with one arm made short and bent at a right angle towards the other to enter the tube, usually from above downward, and the other arm left long to rest on an adjoining tooth, the width of the loop being about equal to the length of the tube. The latter is essential in this and other appliances described, as, when the regulation of the tooth is complete, the long arm should rest next to the collar over the end of the tube to prevent its removal. Force is applied by bending forward the short arm of the spring before its adjustment in the tube, and later the long arm can be bent backward as desired for causing additional force.

It is an advantage in some instances, in the rotation of a tooth, to apply force to both the labial and lingual sides. With this device a tube can be soldered to the labial and one to the lingual side of the collar, each for the attachment of a spring. Fig. 323 illustrates the device employed to rotate a left lower lateral incisor in the case of Miss C., aged twenty-three years.

The inexperienced will sometimes find it difficult to readjust the spring in the tube for increasing the force, in which case the end

that enters the tube should be left long. It is usually best held with small, narrow, flat-nosed pliers.

Fig. 324 illustrates a device that was used for the mesio-labial rotation of a left upper lateral incisor in the case of a boy aged

Fig. 323.

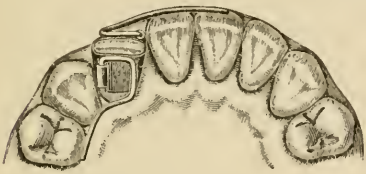

Fig. 324.

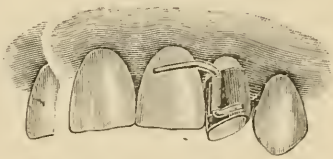

fifteen years. A thin collar with a tube soldered to it, a little shorter than the width of the collar, was cemented to the lateral. The tube was located perpendicularly on the mesio-labial surface, and had a slot cut in the distal side next to the collar, leaving it in the shape of a hook. A small spring-wire was bent twice at right angles in the opposite direction, leaving two arms, one a little longer than the other, the portion between the arms being just equal to the length of the tube. The spring was pressed into the hook-shaped tube, causing the short arm to project on to the collar and the other on to the labial side of the central incisor. Force was applied by removing the spring and bending the ends backward, four changes being required to complete the regulating. The apparatus was especially convenient, as the patient was in attendance at school in a distant town. When the spring is to be left in position a considerable length of time, oxyphosphate of cement or shellac should be applied in the slot to prevent its accidental removal.

For the rotation of lateral incisors mesio-labially, and especially when they need to be made more prominent, a device is shown in Fig. 325. A collar with a spur arranged to project from the disto-lingual side back of the cuspid, and an eyelet or very short tube located on the front near the mesial surface, is cemented to each of the laterals. A spring of suitable length is shaped to cross the labial faces of the central incisors, with each end terminating in a U-shaped loop, usually projecting upward, one part of the loop resting on the central incisor and the other part near the end parallel with the eyelets and made to enter them. Force is applied by bending forward the outer part of the loops or ends of the spring.

Fig. 326 illustrates a similar device with a long curved spring

attached to the centre of the looped spring and reaching to the distal side of the laterals. Action for the rotation of the laterals is effected by bending backward the ends of the curved spring and

Fig. 325.

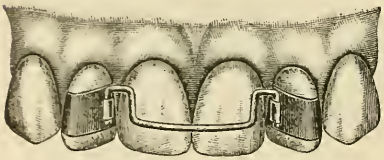

Fig. 326.

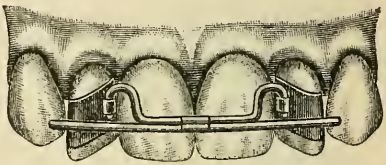

bending forward the ends of the looped portion of the spring that enters the tubes. This rotates the laterals by pressing inward on their distal and outward on their mesial surfaces.

For the rotation mesio-labially of two upper incisors with the device shown in Fig. 327, a collar should be cemented to each with a tube located perpendicularly near the mesial side. To move each tooth a spring is bent into a U-shaped loop with one arm long and the other short, the distance between the arms being equal to the length of the tube. The short arm is bent at a right angle towards the other. The spring would need to be inserted in one of the tubes from above downward, and a similar spring inserted in the corresponding tube from below upward, the springs being retained by their arrangement. Force is caused by bending outward the short arms.

For the mesio-labial rotation of two incisors, a collar with a box-shaped opening can be cemented to each, employing a spring with two U-shaped loops to enter the openings (Fig. 328). The part of

Fig. 327.

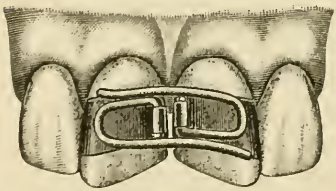

Fig. 328.

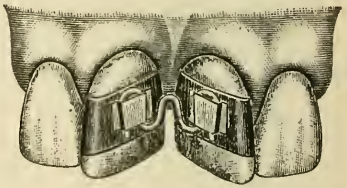

the spring between the loops is curved upward, forming a semi- or complete loop. The latter is an advantage when the teeth are to be rotated a considerable distance, forced farther apart, or drawn closer together. The ends or looped portion of the spring are bent backward or forward according to the direction it is desired to rotate the teeth. The appliance will rotate both of the teeth either in one

direction or in opposite directions. A large-headed pin or a suitably shaped metal T soldered to the surface of the collar can be utilized in some instances in connection with the looped spring in place of the box-shaped metal.

Fig. 329 shows an effective device for the rotation of two incisors. A collar with a short tube or eyelet is cemented to each tooth, the

Fig. 329.

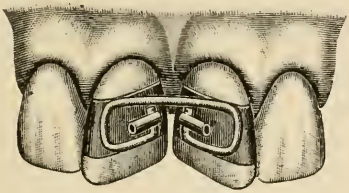

Fig. 330.

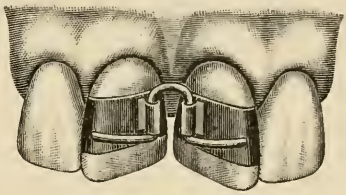

tube being placed horizontally near the mesio-labial surface. Through the sides of each tube near the mesial end a small hole is drilled for the passage of the ends of a spring. The spring is shaped to cross in front of the incisors, usually close above the tubes, with the ends curved downward and towards the mesial surface of the teeth below the tubes, where they are bent at a right angle to pass upward through the openings provided for them. Pressure is applied by bending the free ends of the spring forward a little and forcing them into the openings. The spring can be arranged to have the ends pass through the tubes from above or below as desired.

Another form of device for double rotation that is easily constructed is shown in Fig. 330. A collar, with a strip of metal of nearly equal width, bent into the form of a flange or hook, soldered to the mesio-labial surface of the collar, is cemented to each of the teeth to be rotated; the flanges being made to project from either way, usually towards the median line. A spring is bent into a U-shaped loop with the sides parallel, and with the distance between them just sufficient to pass underneath the hook-shaped flanges on the collars when in position. The ends of the spring below the flanges are bent outward to rest on the collars. The spring is inserted from below upward. To increase the force the ends are bent backward.

The mesio-labial rotation of two incisors, with a spring on the lingual side, is shown in Fig. 331.

A collar with a tube attached near the gum is cemented to each of the teeth to be rotated. A section is removed from the side of one of the tubes close to the collar, leaving the balance of it in the

form of a hook. A straight wire is then passed into the tube on the opposite collar, and the end sprung into the hook. The tendency of the wire to straighten rotates the teeth outward, and when the wire has become straight it can be utilized for rotating the teeth farther in the same direction, by soldering to it opposite the median line a short narrow piece of plate-metal to prevent the wire from turning in the tubes, when the ends may be bent to move the teeth as far as necessary. If the end of the spring is not well retained in the hook on the collar, it is advisable to close the slot with a small amount of oxyphosphate.

Fig. 331.

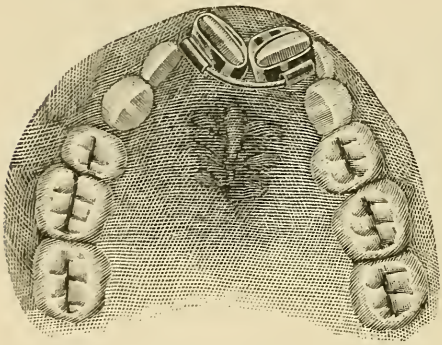

Fig. 332 shows a similar device having a long spring for rotating the upper incisors.

A spring-wire is formed into a U-shaped loop pointing backward at the median line towards the roof of the mouth, with the ends bent outward, one of them extending through a tube attached to the lingual side of a collar on the left incisor, and the other held with a hook on the lingual side of the right incisor. The wire bent in the form of a loop in this manner has the advantage of being more springy; it is easily manipulated, and does not require to be changed as often as some other forms, its shape preventing the spring from twisting in the tubes. The ends of the spring can be bent backward to rotate the teeth as far as required.

Fig. 332.

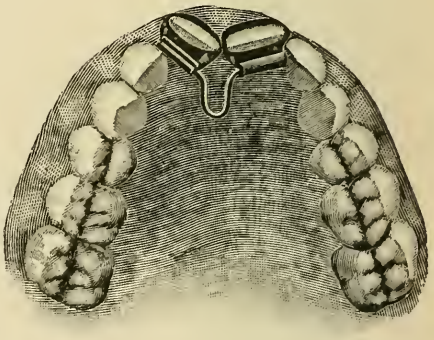

Fig. 333 illustrates a device for the rotation of two incisors, or an incisor and a lateral, both in the same direction. A collar is cemented to each of the teeth to be moved, having an eyelet or a very short tube arranged perpendicularly on the collar, or a tube

arranged horizontally with a hole in the side, as shown in Fig. 307, the tube or eyelet being located near the side of the tooth that is to be moved outward.

Fig. 333.

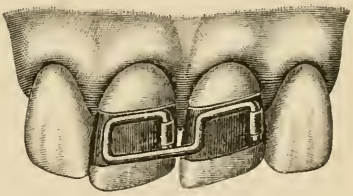

A spring is shaped to rest on the prominent part of one tooth and extend to the prominent part of the other, passing below the line of the tubes. The ends of the spring are shaped to curve upward and cross the width of the teeth above the line of the tubes, where they are bent downward at a right angle to enter the tubes or eyelets. Force for the rotation is produced by bending the ends of the spring outward a little before each adjustment.

Fig. 334 illustrates the case of a boy aged ten years, with the mesial surface of the upper central incisors twisted inward.

A conical shaped supernumerary tooth was erupted between the incisors and had been extracted. The left incisor crossed the arch at nearly a right angle, and the right incisor was twisted still farther, the lingual surface resting in contact with an erupting lateral. An appliance for their mesio-labial rotation, which moved them to position without any apparent congestion, was constructed similar to the one shown in the figure. It was made by first cementing to each of the incisors a gold collar with a tube on the lingual side, and anchoring a lingual base-wire by spring-clasp attachments to the second deciduous molars, the base-wire following close to the side of the teeth. A small spring was formed to extend into the tube on the left incisor from the mesial side; it was bent backward, following the left curve of the arch, and terminated in a hook, shaped to pass around the base-wire from the lingual side near the anchorage. Force was applied by removing the spring and bending backward the end near where it entered the tube, and hooking the other end in place over the base-wire.

Fig. 334.

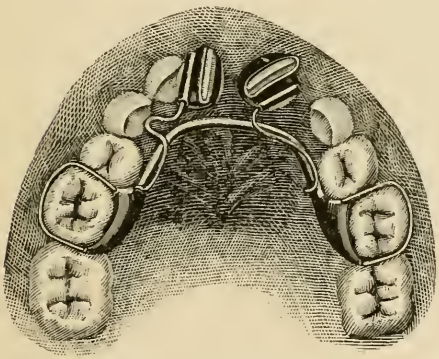

The right incisor was rotated in a similar manner. The spring entered the tube from the mesial end, and was attached to the base-wire on the right side with a hook, but a U-shaped loop was formed in the wire opposite the right cuspid for the purpose of lengthening it and making it more springy, the loop being opened to meet the requirements. After the teeth were rotated to proper positions they were retained by cementing to them two gold collars united with solder.

When the shaping of the end of a spring into a hook for attachment to the base-wire in the manner described proves difficult, small wire hooks may be soldered to the base-wire in form to hold the ends of the springs; or two small springs may be directly soldered to the base-wire for the rotation of each tooth, one shaped to bear on the linguo-mesial and the other on the labio-distal side.

Fig. 335 shows a method of rotating the teeth with springs in connection with a palatine plate when considerable force is required.

Fig. 335.

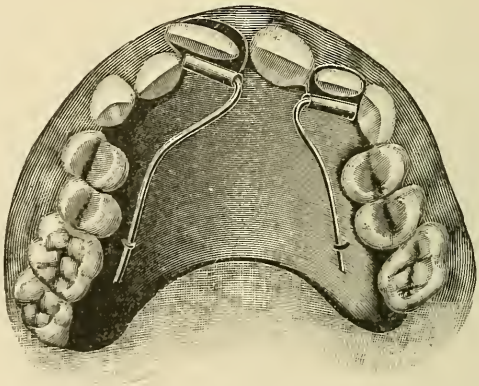

A collar with a tube on the lingual side is cemented to each of the teeth to be moved, and a metal hook arranged in the plate in suitable position, usually near the bicuspids or molars, to hold the end of a spring that is shaped to enter the tube on the collar. The figure illustrates the arrangement for rotating a right central and a left lateral incisor.

When force is applied to a spring in rotating, it is liable, if not counteracted, to move the tooth out of the circle in the direction of the force, often causing the tooth to assume a false position. This is usually prevented by extending a spur from the collar to rest on

an adjoining tooth. With the form of apparatus described the plate prevents the tooth from being pressed too far into the circle, and forms an anchorage for the free end of the spring. When desired the spring may be bent at a right angle just back of the hook on the plate for causing the tension required to draw the tooth into the circle.

Fig. 336 illustrates a case in which an unsuccessful attempt had been made by a general practitioner to correct the position of the incisors, including the rotation of the laterals.

When the case was presented, the upper central incisors were not prominent enough to close in front of the lower incisors. I first moved them outward by means of a spring passing under lugs soldered on the lingual side of collars that were cemented to them. When they were moved outward to proper position, which also gave the necessary space for the laterals, they were retained by a vulcanite palatine plate. To this, on either side, was attached a wire arm extending over the arch at the junction of the bicuspids, with the end bent in the form of a hook resting near the gum on the buccal side. A collar with a tube on the labial side was cemented to each of the lateral incisors. Spring-wires were shaped to extend into the tubes and the ends sprung backward to pass through the hook-shaped arms. This arrangement gave the unusual force required for rotating each of the lateral incisors with a single spring, without losing their position in the circle of the arch. When the laterals had been moved to place, they were retained by cementing to them collars with spurs shaped to extend on to the lingual side of the cuspids and the labial side of the central incisors. The plate was worn for a time to preserve the circle of the arch.

Fig. 336.

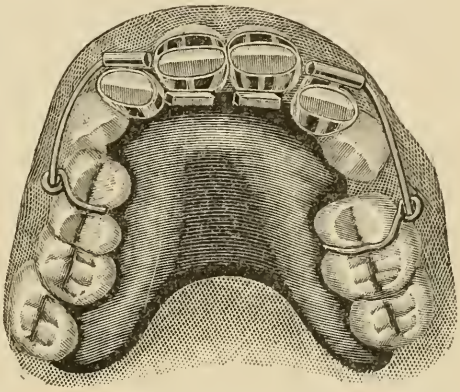

The principles involved in the rotation of the incisors, and nearly all of the methods that have been described in this chapter, are equally applicable for the rotation of the cuspids and bicuspids, and for retaining teeth after their regulation.

CHAPTER XV

INCISORS, TO DEPRESS—SHAPING THE TEETH

Teeth that do not articulate with those of the opposite arch and teeth affected with pyorrhœa alveolaris are gradually extruded from their sockets, lengthening them in appearance. The teeth that are most often affected are the upper and lower incisors and cuspids; less often the bicuspids and molars that have no occlusion. The latter may result from the extraction of the antagonizing teeth. Sometimes teeth used for anchorage are raised in their sockets by the pressure of an appliance. After its removal they generally settle back again, but it usually requires the application of a considerable force to depress teeth that have become extruded from natural causes. When the molars and bicuspids have become elevated from general lack of occlusion (Figs. 99, 108, and 111), the correction of their position is usually sufficient, the new occlusion with the antagonizing teeth causing them to settle back in their sockets.

Extrusion of the incisors is most apparent when they have erupted too prominently. There being no occlusion to prevent, they gradually become elevated, requiring their depression in the process of regulating. Not uncommonly the lower incisors impinge against the necks of the upper incisors or the gum tissue back of them, necessitating their depression or being dressed away to shorten them before moving backward those of the upper arch (Fig. 275). When the lower incisors close in front of the upper ones they also may become extruded to such an extent as to impinge against the gum (Fig. 184). The dressing or shaping of incisors is only recommended when their depression is not practicable and for patients of a mature age.

An appliance for depressing lower incisors is shown in Fig. 337. It consists of a vulcanite palatine plate anchored with a suction, wire-clasps, or spring-clasps. The anterior portion of the plate is thickened so that in closing the jaws all of the pressure in occlusion is caused on the lower incisors, and sometimes including the cuspids. The continued and constant application of pressure in this manner gradually forces these teeth more deeply into their sockets. When the position of the lower incisors is not to be changed otherwise,

slight indentations should be made for them in the rubber, but when they need to be moved outward it can be done at the same time they are being depressed by shaping the thickened portion of the plate described to slope forward in the form of an inclined plane. This

Fig. 337.

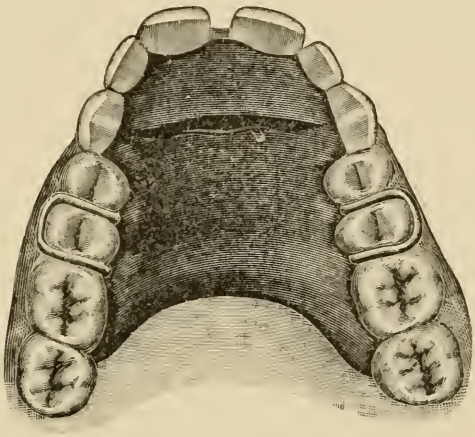

means of depressing the incisors should generally be employed before the age of twenty-one, although it has been used successfully for patients of a more mature age. As the teeth are liable to return to their former position they should be depressed more than it is intended they shall remain.

It is usually necessary to face the incline with sheet-metal, as vulcanite is not sufficiently hard to resist the continued force of the lower teeth without wearing away the plate, which would interfere with their outward movement. The metal can be attached when the plate is being made, or riveted to the plate with large pins at a later time. Additional layers of metal can be attached as required with soft solder, using a soldering iron, first tinning the surface of the metal.

When at the same time upper incisors are to be moved inward, there being spaces, a similar plate with a semicircular spring extending around the front of the arch, as illustrated in Fig. 338, can be employed, or finger-springs, as shown in Fig. 242. As the upper incisors are moved inward with the spring, the anterior edge of the plate should be dressed away a little as required to permit their movement. For retaining, the same plate should be worn for several months after the teeth are in position.

The lingual surface of the upper incisors forms a curved incline reaching from near the cingulum to the morsal margin, and when the teeth are forced inward nearly in contact with the lower incisors, if it is found that the upper incisors need to be depressed,

Fig. 338.

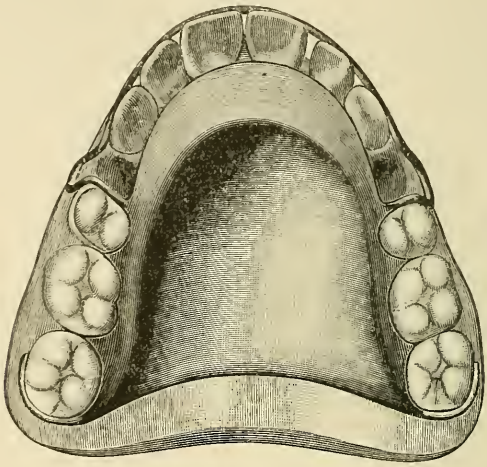

the pressure with the springs should be continued, driving their inclined surfaces against the edge of the plate. This will force them more deeply into their sockets. If any further shortening of the upper incisors is required, a collar with a lug on the labial side (Fig. 339, *a*) can be cemented to each of the teeth to be moved, having the lugs in position so that the spring (*b*), passing in front of the teeth, will rest below the lugs and cause an upward pressure on them.

When it is necessary to elevate the incisors the spring should be arranged to rest above the lug, causing downward pressure.

In Fig. 340 is shown a simple device for depressing the upper incisors, made by bending a narrow piece of plate-metal into an S-shape, with one end (*c*) formed to hook over the edge of one or two of the incisors, and the other end to hook over the spring (*b*). The metal can be soldered to the spring when desired. Lower incisors can be depressed in a similar manner.

Several years since a method was devised of depressing both the upper and lower incisors at one time (Fig. 341), by cementing to each of the upper incisors to be acted upon a thin gold collar, with a

piece of plate-metal shaped in the form of a shallow trough soldered to the lingual side (*d*), into which the lower incisors thrust as the teeth come together.

When the upper incisors are in good line it is sometimes preferable to cement to them a metal cap struck up with dies and having a properly shaped trough soldered on the lingual side. Fig. 378 illustrates a similar cap, with arms projecting backward from it on each side of the arch to rest on the grinding surface of the molars, that was used to depress the incisors, and at the same time to sustain the position of the upper incisors as they were being moved bodily inward.

When both the upper and lower incisors are extruded, with the lower incisors in good line and upper ones too prominent, an apparatus for their correction can be made for the upper arch by arranging a heavy lingual base-wire far enough back of the incisors to permit the lower ones to rest in front of it in occlusion, and anchored with partial-clasps and spring-clasp attachments. To the base-wire (Fig. 342, *e*) is soldered plate-metal, shaped in the form of a

Fig. 339.

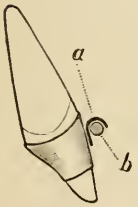

Fig. 340.

Fig. 341.

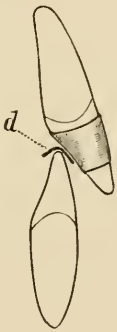

Fig. 342.

cap or inclined plane, sloping forward and downward, fitting the lingual side of the upper incisors near the gum. Strips of plate-metal are attached to the cap and project from it, with the ends bent up in the form of hooks to pass over the edge of the upper incisors, extending about one-third or one-half the length of their crowns to rest on the labial side, as seen at *f*, as further illustrated in the following cut. The apparatus is so adjusted that when the teeth strike in occlusion force is applied both to the upper and lower incisors, driving them into their sockets. The pressure is increased

by curving the strips of metal upward and backward towards the base-wire from time to time; this gradually depresses the incisors, at the same time moving the upper ones inward. The lower incisors are held in an upright position by their occlusion in front of the base-wire.

When both the upper and lower incisors are too prominent and need to be moved inward and at the same time forced into their sockets, a similar apparatus with strips of plate-metal attached to a lingual spring base-wire can be employed (Fig. 343). The wire should have U-shaped loops in it, one arranged on either side of the arch opposite the cuspid or first bicuspid. The gradual closure of the loops causes traction, forcing inward the upper incisors, while the downward slope of the metal acts like an inclined plane, gradually forcing the lower incisors inward and downward.

Fig. 343.

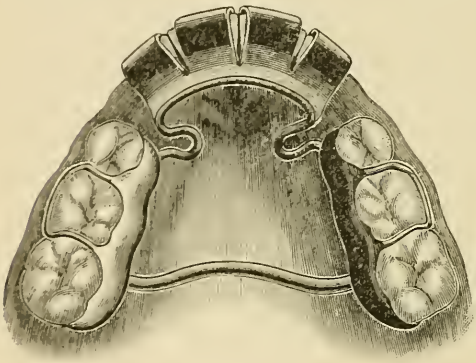

For depressing the upper incisors and moving them inward, where more pressure is required, occasionally it is advisable to apply external force with a cross-bar (Fig. 69).

Fig. 344.

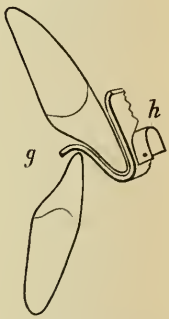

An apparatus that has been used to good advantage, generally in connection with other apparatus, for depressing upper and lower incisors in cases of double protrusion, and at the same time moving them inward, is illustrated in Fig. 344. A metal cap with a lingual flange (*g*) is fitted to the upper incisors; the lower incisors rest against the flange in occlusion. A socket on the labial side (*h*) is sometimes provided for the application of supplemental force with a cross-bar.

When desirable, the cap is cemented to the teeth, especially when used for retaining (Figs. 508 and 509).

Teeth that have been moved by any of the methods described should be retained for a considerable length of time.

Fig. 345.

Dr. Goddard has described a method of depressing the lower incisors with external anchorage as follows:* "A metal-cap is swaged to fit over the occlusal edges. To this is soldered a wire that extends out of the corners of the mouth and is bent into hooks one at each end. From these hooks rubber bands extend to a chin-piece. To prevent this chin-piece from sliding forward it is necessary to extend a tape from it around the patient's neck."

Fig. 345 illustrates a method I devised for depressing the lower incisors. A chin-cap and wire standards are supported by a cranial-cap. A *depressing bar* (Fig. 346) is made on a model by fitting a narrow strip of plate-metal over each of the teeth to be moved. Across

Fig. 346.

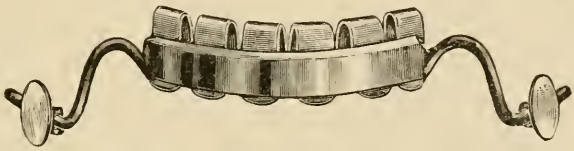

the front of them is soldered a wire shaped to the arch, its ends projecting over the lower lip at the corners of the mouth and bent backward, where a small metal knob is soldered. Pressure on the teeth is produced by hooking elastic bands over the knobs and to knobs on the lower part of the chin-cap. The latter are adjustable, being moved backward or forward on the standard and screwed to place to change the line of traction.

When a thickened plate (Fig. 337) is used for depressing the lower teeth, the operation is hastened by upward pressure with a chin-cap.

Shaping the Teeth.—The operation of depressing teeth in their alveoli is frequently a prolonged one, and it is necessary that they be retained a considerable length of time. When this procedure is not considered judicious, dressing of the teeth may be employed to improve the contour of those that have become extruded. Dressing is also employed for evening-up teeth to improve the occlusion, for improving the surface and contour of those affected with abrasion, to level, making smooth the surfaces of those that have been fractured, and to dress away the uneven surfaces of teeth after regulation for improving their appearance and occlusion. When teeth have become extruded from natural causes, as from lack of occlu-

* Goddard, American Text-Book of Operative Dentistry, 1897, p. 643.

sion, from calcareous deposits about their roots or pyorrhœa alveolaris, or from the lateral crowding of teeth from peculiar occlusion, it is generally better to dress their surfaces rather than to depress them in the alveoli.

The two following cases, one of extrusion and the other of abrasion, were described and illustrated by Dr. How.* Fig. 347 shows

Fig. 347.

Fig. 348.

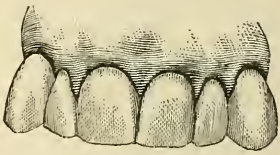

an elongated condition of the upper incisors, which was improved by dressing away their surfaces, as seen in Fig. 348, thus attaining a pleasing appearance without material detriment to the teeth. This is best done with a corundum stone or file, after which they should be thoroughly polished. Fig. 349 represents a case where the lower incisors had become abraded, leaving them jagged, with some

Fig. 349.

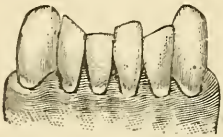

Fig. 350.

of the teeth much longer than others. Fig. 350 illustrates the result after the teeth were shaped by dressing.

Cases of abrasion are common, often affecting the cuspids, bicuspids, and molars, as well as the incisors. When the enamel is worn away the dentine, being less dense, wears more rapidly and becomes hollowed out, leaving the sharp edge of the enamel projecting. Fillings should be inserted in these depressions, or the projecting surfaces dressed smooth and polished to stay the progress of attrition, otherwise the roughened edges would continue to gouge away the enamel and dentine of the antagonizing teeth.

When the incisors are crowded, rotated, or overlap one another, requiring slight additional space for their correction, it can some

* How, Dental Cosmos, 1886, p. 741.

times be gained by dressing the approximal surfaces of the teeth slightly, thus relieving the necessity of extraction or the expansion of the arch, but never dressing to the extent of removing all of the enamel from any part. The writer usually favors the dressing of the approximal surfaces of the bicuspids and molars when sufficient space can be gained in that manner. The proper shaping of approximal surfaces that have been crowded and rotated often gives a suitable bearing for retaining the teeth in an harmonious position (Fig. 514).

A gratifying result has been obtained by grooving longitudinally the approximal surfaces of a crowded, irregular lower incisor, and rounding the crowns of the adjoining ones sufficiently to fit into the grooves, which supported the tooth and prolonged its usefulness for several years.

Dressing the surfaces of the teeth is called for in some instances, to improve the occlusion after their regulation, as reshaping the cusps of the bicuspids and molars, making them fit better into the sulci of the teeth or the interproximate spaces of the opposite arch. The writer has resorted to this practice for adults after jumping the bite, thus establishing a new occlusion. The value of the operation has been proved by the permanence of the improvement after many years.

Teeth that have become extruded in the process of regulation should not be dressed away until after an interval of time, permitting them to settle into their sockets.

CHAPTER XVI

INCISORS, TO ELEVATE

This chapter will describe the construction of apparatus for causing the elevation of incisors in cases of improper or tardy development; of teeth retained by impaction; and for the elevation of incisors that have lost part of their crowns from accidental fracture.

Fig. 351 illustrates an appliance arranged for the elevation of an upper incisor. A broad collar with two tubes soldered perpendicularly on the labial side is cemented to the tooth to be elevated. The ends of the tubes are far enough from the gum to permit the insertion in each of a small-sized spring-wire, which is bent at a right angle to

Fig. 351.

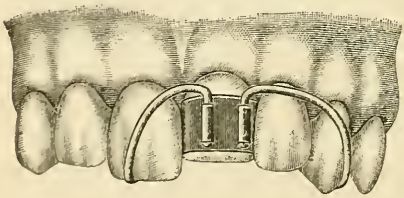

Fig. 352.

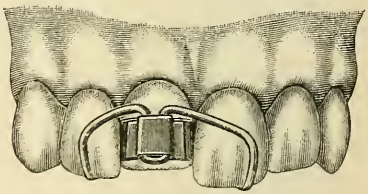

enter the tube. The free end of each of the wires is curved downward and shaped to hook a little over the grinding surface of one or more of the adjoining teeth. Force is applied by changing the curve of the springs.

In place of the perpendicular tubes, a box-shaped attachment can be made to the collar (Fig. 352) for the admission of a U-shaped loop of spring-wire, with projecting arms entering from above downward, made as described in connection with Fig. 309. The ends of the arms of the spring are shaped to catch over the grinding surface of two or more of the adjoining teeth. When there is but a slight difference in the apparent length of the teeth, they can be brought to the same level with a device as described in connection with Fig. 306 or 308.

Fig. 353 illustrates a simple device for elevating a retarded incisor. It is made by fitting two small saddles in the form of caps

to pass over two or more teeth on either side of the incisor to be elevated, the caps being of very thin metal, as platinum. They are shaped to the teeth by pressing the metal over them with a piece of hard rubber, with the assistance of the patient biting upon it; or the metal can be swaged. A small spring-wire is shaped to cross the labial side of the teeth, then bent at right angles with the ends curved to hook over the saddles at the junction of the teeth. The ends of the spring should be attached to the lingual side of the saddles with solder, using enough to stiffen the metal of the caps, but it should not be attached to the labial side, as it would interfere with its springiness. A collar with a short pin soldered to the labial side is cemented to the tooth to be moved. Force is applied by adjusting the apparatus and springing the bar over the pin, bending downward the central portion of the bar from time to time as additional pressure is required.

Fig. 353.

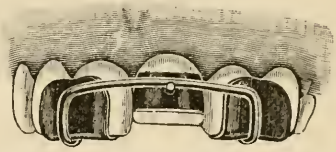

When the force is not sufficient, a similar bar can be made to extend on the lingual side of the teeth, suspended from the saddles, and made to extend below a lug similar to the one described. If the tooth to be moved is wedged between the adjoining ones, the space can be increased by straightening the curves of the spring near the attachment to the saddles, lengthening it slightly.

Fig. 354.

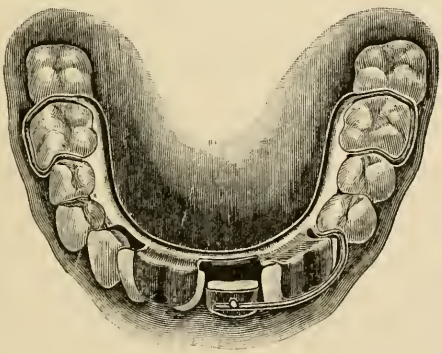

A removable device with a finger-spring for elevating teeth of the upper or lower arch is made by anchoring a lingual base-wire with spring-clasp attachments, having plate-metal shaped to hook over several of the teeth on either side of the tooth to be elevated (Fig. 354). It is to be soldered to the base-wire on the lingual side. A finger-spring is made to extend from the base-wire over the arch at the junction of two of the teeth and extend forward, passing under a lug on a collar cemented to the tooth to be moved. When used in

the lower arch, the necessary force is supplied by bending upward the spring slightly from time to time.

If two or more teeth are to be elevated, or if more force is required, an additional finger-spring can be attached in a similar manner to the base-wire on the opposite side of the arch, or the spring can be made continuous, each end extending over the arch and soldered to the base-wire. This apparatus does not interfere with the occlusion; the spring is readily controlled, graduating the force, and is easily removed for cleansing.

Fig. 355 illustrates an appliance that was used for the elevation of a right upper central incisor that had been fractured. Both

Fig. 355.

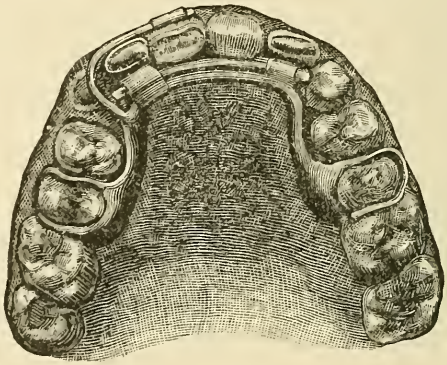

upper lateral incisors had erupted in a twisted position. They were rotated mesio-lingually by means of a device as seen in Figs. 312 and 313, there having been a collar with a tube on the lingual side cemented to each of the laterals to accommodate the device for rotating, after which a slightly curved wire was passed through the tubes for retaining, as seen in the figure. About one-third of the crown of the right upper incisor was lost by an accident. The appliance for its elevation was made by forming a lingual base-wire to pass just back of the tubes and wire on the lingual side used for retaining, with the ends extending backward to be soldered to a spring-clasp attachment for anchorage over each of the second bicuspids. The right deciduous cuspid was absent and the permanent one had not yet appeared. A spring-wire was soldered to the base-wire on the right, and passed outward to the labial side through this space; there it was bent forward and shaped to rest in a hook on a collar

that was cemented to the incisor to be elevated. The front part of the appliance was supported and prevented from pressing against the gum by soldering pieces of plate-metal to the base-wire on either side, having them curved in shape to hook over and rest on the tubes on the collars cemented to the laterals. Force for elevating the tooth was caused by bending downward the end of the spring.

In Fig. 356 is illustrated a device recommended by Dr. Goddard for the elevation of a fractured incisor, the object being to elevate the

Fig. 356.

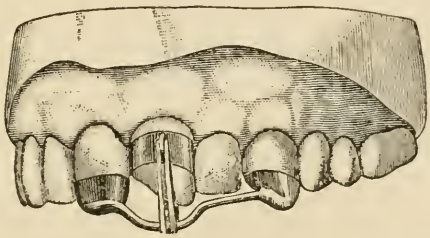

incisor, then to dress the edge sufficiently to bring it into harmony with the adjoining teeth.* The apparatus is made by fitting to a tooth on either side of the one to be moved a cap having a stiff bar of metal shaped to connect the two, and curved downward in the centre to pass below the tooth to be moved. A collar having a spur on the labial side and another on the lingual side is cemented to the incisor, and the necessary force is got by stretching a rubber ligature over the bar and hooking it to the spurs on the collar.

The gradual elevation of a tooth usually drags the gum and the process with it, and accordingly, when the edge is dressed away in the manner described, it causes a shortening of the crown as compared with the adjoining ones. Teeth moved in this manner should be retained a long time, as invariably there is a tendency for the process and tooth to return to their original position. Separating the gum from the neck of the tooth from time to time during the regulation causes the gum to recede, and results in an apparent lengthening of the crown. Another complication is the overlap of the bite. As the upper incisor is forced downward, the occlusion with the lower incisors causes it to become too prominent. This

* Goddard, American Text-Book of Operative Dentistry, 1897, p. 595.

can be overcome only by grinding the lingual face of the upper incisor enough to cause a proper occlusion, or by forcing the lower incisors inward or downward. The latter procedure I do not regard with favor.

The elevation of cuspids, bicuspids, and molars is effected by similar apparatus. (For further reference, see their respective chapters.)

Generally the teeth of young patients move easily, but a considerable force is sometimes required for the elevation of the teeth of adults, especially of malposed and impacted incisors and cuspids, and those retarded as a result of trauma. In correcting these conditions, supplemental force is introduced to advantage. Fig. 357 illustrates a device used for the elevation of the upper teeth when considerable force is required. A metal chin-cap and wire standards supported by a cranial-cap is made as described in connection with Fig. 144. To the lower margin of the chin-cap is attached an adjustable knob. A strong collar with a tube, eyelet, or flange, soldered usually on the labial side, is cemented to the tooth to be moved. A small wire, No. 18 gauge, is shaped to hook into the tube, and a loop formed to extend outward and downward over the lower lip to rest on the front of the chin-cap. Through the loop of this wire is passed a rubber band, or one end of a coiled spring, extending downward and held by the knob. The amount of tension is governed by the requirement of the case. Always begin with slight force and increase it gradually, the wire being of sufficient length to permit the use of a band of small diameter. The force is to be increased by using a heavier band, thus preventing the too sudden movement of the tooth and stretching of the pulp, obviating the danger of strangulation.

A similar device, with apparatus in the mouth, was employed in the case of Miss B., aged twenty-three years. The right upper central incisor was considerably shorter than the adjoining teeth. The history was somewhat obscure. The patient thought that the tooth was gradually settling back into the socket. On very close inquiry, it was ascertained that some years previously a blow had been received on the tooth. From a radiograph it was found that the root was straight and that no adhesions were perceptible, but it was evident, from the ankylosed condition, that the peridental membrane had been injured, and in the healing process a bony deposit had taken

Fig. 357.

place, connecting the root with the process. (Figs. 30 and 31 illustrate a case of injury with the roots deflected.) Luxation of the tooth was advised, but the patient objected. Rubber rings with the apparatus were applied in the manner described, the force being increased gradually until two heavy umbrella rings were employed, being worn at night and several hours during the day. The tooth has been elevated somewhat, but at the present writing is not in satisfactory position.

For the elevation of lower teeth, supplemental force can be applied with the apparatus illustrated, by soldering a spring to the front of the chin-cap, the spring being suitably formed to pass over the lower lip and attached to the teeth. The chin-cap is sustained by a rubber band extending from either side of the cranial-cap, the tension being increased by changing the adjustable knobs on the standards, or using a heavier band.

CHAPTER XVII

INCISORS, TO MOVE BODILY

Lateral Bodily Movement of Incisors.—Procedures to cause the lateral movement of the roots of the incisors through the alveolar process have been known to the profession for several years.* The operation consists in moving the root and crown of the tooth in the same direction, the alveolar process being absorbed for the movement.

Formerly this manner of moving the teeth was utilized principally for drawing together upper incisors that had erupted considerably apart, and for the correction of cases where, from continued development of the jaw and process after the eruption of the incisors, the space between them had become unduly broad, the roots of the teeth in their alveoli being farther apart than should be to permit the crowns to take a proper relative position when drawn together with an ordinary apparatus.

The best method of treatment for these conditions can only be determined by a careful study of the case at hand. When the space between the teeth is very broad, it is generally the wiser plan to insert one or more artificial teeth supported by a carefully adjusted appliance. When the artificial teeth do not present a pleasing appearance, sometimes the space can be increased to advantage for the admission of wider teeth.

If the incisors are to be moved a considerable distance, and force is applied with an ordinary device, the crowns are made to incline towards one another without materially moving the upper third of their roots. The teeth in this position have a very unpleasing appearance.

Dr. Farrar in his work on Irregularities, describes a novel device for moving the roots of the incisors with the crowns laterally towards one another. Around the crowns of the teeth to be moved, and near the gum line, he passes a clamp-band made of a narrow strip of thin plate-metal, the ends connected with a threaded bolt and

---

* Farrar, Dental Cosmos, 1882, p. 190.

nut in such a manner, that by turning the nut the band will be shortened. A secondary screw is arranged between the crowns of the teeth near their incisive edge so that it can be turned, permitting the ends of the crowns to approach one another as the roots are drawn together by the clamp-band, the intention being to have the roots and crowns of the teeth remain parallel to one another, or in the same relationship throughout their movement.

An appliance that I have devised for moving the teeth bodily is shown in Fig. 358. The upper central incisors were erupted with a

Fig. 358.

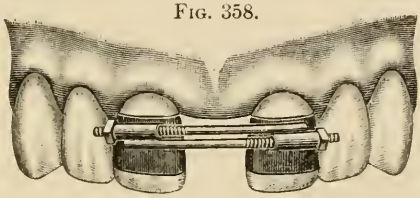

considerable space between them, having assumed a position close to the cuspids, the lateral incisors being absent.

A strong, broad collar is adjusted to each of the central incisors. To the labial side of each of the collars is soldered horizontally a short tube with one end even with the distal surface of the collar. By the side of each of the tubes is attached one end of a stiff wire arm long enough to span the space between the teeth and to pass through the tube on the opposite collar. Both of the collars are cemented to the teeth at the same time, the arms resting parallel, with the free ends passing through the tubes. By this device the teeth are held continuously in the same relationship while being moved together and retained.

Force is usually applied by means of a thread cut on the free ends of the arms, on which are run threaded nuts. The nuts are turned from time to time for moving the teeth. As the teeth approach each other the arms will project more from the ends of the tubes. If they interfere with the action of the lip, they can be cut off or bent backward. When desired, a spring rather than a screw can be utilized for applying the force, the spring being formed and attached to a base-wire ; or a suitably shaped spring can be used in addition to the long arms. (See Figs. 287 and 288.) Cord ligatures or rubber bands may be used, but their movement is not so regular, and more attention is required to obtain the desired result.

The attachment of a long tube on the front of each collar, through

which is passed a threaded bolt with a thick nut and a strong thread for causing traction, is applicable when the teeth are to be moved but a short distance.

The too rapid movement of the teeth is always objectionable. The alveolar process is gradually absorbed as the roots of the teeth are moved towards one another, and if the apices of the roots are moved too rapidly through the process there is always danger of strangulation of their pulps. Especially is this the case with the adult, as the process, being more dense, is not absorbed so readily.

In young patients, when the roots of the central incisors diverge to such an extent as to give an unpleasant appearance of the crowns of the teeth, they can be forced together with a device as illustrated in Fig. 359. A collar with a tube soldered perpendicularly on the mesio-labial surface is cemented to each of the incisors. The ends of a spring-wire are bent at a right angle, making the width between

Fig. 359.

Fig. 360.

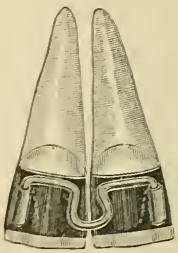

the parallel sides equal to the width of the two teeth. The arms of the spring are then bent towards each other, and again bent sharply at a right angle towards the main portion of the spring to pass through the tubes, usually from above downward, leaving the body of the spring to pass close underneath the ends of the tubes. To draw the roots together force is caused by bending the ends of the spring slightly from time to time where they enter the tubes, bending them laterally from the median line in the direction of the dotted lines.

This device may be used for separating the roots of the incisors when desirable, as in case of diverging crowns (Fig. 360). In such a case the tubes on the collars should be located on the labio-distal surface, and the spring made with a loop in the centre, the ends bent outward and again downward at a right angle to enter the

tubes. Force is got by bending the ends of the spring where they enter the tubes a little at a time towards each other in the direction of the dotted lines. It is essential that the spring be fitted carefully to place, to cause pressure only in the direction required as force is applied. Bend the ends of the spring slightly at a time, and equally, to prevent the lengthening of either of the teeth. The centre loop of the spring may be opened by bending when desired for increasing the distance between the crowns, or *vice versa*. The teeth should be retained a long time. Generally the same or a similar device is suitable.

When the lower incisors in the process of eruption assume a fan-shape, with the apices of the roots crowded together (Fig. 361), they can sometimes be forced into a normal position as respects the base of the alveolar ridge by a device similar to the one previously described. A collar with a perpendicular tube on the labial side is cemented to each of the lateral incisors, the tubes being placed near the labio-distal surface. A spring-wire is bent into a short U-shaped loop to rest opposite the central incisors; the ends extend outward and are bent downward at a right angle to enter the tubes. Force is applied by bending the ends of the spring outward slightly, and when necessary adjusting the length of the spring by changing the width of the U-shaped loop, which moves the roots laterally from the median line to an upright position. If the appearance of the central incisors is not sufficiently improved by the manipulation, they can be corrected in a similar manner.

Fig. 361.

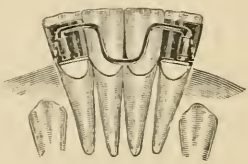

Early in practice I moved the incisor teeth bodily, both anteriorly and posteriorly, without changing their angle. (See *Dental Cosmos*, 1887, page 385, and 1888, page 512.)

In but a small percentage of the cases presented for treatment requiring the incisors to be moved outward or inward is it found necessary to adapt special apparatus and move them bodily, and again but a few of the cases that are so treated meet the full expectations of the operator, especially when the operation is performed upon an adult. After the teeth and bone have been moved, in the healing process there is always a contraction similar to the contraction of scar tissue after a wound; and if an ordinary retainer is applied which does not hold the teeth bodily, this condi-

tion will force the roots of the teeth towards their original position, which gives an unpleasant appearance of their crowns. Moving all of the incisors outward at one time by force applied to their crowns carries more or less of the alveolar process with them, particularly the outer table. With young patients the stretching of the premaxillary bone encourages its development. The suture between the premaxillary and the palatal processes of the maxillary bones is not fully united in early childhood. Flat bones grow from their edges. The premaxillary may be numbered with this class; during its development it can be encouraged by pressure to take on a different form, and therefore better results are obtained if the change is made while the alveolar process and jaws are in this active stage of development. In any case, the continued retention of the teeth in their new position for a considerable length of time, to permit the process to become firm around them, is essential. This is sometimes difficult to accomplish while the bones and process are still developing and before the bicuspids are fully erupted. Space for the accommodation of the permanent cuspids should be constantly preserved. If the deciduous cuspids are absent, with insufficient room for the permanent ones at about the time of their eruption, the case should be carefully examined to determine whether the roots of the lateral incisors are sufficiently in front of the incoming cuspids to permit the latter to take a correct position. The roots of the lateral incisors are somewhat flattened laterally, and they should be located so that the incoming cuspids will not rotate them. These precautions are necessary when the anterior region of the upper arch is not sufficiently prominent to harmonize the features. It is difficult sometimes to determine fully before the tenth or twelfth year how the jaws are going to harmonize as to their fulness, and when the deformity is not very marked it is usually advisable to defer operating until a satisfactory diagnosis can be made.

Outward Bodily Movement of Incisors.—The first appliance that I devised for moving the teeth bodily outward was made for improving the position of four upper incisors. A metal cap of No. 29 gauge, made with accurate metal dies, was attached to the incisors (Fig. 64). To the lingual side of the cap near the gum were soldered two heavy wire arms, extending backward and following the inner curve of the arch, one on either side, near the bicuspids and molars. Holes were made in the labial and lingual

sides of the cap, in position to accommodate wire ligatures passing between the teeth near the margin of the gum. The cap was fastened to the teeth by first passing the ligatures between them and the holes in the edge of the cap, drying the teeth carefully, and setting the cap with cement, hastily drawing the ligatures up firmly and twisting their ends. The anchorage for moving the teeth was secured by shaping a partial vulcanite plate to the palatine arch, covering the arms described. In these places the plate was thickened, forming grooves, extending from front to back on the lingual side, for the accommodation of the arms.

The plate was retained with wire-clasps passing around the first bicuspids and first molars. Each arm had a small projection or knob soldered to the side of it, made long enough to project through the surface of the plate to engage with springs for supplying the force, the plate being dressed away in these parts down to the grooves to expose the knobs, and to form a short slot in front of them to permit the movement. Two springs for this purpose, one on either side, were attached in the anterior third of the plate, and shaped in a double curve to extend back of and engage with the distal side of the knobs on the arms, thus giving the desired pressure forward.

Several methods of making attachment to the teeth will be described. To the incisors a fixed attachment may be made with collars, soldering to them a heavy lingual base-wire, with the ends extending backward in the form of arms; or by arranging on the inner curve of each side of the arch a forked arm, one of the forks being soldered to a broad collar previously fitted to the central, and the other soldered to a similar collar on the lateral. With the arms forked in this manner, the collars are easily adjusted for cementing. The free ends of the arms project backward to be supported, and engage with springs in a plate in the manner mentioned; or force can be applied from a metal anchorage. To make the long arms removable for cleansing, etc. (Fig. 362), solder a strong short arm to the lingual side of each of the collars, or to a metal cap, the arms pointing backward parallel one with the other, to project into strong tubes attached to a lingual base-wire, or to forked arms. The tubes, if required, should be a little larger in the mesio-distal diameter to allow for any side variation in the line of the posts, and to permit of easy removal. This connection can be made in the reverse

manner by soldering the tubes to the collars, and the arms shaped to project into the tubes. The anchorage usually consists of spring-clasp attachments to the first bicuspids and first molars, the sides being connected by a palatine base-wire. Each end of the base-

Fig. 362.

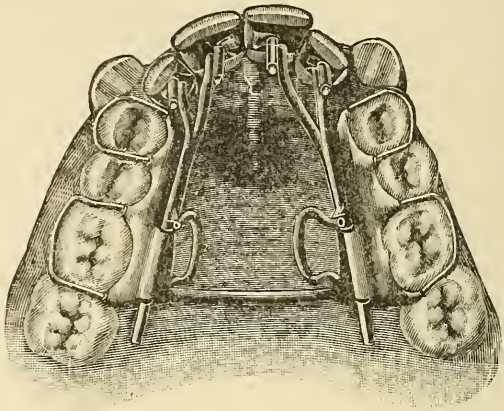

wire, a tube, and one end of a U-shaped spring pointing towards the roof of the mouth, are soldered to the partial-clasps opposite the molars, the tubes being properly placed for the support of the arms. Each arm is provided with a flange to engage with the free end of the spring. Force is applied by bending the ends of the springs forward.

Later the system of attachment of the arms to the teeth was simplified by soldering horizontally to the lingual side of each of the collars a small loop of flat or round metal, to engage with suitably shaped spurs projecting downward and forward from the anterior part of a lingual base-wire. This attachment is in effect like a hinge that comes to a full stop when the distal part of the arm is pressed into place. It holds the teeth in the same relationship to the base-wire when force is applied, but it is easily unhooked for removal.

This form of attachment is also available for moving the incisors bodily inward by reversing the hinged attachment of the base-wire arms, having the loops or eyelets near the necks of the teeth.

Fig. 363 illustrates another method of making an attachment on this principle. To each of the incisors to be moved is cemented a collar with a hook-shaped flange on the lingual side nearly as broad as the width of the tooth, and bent at a right angle towards the

gum to engage with spurs projecting downward from a lingual base-wire. The base-wire is forced forward with a spring device, as in Fig. 369.

When the incisors are nearly in a line, cementing to them a swaged metal cap, covering all of the teeth to be moved, is sometimes preferable to the use of collars (Fig. 364). The base-wire is

Fig. 363.

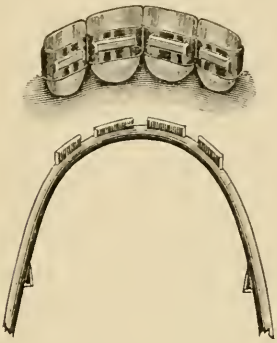

Fig. 364.

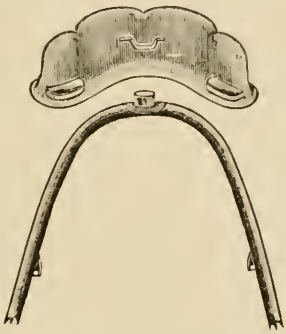

attached to the cap in an adjustable manner by soldering one or more loops to the lingual side of the cap to engage with spurs on a base-wire. One loop should be placed at the median line, and a shelf-like projection near each of the distal ends to support and hold the cap and bar in the same relationship as force is applied; or a short post may be soldered to the disto-lingual sides of the cap to engage with tubes on the base-wire.

Fig. 365.

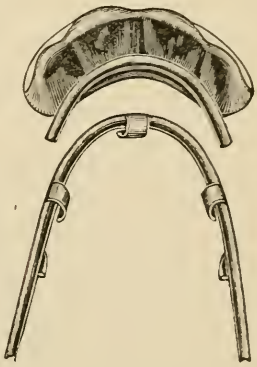

Another method of making this connection is illustrated in Fig. 365. A large semicircular wire is soldered to the lingual side of the cap near the gum, with the ends projecting a little. To a lingual base-wire of the same curve is attached one or more flanges that project upward and curve outward to engage with the upper surface of the semicircular wire attached to the cap, the base-wire being removable as described. As force is applied, the flanges lock with the semicircular wire on the cap.

Several variations from these forms of attachment have been devised. One that has proved convenient is made by soldering two

horizontal planes to the lingual side of a cap, as illustrated in Fig. 366. The planes are formed of two pieces of plate-metal cut on a curve, the space between the planes being just sufficient to pass either side of the base-wire.

Fig. 366.



This form of cap was employed in moving the upper incisors outward bodily for Miss S., aged seventeen years. The history of this case is interesting. Fig. 367 illustrates a cast of the features before regulation. The patient had been afflicted with nasal disease since childhood. There was a lack of development of the upper maxilla; the region of the face about the upper lip was much depressed and wanting in rotundity. The incisors were rather regular, with the lateral incisors standing a little back of the line of the centrals (Fig. 368). The lateral on the right side rested in contact with the first bicuspid, the cuspid having erupted anterior to them. On the left side the cuspid was also very prominent, with a narrow space between the lateral incisor and first bicuspid. The upper incisors closed considerably back of the lower incisors. The arch in the region of the bicuspids and first molars was poorly developed, being considerably narrower than that of the lower arch, with only two or three teeth occluding.

The patient was extremely anxious to have the deformity corrected, and was referred to me after having applied to several prominent operators for treatment. One practitioner advised the extraction of the cuspids; others said that nothing could be done.

The metal-cap accurately made with dies was cemented to the incisors to be moved. For anchorage a spring-clasp attachment was formed over the first bicuspid and the first molar on either side of the arch, and partial-clasps on the second bicuspids and second molars (Fig. 369). These parts were connected with a palatine base-wire crossing the arch opposite the distal surface of the first molars, with the ends bent at right angles to rest on the partial-clasps. By each end was attached a tube for holding the curved arms of a lingual base-wire. All was united by solder, joining at the same time the spring-clasps, partial-clasps, base-wire, and tubes, and also two springs for causing force, one on either side. These were formed into U-shaped loops resting in front of the base-wire, and made to point upward into the arch towards the median line following the palatal curve. One end of the spring being united

Fig. 367.

Fig. 368.

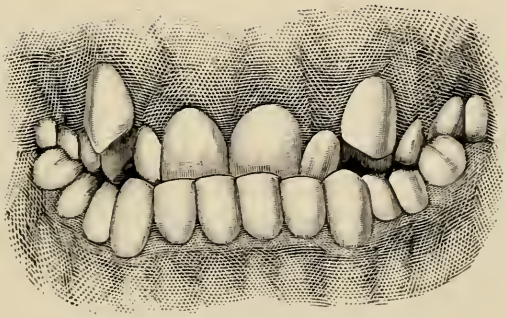

with solder to the base-wire near the tubes, the other end projected above and was made to catch back of a knob that was soldered on the side of the arms. All of the appliance except the metal cap over the incisors was removable by first unhooking the springs from the knobs, and sliding the arms backward through the tubes sufficiently to disengage the curved portion of the lingual base-wire from the groove formed by the planes on the cap, and drawing downward on the spring-clasp attachments. The appliance was removed daily by the patient for cleansing.

The necessary force for moving the incisors outward was applied by opening the loops in the springs by bending, and again springing

Fig. 369.

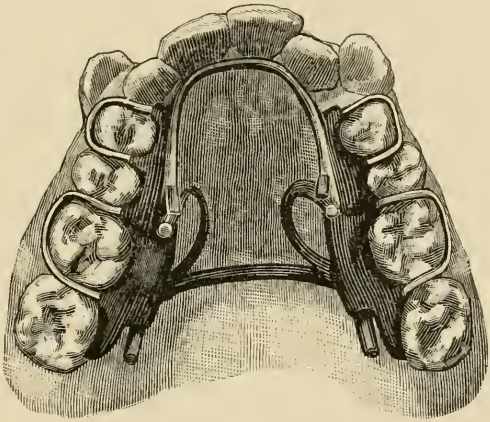

the ends back of the knobs on the arms. The changes were made at first about once a week, and later not as often.

The appliance as shown in the figure was inserted on April 26, and by the constant gradual force applied the incisors were moved outward, as seen in Fig. 370, on September 8, when it was found advisable to commence expanding the arch laterally. For this the same apparatus was employed by simply cutting a narrow section from the heavy palatine base-wire that crossed the arch, and soldering to the remaining ends the ends of a U-shaped loop of wire of the same size for forming a spring as seen in the figure. It will be readily understood that it would not have been advisable to commence expanding the arch laterally by moving the bicuspids and molars outward until after the incisors had been moved outward

nearly as far as it was intended they should go, as the teeth for anchorage, having been once moved, would not form a sufficiently fixed point of resistance for causing the required force.

Fig. 370.

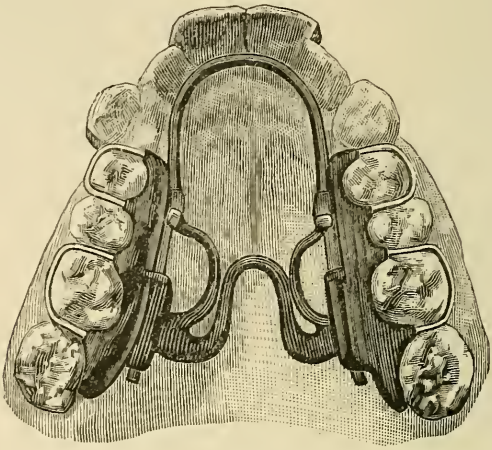

The arch was expanded by bending the loop in the palatine spring base-wire, broadening it slightly, and at the same time aiding the force by bending outward the sides of the lingual sliding base-wire

Fig. 371.

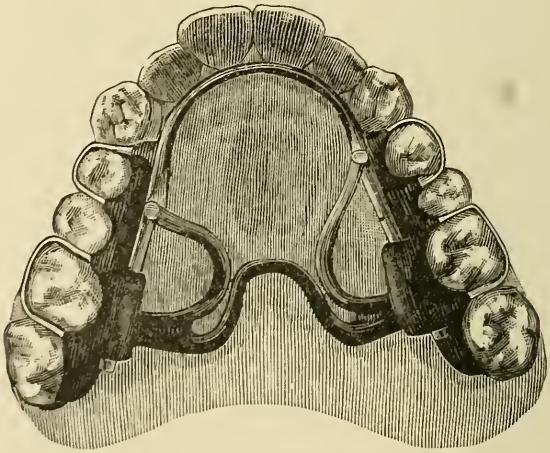

forming the arms. The metal cap had not been removed from the incisors. It will be remembered that the lateral incisors originally held a position a little back of the line of the centrals. When the

Fig. 372.

Fig. 373.

arch was nearly expanded they were moved outward into line by cutting away a portion of the metal cap just in front of them and forcing absorbent cotton between them and the cap on the lingual side. The lateral incisors gained a correct position at about the time the arch was sufficiently expanded. Fig. 371 illustrates the apparatus, the expanded condition of the arch, and the position of the teeth on the following May 14.

The remaining portion of the cap was removed from the incisors, and for retaining them a larger cap, to include the cuspids, was made of gold plate and cemented firmly to place (Fig. 509).

To retain the teeth of the distal part of the arch a vulcanite plate was made to cover the palatine portion, fitted well to the gold cap and to the necks of the teeth.

As was natural after this extreme expansion, the teeth of the upper arch did not occlude as well as was desired with those of the lower, and a chin-cap for pressing the teeth of the lower jaw forcibly against those of the upper was used, as shown in Fig. 372, the apparatus being worn at night and as many hours as convenient during the day for a few weeks, then regularly at night. By this means the teeth settled together so that an even and good occlusion was secured. The plate and gold cap over the incisors was worn continuously for over two years, the case being examined frequently and the cap reset three times. The patient was instructed to continue the use of the palatine plate and the chin-cap for a longer time.

A metal cap with two horizontal planes similar to Fig. 366, with an appliance, was utilized for moving outward bodily two upper central incisors for Mr. A., aged twenty-two years. The lateral incisors had been extracted years before by an inexperienced practitioner. The cap was fitted to the incisors and the horizontal planes attached to the lingual side. The one next the gum was made of stiff metal and rather broad, extending backward opposite the cuspids in the same curve as the base-wire. The base-wire rested on this, passing between the planes as before, which gave a suitable bearing for moving the incisors. After regulation a plate with two lateral incisors was applied to fill the spaces and retain the centrals.

In moving teeth outward, especially in moving them bodily, considerable force is sometimes required. When desirable, supplemental force can be applied (Fig. 373). To the labial side of a metal cap

over the teeth or to collars is soldered an eyelet or other shaped device for the attachment of a supralabial bar. A chin-cap is supported by wire standards and a cranial-cap. To the band of the cap on each side is attached one end of a suitably sized tube extending downward in front of the ear; into this tube the wire standard is made to pass. To the lower end of the tube is attached an adjustable knob, and another to the standard below the end of the tube. Over the knobs is passed a rubber band. The lower knob is located so as to give just enough tension of the elastic to retain the apparatus in place when in use. The supralabial bar is made of wire, No. 12 gauge or larger, formed to pass in front of the face, with a U-shaped loop arranged near each end, extending upward or downward in front of the standards. To each end of the wire is soldered a rigid piece of plate-metal that has a deep notch cut into the distal edge (Fig. 374, *a*, *a*) sufficiently large to hook onto the adjustable knobs of the standards for holding the bar in place; or,

Fig. 374.

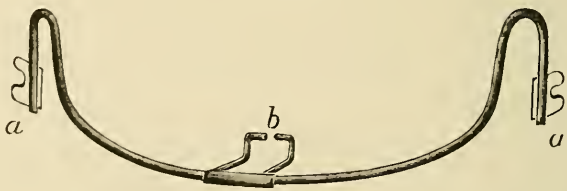

instead of the plate-metal, the ends of the wire may be bent into the form of a hook to engage with the knobs. At the centre of the supralabial bar is attached a wire (*b*) shaped suitably to hook into the tube, eyelet, or other form of attachment. Force is applied by opening the loops of the supralabial bar a little at a time. Too much force or force too suddenly applied is always objectionable. The adjustable knobs can be moved up or down on the tubes for improving the line of traction. The wire standards passing into tubes in this manner permit the movement of the lower jaw without interfering detrimentally with the action of the supralabial bar when it is used for either anterior expansion or the contraction of the arch.

Fig. 375 shows the position of the teeth of Mr. S., aged twenty-two years.* The upper maxilla was not sufficiently developed anteriorly. The arch was narrow and very deep, and the upper incisors

* Jackson, Dental Cosmos, 1890, p. 879.

closed far back of the lower ones, measuring three-fourths of an inch from the lingual side of the upper laterals to the labial surface of

Fig. 375.

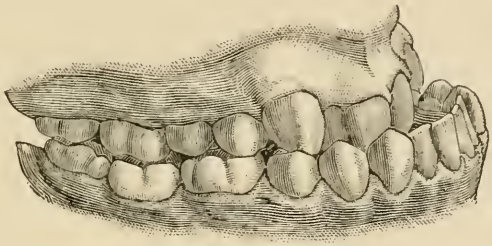

the lower laterals and cuspids. The lateral incisors were near the first bicuspids, causing an extreme depression in the region of the incisors, and the lower jaw was excessively prognathous.

The patient had suffered with nasal disease since childhood, and had had several operations performed. The upper teeth, together with both the inner and outer table of the alveolar process, were moved outward by the use of a modified Coffin plate (Fig. 376). The plate was made to cover the palatine portion of the arch, fitting

Fig. 376.

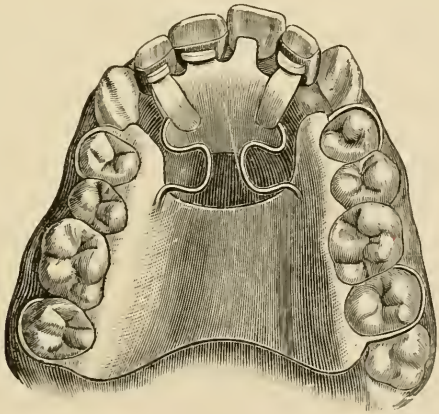

well about the necks of the molars, bicuspids, and the incisors to be moved. It was designed to separate the plate laterally in two parts, having them connected with spring-wires, with the anterior part about as broad and long as the palatine portion of the intermaxillary bone back of the incisors. The divisions of the plate were connected with

two spring-wires, No. 16 gauge (a larger size is sometimes preferable), each being formed into three partial U-shaped loops, with the ends flattened to make a good anchorage in the vulcanite. In making, a try-plate of wax was first formed as in an ordinary case, and several pieces of binding wire placed around each spring, with the ends projecting upward, so that when the plaster was poured in the upper half of the flask it surrounded the ends of the binding wire and held the spring in position when it was removed for packing the rubber. The surface of the wax was marked where it was intended to separate the plate when finished.

The ends of the springs were arranged in the parts of the plate so that the centre loops rested towards the median line. The plate was anchored with wire-clasps, and collars with lugs, having clasps extending around the mesial and buccal surface of the first bicuspids, and similar clasps extending from the distal part over the arch at the junction of two of the teeth to rest on the buccal side of the second molars. The anterior part was anchored by cementing to each of the lateral incisors and one of the centrals a gold collar with a broad lug on the lingual side, shaped to project over the edge of the plate. After the plate was finished it was divided with a fine saw, following the line indicated on the surface, and the edges properly smoothed.

Gradual force was applied by opening the loops slightly in the springs by bending, the changes being made about once a week. The part covering the intermaxillary portion was kept in an inclined position most favorable for pushing the process bodily outward, the plate being removed by the patient twice a day for thorough cleansing. A continuation of this case will be found on page 324. Fig. 379 shows the position of the teeth after the plate had been worn six months.

Inward Bodily Movement of Incisors.—The bodily movement inward of prominent teeth and the process is conducted on the same principle as for moving them outward, the object being to reduce the prominence in the incisive region for improving the facial contour, the occlusion, appearance, and angle of the teeth. It should be kept in mind, however, that the inward movement of the upper incisors and process does not usually lessen the prominence of the nasal spine of the maxilla, and therefore no case should be undertaken until the prospective prominence of the nose, which does not

come to full development until the age of maturity, has been carefully considered.

Ordinary cases of protrusion can be reduced by moving the teeth and process inward with apparatus as described in Chapter XII., Incisors, to move Inward. The force should always be applied close to the margin of the gum on the labial side, using gradual steady pressure to produce the desired absorption of the process opposite the lingual side of the roots of the teeth. If the force is sufficiently gradual, there is generally no corresponding tipping forward of the apex of the roots, or tendency of the teeth to rotate.

In Fig. 377 it will be seen that, as force is applied with a spring (*a*, *b*) on the labial faces of the incisors, at the margin of the gum,

Fig. 377.

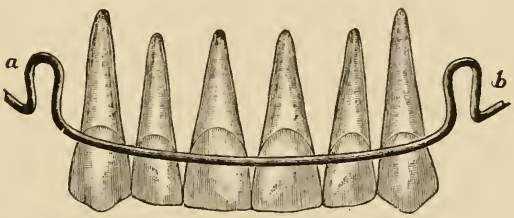

the teeth will necessarily be moved inward together until they press against the lower incisors, or until they all touch their approximal surfaces, resting against one another near their incisive edge. This will prevent further inward movement of their crowns, and when gradual force is continued while they are in contact in this manner, it will be exerted upon their roots, moving them inward. If excessive force is applied at this stage it will cause the teeth to crimp.

Direct bodily movement inward of the teeth is caused by an appliance made similar to Fig. 369, with reversed action of the springs; the adjustable arms being attached to collars over the teeth or to a cap in a reversed manner from that shown in Figs. 363 and 364.

A device made of vulcanite, as described on page 310 of this chapter, is made applicable by reversing the action of the springs and dressing away a small portion of the rubber back of the teeth to be moved.

In the case of Miss E., aged eight years, an extreme protrusion of the upper teeth, with prominence of the jaw and process, was corrected. There was an apparent recession of the lower jaw, the lower incisors biting against the soft tissues of the upper arch.

A vulcanite palatine plate, made as illustrated in Fig. 338, was employed. The rubber in the anterior part was thickened to form an inclined plane for depressing the lower incisors in their sockets, they being considerably extruded. For moving the incisors and deciduous cuspids inward, a semicircular spring with two U-shaped loops was arranged to cross the labial side of them, the ends passing over the arch at the junction of the first and second bicuspids to be anchored in the vulcanite. When the spaces between the upper incisors and cuspids were closed by the application of the spring, the unerupted first bicuspids were extracted, and a little of the anterior margin of the plate was dressed away from time to time to permit their continued movement. The spring was placed rather near the incisive edge, for tipping them inward to the desired angle; after which a metal cap, with two wire arms attached to the lingual side, was applied to the incisors and deciduous cuspids for moving them inward bodily. The cap was made in the manner described in connection with Fig. 64. For continuing the depression of the lower incisors, a semicircular piece of plate-metal for forming an inclined plane was soldered to the lingual side of the cap, projecting backward and downward. Two arms of round wire, No. 12 gauge, were soldered to the cap underneath the inclined plane, and shaped to extend one on either side, following the inner curve of the arch; they terminated on the grinding surface of the first permanent molars. The cap was then strongly cemented to the incisors and cuspids. Fig. 378 shows the cap in position when the regulation was nearly completed. The

Fig. 378.

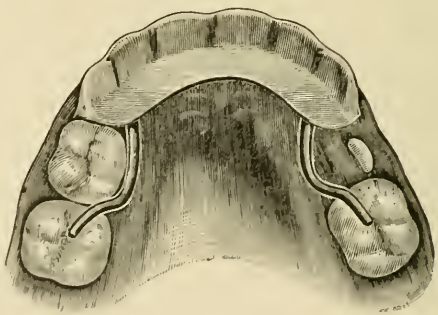

arms projecting backward from the cap and resting on the grinding surface of the molars in this manner prevented the front teeth from tipping or changing their angle as they were forced bodily inward.

The pressure for causing their movement was applied by a cross-bar and cranial-cap in the manner illustrated in Fig. 69, the cap being worn regularly at night and as many hours during the day as practicable.

Dr. Case has described a method of moving teeth bodily, the principle of which is as follows.* A collar well fitted to each of the incisors to be moved has an arm soldered to the front, projecting near the gum under the lip, and reaching about one-third of the length of the root. Strong collars are also fitted to one or more of the molars on each side of the distal part of the arch for anchorage, with two tubes soldered in suitable position on the buccal side. The collars are cemented to the teeth. Force for moving the teeth is supplied by two curved bars, made to extend around the labio-buccal side of the arch and passing through the tubes. One of the bars is fastened to the ends of the arms projecting upward from the collars for causing the power, and the other to the arms near the incisive edge of the teeth, acting as a fulcrum. The ends of the bars are provided with a thread and nut. Traction for moving the teeth bodily inward is got by turning the nuts on the ends of the upper bar, which engages with the distal ends of the tubes, thus drawing inward on the arms, while the lower bar is made to prevent the inward movement of the lower portion of the crowns by having the nuts on the bar rest on the mesial end of the tubes which it enters. As the nuts of the upper bar are turned, the roots of the teeth are made to move inward through the process. For moving the teeth bodily outward, the nuts on the upper bar are arranged in front of the tubes, while those on the lower bar are usually placed at the distal end of the tubes.

---

* Case, American Text Book of Operative Dentistry, 1897, p. 690.

CHAPTER XVIII

PROGNATHISM

Prognathism is a prominent condition of the jaws. The word, as generally used in Orthodontia, refers to prominence of the lower jaw. Prognathism may result from inherited, acquired, or local causes.

In cases of marked prognathism, the lower incisors close more or less in front of the upper ones. The natural or anatomical angle of the jaw at the junction of the body and ramus, as seen in the adult, is changed, so that the lower edge of the bone from the symphysis to its articulation forms more nearly a plane.

In less marked cases, the angle of the jaw is more apparent, and the lower incisors may close against the incisive edge of the upper incisors, or they may close back of them in approximately a normal position, with the jaw prominent and the lower teeth and process tipping inward. The lower incisors may close back of the upper ones, but with the anterior upper teeth projecting outward. Or, again, the point of the chin may lack fulness, the alveolar process and teeth being crowded forward.

Fig. 375 illustrates an excessively prognathous jaw,* in the case of Mr. S., aged twenty-two years. The upper incisors had receded

Fig. 379.

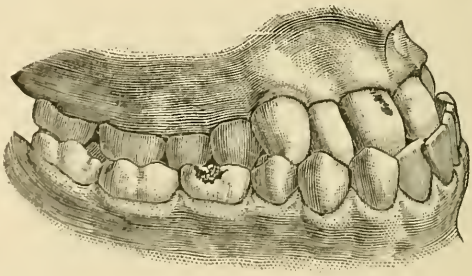

considerably from a normal contour, and were first moved bodily outward with an appliance as illustrated in Fig. 376. After six

* Jackson, Dental Cosmos, 1890, p. 879.

months' treatment, the upper arch and teeth had assumed the position seen in Fig. 379.

Owing to the mature age of the patient, it was not advisable to depend solely on the pressure of a chin-cap and cross-bar for correcting the deformity of the lower jaw by changing the angle causing absorption in the glenoid fossæ, or by bending the neck of the condyles, as is common with young patients. It was determined to gain as much movement as possible with the chin-cap, and to extract the first lower molars, which were pulpless at the outset, and then to move the lower incisors, cuspids, and bicuspids backward in the circle of the arch. The latter was accomplished with a device attached to a chin-cap, as seen in Fig. 380. The apparatus was constructed by first swaging with accurate dies a chin-cap of

Fig. 380.

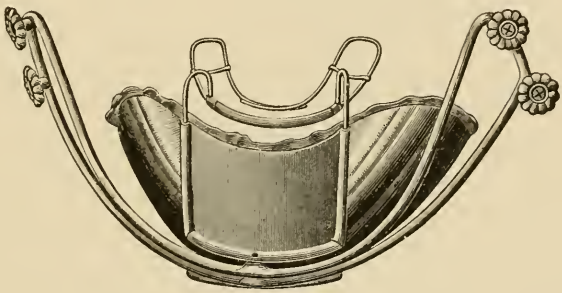

plate-metal. Over the prominent part of the cap was hinged a double cross-bar. (See Chin-Cap, page 100.)

The appliance for retracting the lower teeth was made by first shaping a spring-wire, about No. 16 gauge, to cross, near the gum, the labial side of the teeth to be moved. It was bent into the circle it was desired the teeth should assume, extending back on either side of the arch, and bent to pass through the space caused by the extraction to the inner side, where the ends were shaped to extend forward again, following the lingual curve of the teeth to act as springs, each passing the other at the median line. Each of the springs was united and strengthened by a bar of spring-wire, which was curved upward and made to extend over the arch at the junction of two of the teeth and soldered. To the front part of the crib arrangement were soldered two posts, made by shaping a secondary spring to pass in front of the teeth, giving additional strength to the

anterior part, and extending near the corner of the mouth on either side. There it was bent into loops with the ends projecting downward, passing over the lower lip, to be inserted into perpendicular tubes which were soldered to the outer surface of the chin-cap, as seen in the figure.

It is found from experience that forcible retraction of six or more of the anterior teeth, either in the upper or lower arch, by means of a curved bar of metal on the labial side, will cause some of the teeth to crimp; *i.e.*, the edge of one will pass over the edge of the adjoining one. The crimping is prevented by moving the teeth slowly or by applying slight pressure to the lingual side of those that are inclined to be forced out of the circle. In this instance the lingual springs connected with the crib arrangement described, distributed the pressure required.

In adjusting the combined apparatus (Fig. 381), the chin-cap was first placed in position. The crib passed over the teeth, and the posts were pressed into the tubes deeply enough to have the appliance rest near the gum. When the posts move too easily in the tubes, they should be crooked slightly near the ends.

It is obvious that properly directed traction on the chin-cap would press the crib backward, carrying all of the enclosed incisors, cuspids, and bicuspids bodily towards the second molars, which were finally almost touched by the bicuspids. It will be noticed that the arch of the lower oral teeth was maintained while in transit, and the molars were in nowise disturbed. The apparatus was worn continuously for six months. The resulting improvement in the relationship of the teeth is shown in Fig. 382.

For retaining, an appliance was inserted in the lower arch, made with a lingual base-wire and anchored with spring-clasp attachments to the molars. A semicircular spring-wire with two U-shaped loops was formed to the labial side of the teeth near the gum, with the loops opposite the bicuspids, the ends of the wire being bent to pass through the space, one on either side, and soldered to the base-wire. In addition to the retaining device, the chin-cap with the crib arrangement described was applied regularly at night for over two years.

In 1878 Dr. George S. Allan recommended a chin-cap that has proved of great service to the profession for the reduction of prognathism. It has two arms of wire soldered to the front of the cap,

Fig. 381.



the ends of which project backward on either side and terminate in hooks for the attachment of elastic bands.*

In constructing a chin-cap for the reduction of prominence of the jaw it should be made on an accurate model of the chin to insure

Fig. 382.

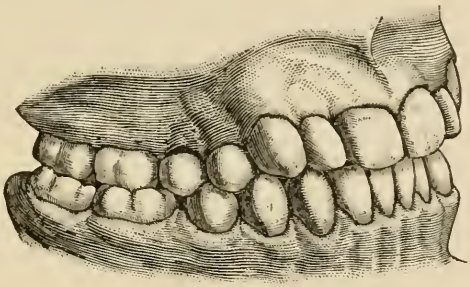

its perfect adaptation, and good judgment must be exercised in determining its outlines.

Some of the chin-caps recommended are made to project far back under the body of the jaw towards the angle on either side, the means of attachment for causing traction being placed near the distal edge. When elastic pressure is applied so far back near the angle of the jaw, it results in drawing upward on the lateral body at this point, and tends to straighten or cause the angle to become more obtuse rather than more acute, as is desired. The chin-cap should be made to project sufficiently under the jaw, extending well back on either side, to equalize the bearing and to keep the appliance from twisting out of place without causing excessive pressure on those parts; but the force should always be applied at the median line a little above the point of the chin, especially in the treatment of prognathism. The lines of force required are shown in Fig. 383, *a*, *b*.

Fig. 383.

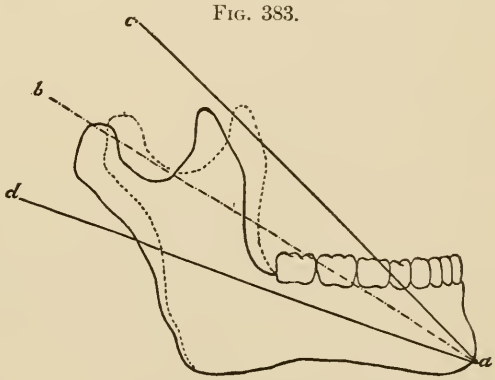

* Allen, Trans. Odontological Society, 1878.

To obtain the best results the chin-cap should be applied rather early in life, before the bone has become fully developed. This is especially necessary when the deformity is inherited. If the chin-cap is applied when the deformity is first apparent, there is usually a quick response to the pressure. In these cases the chin-cap is required to be worn only at night and a few hours during the day. The body of the jaw is elongated for the eruption and accommodation of the molar teeth by absorption of the mesial surface of the rami and a corresponding deposit of bone on its distal surface. While this progressive anterior development of the jaw is taking place for the accommodation of the erupting teeth it generally requires but a comparatively slight, though persistent, force to change the angle.

It is thought by some authors that the angle of the jaw is not materially changed by external force, but that when recession of the jaw is brought about it is accomplished by forcing the condyles backward in the glenoid fossæ, causing absorption of the bone in the distal part.

Distinct changes at the angle of the jaw from external force cannot be depended upon after the twelfth or fourteenth year. Later in life the bones become more dense, and only the most persistent application of the chin-cap will be of service. Likewise there is more soreness and discomfort, and if there is a beard it usually proves troublesome. The continued pressure on the chin interferes with the growth of the hair, causing congestion, which results in folliculitis. This condition can be met by medication, padding the cap with soft materials,—chamois, cottonoid, or linen,—removing the apparatus frequently and keeping the chin closely shaven.

The physiological law (see "The Application of Force," p. 117), that continuous pressure on any part of the body will cause absorption, while pressure alternating with rest will cause a building-up, is fully as evident in the use of the chin-cap as in the regulation of the teeth. When the bony tissues are dense the application of the chin-cap at night only, say eight hours, and a rest during the day will generally avail little, for during the sixteen hours, in a healthy person, nature will have had sufficient time to repair any injury of the bone that may have been caused by the continuous strain of the chin-cap during the night. For this reason, with the adult, the chin-cap should be worn continuously, or at least eighteen or twenty hours out of the

Fig. 384.

Fig. 385.

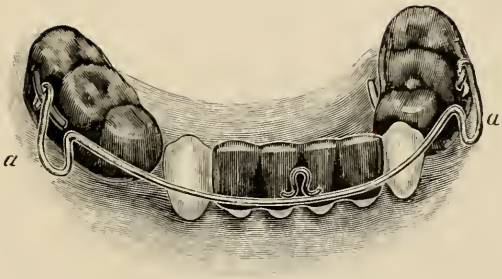

Fig. 386.

Fig. 387.

twenty-four. If force is applied but a few hours during the day, and nature is able to resist it, the part of the jaw put under strain becomes more developed and its walls are thickened. When the chin-cap is used for a considerable length of time for the correction of obstinate cases of prognathism or lack of anterior occlusion, the lower jaw in some cases, especially with the adult, becomes broadened in the region of the angle, and the bone is thickened to a disagreeable and noticeable extent. When this prominence is being brought about it can be prevented by extending a round or flat metal spring backward from the sides of the chin-cap supporting a pad to rest over the prominent parts, to press inward as force is applied at the point of the chin.

Again, when the bones are dense, a cross-bar for reducing upper anterior protrusion, when used alone and only at night is seldom efficacious. A regulating device should be worn continuously in the mouth and the cross-bar used as supplemental force, or the cross-bar used continuously. In other cases a cross-bar is used only at night.

In moderate prognathism with the adult, not infrequently a satisfactory improvement in the contour of the features and occlusion of the teeth can be made by moving the upper front teeth and process outward and the lower front teeth inward, harmonizing the mesio-distal relation of the jaws. This treatment with the following apparatus was employed in 1897 in the case of Mr. A., aged eighteen years. The method was used in a similar case in 1889.

Fig. 384 shows an outline of the features before regulation. The upper incisors were moved bodily outward, the apparatus being arranged to open the bite. An appliance was made for moving the lower incisors and cuspids inward, the loss of the first bicuspids leaving space (Fig. 385). For anchorage, a swaged metal-cap with a wire staple or eyelet soldered to the buccal surface was cemented to the molars and second bicuspid on each side of the arch. A similar metal cap was cemented to the incisors, on the front of which was attached a wire loop projecting upward and forward to support a cross-bar. A labio-buccal spring, No. 14 gauge, was applied. It was provided with a U-shaped loop on either side pointing downward opposite the first molars, as shown at *a*, *a*, and the ends were shaped to hook into the eyelets on the buccal side of the caps. The labial part of the spring was retained by passing below the wire projection of the cap on the incisors. Pressure was caused by closing the loops of the spring slightly from time to time.

To supply the main force, an external apparatus, made as described on page 97, with a cranial-cap and a double cross-bar pivoted in the centre, similar to a swing-tree, was applied (Fig. 386). A curved arm of rigid wire, No. 8 gauge, was shaped to extend over the lower lip (the bar can be left straight if desired), with one end formed into a head to catch into the loop on the cap over the incisors, and the other end soldered firmly to the cross-bar.

The curved wire extending over the lip in this manner exerted direct inward force on the lower teeth when traction was applied from the occipital anchorage. The operator should bear in mind that the articulation of the jaw in the glenoid fossæ is a little in front of the middle third of the ear from above downward. The elastics extending from the cranial-cap to the bar should not draw downward or upward too much, but their traction should be such as to balance the jaw upward slightly, so that the lower molars and bicuspids will rest against the upper ones. If there is a tendency for the incisor teeth to elevate, a thickened palatine plate similar to Fig. 337 may be employed; the bite can be opened when necessary by extending the plate over the molars. In the case described the cross-bar was worn regularly at night and as many hours as practicable during the day, shortening the straps for causing additional force by rebuckling as required. Fig. 387 illustrates the contour of the features after correction.

With the adult, when the alveolar process is dense, it is sometimes injudicious to apply the excessive force required for moving the four incisors and the cuspids inward at one time. Instead of this, first move the teeth on one side of the median line and then those on the other. In such a case a metal cap with a socket in the centre should be cemented to only the incisors and cuspid on one side of the arch. After they are moved to position, the teeth on the opposite side can be moved in the same manner.

When supplemental force is required in moving outward the upper teeth, while at the same time the lower teeth are being moved inward, an equalizing device, as seen in Fig. 388, can be applied. It is made with a chin-cap and standards of wire and tubes supported by a cranial-cap, as described on page 255. An infralabial bar of stiff wire, as illustrated in Fig. 214, is adjusted to cause pressure on the lower teeth. Force is caused by passing elastic ligatures from the knobs on the bar to the adjustable knobs on the

Fig. 388.

Fig. 389.

Fig. 390.

Fig. 391.

Fig. 392.

wire standards. A supralabial bar for moving outward the upper teeth (Fig. 374) is made of wire with large loops projecting upward just in front of the standards. The bar is attached to the teeth by a wire (*b*) curved to extend from it over the lip, with the ends shaped to hook into an eyelet or bent at right angles to hook into a tube; or the attachment can be made in any other manner desirable. The ends of the bar are provided with hooks to engage with adjustable knobs on the tubes of the standards. Force is got by opening the loops gradually by bending. This apparatus can be adjusted for forcing outward the teeth in a receding lower jaw, at the same time reducing the prominence of the upper jaw by reversing the arms and their attachment. In equalizing the jaws when moderate force is required, the device, with slight modification, may be used without the chin-cap.

For moving cuspids inward or backward by means of external anchorage, see Fig. 439; for moving bicuspids backward in the line of the arch, see Figs. 470–475.

When the incisor teeth occlude on their edges, their position should be corrected, causing the upper incisors to close in front of the lower ones. If not corrected, the edges of these teeth and of others in the arch become worn, disfiguring them and allowing the jaws to come closer together. The temporo-maxillary articulation of the lower jaw is considerably above the line of the occlusion of the teeth, and as the teeth become worn, the jaw is gradually permitted to project farther forward, causing the lower incisors to close in front of the upper ones.

Fig. 389 illustrates the features of Miss S., aged forty-nine years. The early regulation of the teeth had been neglected, and an extreme prognathous condition resulted in the manner described.

The bite was opened, and the lower teeth moved inward to close back of the upper ones with an appliance similar to that shown in Fig. 210. For opening the bite, bars of metal were attached to the spring-clasps over the anchorage portion (Fig. 188). After the incisors were moved inward, pressure was applied with a chin-cap to force the jaws together and adjust the occlusion. The change in the line of the features is shown in Fig. 390.

Hereditary prominence of the lower jaw is usually accompanied with nasal stenosis, enlarged tonsils, and more or less arrest of development of the upper maxilla. Examples are seen in Figs. 381, 391, and 393.

Fig. 391 shows the contour of the features of Mr. J., aged twenty-one years, a case of heredity. His sister and one of their parents had a similar deformity. When the patient was first examined, the lower incisors were beginning to close in front of the upper ones. The tonsils were found to be enlarged, and there was partial nasal stenosis. To improve the nasal breathing the obstructions were removed by a rhinologist. A chin-cap was then applied, as shown in Fig. 392, for forcing the jaw backward into its relative position, and the patient was directed to wear it continuously or regularly at night and as many hours as possible during the day. The sister's deformity was also corrected.

The serious conditions that result from neglect of early treatment of prognathism should warn the operator to watch carefully any suspected case and advise the patient.

The history of an interesting case of progressive prognathism is described on page 202.

Fig. 393 illustrates a case of extreme protrusion of the lower jaw. Miss H., aged twenty-four years. There was no apparent angle of the jaw and only slight occlusion of the back teeth. The lower lip projected nearly as far as the point of the nose. The upper incisive region was poorly developed, and there was a marked degree of nasal stenosis. Owing to the age and the extreme protrusion of the jaw, it was decided that the ordinary method of procedure for its correction would not be effective, and that a surgical operation should be resorted to,—the removal of a section of bone from the body of the jaw and alveolar process in the bicuspid region on each side of the arch.*

When in cases of extreme prognathism in the adult it is not considered advisable to change the position of the teeth in the process, the contour of the features can in some instances be improved by the use of a plate in the upper arch, having artificial teeth arranged outside of the line of the natural ones. Several methods have been recommended by different practitioners. Dr. J. H. Meyer cites a case† in which he swaged a platinum plate to pass

---

* Hullihen, American Journal of Dental Science, 1849, p. 157 ; Ottolengui, Dental Cosmos, 1897, p. 143 ; Whipple, Dental Cosmos, 1898, p. 552 ; Angle, Dental Cosmos, 1898, p. 635.

† Meyer, Dental Cosmos, 1884, p. 669.

Fig. 393.

Fig. 394.

Fig. 395.

Fig. 396.

over the natural incisors and cuspids, supported with vulcanite, passing over the palatine portion of the arch. To the platinum on the labial side were soldered plate teeth in position to articulate properly with the teeth of the lower arch. The appearance and outline of the features were noticeably improved.

Not infrequently cases are presented where it is desirable to improve the general occlusion of the teeth, the lower arch being broad and prominent, the upper arch narrow and insufficiently developed, with perhaps one or more teeth absent, permitting the teeth of the upper arch to close inside of the circle of the lower ones, giving too close a bite and bringing about prognathism. For this condition a palatine plate may be made, passing over the upper teeth, with a ledge on the outer surface, or artificial teeth attached when necessary, to form an occlusion with the lower teeth. This procedure was recommended in the case of Master K., aged thirteen years. These conditions may also occasionally be improved by the application of a plate supported by the lower teeth, made to project inward from the teeth sufficiently to form a grinding surface for occlusion with the teeth of the upper arch, but not projecting so far as to irritate or interfere with the action of the tongue, the inner edges of the plate being well rounded and smooth. The plate can be made entirely of vulcanite, or of metal by fitting a swaged portion accurately over the grinding surface of the lower teeth, making it project lingually to form a ledge for the articulation with the upper ones. When there is sufficient room, thin porcelain teeth can be attached to the swaged portion of the cap on either side, setting the teeth in natural position, or having them reversed and attached with solder or vulcanite.

The opposite condition is sometimes presented. In the case of Master S., aged seven years, the upper arch was very large, with no spaces between the teeth; the lower arch small, and the front teeth biting against the gum, none of the teeth occluding with those of the upper arch. An upper palatine vulcanite plate having a ledge for occlusion with the lower teeth was inserted favoring natural mastication; at the same time a device was applied in the lower arch for its expansion. (See description in connection with Figs. 88–91.)

When the nose is large and the region of the upper lip is depressed, with a prognathous lower jaw, it is usually advisable to

move outward the upper incisors and process to improve the facial line.

Fig. 394 illustrates the case of Master S., aged fourteen years. During the eruption of the permanent teeth the upper incisors were permitted to close back of the lower ones, which encouraged the lower jaw and teeth to take a prominent position and depress the anterior part of the upper arch. As is usually the case when this condition is permitted to continue, the anterior development of the lower jaw had been encouraged by the abnormal occlusion of the teeth to such an extent that it was not only necessary to move the upper incisors outward to close in front of the lower ones (Fig. 395), but to apply a chin-cap to cause inward pressure on the lower jaw, and at the same time to force it upward, in order to cause the lower incisors to occlude well back of the upper ones and improve the profile (Fig. 396).

Attention has already been called in this chapter to the advantage of early treatment for the correction of prognathous conditions, especially when the deformity is *inherited.* When brought about by an *acquired* or *local* cause it should first be removed and the correction proceeded with in the usual manner.

Fig. 397 illustrates the case of a child aged five years, with the deciduous lower incisors and cuspids closing in front of the line of

Fig. 397.

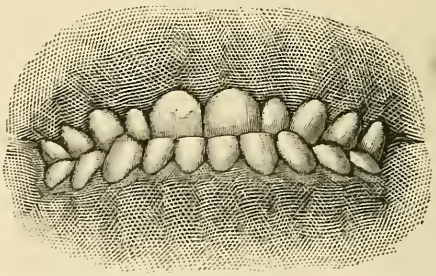

the upper ones. The irregularity was inherited, both parents having a prominent lower jaw. On examination the child was found to be suffering with both faucial and nasal obstructions. The parents were directed to have the obstructions removed by the rhinologist, but these directions were not carried out.

When the child was ten years of age the writer was again called upon to examine the case. The permanent teeth had erupted, with

Fig. 398.

the lower incisors closing considerably in front of the upper ones and with the nasal and faucial conditions aggravated. The parents were again advised to have the obstructions removed immediately. The operation was performed, improving the nasal breathing, as was anticipated. The upper incisors were then moved outward, after which a chin-cap, as seen in Fig. 398, was applied and worn regularly at night and a few hours during the day. In this case, as is common with young patients, the jaw yielded to the force and took a good position, but the use of the chin-cap was continued with light pressure for over a year, the case being examined carefully from time to time to anticipate any undesirable change. The continued use of the chin-cap is often required for several years.

In prognathous conditions it is sometimes an advantage to use an inclined plane for their correction. The pressure in occlusion settles the incisors into their sockets, while the relief from pressure on the teeth in the sides of the arch permits the latter to elevate, gradually bringing them and the incisors to the same plane of occlusion. The inclined plane for this purpose, however, should not be employed except where the incisors are considerably elevated. A unique case of this character is seen in Figs. 184–186.

Unilateral Prognathism.—Unilateral prognathism of the lower jaw is frequently met with. It may result from a local or a constitutional cause, as from the injudicious extraction of one or more of the permanent teeth on one side of the upper arch, from an excessive development of the lower arch, or from the improper development of the upper arch; the two latter forms result from inherited or acquired causes. It is usually progressive, becoming more defined as the patient grows older. When the upper arch is less fully developed on one side than the lower, this condition permits the teeth to close inside of the line of the lower arch, destroying the occlusion on that side. The teeth become extruded, gradually forcing the lower jaw forward and to one side, and wearing away the edge of some of the incisors, but usually leaving a reasonably good occlusion of the teeth on the opposite side of the arch. This results in an extreme deformity of the features. Fig. 107 illustrates a marked case. For its correction it is usually necessary to expand the upper arch (see Unilateral Expansion, page 138) or to contract the lower arch, and in some instances to extract one or more of the lower teeth and apply a chin-cap in the manner described.

CHAPTER XIX

RECEDING LOWER JAW

Recession of the lower jaw may result from heredity, from an arrest of development, or from the injudicious removal of the lower permanent teeth, interfering with its anterior growth.

An *apparent recession* of the lower jaw may be caused by abnormal prominence of the upper incisors and alveolar process (Fig. 399). In these cases, the line of the features can generally be improved by moving inward the upper teeth and process.

If, from the contour of the features, or the size and prominence of the nose, the lessening of the fulness in the region of the upper lip is not desirable, the facial line and the occlusion can sometimes be improved by the anterior expansion of the lower arch; moving outward the lower front teeth and process by an appliance similar to Fig. 134 or 137. In some instances a slight and gradual broadening of the upper arch laterally will be sufficient to move the lower arch forward as a result of improved occlusion.

Fig. 400 illustrates the features of Miss F., aged eleven years; a marked case of receding lower jaw, with the upper arch too prominent. The patient suffered from mouth-breathing, induced by nasal stenosis. The first upper bicuspids were extracted, the incisors and cuspids, with the process, moved inward, and the arch broadened. This procedure caused the lower jaw to bite farther forward, improving the facial line, as seen in Fig. 401.

An interesting case of hereditary recession of the jaw is shown in Fig. 402, Miss C., aged twenty-three years. The upper incisors were prominent, irregular, and a little to one side of the median line. To give space for their correction and to reduce the prominence, a first upper bicuspid was extracted, and a device was inserted which at the same time encouraged the lower jaw to bite farther forward. An appliance was also inserted in the lower arch for its anterior expansion.

Equalizing the Jaws.—Many methods have been employed for harmonizing the antero-posterior relationship of the jaws when unequal in prominence or size, for improving the facial contour and

Fig. 399.

Fig. 400.

Fig. 401.

Fig. 402.

the occlusion, the effect being to force inward one arch and outward the other. Suitable apparatus is described. For this purpose rubber bands have been used, attached one on either side of the arches. extending from the anterior third of a prominent upper arch to the distal part of a receding lower arch, or *vice versa.*

From time to time for many years, members of the profession have employed and described elastic rubber extending from one arch to the other, ligating the rubber directly to the teeth. or fastening it to collars, but without any general systematic method in its application.

More recently the especial advantages of elastic rubber for these purposes has been pointed out, notably by Drs. Case*, Angle,† and Baker.‡

The objection to its use has been the displacement of the teeth used for anchorage, crimping them or drawing some of them out of their sockets. The principle will be better understood when we consider that in prominence of the upper arch the incisors and those of the lower arch are naturally more or less extruded with the process, being elevated beyond their normal plane. The constant tension of rubber bands for relieving the upper prominence, owing to its angle, drawing downward and backward on these teeth, tends to elevate them more, and at the same time it elevates the teeth used for anchorage in the distal part of the lower arch.

When used for correcting a receding upper jaw and prominent lower jaw, the effect is about the same, in some instances drawing upward on the anterier lower teeth, in others tipping the upper jaw forward and upward and elevating the molars used for anchorage to such an extent as to cause lack of anterior occlusion. Rubber bands attached to the distal part of the upper arch by continuous apparatus passing over the teeth, and to the anterior third of the lower arch by continuous apparatus were used for Mr. D. in 1889. The anchorage teeth were disturbed in their sockets before the jaws were equalized, and another form of apparatus was necessarily devised.

In the use of rubber bands, the anchorage to the teeth is to be

---

* Case, Trans. World's Columbian Dental Congress, 1893, vol. ii. p. 731; Dental Cosmos, 1904, p. 345.

† Angle, Treatment of Malocclusion of the Teeth, 1900, p. 284.

‡ Baker, International Dental Journal, 1904, p. 344.

made in any suitable manner; but it is always necessary to include in the anchorage on each side at least three teeth in each arch; otherwise the teeth would gradually be drawn out of position by the constant force applied, either elevating or crimping them. In some instances this can be prevented by using a band of less tension, or by forming an anchorage to more of the teeth in each arch. This is done either by cementing collars to some of them with bars connecting the collars, by cementing to the teeth of the upper and lower arches carefully adjusted spring-clasp attachments, or by cementing to the teeth thin metal caps, usually passing over all of the teeth, having the occlusal planes made broad and arranged at an angle or incline favoring the movement towards a normal occlusion. When the upper or lower incisors are extruded or rest on a higher plane than the molars and bicuspids, elevating the planes and opening the bite is sometimes necessary, to permit the incisors to pass from a labial to a lingual occlusion, or the reverse. Knobs, hooks, or eyelets for holding the rubber band or a metal spring, should be located on the buccal side near the occlusion line. This provision causes a more direct tension from front to back; improving the angle, and thus lessening the tendency to the tipping of the arches.

In equalizing the jaws the apparatus, to be most effective, should be applied while the patient is young, and the appliance arranged to hold the jaws at the desired plane. The force must be constant and sufficient to overcome the natural tension of the muscles, and continued until the jaws become equalized, either by, first, bending the bones; second, causing contraction of one of the arches and anterior development of the other; third, the instituting of a new temporo-maxillary articulation, or, fourth, by establishing a new occlusion. The two former results are to be sought for; they are usually attained with the young and when the force is continued. The two latter seldom prove as satisfactory, as usually while laughing, or when the features are in repose, the teeth not resting in contact, the lower jaw slides backward more or less, marring the facial line and causing an *apparent upper protrusion.*

In the following division of this chapter, and in different parts of this work, other methods are described for harmonizing the antero-posterior relationship of the jaws.

Jumping the Bite.—Recession of the lower jaw is caused by its

failing to keep pace with the upper jaw in its anterior development, often making the lower teeth occlude back of their normal position as far as the width of one of the bicuspids; that is to say, the cusps of the first lower bicuspids close back of the cusps of the first upper bicuspids, instead of in front of them as in normal occlusion; while the lower incisors are usually elevated, and on a considerably higher plane than the bicuspids and molars.

After careful measurement, if it is seen that the anterior expansion of the lower arch by the outward movement of the lower incisors will not sufficiently improve the facial line and cause a good occlusion, an appliance for moving the lower jaw forward the width of one of the bicuspid teeth should be employed. This operation has been termed jumping the bite, and was first recommended by Dr. Kingsley. He used for this purpose a palatine vulcanite plate having an inclined plane located near the upper incisors, shaped to project sharply downward and backward to engage with the lingual faces of the lower incisors in occlusion.* By this the lower incisors are sometimes tipped outward, although in young patients the principal change is the lengthening of the lower jaw, which takes place in its body and at its angles, as a result of interstitial growth. This gradual change will be better understood when we consider nature's method of lengthening the jaw, which naturally takes place near the rami for the accommodation of the erupting molar teeth.

Aside from the interstitial growth, there is an absorption of the mesial surface of the rami, and a corresponding deposition of bone on the distal part, which makes apparent the change in the shape of the jaw, from the obtuse angle of the child to the more right angle of the jaw of the adult.

The operation of jumping the bite or equalizing the jaws, to be most successful in the way of lengthening the lower jaw, should be undertaken before the twelfth year, or before the eruption of the second permanent molars. The appliance should be worn constantly for several months, or until the occluding teeth have become settled together, and if need be until there is a normal articulation of the condyles of the jaw in the glenoid fossæ, the second molars being fully erupted and a new occlusion established. In the adult the operation of jumping the bite is not as satisfactory, as the change in

---

* Kingsley's Oral Deformities, p. 84.

the form of the jaw is not as readily made. If the treatment does not change the shape of the jaw, it should be held forward in its new position, being retained for an indefinite period, when gradually a new temporo-maxillary articulation will be established in the glenoid fossæ, sometimes by the building on of bone. The object of moving the jaw forward in this manner, changing the bite, is to improve the facial line, and at the same time improve the occlusion of the molars and bicuspids as well as the incisors.

Jumping the Bite Forward.—When the jaws are inharmonious in their mesio-distal relations, and jumping the bite forward is indicated, any spaces that exist between the teeth of the upper arch should first be closed by moving them inward, and an apparatus anchored in each arch for the attachment of small rubber bands for causing the required anterior and posterior traction as described; or a semicircular spring can be shaped to pass in front of the incisors with the ends anchored in a palatine vulcanite plate used to support an inclined plane, as seen in Fig. 403. The plate is made with

Fig. 403.

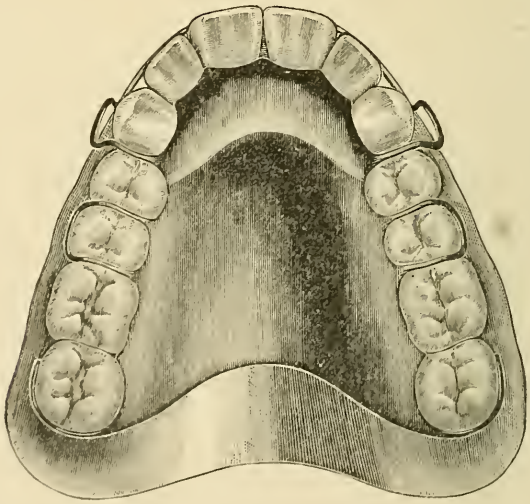

suitable means of anchorage, as with spring- or wire-clasps, with a projection of rubber extended from the anterior part sloping sharply downward and backward for forming the inclined plane; it should be shaped so that during occlusion it will pass back of the lower incisors and cuspids, causing the lower jaw to be moved forward for

a distance usually equal to the width of one of the bicuspid teeth. The closing of the lower incisors against the inclined plane in the manner described has the effect of stretching the lower jaw, encouraging its anterior development.

Another form of apparatus for this purpose is constructed as seen in Fig. 404. A palatine plate of vulcanite is well fitted to the

Fig. 404.

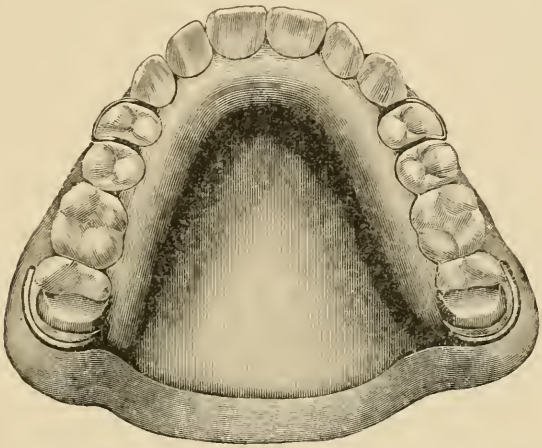

upper arch. From the disto-lateral edges there is an extension of vulcanite or metal passing across the grinding surface of the last erupted upper molar on each side. They should be shaped in such a manner as to project downward, forming steep inclined planes, sloping slightly backward to engage with the distal grinding surface of the last erupted lower molars. Projecting inclined planes of metal attached in the vulcanite are usually preferable. It is essential that the plate be strongly anchored and worn constantly for a considerable length of time. A lingual base-wire (Fig. 406) is sometimes used in place of the plate.

In jumping the bite forward, where the molars are sufficiently erupted, a device for retaining the lower arch in position can be made by attaching an inclined plane directly to one of the last upper molars on each side (Fig. 405). A strong, broad collar is fitted well to one of the molars, and a suitably shaped piece of heavy plate-metal or a bar for an inclined plane is soldered to it. The incline should project downward back of the last molar in the lower arch, causing the teeth to occlude as desired. The collars should be

strongly cemented. If either the device or the anchorage-teeth become loosened under the pressure, an additional collar should be fitted to an adjoining tooth, the two collars united with solder and cemented firmly to the teeth, one inclined plane on each side of the arch, or another means of anchorage should be used.

Jumping the Bite Backward.—The opposite procedure from jumping the bite forward is indicated when the lower jaw has moved forward more than is natural in its articulation, the cusps of the second lower bicuspids occluding with or in front of the cusps of the first upper bicuspids. This condition is not unusual. It may be brought about by heredity, enlarged tonsils, with nasal stenosis accompanying mouth-breathing, or by local causes, as the improper eruption of the upper incisors, they taking a position back of the lower ones, forcing the lower jaw forward. In young patients, for its correction, the movement of the upper incisors outward to close in front of the lower ones is sometimes sufficient, but when the articulation has become established the cause should be removed when possible, and an equalizing device or a chin-cap applied to force the jaw backward. (See Chapter XVIII., Prognathism.)

Fig. 405.

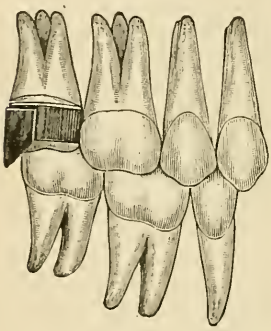

When the articulation has not become fully established, the jaw can sometimes be forced backward to a correct occlusion by attaching an inclined plane to a strong, broad collar cemented to one of the lower molars on each side of the arch, projecting back of the upper molars in an arrangement reversed from that shown in Fig. 405. Or a removable apparatus (Fig. 406) can be applied in the lower arch; it should be strongly anchored to the molars and bicuspids, with broad spurs projecting upward like inclined planes to rest back of the last upper molars in occlusion, and when necessary similar spurs pass back of the incisors and cuspids or other teeth. The inclines should be rigid or made of heavy gold spring-clasp metal, which can be bent forward from time to time. When it is required to open the bite to permit the backward movement of the jaw, attach bars of metal to the spring-clasps, arranging them to pass over the grinding surface of the molars and bicuspids. In locating the inclined planes on the apparatus, adjust the fixture to the teeth,

place over it a small amount of modelling compound, and direct the patient to close the teeth into it, making a bite. The device is then to be removed with the compound, transferred to the articulator, and filled with plaster. After taking the bite in this manner the inclines can be fitted to the teeth of the opposite arch and arranged at just the angle desired.

When the molar teeth are not sufficiently erupted or not of suitable shape for the application of the devices referred to, an appliance with a base-wire can be anchored to the teeth in each arch,

Fig. 406.

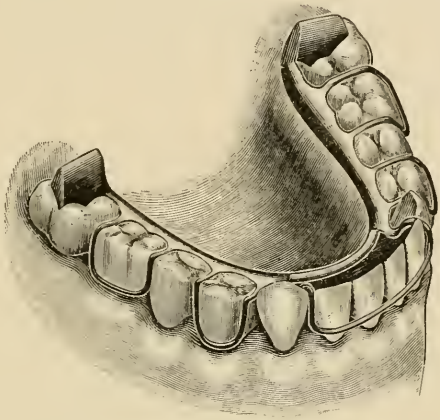

the bite taken with them in place, and spurs, flanges, or inclines attached to the upper and lower appliances so as to engage one with the other, thus forcing the lower jaw forward or backward as desired. In the latter case the chin-cap is usually employed. When extreme force is required, an equalizing device, as shown in Fig. 388, is effective.

The inclined plane was used to advantage in jumping the bite backward for Miss I., aged two years and ten months. (See Figs. 184–186.)

CHAPTER XX

LACK OF OCCLUSION

The regular occlusion of the teeth is not infrequently lacking, both in young patients and in the adult. The malocclusion may be general, there being no reasonable occlusion of the upper and lower teeth in any part of the circle of the arch (Fig. 99); there may be an improper articulation on one side, as seen in Figs. 108 and 111. Other forms of deficient occlusion are termed *Lack of Anterior Occlusion*, *Lack of Posterior Occlusion*, *Lack of Lateral Occlusion.*

Lack of Anterior Occlusion.—The teeth in the region of the incisors, cuspids, and sometimes the bicuspids have more or less space between their occlusal surfaces, the teeth in the back part of the arch standing high and occluding. Of the more pronounced forms of lack of occlusion this is perhaps the most difficult to correct. The irregularity usually occurs in the upper jaw, although the lower may be changed in its angle, or the anterior portion of its body may be bent downward, sometimes presenting an hypertrophied condition of the alveolar walls. Imperfect development of the bone and process of both the upper and the lower arch is usually indicated; it may be the result of nasal disease with stenosis, and is usually accompanied by mouth-breathing and enlarged tonsils. The buccinator muscle is attached to the outer surface of the alveolar process of the jaws opposite the molars, sometimes as far forward as the second bicuspid teeth. The continued abnormal separation of the jaws causes the muscle to drag on the processes, and this tends to elevate the molars gradually, inclining them with the bicuspids towards the inner side of the arch. Lack of development of the rami of the lower jaw, the injudicious extraction of teeth, the habit of sucking the thumb, and mouth-breathing are also factors in causing this form of irregularity. (See Chaper I., Etiology.)

Fig. 407 shows the features of Mr. D., aged seventeen years, a mouth-breather, with nasal stenosis and enlarged tonsils. The lower arch was broad and prominent, as is generally the case when the tongue is continuously drawn downward in mouth-breathing, and there was lack of development of the upper arch. From the

Fig. 407.

Fig. 408.

want of support of the tongue in the roof of the mouth, the arch was much contracted; the buccal cusps of the molars occluded with the lingual cusps of the lower molars. There was a considerable space between the upper and lower incisors, with inability to close the lips. This interfered with enunciation. The upper arch was expanded, and for forcing the jaws together a chin-cap was applied supported by a cranial-cap and rubber umbrella rings. The latter were employed to give the considerable force required for traction (Fig. 408. For the method of making the apparatus, see Chapter VII., Anchorage and Appliances, pp. 97 and 100.) The device was worn at night and as many hours as convenient during the day. This gradually depressed the molars and improved the occlusion, permitting the lips to close freely. The appliance was continued in use for over two years.

Fig. 409 illustrates a case with extreme lack of anterior occlusion. The patient, Miss T., aged seventeen years, was referred to me for

Fig. 409.

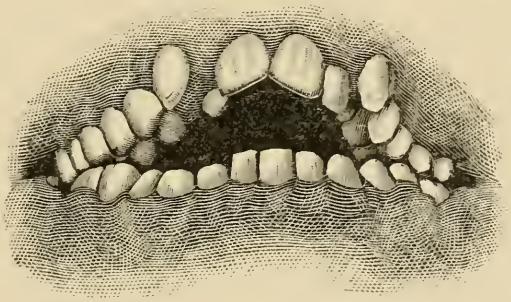

treatment. She was suffering with nasal stenosis, and breathed through the mouth. The lower lip was thick, and was drawn backward over the lower teeth, the end of the tongue resting in contact with it. The upper lip was also thick, but appeared considerably depressed, causing an apparent prognathous condition. It was only with an effort that the lips could be closed, and when at rest they were separated, giving the face an unpleasant expression.

From the history of the case given by the mother, it was learned that the patient had been a mouth-breather from childhood, and that several operations had been performed on the nose by rhinologists for the removal of the stenosis, but they had afforded only temporary relief, as the lips could not be kept closed.

All of the teeth but the third molars were erupted, none of them occluding but the second upper and lower molars. Between the front teeth a space was left in the form of an ellipse, measuring about five-sixteenths of an inch between the upper and lower incisors at the median line. The process of the lower jaw was much thickened, the mucous membrane spongy; all of the front teeth tipped inward and were shortened, being depressed by the pressure of the lip and tongue. The vault of the upper arch was high and contracted laterally. The bicuspids, cuspids, and incisors needed to be moved outward.

It was found, from a study of the models, that the teeth of the anterior part of the arch could be made to approximate fairly well by expanding the upper arch, destroying the pulps of some of the molars on each side, grinding the crowns away, also dressing a little from the surface of the bicuspids, and then applying a chin-cap as described. The patient was advised to adopt this plan of treatment, and to visit the rhinologist again for the improvement of the

Fig. 410.

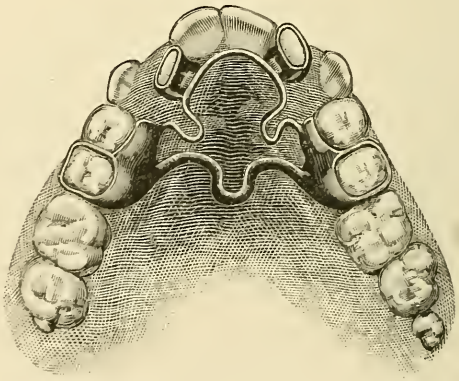

condition of the nasal organs, with the hope of making her a nose-breather.

To expand the arch and move the incisors outward, an appliance was constructed as follows (Fig. 410): Spring-clasp attachments were made to pass over the second bicuspids, with partial-clasps on the first bicuspids. The anchorage portions were connected with a palatine spring base-wire, No. 14 B. & S. gauge, formed to cross the arch, with a U-shaped loop resting at the median line. A spring-wire, No. 18 gauge, was bent to follow the lingual contour of the

incisors, passing under lugs on collars that were cemented to each of the laterals; back of these a U-shaped loop was formed in the wire on either side, with the end of the loop pointing towards the median line, and fitting close to the soft tissues. The ends of the spring were then curved backward and united with solder to the anchorage.

The action of the appliance was caused by opening the loops in the spring for moving the incisors outward. After they were moved nearly to position, the loop in the base-wire was broadened for expanding the arch. The teeth were moved outward sufficiently, and retained with the same appliance. The expansion of the arch in this manner elevated the incisors, and improved the occlusion and general appearance of the teeth and of the features. Preparations were made to shorten the crowns of the molars, and to apply a chin-cap, but the patient was taken ill, and for retaining, a rubber plate was inserted, covering the palatine arch, and fitting accurately the necks of the teeth. After three years the conditions were found to be much improved.

The chin-cap was used after the expansion of the upper arch in the case of Mr. L., a minister aged twenty-four years (Fig. 411). The patient was a mouth-breather with progressive lack of anterior occlusion, the lips being closed with difficulty, interfering with speech. A rhinological operation was performed and the chin-cap applied, which soon caused marked improvement in the breathing. Fig. 412 illustrates the apparatus in position. It was worn as many hours as practicable, gradually elevating the jaw and permitting the lips to close easily. In a year's time the occlusion of the teeth and pronunciation were quite satisfactory, but the patient was advised to continue the application of the chin-cap with lessened force.

I have treated some cases of lack of anterior occlusion which were dismissed with a feeling of dissatisfaction, while in others the treatment proved to be of more value than was expected. In the case of Miss S., none of the teeth in front of the second bicuspids occluded; the lower jaw closed a little to one side. These conditions were corrected by grinding the occluding surfaces of the molars, thus permitting the teeth in the front of the mouth to articulate. To improve the occlusion, it occasionally becomes necessary to dress a good deal from the crowns of the teeth, in some cases to destroy the pulps. Dr. Guilford recommends the use of an

anæsthetic when the dentine is sensitive, to allay the pain while grinding, afterwards making repeated applications of chloride of zinc, caustic potash, or nitrate of silver for obtunding. When this does not control the sensitiveness of the dentine, it may be necessary to devitalize the pulps of two or more teeth on each side of the arch, and subsequently to treat and fill the canals.

When there is a considerable lack of occlusion that would require the grinding both of the upper and lower back teeth, I think it is usually better to preserve the lower ones and to extract the upper molars and sometimes the bicuspids to permit the approximation of the jaws, and to insert a plate. When the extraction of the upper teeth is not sufficient to let the jaws come together, enough of the alveolar process and gum should be removed to favor the desired occlusion and also to allow sufficient space for the introduction of a partial upper plate of metal or vulcanite. If the space procured by the removal of the teeth and process is not sufficient to admit the use of porcelain teeth, a bite may be made directly on a metal plate, or white vulcanite used to represent teeth on an ordinary base-plate. Usually in these cases the distal part of the upper arch is much vaulted, and the treatment in this manner leads one out of difficulty without the grinding and final destruction of the lower molars, at the same time causing a good occlusion. In some rare cases the same method of treatment can be applied in the lower arch, but it is seldom required.

The grinding of the crowns of the teeth is occasionally necessary to allow the teeth of one arch to fit more closely with those of the opposite arch. This is sometimes required after expanding for the correction of the position of irregular incisors; a procedure which often tips the molars and bicuspids outward, especially when the upper arch has been spread to much extent. The new position of the teeth elevates them, opening the bite and separating the upper and lower front teeth. To lessen this abnormal condition force should be applied with the chin-cap to depress the teeth on the sides of the arch, or the cusps of the teeth that prevent the proper occlusion should be dressed away. The latter method is generally preferred when only a little change is required. When done judiciously the grinding is not a material injury to the teeth, and the final result often proves satisfactory. (See Shaping the Teeth.)

Lack of Posterior Occlusion.—The teeth in the distal part of the

Fig. 411.

Fig. 412.

arch on one or both sides of the circle do not close together, while those in the front of the arch occlude.

There are but few recorded cases of continued lack of occlusion of the posterior teeth. When this condition exists in young patients all of the pressure from occlusion is exerted on the front teeth; this generally drives them more deeply into their alveoli, and at the same time, there being no pressure on the teeth in the distal part of the arch, they gradually become elevated until they meet with those of the opposite arch. When only the incisors, and perhaps the cuspids occlude with their antagonists, it is generally found that in chewing the patient has the habit of moving the lower jaw sufficiently forward to permit the lower incisors to close in front of the upper ones. This usually allows the molars and bicuspids to antagonize. The condition may be improved by the expansion of one of the arches, or by wearing a chin-cap. This should extend far back on either side for causing upward traction under the body of the jaw, the cranial-cap being placed well forward on the head; when necessary first opening the bite.

Fig. 413.

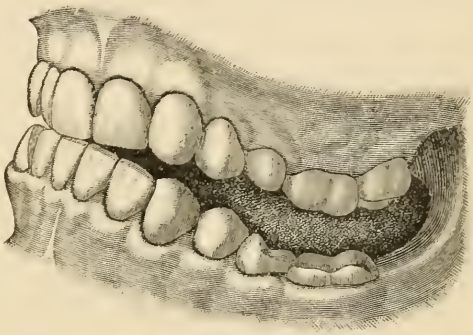

Fig. 414.

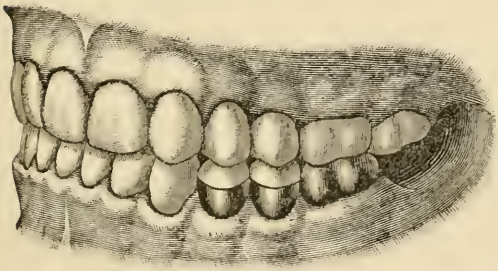

Dr. Willis* cites the case of a girl aged sixteen years with lack of posterior occlusion (Fig. 413), which he corrected by the application of gold crowns to the molars and bicuspids (Fig. 414).

Lack of Lateral Occlusion.—The teeth in the region of the bicuspids do not articulate, while there is a good occlusion of the incisors in the anterior and the molars in the distal part of the arch. This

* Willis, Dental Cosmos, 1895, p. 584.

irregularity is generally due to the impaction of one or more of the teeth, and may occur on one or both sides of the arch. It is caused usually by the tardy eruption of the bicuspids, the deciduous teeth being extracted too early and the adjoining teeth crowded into the space. It may also result from heredity or arrested development of the jaw or alveolar process. When resulting from impaction in young patients, the broadening of the space will usually permit the teeth to become elevated to a correct level. If the teeth do not take a good position, an appliance with a base-wire supporting a finger-spring, shaped to engage with a lug on a collar cemented to each of the teeth to be moved, should be applied for their elevation. (See Elevation of Bicuspids, page 408.)

When it is determined that the lack of occlusion is the result of heredity or arrest of development, there is generally no advantage in the elevation of the teeth mechanically, as when they are raised in their sockets the necessary additional bone or process for building up is not usually supplied, and when the retaining device is removed the teeth settle back more deeply than before regulating. Sometimes as the teeth are elevated the adjoining ones settle more deeply into their sockets.

CHAPTER XXI

CUSPIDS, TO MOVE OUTWARD—FORWARD IN THE LINE OF THE ARCH

The permanent cuspids are erupted from about the tenth to the twelfth year, gradually wedging their way into proper line in the circle of the arch. When from the premature loss of the deciduous cuspid or other reason the space between the adjoining teeth has become too narrow for the admission of the permanent cuspid, it is frequently caused to point outward and take a more or less prominent position, or it may incline inward and take a position inside of the line of the arch. The former accident is the more frequent; there are more cases with the cuspids too prominent than inclining inward.

If an irregular cuspid is not forced to proper line soon after its eruption, it occasionally becomes necessary to extract one of the bicuspids to admit it into the circle and prevent overcrowding.

During its eruption the cuspid is moved readily, but its root is long, and after the alveolar process has shrunken around it and become dense it often requires more force to move a cuspid than any of the other teeth. In the adult, all of the teeth used for anchorage may be forced more or less out of position before it will yield, therefore an appliance for the movement of a cuspid should be firmly anchored.

A thick layer of alveolar process sometimes prevents the tooth from advancing as rapidly as it should when force is applied. In this case a longitudinal section of the process in front of it can be removed with a small instrument, as a trephine or pointed barrel bur, to hasten its movement, always avoiding injury to the immediate bony socket about the root. The removal of alveolar process to encourage the regulation of teeth in other parts of the arch is sometimes justifiable.* In some instances the retention of teeth after regulation is assisted by removing some of the process in this manner.

Fig. 415 illustrates a device that was used for moving outward and forward a right upper cuspid for Miss A., aged eighteen years.

The lateral incisors had not erupted, and the cuspid closed inside

---

* Jackson, Dental Cosmos, 1890, p. 293.

of the lower arch. A palatine base-wire, No. 14 gauge, the foundation of the appliance, crossed the arch at about the line of the first bicuspids. On the left side, it was anchored by partial-clasps on the cuspid, bicuspids, and first molar, with a spring-clasp attachment around the second bicuspid; on the right side by a spring-clasp attachment to the first bicuspid.

Fig. 415.

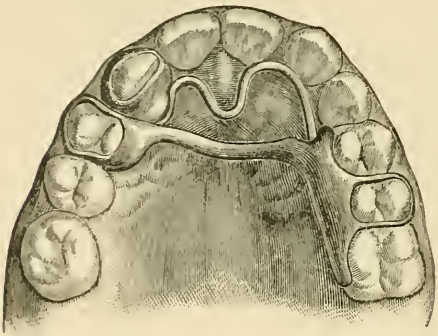

The spring to move the cuspid outward was attached to the partial-clasp with the end of the base-wire on the left side, and was bent into two U-shaped loops about three-eighths of an inch long, forming a letter S. The other end of the spring was made to extend in a gentle curve across the arch to the cuspid to be moved, where it was bent nearly to a right angle and shaped to pass underneath a lug on a collar cemented to the tooth. The loops in the spring-wire were opened to give the desired pressure. It is always well to arrange the loop-shaped portion of the spring on the opposite side of the arch from the tooth to be moved.

Fig. 416.

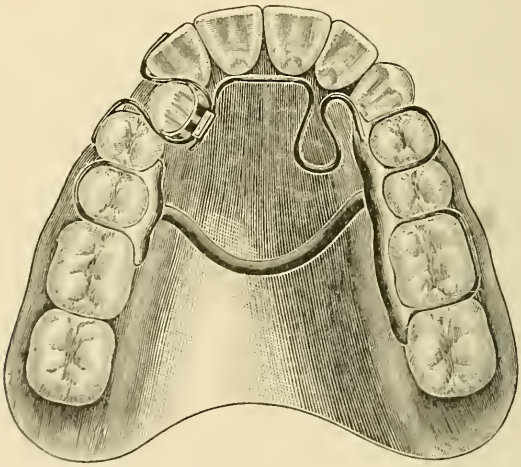

When the right upper cuspid is erupted inside of the line of the arch, with insufficient space to admit it (Fig. 416), an appliance can

be made to broaden the space and move it into position, by adjusting a rigid palatine base-wire to cross the arch. Anchor its ends strongly by partial-clasps and spring-clasp attachments. A spring-wire is then to be attached to the base-wire or to partial-clasps on the left side, where it is formed into one or more U-shaped loops with the end extending across the arch to rest on the cuspid at an angle suitable for moving it outward.

When there is insufficient room to admit the cuspid, it is usually necessary to apply force for increasing the space, otherwise, as the cuspid is moved outward, one or more of the adjoining teeth are likely to be forced with it and assume an irregular position.

To increase the space between the lateral incisor and first bicuspid, a U-shaped spring is formed by bending a small wire twice at right angles, the distance between the parallel arms being equal to the antero-posterior width of the cuspid. This wire is sometimes soldered to the end of the looped spring, and made to extend over the grinding surface either side of the cuspid at the junction with the adjoining teeth. The arms are then bent towards the gum on the labial side and separated, one end resting on the labial face of the lateral incisor, and the other on the first bicuspid.

Springing the appliance into place, after separating the ends of the wire last described by bending, tends to increase the space for the cuspid, and when the ends are curved backward they cause pressure on the labial face of the incisor, and the bicuspid, thus assisting in moving the cuspid outward. When necessary a collar with a small lug on the lingual side may be cemented to the cuspid to retain the spring in position.

If the tooth has not become too firmly set in the socket, the U-shaped spring last described may be used alone for moving a cuspid outward.

In Fig. 417 is shown a device for moving outward a cuspid when great force is required. The anchorage includes all of the teeth but the cuspid to be moved. It is made with a broad rigid base-wire crossing the distal part of the arch, and a lingual base-wire passing back of the incisors. These are anchored with partial-clasps and spring-clasp attachments to some of the teeth in the usual manner, and to others with continuous spring-clasps, and wire-clasps. A large spring is attached to the anchorage on the opposite side of the arch from the cuspid to be moved. It extends backward, crossing

the arch, following approximately the line of the palatine base-wire, then extends forward like an arm to rest under a lug on a collar cemented to the cuspid. Force is caused by bending the end of the

Fig. 417.

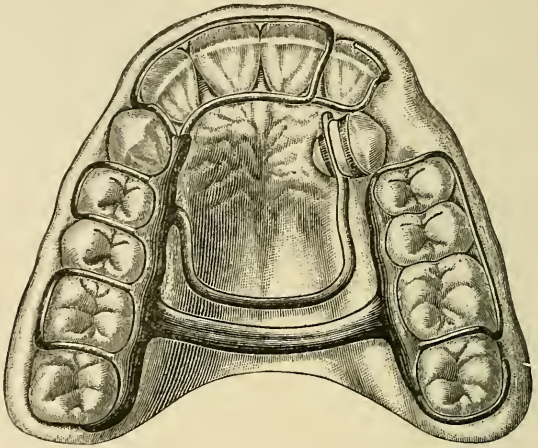

arm outward. Two springs of this character can be utilized when excessive force is required.

Fig. 418 shows a compensating device used several years since by the author to move outward a cuspid that had a lingual occlusion, and at the same time to draw into line a prominent lateral incisor.

It was made of spring-wire, being shaped to extend around the buccal and lingual sides of the molar, and bicuspids at the gum line.

Fig. 418.

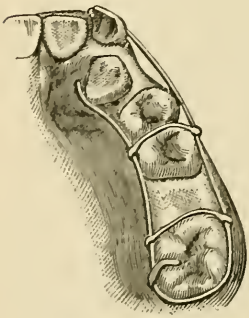

The outer and inner sides of the device were connected by passing two arms of wire over the arch at the junction of the teeth, the ends being shaped to hook over the wires to which they were soldered. The ends of the spring were left free, one arm extending to the lingual side of the instanding cuspid, and the other to the labial side of the prominent lateral, to move these teeth to their respective positions. With this form of device, if it is not well retained, partial-clasps should be employed, and a collar with a lug on the lingual side cemented to the cuspid, and another when need be on the lateral incisor.

The following is the history of the case of Miss T., aged sixteen

years.* Both of the lower first molars had been extracted, and the second molars had moved forward and taken their place. The upper incisors were too prominent, and the laterals were twisted outward so that their edges rested across the lower arch. The left upper cuspid was about one-third erupted and was inside of the circle of the arch, with insufficient space for it in proper line. The removed teeth, including the first left upper molar, had been extracted by a practitioner who inserted a vulcanite plate that covered the roof of the mouth and extended through the space made by the removal of the molar, to form a clasp around the second molar. From this projected a metal point, both on the labial and lingual side of the tooth, for the attachment of four rubber bands which extended to and were hooked over gold spurs that projected from collars cemented to the first and second bicuspids for the purpose of drawing them back-

Fig. 419.

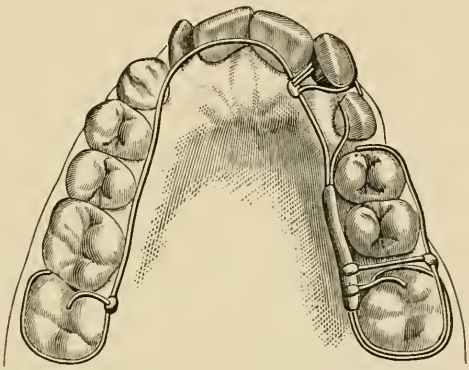

ward to make room for the cuspid and lateral incisor. The plate was well adjusted, but as the molar was very short it was not well retained.

The patient was referred to the writer, and an appliance made as shown in Fig. 419. A base-wire was formed to follow the lingual side of the teeth, and retained with wire-clasps extending nearly around each of the second molars. A U-shaped spring with long extending arms was then formed so as to pass on either side of the second left molar and the bicuspids, and attached to the base-wire on the lingual side. One end of the spring was shaped to press outward on the lingual surface of the instanding cuspid, and the other arranged to rest on the mesial surface of the first bicuspid for

* Jackson, Dental Cosmos, 1891, p. 1080.

moving it and the second bicuspid backward in the line of the arch. The U-shaped spring was stiffened by connecting the sides with a wire which was attached to the base-wire and made to pass outward just in front of the molar.

After the cuspid was nearly in correct position, a new appliance, as shown in Fig. 420, constructed with base-wire and partial-clasps, was introduced to retain the teeth that had been moved, and to rotate both laterals mesio-lingually. As the teeth were prominent, the second bicuspid on the right side was extracted to relieve the crowded condition, and the first bicuspid and cuspid were moved backward by two finger-springs, one arranged on the buccal and the other on the lingual side, as described for moving the bicuspids on the left side. At the same time other springs were added to the appliance for rotating the lateral incisors. The object was to have a spring-wire with a straight portion in contact with the lingual side of the tooth, and another extending from the base-wire in a curve, resting on the labial side in such a manner as to cause pressure for rotating it. The angle of the ends of the springs was changed from time to time as required. Fig. 421 illustrates the appliance in position.

Fig. 420.

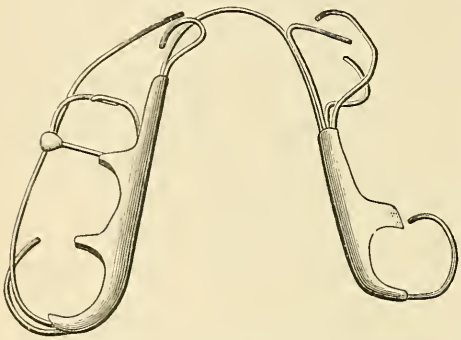

Fig. 421.

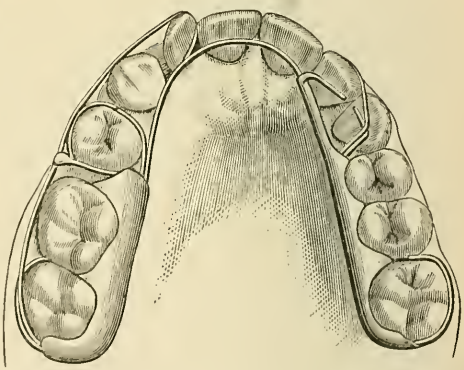

I usually depend on spring-pressure for moving instanding cuspids, but some operators are partial to the use of the jack-screw. It can be anchored with spring-clasp attachments, as shown in Fig. 422, or a palatine base-wire can be utilized for strengthening this form of anchorage, having spring-clasp attachments extending over one or more teeth on each side of the arch. In making the appliance, the jack-screw should be

placed in position on the model, with the nut in contact with the partial-clasps to which it is joined with soft solder, at the same time uniting the anchorage portion. A collar is then cemented to the cuspid, with a suitable socket to hold the pointed end of the jack-screw.

Fig. 422.

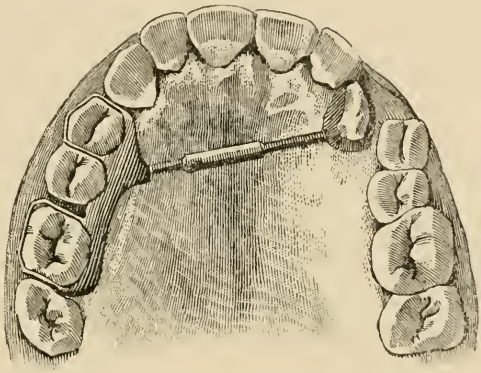

This is a convenient form of anchorage, and permits of easy removal for cleansing.

When one or both of the upper cuspids are inside of the line, with nearly sufficient space for them to take a normal position between

Fig. 423.

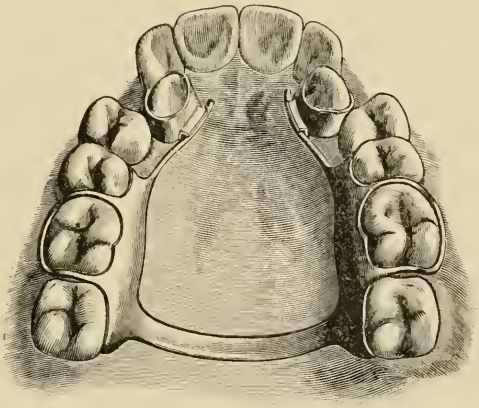

the lateral incisors and first bicuspids, constant force is the only requisite for moving them outward, the space being increased by their movement.

A convenient form of device for their correction is seen in Fig. 423. A collar with a lug on the lingual side is cemented to each of

the cuspids to be moved. A palatine base-wire is anchored with spring-clasp attachments to the first molars or second bicuspids, according to the length of the spring-arms it is desired to use, the arms being of suitable size and shaped to project forward from the anchorage on either side to rest under the lugs to give the required force. Generally it is advisable to have the spring-arms rather long. The base-wire should be rigid, being made of a large-sized wire, or of two or more smaller wires united, and located well back if other parts of the arch are to be expanded laterally, when a slight bend in the wire is sufficient for causing lateral force.

Fig. 424 shows a method employed for moving outward two instanding upper cuspids, and equally available for moving outward the cuspids of the lower arch.

A spring base-wire, usually No. 17 gauge, is formed into three U-shaped loops, each about three-eighths of an inch long; the

Fig. 424.

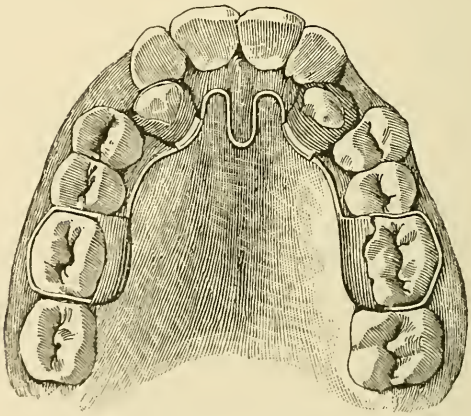

middle loop pointing backward at the median line, and the other loops resting back of the central incisors, the outer sides being arranged to press against the lingual surface of the cuspids to be moved. The ends of the spring extend backward to a spring-clasp attachment for anchorage on either side. A collar with a lug soldered to it in suitable position should be cemented to each of the cuspids, to keep the spring portion of the appliance from slipping out of position. Action is caused by opening the loops in the spring for the desired pressure.

This form of apparatus, when used in the upper arch, can be made more rigid by the addition of a palatine base-wire.

A simple device for correcting the position of upper cuspids that have erupted inside of the arch and require to be rotated is illustrated in Fig. 425. A collar is cemented to each of the cuspids, with a tube on the lingual side near the gum. A spring-wire is

Fig. 425.

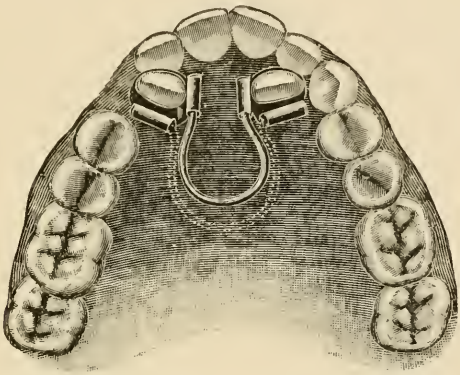

bent into a broad U-shaped loop, fitting the contour of the roof of the mouth, as shown by the dotted lines, or the spring may be extended farther back, as in Fig. 457, with the ends bent outward in position to enter the tubes. Force is brought to bear on the cuspids for their movement, by bending outward the arms of the loop, while at the same time the ends of the spring that enter the tubes are bent backward in form to give the force for rotating them.

If more force is required, a larger spring can be adopted, or an additional spring formed into a large loop similar to the one described, its ends extending into other tubes, which are soldered longitudinally to the collars and parallel with the median line near the gum, as shown in the figure. Or a short section of tube can be attached to the collar in a perpendicular position, which is sometimes preferred, the spring being bent at a right angle to enter the tubes. These tubes necessarily have to be dressed away before the teeth can assume a normal position.

Springs for moving the teeth in this manner can be made in various forms.

Fig. 426 illustrates a device for moving outward instanding cuspids, at the same time contracting the anterior part of the arch. A palatine base-wire is anchored with spring-clasp attachments to the second bicuspids. A spring-wire is bent into three U-shaped loops,

conforming to the palatine arch, the centre loop pointing backward at the median line, and the outer sides of the other loops resting under lugs attached to collars cemented to the cuspids. The ends of the spring extend backward, and are attached with solder to the

Fig. 426.

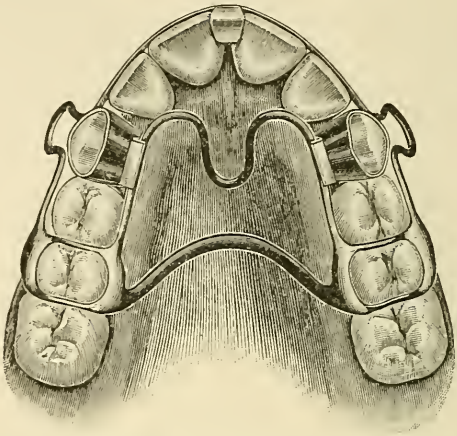

partial-clasps with the ends of the base-wire. The opening of the loops slightly from time to time by bending forces the cuspids outward, giving room for the inward movement of the incisors.

A semicircular spring for contracting the anterior part of the arch is fitted to the labial side of the incisors, with a loop arranged on either side opposite the cuspids. The ends of the spring extend backward at the gum line, and are attached to the spring-clasps by passing underneath them a thin narrow piece of metal, shaped like a partial-clasp; they are united with solder, or they can be arranged to hook into eyelets attached to the spring-clasps. Force on the incisors is applied by closing the loops slightly.

For moving cuspids outward, sometimes a labio-buccal spring base-wire can be used by attaching spring-clasps to the ends, so located and shaped as to hook over lugs on the lingual side of collars cemented to the cuspids or the ends of the base-wire, shaped to hook into tubes or eyelets attached to the buccal side of the collars, the base-wire being bent outward a little from time to time as required. In the same manner bicuspids and molars may be moved outward with a labio-buccal base-wire, either by hooking into tubes, by individual spring-clasps, or by continuous spring-clasps passing over those to be moved.

When the apparatus employed is not efficient in moving cuspids outward, or forward in the line of the arch, supplemental force may be applied as seen in Fig. 144; or with an infralabial or supralabial bar similar to Fig. 373. In either case, a collar with an eyelet

Fig. 427.

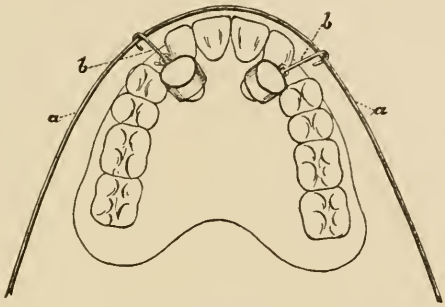

on the labial side may be cemented to each of the teeth to be moved, as shown in Fig. 427. From the labial spring, or bar, *a*, *a*, curved wires, *b*, *b*, are arranged to extend over the lip to hook into the eyelets.

CHAPTER XXII

CUSPIDS, TO MOVE INWARD—BACKWARD—ELEVATE—DEPRESS—ROTATE

Moving Cuspids Inward—Backward in the Line of the Arch.—When the right upper cuspid is too prominent and only partially erupted, with insufficient space for it in a normal position (Fig. 428), the following method of moving it into place will be found efficient: Form an anchorage to the teeth on the left side with a spring-clasp attachment over the first bicuspid and first molar. Attach to the anchorage a spring bent into a U-shaped loop resting near the gum back of the central incisors, with the end extending to the opposite side of the arch passing back of the lateral, where it is again to be formed into a loop as wide as the width of the cuspid to be moved;

Fig. 428.

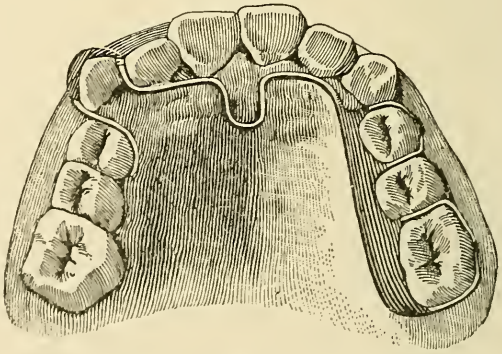

the free end being shaped to cross the mesio-lingual surface of the first bicuspid. The outer part of the loop is to be bent upward to rest on the labial side of the cuspid at the gum line for the purpose of forcing it inward. The portion of the spring back of the lateral incisor is gradually straightened to broaden the space, and the desired force for moving the cuspid is applied by curving backward the end of the spring on the lingual side of the bicuspid, at the same time closing slightly the U-shaped loop at the median line.

If the spring is not well retained, a partial-clasp can be formed to the labial side of the cuspid and united to the spring with solder;

or a collar with a slight lug can be placed on the lateral incisor or first bicuspid. When the cuspid is not fully erupted, the operator should be careful not to wedge it between the adjoining teeth by applying too much force without increasing the space, as the lateral pressure would retard its eruption; nor should he let the shape of the spring in any way interfere with its downward movement. He should first broaden the space and then force the cuspid inward.

In cases where the upper cuspid outside of the line of the arch is fully erupted, with the space between the adjoining teeth much too narrow for its admission, and it has been determined by measurement that it is not necessary to extract one of the bicuspids (Fig. 429), simple pressure on the labial side of the cuspid will not usually be

Fig. 429.

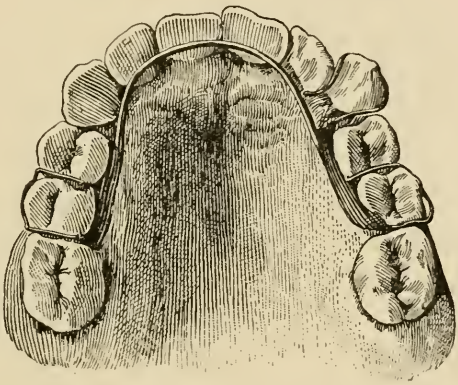

sufficient for its correction, as the force will often move the adjoining teeth towards the centre of the arch. The latter may be avoided by an appliance made in the following manner:

A lingual base-wire is formed to the contour of the arch at the gum line, the ends anchored on either side with partial-clasps and a spring-clasp attachment. The spring for moving the cuspid is soldered to the partial-clasps with the base-wire, made to pass through the space in front of the first bicuspid near the grinding surface at the junction of the teeth, and bent into the form of a loop curving upward towards the gum; it crosses the labial face of the cuspid. The front arm of the loop is shaped to pass over the arch near the incisive edge, the end resting on the disto-lingual surface of the lateral incisor. The space is increased by broadening the loop of the spring, and the cuspid is forced into place by

curving nearer to the base-wire the portion of the loop that crosses the labial side, the base-wire preventing the adjoining teeth from being pressed inward.

An appliance that is effectual for forcing into line an upper cuspid that has erupted too prominently and anterior to its normal position is shown in Fig. 430. It is made by forming a lingual base-wire to

Fig. 430.

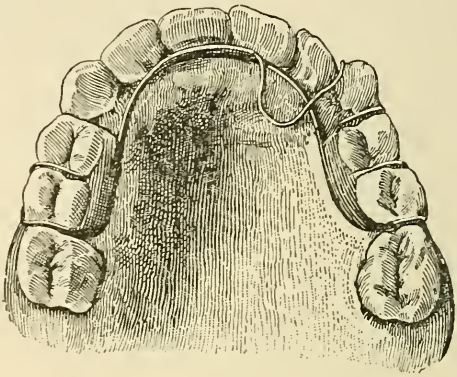

the inner curve of the arch, anchored on either side with partial-clasps and a spring-clasp attachment.

A spring-wire is soldered to the base-wire opposite the incisors, it having been bent into a shallow loop projecting towards the median line; the spring extends over the arch at the junction of the lateral incisor and cuspid near the edge, where a secondary loop is formed to cross the mesio-labial side of the cuspid near the gum, the end resting on the mesial surface of the bicuspid. The location of the attachment of the spring to the base-wire should be governed by the required direction of pressure. Force for moving the cuspid is applied by bending inward the whole spring, or the part that crosses the labial side. When the space is insufficient it can be increased by the lateral action of the loop.

The two following figures illustrate the case of Mr. M., aged twenty-six years. The patient was a large-framed man with dense bony structures.

In the upper arch the right cuspid was outside of the circle and very prominent, with a space only about one-third of its width. The left cuspid and the lateral incisors were also irregular. In the lower arch the first right bicuspid and cuspid were too prominent,

with little more than sufficient space to admit one of them in proper position. The incisors were much crowded and irregular.

After a careful study of the conditions, it was not deemed expedient to expand the arches sufficiently to admit the irregular teeth. A first upper and lower bicuspid were extracted, and appliances made for moving the cuspids into position. Both appliances were worn at the same time.

Fig. 431 shows the form of device used for correcting the position of the upper cuspid. A lingual base-wire was shaped to follow the

Fig. 431.

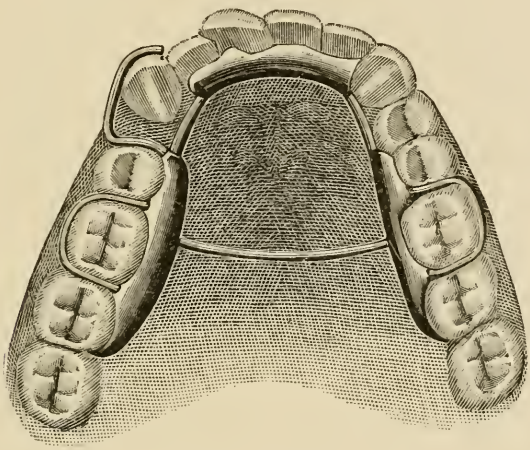

inner curve of the teeth; its ends were anchored on each side by partial-clasps and a spring-clasp attachment. The sides were connected with a palatine base-wire to give more stability to the appliance. Partial-clasps were also arranged on the lingual side of the incisors and attached to the base-wire for the purpose of assisting the anchorage. A stiff spring for moving the cuspid was soldered to the partial-clasp with the base-wire; it extended through the space just in front of the second bicuspid to the buccal side, where it was bent forward in a curve to rest on the mesial surface of the cuspid, ending in the shape of a partial hook. The spring was curved backward from time to time to cause pressure on the cuspid, and as it moved, the end of the spring was cut away to prevent it from coming in contact with the lateral incisor.

Fig. 432 illustrates the appliance used in the lower arch. Partial-clasps were arranged on the second bicuspids and first molars, with

wire-clasps around the second molars. A spring-clasp attachment passed over the first molar on the right side, but owing to the worn condition of the teeth no spring-clasp was used on the left side. From the dense structure of the tissues and the position of the

Fig. 432.

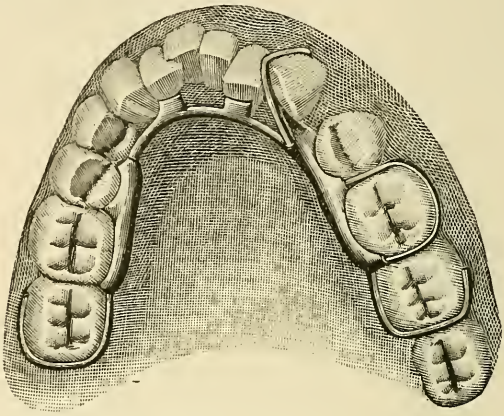

cuspid it was evident that its movement would require more than ordinary force, and additional anchorage of the appliance was effected by fitting flat pieces of metal to the lingual side of the lateral incisors in front of the base-wire to which they were soldered. These metals were bent forward later for moving the laterals outward.

A strong spring-wire for moving the cuspid was attached to the partial-clasp by the base-wire on the right side, and extended forward in a curve to pass over the arch at the junction of the cuspid and lateral incisor, where it was bent downward to the gum line, with the end shaped to rest on the mesio-labial surface. Additional force was caused as required by bending the end of the spring backward.

Usually this form of spring is more easily controlled when attached to the base-wire some distance back of the tooth that is to be moved.

When an upper or lower cuspid is too prominent, with insufficient space, and the first molar has been removed on account of decay or to relieve the overcrowded condition, the cuspid can be moved to proper position, and the bicuspids at the same time moved backward into the space caused by the extraction. The device is shown in Fig. 433.

A stiff lingual base-wire should be arranged to follow the inner curve of the arch, resting in contact with each of the incisors, with one end anchored with a spring-clasp attachment to the second left molar, and the other end strongly anchored to the molars and bicuspids. When necessary, the front part of the appliance is further retained by fitting partial-clasps to the incisors and attaching them to the base-wire, or by cementing to one or more of the incisors a collar with a slight lug to engage with the base-wire, in this manner utilizing for anchorage all of the teeth that are not to be moved. For moving the cuspid and bicuspids backward a spring-wire, No. 17 gauge or larger, is attached to the base-wire and partial-clasp, the spring being shaped to extend through the space just in front of the second molar to the buccal side, where it is bent forward, the end terminating on the mesio-labial surface of the prominent cuspid.

Fig. 433.

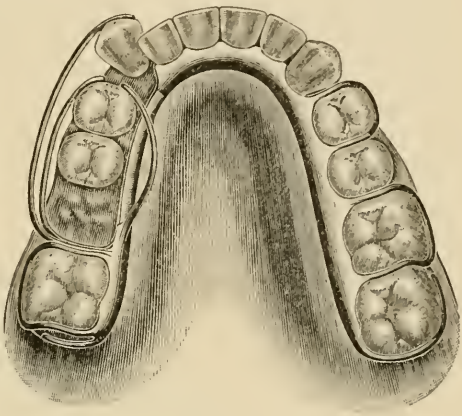

Generally it is advisable to first start the bicuspids in their movement by a U-shaped spring attached to the base-wire just in front of the second molar. The arms should extend forward to the mesial surface of the first bicuspid, one passing on the lingual and the other on the buccal side. Force is caused by curving the ends of the springs slightly from time to time, dressing them as required.

Fig. 434.

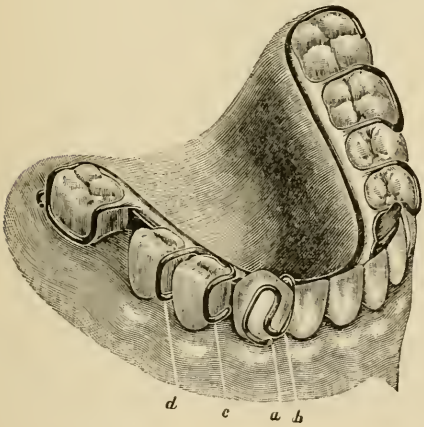

Fig. 434 illustrates a similar device that has given satisfaction for moving a cuspid and two bicuspids backward when considerable force is required. The spring

is attached to the base-wire opposite the bicuspids to be moved. It is shaped to extend forward, passing over the arch in front of the cuspid, where it is formed into a double U-shaped loop conforming to the surface of the tooth, with the end curved forward to rest on the mesial and labial side at the gum line, as shown at *a*, *b*. To assist in moving the bicuspids backward an additional spring is sometimes used to advantage by first separating the teeth with a wedge and attaching the spring to the base-wire. It is first bent twice at right angles with the distance between the parallel sides a little more than the antero-posterior measurement of the first bicuspid. The ends are then curved downward and backward towards the base-wire, and left sufficiently long to rest between the teeth near the gum, with one end arranged to cause force on the mesial surface of the second bicuspid and the other on the mesial surface of the first bicuspid, as shown at *c*, *d*. Force is applied by bending backward the ends of the curved springs, first moving backward the second bicuspid.

Fig. 435.

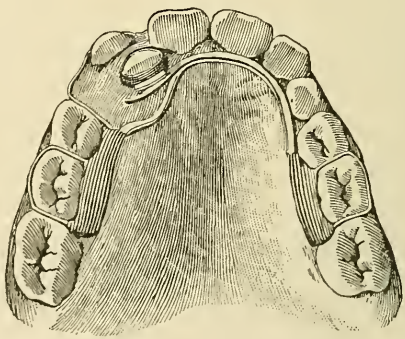

Fig. 435 illustrates the case of a boy aged nine years. The right upper lateral incisor had a lingual occlusion. The permanent cuspid had erupted directly in front of it, while the deciduous cuspid was still in place. The deciduous incisors were lost earlier than usual, two of them being joined. Each of the parents had full regular arches of teeth. A rather unusual feature in the case was the eruption of the right permanent cuspid before the loss of the deciduous cuspids or molars.

The deciduous cuspid was extracted and an appliance made to correct the position of the irregular teeth. A lingual base-wire was

applied considerably back of the lateral to be moved, and its ends were anchored by spring-clasp attachments to the deciduous molars. The permanent cuspid was moved into place by a curved finger-spring soldered to the partial-clasp with the base-wire, and shaped to pass close to the mesial surface of the first deciduous molar, through the space caused by the extraction of the deciduous cuspid. It was bent forward, ending in a curve on the mesio-labial surface of the permanent cuspid. The lateral incisor was moved outward by a finger-spring fastened to the base-wire near the anchorage on the left side; it followed the lingual curve of the arch, extending to the distal side of the lateral incisor, and passed under a lug on a collar for anchorage. Force for moving both of the teeth at the same time was applied by the springs.

Fig. 436.

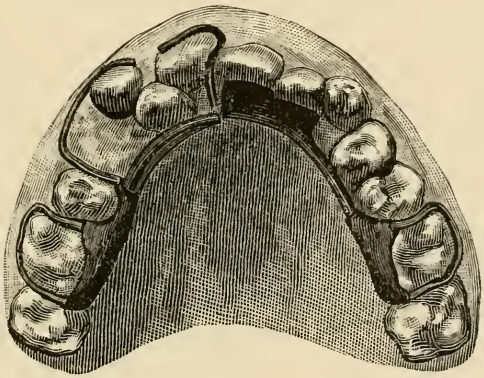

Fig. 436 illustrates a device for moving into line a right upper cuspid and central incisor that were too prominent, with insufficient space for them in the arch, and at the same time moving outward an instanding lateral.

A first bicuspid was extracted to afford the necessary space. A lingual base-wire was anchored to the remaining bicuspids and first molars. The cuspid was moved backward by a curved finger-spring. A similar spring was attached to the base-wire just back of the central and lateral incisor on the left side, in connection with two inclined planes made of plate-metal. It was shaped to extend over the arch at the junction of the central incisors, and bent at a right angle to rest on the labial face of the prominent incisor near the gum.

A third spring was attached in the anchorage on the right

side, and curved forward to rest on the mesio-lingual surface of the lateral incisor. Force was applied by all of the springs at one time, gradually moving the teeth into a normal circle. A spring shaped like the one extending over the arch at the median line, can be used to move several teeth laterally towards one side.

Fig. 437.

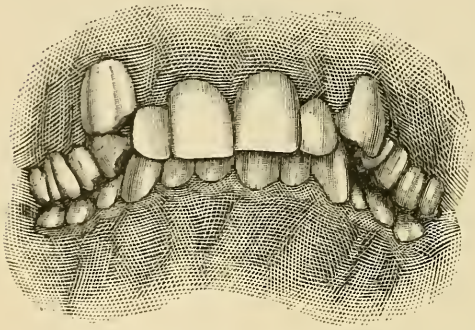

In Fig. 437 is shown the position of the teeth of Miss A., aged fifteen years.

The upper cuspids were very prominent, and rested somewhat over the lateral incisors, forcing the laterals out of place. The first bicuspids had moved forward, occupying a position near the lateral incisors. The laterals needed to be moved somewhat outward. The left central incisor was too prominent, and required to be moved inward. The first upper bicuspids were extracted, and an appliance was made for the correction of the position of the irregular teeth, as shown in Fig. 438. The lower incisors impinged upon the gum of the upper arch, necessitating the arrangement of the foundation or base-wire of the appliance with a space between it and the upper incisors. The base-wire was anchored by spring-clasp attachments to the first molars, partial-clasps on the second bicuspids, and by pieces of plate-metal, No. 24 gauge, shaped in the form of inclined planes resting against the lingual side of the lateral incisors; these followed the contour of the gum back to the base-wire to which they were soldered. After the cuspids were moved to position, the metal inclined planes were bent forward slightly, causing pressure on the lingual side of the lateral incisors for moving them outward, while at the same time

Fig. 438.

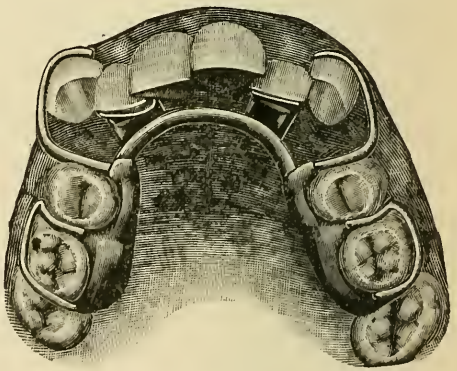

they were moved laterally by curving forward the inner edge of the metals. The appliance was inserted February 15, and the teeth were in a good position on July 6, the appliance being worn as a retainer.

In moving prominent cuspids inward or backward, it is sometimes necessary to apply supplemental force with the cross-bar in connection with an appliance in the mouth, as otherwise the anchorage teeth are liable to be drawn forward by the extreme pressure required.

Fig. 439 illustrates a cross-bar device that was used in 1897 for the backward movement of the lower cuspids in the case of a young

Fig. 439.

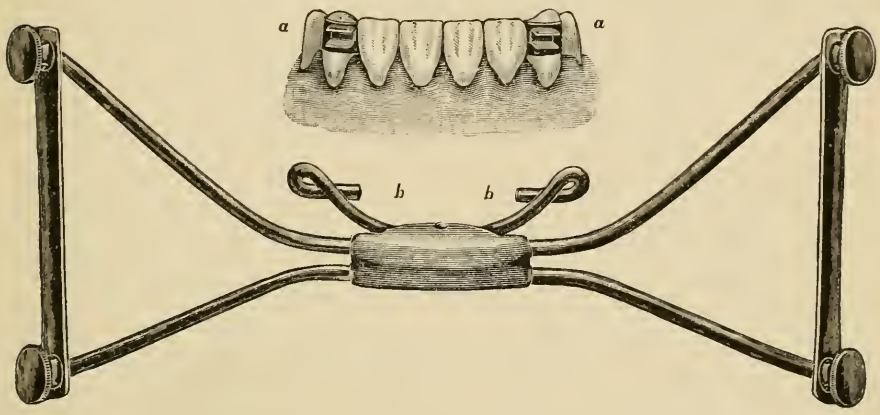

man aged twenty-two years. A broad collar with a curved piece of flat metal as long as the width of the tooth, soldered horizontally to the labial side, forming a groove as seen at *a*, *a*, was cemented to each of the cuspids. A semicircular wire, No. 8 gauge, with the ends bent downward and at an acute angle towards one another, as shown at *b*, *b*, with the right distance between them to rest in the grooves on the collars, was hinged in the centre to the cross-bar. Force was applied by elastics and straps extending from a cranial-cap to the knobs of the cross-bar. The semicircular wire should always be shaped to interfere as little as possible with the closure of the lips.

The cross-bar device has been used to advantage in forcing inward or backward prominent lower and upper incisors, cuspids, bicuspids, and molars on one or both sides of the arch.

In the case of Miss D., aged twenty-four years, the right upper

cuspid was tardy in its development, and the bicuspids and molars had moved forward, narrowing the space. The cuspid was elevated, and supplemental force was applied with the cross-bar to reduce its prominence and at the same time to move backward the bicuspids and molars. The attachment of the cross-bar to these teeth was made with a removable cap and socket retained with a spring.

Fig. 440.

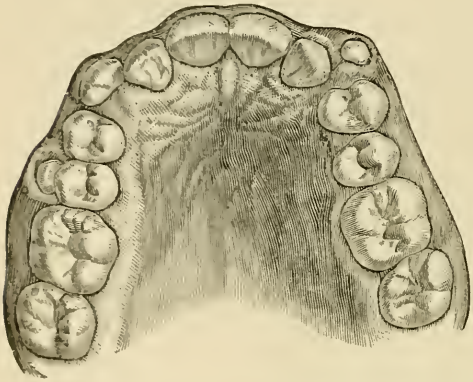

Fig. 240 illustrates another form of apparatus for causing supplemental force in moving backward any or all of the teeth of the upper arch. For supplemental force in moving backward the teeth of the lower arch, see Fig. 212.

Fig. 440 illustrates the case of Miss V., aged eleven years.* The upper cuspids were erupting entirely outside of the line of the arch, with insufficient space to admit them. The lateral incisor on the left side rested nearly in contact with the first bicuspid.

Fig. 441.

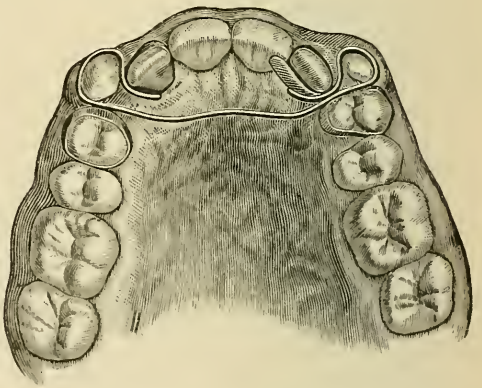

A spring for getting space, moving the incisors outward and forcing the prominent cuspids inward, was shaped as seen in Fig. 441. The spring, No. 20 gauge, crossed the arch, following the lingual curve, the ends passing to the buccal side just in front of the bicuspids. There it was curved forward and bent back on itself, forming loops of sufficient size and depth to surround the cuspids and pass again to the lingual side, terminating on the disto-lingual side of the laterals.

* Jackson, Dental Cosmos, 1889, p. 855.

Fig. 442. To the spring was soldered a small-sized base-wire, formed to extend backward on either side, and anchored with a spring-clasp attachment to a bicuspid or molar. The front part of the appliance is best retained by cementing a collar with a groove

Fig. 442.

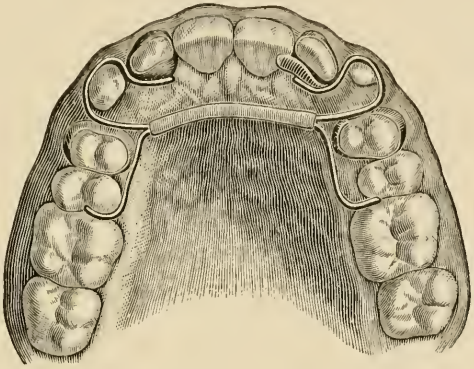

on its surface to one or more of the teeth on each side of the arch. The lateral incisors are generally chosen. Retaining collars are not required in all cases. After the collars are fitted to the teeth, the appliance is placed in position, and the collars are marked below its line of contact. They are then removed, and a small-sized wire is soldered to the marked portion to form a groove, after which the collars are cemented to place. Collars may be placed on the bicuspids or other teeth as needed. If the lateral incisors are to be moved a considerable distance, a collar with a spur projecting onto the lingual side of the central incisor should be cemented to each. When all of the incisors are to be moved outward, a thin bar can be shaped to the lingual side, and attached with solder to collars on the laterals, thus holding all of the incisors in the same relationship.

Similar appliances to those described may be used for making room and forcing prominent lower cuspids into line.

If the arch is not to be expanded laterally, or the position of the bicuspids changed, the first wire crossing the arch can be used alone in some cases by employing collars on the lateral incisors and first bicuspids; or two springs may be arranged to cross the arch, fastened in the centre with one end curved to encircle the cuspid, and the wires separated, acting as a spring to gain the space required.

In this case each of the loops that passed over the arch, when spread by bending, formed a spring which separated the lateral from the bicuspid, making room for the cuspid. The end of the loop was then bent upward, which made an additional spring that pressed on the labial side of the cuspid, and forced it into line as space was made for it. When it is found that any portion of the arch back of the cuspids requires to be expanded to assist in correcting the irregularity or to improve the occlusion, the arms of the base-wire can be bent outward.

In favorable cases it may not be necessary to anchor the ends of the base-wire with spring-clasp attachments. Curve the ends of the wire onto the grinding surface at the junction of the teeth at any place in the distal part of the arch that will not interfere with the occlusion; this will prevent the apparatus from pressing on the gum.

When there is insufficient space and it is found necessary to extract a bicuspid to give room for a prominent cuspid (see Fig. 443), cement

Fig. 443.

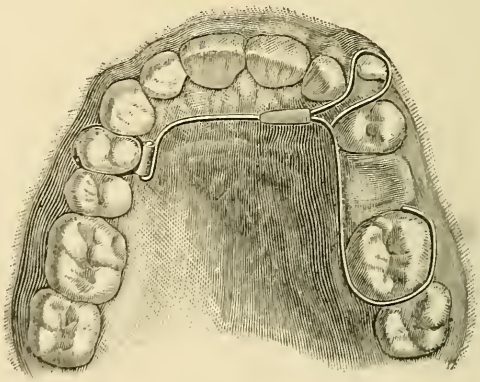

a collar with a tube to a bicuspid on the opposide side of the arch to hold one end of a base-wire, which follows the lingual curve, and anchor the other end by a spring-clasp attachment to a molar. Or the end of the base-wire may terminate in a curve to clasp the molar for anchorage.

If the first bicuspid and cuspid are to be moved backward into the space caused by the removal of the second bicuspid, make a loop in a spring-wire to cross the labial surface of the cuspid at the gum line, with the ends passing through the space to the lingual side. There

attach one end to the base-wire with solder, letting the other rest free on the mesial side of the bicuspid. The action of this moves the bicuspid backward; and at the same time the looped portion of the spring is to be curved to cause pressure on the cuspid to move it into line. When necessary the looped portion of the spring can be retained by cementing to one of the incisors a collar with a slight lug.

The inharmonious development of the teeth in young patients often misleads the inexperienced operator and prompts him to remove teeth that should be saved to complete the arch, make a good occlusion, and harmonize the features.

For lessening the prominent effect of the upper arch a molar or bicuspid is the most frequently removed, and a year or more later it is found that the lower jaw has lengthened and broadened without the corresponding development of the upper jaw. The upper lip

Fig. 444.

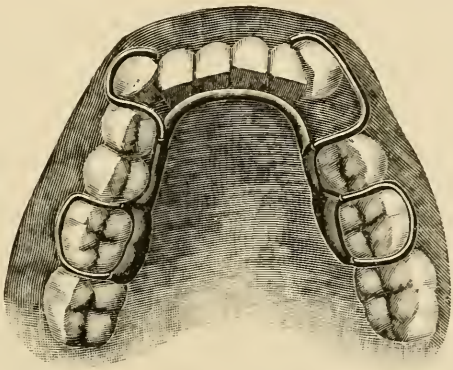

has consequently a sunken appearance that is difficult to remedy, and cannot be remedied except by extraction and contracting the size of the lower arch, or by the movement outward of the incisors and cuspids in the upper arch. But the latter method will not always correct the sunken appearance at the canine eminence and below the alea and lower part of the nose, which can only be improved by moving the roots of the teeth bodily outward.

Fig. 444 illustrates the case of Miss P., aged twelve years. The first bicuspid on each side of the upper arch had been removed by another practitioner to lessen the prominence, and later the lower arch had developed so that the cuspids had erupted outside of the circle, which increased the unpleasant expression of the features.

It was determined by measurement that the contraction of the lower arch by the width of one tooth would be sufficient to allow both cuspids to be brought into the circle. The first right bicuspid was therefore extracted, and an appliance made by arranging a strong lingual base-wire to the inner curve of the arch, anchored on either side with partial-clasps and a spring-clasp attachment. A spring-wire was soldered to the base-wire on the right side opposite the second bicuspid, passing through the space given by the removal of the first bicuspid. Then extending forward, the end terminated in a curve on the mesio-labial side of the cuspid, the action of which, by curving the end of the spring, moved the cuspid backward in the line of the arch, close to the second bicuspid.

A similar spring was attached to the base-wire opposite the second bicuspid on the left side. It extended forward to the mesial side of the first bicuspid, then over the arch in a curve at the junction of the cuspid with the bicuspid, and was formed into a partial loop to cross the cuspid at the gum line. The action of the spring moved the cuspid into line, and at the same time moved the four incisors laterally towards the right, permitting all of the teeth to close back of those in the upper arch.

The deviation from the median line, caused by moving the incisors laterally in the lower arch, is not so noticeable as in the upper.

If the teeth are much exposed to view, they should not be moved laterally without first examining the features to see whether the movement would be detrimental to the expression.

Fig. 445.

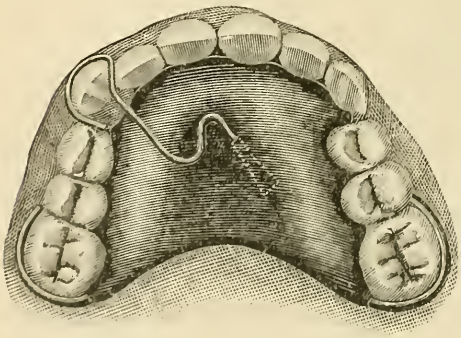

Regulating springs of any form described in this chapter can be used in connection with a well-anchored plate.

Fig. 445 illustrates an appliance for broadening the space for a prominent cuspid and moving it into line. A plate is formed covering the palatine portion of the arch, anchored with a suction in the centre or a wire-clasp around one or more of the teeth on either side.

The spring for moving the prominent cuspid is bent into the

form of a loop to cross the labial side of it at the gum line. The ends are shaped to pass through the space between the adjoining teeth, one end terminating at the edge of the plate and the other attached near the centre in the usual manner. If the tooth is to be moved a considerable distance, the part of the spring that rests over the plate is formed into one or two U-shaped loops. When the cuspid is to be moved but a short distance, the arm of the spring should be left straight and fastened in the rubber near the edge of the plate.

This form of spring can be used to move into line one or more prominent upper incisors, when the occlusion will permit, it being properly anchored in the plate, following its contour, with the loop shaped to extend over the incisive edge at the junction of the teeth to rest on the labial side, near the gum, as shown in Figs. 217 and 223.

When first molars are extracted to make space for moving prominent cuspids backward in the line of the arch, a plate with springs, as shown in Fig. 446, may be employed. The plate is anchored with

Fig. 446.

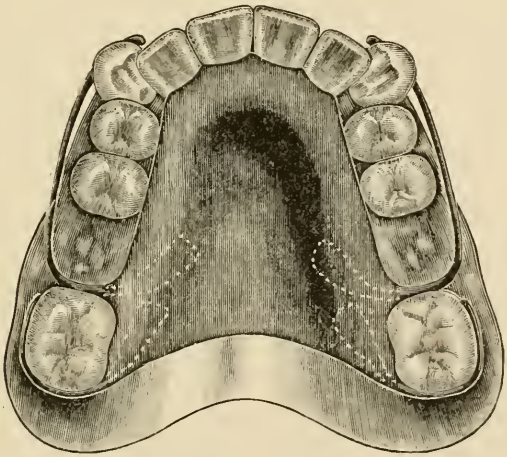

wire-clasps passing around the second molars, the anterior part resting in contact with the incisors and the curve of the arch. Rather large finger-springs are attached in the plate next the second molars, and shaped so as to extend forward on the buccal side to rest on the mesio-labial surface of the cuspids. Additional pressure is got by bending the ends of the springs towards the plate, wedging the cuspids to place and forcing the bicuspids backward.

Fig. 447 illustrates the case of a lady aged twenty-five years, in which a modified split plate was employed for expanding the upper arch, it being much too narrow to articulate with the lower, and at

Fig. 447.

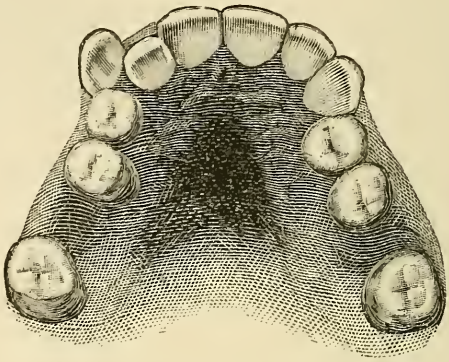

the same time moving into line a very prominent cuspid, there being insufficient space.

Generally the first bicuspid is extracted in such a case, but as the bicuspids were of good quality and the first molar decayed, the latter was extracted, and the bicuspids were moved backward in the line of the arch to give the necessary space. The plate was made to cover the palatine arch (Fig. 448), anchored on the left side with

Fig. 448.

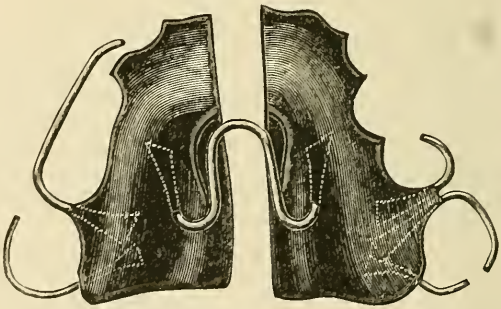

wire-clasps extending around a molar and a second bicuspid. On the right side it was anchored by a wire-clasp passing around the second molar, and by a long finger-spring provided for moving the cuspid and bicuspids backward. The spring was shaped to extend from the plate through the space next to the second molar, and to reach

forward to rest on the mesio-labial surface of the cuspid, where it terminated in the form of a slight hook.

The action of the spring was caused by curving the end nearer to the plate from time to time, which moved the cuspid and bicuspids backward into line. At the same time, the U-shaped spring that joined the lateral halves was separated to expand the arch. When this was sufficiently expanded, and the teeth were in position, they were retained by cementing to the cuspid a gold collar with a spur on the lingual side, reaching on to the adjoining teeth (Fig. 502), and a thin rubber plate was inserted to maintain the width of the arch.

Elevation of Cuspids.—Fig. 449 shows an appliance for drawing into position a cuspid that is tardy in its development from overcrowding or other cause, or pointing in a wrong direction.

When there is not room to admit the cuspid without crowding the

Fig. 449.

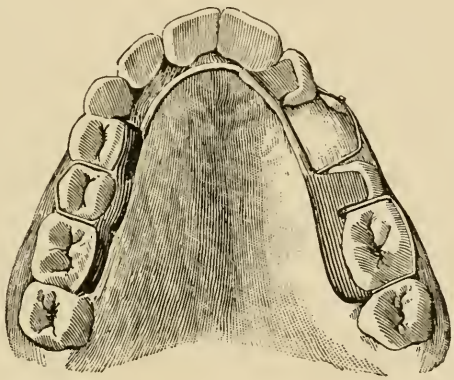

incisors out of position, the arch should be expanded, or the first bicuspid extracted, but the bicuspid should not be removed without first making accurate measurements, taking into consideration the prospective development of the arch, the occlusion, etc. In the case illustrated, the first bicuspid was extracted, the appliance was constructed with a lingual base-wire, anchored by partial-clasps and a spring-clasp attachment to one or more teeth on each side of the arch. Pieces of plate-metal were shaped to rest on the lingual prominences of the teeth, and soldered to the base-wire, to prevent it from pressing on the gum. When required, the metals can be extended in the form of a hook over the edges of the incisors and

on to the grinding surface of the bicuspids or molars. Occasionally wire is used for the latter purpose.

A spring-wire was attached to the partial-clasp by the base-wire, shaped to pass through the space next to the second bicuspid, and to extend forward in a gentle curve, terminating on the labial surface of the cuspid to be moved. When the cuspid is sufficiently advanced in the process of eruption, a collar with a pin or hook in suitable position to hold the end of the spring may be cemented to it. Or if the tooth is not sufficiently erupted, the spring can be anchored by a small metal pin, screwed or cemented into a pit, drilled as near the neck of the tooth as practicable, or by attaching a small eyelet or hook in the same manner to the point of the tooth, which is preferable if the labial side is covered with integument.

When there is sufficient space for the admission of the cuspid without the removal of an adjoining tooth, the spring may be attached to the base-wire, passing over the arch at the junction of the bicuspids, and formed to extend forward in the manner described.

If the point or the labial face of the cuspid is not sufficiently exposed for operation, the soft tissue may be forced back by pressing sterilized cotton or cord between it and the tooth daily for some time, or the tissue dressed away. If the cuspid is not exposed, the soft tissue may be removed with a curved bistoury, and, when necessary, remove some of the alveolar process with an engine bur. When no ordinary means of attachment to the tooth can be made, often the end of a spring can be shaped to hook over the cuspid for drawing it downward or outward until a collar with a pin can be applied. Undue force is objectionable, as too rapid movement of the tooth endangers the life of the pulp.

In changing the adjustment of the spring, it should be bent to rest a little below the metal pin inserted in the tooth and then sprung over the pin into position. In this manner the distance the tooth will be moved by the spring can always be determined.

It is unusual for the cuspid to point backward and rest opposite the buccal surface of the bicuspids. When found in that position, or when the cuspid is erupting inside of the line of the arch, the base-wire can be shaped in suitable form and anchored as described, the spring being attached and bent into the required shape.

A method of elevating an improperly erupted cuspid, as presented

by Dr. H. H. Jackson, is as follows (see Fig. 450): A thin collar with a long metal tube soldered to the buccal side is cemented to a first molar, the tube projecting forward at the gum line to the junction of the bicuspids, where a T is attached to assist in supporting

Fig. 450.

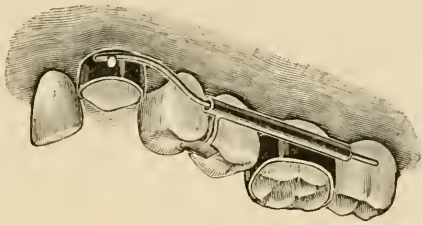

the end of the tube. The T is made by soldering a short narrow piece of plate-metal to the curved end of a wire shaped to hook over the grinding surface to engage with the buccal cusps of the bicuspids. A collar with a pin on the labial side is cemented to the cuspid, and the necessary force for its elevation is got by passing a small spring-wire into the tube and springing it over the pin on the collar, changing the shape as desired for causing additional force. When supplemental force is required for the elevation of a cuspid, an apparatus as illustrated in Fig. 357 can be employed. For other means of elevating the cuspids, see Chapter XVI., Incisors, to elevate.

Depression of Cuspids.—The depression of cuspids is not often required, but when necessary, apparatus used for the depression of the incisors is applicable. (See Chapter XV., Incisors, to depress.)

Rotation of Cuspids.—Apparatus used for the rotation of incisors is applicable for the rotation of the cuspids, although each part should be made stronger as more force is required. Owing to the shape of the crown of the cuspid, care should be exercised in the adjustment of the collar, making it fit well at the neck and strongly cementing it to prevent it becoming displaced when force is applied. In cementing, the end of the collar should be kept covered, to force the cement forward with it.

CHAPTER XXIII

BICUSPIDS, TO MOVE OUTWARD OR IN A BUCCAL DIRECTION

Malposition of the bicuspids, like malposition of the incisors and cuspids, is more easily corrected when the arch is not overcrowded. Unfortunately, the latter condition usually accompanies the irregularity. Its correction generally necessitates the use of an appliance that will enlarge the circle of the arch and at the same time give sufficient force to move into line those teeth that are out of position.

The overcrowded condition of the bicuspids is often caused by premature extraction of the deciduous molars, either on account of the crowns breaking down from excessive decay, or their injudicious removal resorted to to relieve pain.

The permanent molar teeth have a tendency to move forward in the line of the arch when not obstructed. If one of the deciduous molars is removed before the crown of the relative bicuspid has reached the margin of the gum in its development, the space is encroached upon by the gradual movement of the molars, and often becomes too narrow to admit the bicuspid in a correct line. Under such conditions, the bicuspid may force its way to proper position, but occasionally it is deflected to the inner or outer side of the arch; or it becomes rotated or impacted, and if not liberated by broadening the space, it may remain in an impacted condition.

Another common cause for rotation or deflection of the bicuspids, is the presence of broken-down carious roots of a deciduous molar that has lost its crown from caries. After losing vitality, the roots are absorbed slowly, and act as an obstruction to the bicuspid in its regular eruption.

The anterior posterior width of the crown of a deciduous molar is broader, and occupies more space than is required for a bicuspid when erupted, and therefore, if the deciduous molars are retained, and the bicuspids are erupted in their natural order, they will have ample room to take a correct position, and will be likely to do so if not interfered with by some hereditary or acquired influence.

When the right upper bicuspid has erupted inside of the circle of the arch, and the space between the cuspid and the second bicuspid is sufficient, or nearly so, to admit it (Fig. 451), an efficient device for moving it outward is made by anchoring on the opposite side of the arch the end of a lingual spring base-wire with partial-clasps and spring-clasp attachments to the molars and bicuspids. The other end of the base-wire is retained by a spring-clasp attachment passing over the tooth to be moved. Force is applied by removing the apparatus and bending outward the sides of the base-wire. This appliance is also suitable for moving outward a second bicuspid.

Fig. 451.

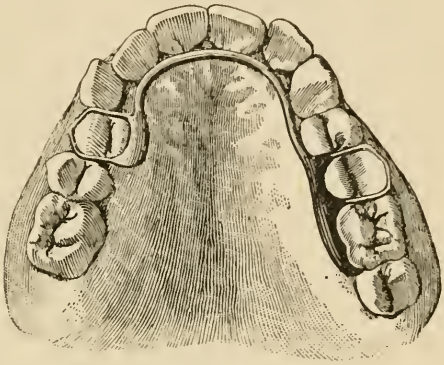

When both second bicuspids of the upper or lower arch are erupted inside of the normal line, with sufficient space for one of them, as the one on the left, and insufficient space for the one on the right between the adjoining teeth, their position can be corrected by an appliance similar to the one shown in Fig. 452. It is made with a lingual spring base-wire, having one end anchored by a spring-clasp attachment to the bicuspid on the left side, and the other end to the right bicuspid by a partial-clasp and a spring-wire about No. 22 gauge. The spring is formed to cross the partial-clasp on the lingual side of the bicuspid near the gum line, with the ends extending either side, up and across the grinding surface at the junction of the adjoining teeth, similar to the wires of a spring-clasp. The ends are bent sharply again towards the gum, then separated, forming a curve so that they will rest on

Fig. 452.

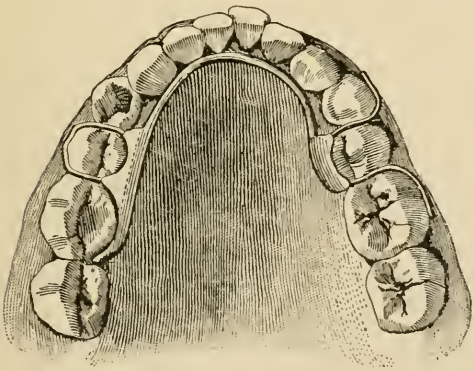

the buccal side of the adjoining teeth. All of the metals are joined by soldering, completing the appliance. It will be observed that by removing the appliance, and separating the sides of the spring-wire last described, the tendency will be to increase the space between the first bicuspid and first molar, while at the same time the ends of the spring are bent backward to cause pressure on the adjoining teeth, which assists the action of the base-wire in moving the right bicuspid outward to proper position.

In this case, the bicuspid on the left moved more rapidly than the one on the right, as it was not so crowded in the arch, and when it had taken a proper position, the anchorage was made to include the first molar and first bicuspid.

Fig. 453 illustrates a simple device that is applicable for moving outward a crowded bicuspid when only a moderate force is required,

Fig. 453.

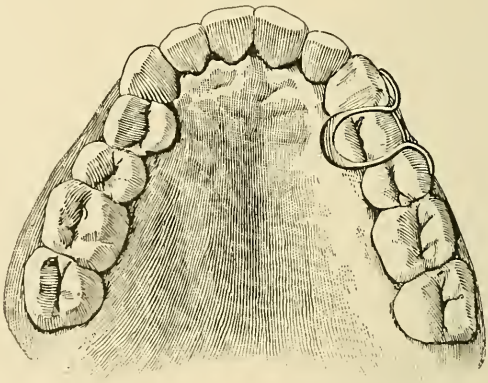

first broadening the space for its movement. It is made like the spring previously described. A partial-clasp is fitted to the bicuspid to be moved. A small spring-wire is used for a spring-clasp for anchorage, with a slightly larger spring shaped to extend from the partial-clasp over the arch either side of the bicuspid, just above the spring-clasp, its ends bent outward to rest on the buccal side of the adjoining teeth near the gum. The arms of the spring are bent outward to broaden the space, and the ends are curved backward to give force for moving the bicuspid into position.

The wires should never pass between the teeth from the lingual to the buccal side, but always be arranged to pass over at the grinding surface and junction of the teeth.

Generally the device is well retained, and is effective without the use of the spring-clasp attachment. The principle of the appliance is useful in many combinations.

In Fig. 454 is shown the form of an appliance that was utilized in the case of Master B., aged fourteen years, to correct the position

Fig. 454.

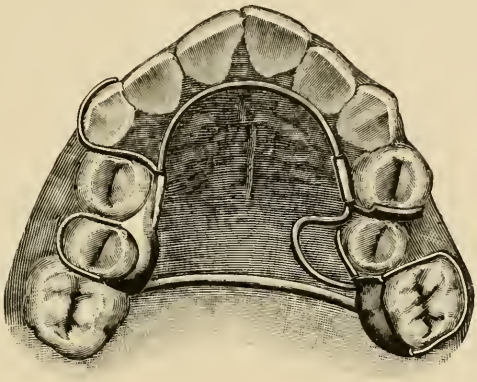

of a second left upper bicuspid that was erupting considerably inside of the arch with insufficient space, and at the same time forcing into line a prominent cuspid. The patient lived many miles away, and could make visits only at long and stated intervals. The teeth were large and firmly set in the process. A palatine base-wire was anchored with spring-clasp attachments to the first left molar and second right bicuspid. A lingual spring base-wire was formed to the inner curve of the arch, with a loop opposite the bicuspid to be moved; the ends were soldered to the partial-clasps with the palatine base-wire, the end of the loop pointing towards the median line of the arch. At the same time a finger-spring was attached to the partial-clasp and shaped to project forward in a curve resting near the gum on the lingual side of the bicuspid. Action was caused by opening the loop in the lingual base-wire for broadening the space, and bending outward the finger-spring to move the bicuspid. The position of the prominent cuspid was corrected with a spring attached to the partial-clasp and base-wire, extending in front of the first bicuspid to the buccal side, and bent forward to cross the cuspid at the gum line, with the end curved to extend over the arch and rest on the disto-lingual side of the lateral incisor. Force was caused by bending the looped portion inward or nearer to the base-wire,

and shaping the end to press on the lateral incisor for increasing the space.

The device shown in Fig. 455 has been used in favorable cases for drawing into line a bicuspid that was inside of the arch, especially when there was sufficient space. A spring-wire is bent in the form of a continuous spring-clasp, surrounding the irregular tooth and an adjoining one on each side, resting on the buccal and lingual faces near the gum, with each end of the wire terminating upon the tooth to be moved in the form of a separate spring.

Fig. 455.

The appliance is more firmly anchored when partial-clasps are used (see Fig. 464).

Many appliances described in other parts of this work are applicable for moving outward the bicuspids (see Figs. 128–130).

An appliance used for moving outward the first upper bicuspids for Miss T., aged fourteen years, is shown in Fig. 456. A lingual spring base-wire was formed to the inner curve of the arch, with the

Fig. 456.

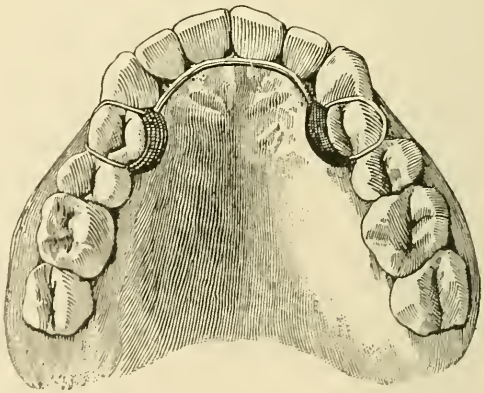

ends anchored with spring-clasp attachments to the teeth to be moved. The action of the base-wire was caused by straightening the curve from time to time. These teeth, being closely wedged between the adjoining ones, and their outer cusps articulating deeply inside of the cusps of the lower teeth, were especially hard to move. However, the regulating was completed in a moderate time.

The appliance, with the base-wire in this form, is applicable for moving outward bicuspids in the lower arch. If, by measurement,

it is found that the length of the base-wire when straightened will not be sufficient to correct the position of the irregular teeth, a loop may be made in the centre or arranged as illustrated in Fig. 457. The latter shape is usually preferable owing to its greater elasticity

Fig. 457.

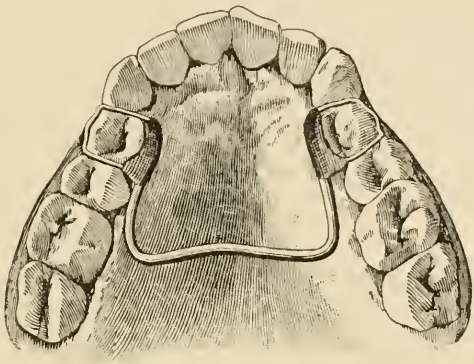

and ease of adjustment. A palatine spring base-wire is arranged to cross the arch near the molars, the ends extending forward like arms and anchored with spring-clasp attachments to the teeth to be moved.

A base-wire in this form does not interfere with the tongue in pronunciation; the arms are longer, giving more action, and conse-

Fig. 458.

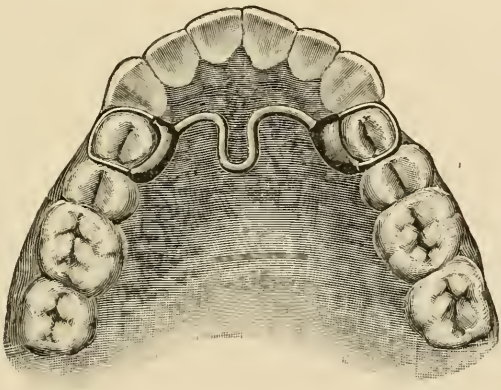

quently the appliance is more easily managed and does not require to be adjusted as often as the one previously described.

Fig. 458 shows another appliance that is convenient for moving outward two upper bicuspids. A palatine spring base-wire, with a

U-shaped loop at the median line, is anchored by spring-clasp attachments over the teeth to be moved. The base-wire does not interfere with the tongue in pronunciation when made to cross the arch as far back as the line of the bicuspids. The action is readily controlled by spreading the loop.

If one of the bicuspids is moved to position before the other, a partial-clasp should be fitted to one or more of the adjoining teeth and soldered to the appliance to assist the anchorage on that side.

The appliance represented in Fig. 459 was used in the case of a physician, aged twenty-eight years, for moving outward the left

Fig. 459.

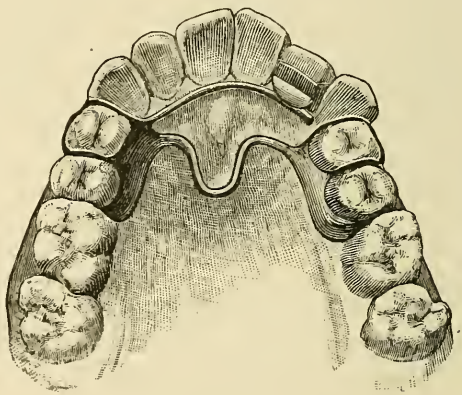

upper bicuspids and a lateral incisor that had a lingual occlusion, the cuspid being in good position. The appliance was made with a palatine spring base-wire, No. 14 gauge, with a loop formed in the centre about three-eighths of an inch long, opening towards the front. The ends of the base-wire were bent nearly to a right angle, and crossed partial-clasps, to which it was soldered, with a spring-clasp attachment over one of the bicuspids on each side for anchorage. At the same time a finger-spring was soldered in the anchorage on the right side and made to reach to the distal face of the lateral, following the lingual curve, where the spring passed under a lug on a collar to hold it in position.

The incisor was moved by bending outward the end of the finger-spring, and the loop in the spring base-wire was opened from time to time to move the bicuspids in a buccal direction. After the teeth were in position the same appliance was used to retain them. Gen-

erally with this form of device the anchorage should include more teeth on the side that is not to be moved.

Often the sides of the arch are flattened, with the outer cusps of the first or second upper bicuspids closing inside of the line of the cusps of the lower ones, and the anterior part of the arch prominent. In cases like this it is desirable that the bicuspids be moved outward and the front part of the arch forced inward to permit the teeth to articulate more perfectly with the lower ones. An appliance utilized for this purpose will be seen in Fig. 460. It is made with a

Fig. 460.

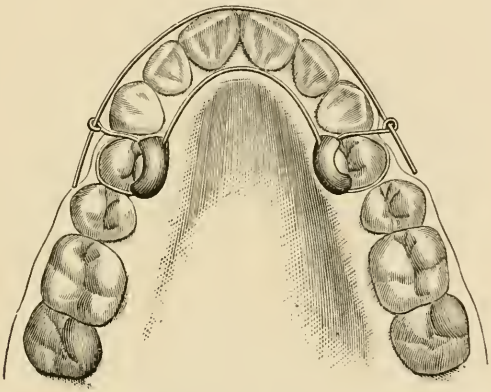

lingual spring base-wire, anchored with spring-clasp attachments to the bicuspids to be moved. A small wire is attached to the partial-clasp, one on each side of the arch, and made to extend to the buccal side accompanying the spring-clasp, with the end bent into the form of a small eyelet or hook located about midway between the grinding surface and the gum. A straight spring-wire is bent backward across the front of the prominent incisors and passed through the hooks. The tendency of the spring to straighten assists the base-wire in moving the bicuspids outward, and at the same time causes pressure on the labial side of the incisors, moving them into the desired curve. The teeth were retained with a palatine plate, as shown in Fig. 494, having a small-sized wire of a semicircular shape passing in front of the incisors and back to the first bicuspids, where U-shaped loops were formed in the wire (*a*, *a*), the ends passing over the arch at the junction of the teeth and extending into the plate.

In some cases a metal retainer (Fig. 486) will be more comfortable to the patient. It is easily made and efficacious.

A labio-buccal base-wire can be used independently for moving one or more bicuspids and molars outward. Anchor it by spring-clasp attachments, or by continuous spring-clasps, separating the ends of the base-wire for getting force.

For young patients, when both the upper and lower bicuspids require to be moved outward and the teeth occlude well, an appli-

Fig. 461.

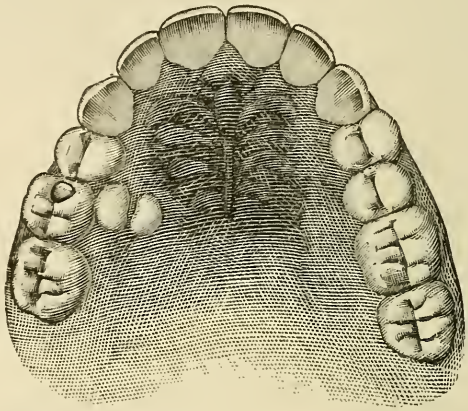

ance used in the lower arch, if the teeth are moved slowly, will sometimes move the teeth of the upper arch.

Fig. 461 shows an irregularity in the case of a girl aged twelve years that was corrected with finger-pressure. The second right upper bicuspid was erupting inside of the line of the arch, the deciduons molar still being retained.

The molar was extracted and the patient instructed to press outward on the side of the bicuspid several times a day, which gradually moved it into line.

CHAPTER XXIV

BICUSPIDS, TO MOVE INWARD OR IN A LINGUAL DIRECTION

With ordinary methods, where the teeth are crowded, it is more difficult to move a prominent bicuspid inward than to move an instanding bicuspid outward, the direction of the required force for moving a bicuspid inward being such as to tend to lessen rather than to increase the size of the arch, wedging the teeth, and in some instances at the same time forcing the adjoining ones towards the median line. For this purpose an appliance can usually be devised to act from the inner side of the arch. It is less conspicuous and more comfortable to the patient than one arranged on the outer side.

Fig. 462 shows an appliance for moving into line a prominent bicuspid that is not overcrowded. It is made by shaping a spring-

Fig. 462.

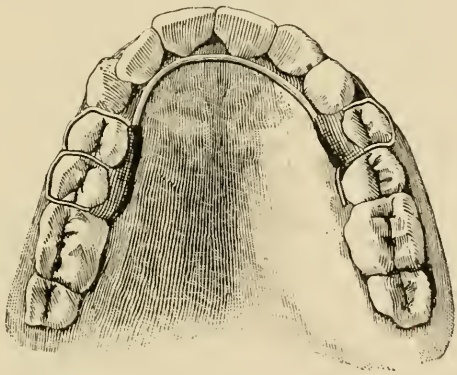

clasp attachment to the tooth, to which is soldered the end of a heavy lingual spring base-wise, arranged near the gum, with the other end of the base-wire strongly anchored to several teeth on the opposite side of the arch. The irregular tooth is moved inward by bending together the ends of the base-wire slightly from time to time.

A small-sized spring-wire can be attached with the end of the base-wire to the partial-clasp on the tooth to be moved. The spring

is shaped to extend backward and rest on the lingual side of an adjoining tooth, being bent outward when required to assist the action of the base-wire.

When the teeth in the arch are crowded (Fig. 463) an appliance for increasing the space and moving a prominent bicuspid into position may be made with a lingual base-wire properly anchored. Solder to it, opposite the tooth to be moved, a spring-wire, about No. 12 gauge or a little larger, bent twice at right angles, the width between the parallel arms being equal to the diameter antero-posteriorly of the tooth out of position, and the ends shaped to extend over the arch on either side of it to rest on the buccal face near the gum. There is a space between the base-wire and the tooth that is to be moved, while the base-wire is in contact with the lingual faces of the adjoining teeth. The arms of the spring that extend from the base-wire should be formed to cross the space near the gum line, and curved to pass over the grinding surface at the junction of the teeth. It will be seen that by separating the arms slightly by bending, and curving the ends nearer the base-wire, the tendency would be to increase the space for the bicuspid, and at the same time to apply force on the buccal face for moving it into proper line. One spring extending over the arch in this manner is sometimes sufficient for wedging the tooth into place.

Fig. 463.

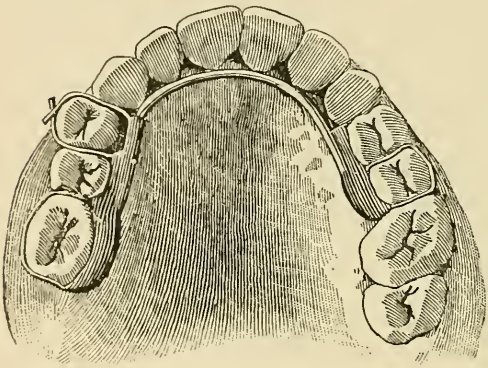

Fig. 464.

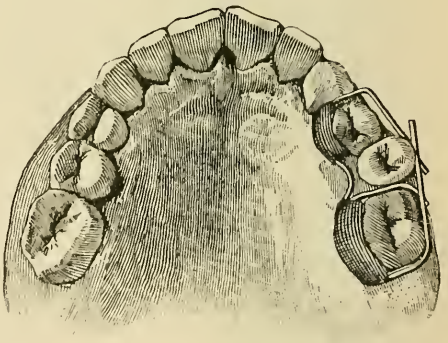

Fig. 464 shows a device used for moving into position a bicuspid erupting outside of the normal line.

It is made by arranging partial-clasps on the lingual surface of the teeth either side of the bicuspid. A rather stiff spring-wire is bent into a slight loop, crossing the partial-clasps, to which it is finally soldered and shaped to pass over the arch to surround the adjoining teeth loosely in the form of a continuous spring-clasp, with the ends terminating on the buccal side of the tooth to be moved. The space is gradually increased by straightening the looped portion of the wire a little at a time, and bending the free ends of the spring inward to cause pressure for moving the bicuspid. When the device is not well retained a spring-clasp can be added.

An appliance arranged on the outside of the arch as seen in Fig. 465 can be utilized in some cases for moving into line a prominent bicuspid on one or both sides, whether fully or partially erupted.

Fig. 465.

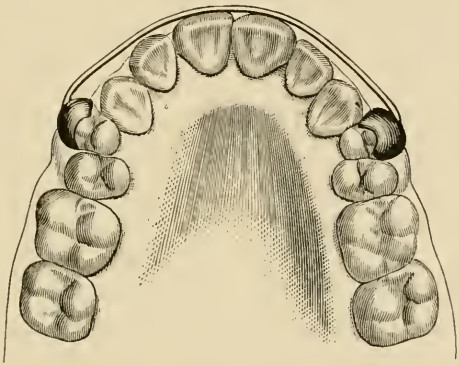

It is made by fitting partial-clasps to the buccal surface of the teeth to be moved, extending the metal well towards the neck and distal sides. A labio-buccal spring base-wire is shaped to follow the outline of the teeth, not fitting them too closely, and extended to the partial-clasps, to which it is soldered. The appliance is removed from time to time, and the clasping ends of the spring bent towards each other to give the force required. A U-shaped loop in the base-wire sometimes proves of advantage. The appliance has been used for general contraction of the arch by arranging partial-clasps and spring-clasp attachments on the teeth as required.

A few practitioners are still using and recommending cord ligatures and rubber bands for moving irregular teeth. A convenient device for holding them in position to get the required force for

moving bicuspids is made as shown in Fig. 466. When a second right upper bicuspid is too prominent (*a*), a spring-clasp attachment can be formed to the first bicuspid, with the partial-clasp arranged on the lingual side. A small straight bar of wire is soldered to it,

Fig. 466.

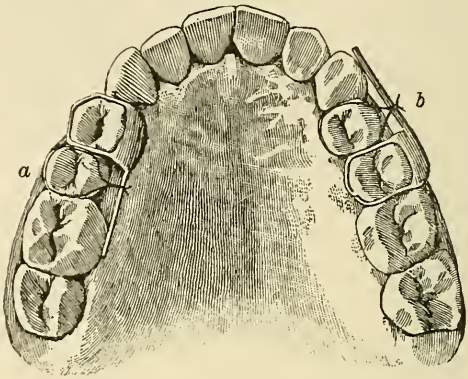

extending backward to rest on the lingual side of the first molar. A rubber band or ligature is then placed around the bar and the bicuspid to be moved.

When the first left bicuspid is inside of the arch (*b*), it can be moved outward by a similar appliance, forming a spring-clasp attachment to the second left bicuspid, with a partial-clasp arranged on the buccal side. A bar shaped to extend to the labial side of the cuspid is then soldered to it, and a rubber band or ligature passed around the bar and the bicuspid to be moved.

CHAPTER XXV

BICUSPIDS, TO MOVE BACKWARD IN THE LINE OF THE ARCH

The cases that most often require the bicuspids to be moved backward in the line of the arch, are those where a molar or one of the bicuspids have been removed to relieve a crowded condition.

Occasionally the removal of a first or second bicuspid on one or both sides of the arch is required to cause space for a prominent cuspid, or prominent or overcrowded incisors.

For such conditions, when expansion of the arch is not practicable, the writer usually recommends the extraction of the first bicuspid rather than the second, as the second bicuspid assists the first molar in anchorage. Its preservation is especially necessary where the regulation is attempted before the eruption of the second permanent molars. After the eruption of the second molars, the anchorage would consist of the second bicuspids, the first and second molars, thus having three teeth on either side to sustain the apparatus in moving inward the six front teeth. Even with the assistance of the second bicuspids, the teeth used for anchorage are liable to be moved forward when force is brought to bear for moving all of the front teeth at one time. The anchorage can be further strengthened by the adoption of a vulcanite plate covering the roof of the mouth, its added value being measured by the depth of the arch.

The matter of choice as to the extraction of one of the bicuspids depends much upon their position, occlusion, shape, size, and structure. It very often occurs that the second bicuspid is smaller than the first, or that its structure is not equally good. In such case, it is wise to retain the first bicuspid, even though the regulating cannot be accomplished as readily.

Where teeth are to be extracted for the accommodation of others, they should not be removed until just before inserting the appliance for the correction of the irregularity. This is especially important with the adult, as, owing to the added density of the alveolar process, it is not easily absorbed. But if the regulating of the adjoining tooth is begun before the bone has formed in the socket of the tooth extracted,

the root can be moved to its new position more readily, and is less liable to return. The recent extraction of bicuspids is advantageous in moving cuspids, either when they are too prominent, or when all of the front teeth are to be moved backward into line. When the second bicuspid is extracted to give room for a prominent cuspid, the first bicuspid can be moved backward by persistent wedging, or by the force that is employed for moving the cuspid.

Fig. 467 illustrates the case of a girl aged fourteen years. The upper incisors were much too prominent, and closed in front of the

Fig. 467.

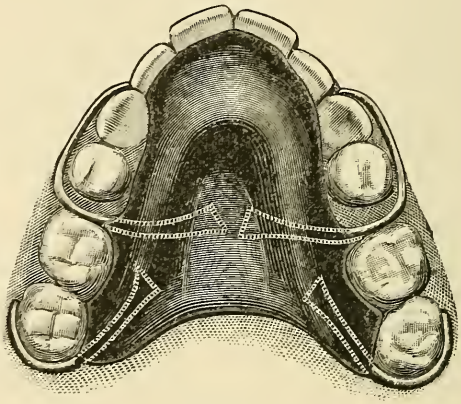

lower lip, the lower incisors biting against the gum considerably back of them. The case was referred to the writer under the conditions illustrated. The second bicuspids had been removed with the expectation that the incisors, cuspids, and first bicuspids would move backward in the arch; but instead, the molars, following the usual tendency, moved forward, encroaching upon the space caused by the removal of the second bicuspids. As anchorage to the first and second molars would not be sufficient to move the first bicuspids, cuspids, and incisors at one time, the regulation was divided into two operations, first moving the cuspids and bicuspids backward. By this plan the anchorage of the appliance could be improved by means of a vulcanite plate, covering the roof of the mouth, the front part of it resting against the anterior palatine arch and the lingual side of the incisors; and the distal part retained by wire-clasps around the second molars. The plate was firmly anchored, and at the same time the front part, being somewhat

thickened, caused the lower incisors to be depressed in their sockets through occlusion. For moving the bicuspids and cuspids, a spring-wire was extended from the plate outward on each side, passing through the space close in front of the first molar, with the end of the spring curved forward and shaped to rest on the mesio-labial surface of the cuspid. The springs were shaped to pass through the space near the grinding surface of the teeth rather than near the gum, to allow the first bicuspids to be moved backward in close contact with the molars.

The edge of the plate opposite the cuspids and first bicuspids was made straight and smooth to permit their backward movement. Action of the springs was caused by bending them in proper curve towards the plate from time to time, the ends being made shorter when required by dressing with a corundum stone. When these teeth were moved backward into position, similar springs, as shown in Fig. 242, were extended from the plate in front of the cuspids to the labial side of the incisors for moving them inward. But for this purpose it is usually better to construct an entirely new appliance.

The cuspids and first bicuspids had not become firm in their new position, and it was not considered advisable to depend on the anchorage of the plate alone for moving the incisors. Accordingly supplemental force was applied by a cross-bar (Fig. 69) worn at night, and the regulating was completed in a limited time.

Fig. 468 shows an appliance for correcting the position of a left lower cuspid that was much too prominent, with insufficient space, and closing in front of the teeth of the upper arch. The occlusion would not permit the enlargement of the arch, and therefore the extraction of one of the teeth was required to give space to allow the cuspid to take a correct position. Usually when extraction is necessary, if the first permanent molar is of good structure, the first or second bicuspid should be removed, preserving the one that is found on careful examination to articulate the better and more strongly when it and the cuspid are moved backward into position.

In this case the molar was defective. It was extracted, and the bicuspids were moved backward. An appliance was made by forming a rigid lingual base-wire to the inner curve of the arch, fitting well to the incisor teeth, following the line of the gum to the second molars. For anchorage, carefully fitted partial-clasps were arranged

on all of the teeth not to be moved, with a spring-clasp attachment over the second left molar and a wire-clasp passing back of it, and a spring-clasp attachment over the first bicuspid and first molar on the right side, with a wire-clasp passing around the second molar. For moving the bicuspids backward, they were first wedged a little. A double spring was attached to the base-wire opposite the first bicuspid. The spring was bent twice at right angles, with a little more space between the parallel arms than the antero-posterior measurement of the bicuspid. The ends were curved downward and again towards the base-wire as shown at *c*, *d*. Force was caused for moving the teeth by bending backward the ends of the arms from time to time. When teeth are to be moved some distance with this form of spring, it can be moved backward on the base-wire when required and resoldered. For this purpose an adjustable attachment has been devised by using a square base-wire, fitting to it a tube to which the spring is attached and held with a ratchet. The cuspid was moved with a spring attached to the base-wire, passing over the arch at the junction with the lateral incisor, where it was bent into a U-shaped loop, extending across the face of the cuspid, with the end terminating on the mesio-labial surface near the gum, as shown at *a*, *b*; force being got by bending backward the end of the spring.

In Fig. 469 are shown the features of Miss M., aged fourteen years, a case of double protrusion regulated in 1896.

The teeth of both the upper and lower arch were overcrowded, the incisors being much too prominent, with the upper incisors rotated and resting on the lower lip, giving the mouth a full and unpleasant expression. Each arch was sufficiently broad, and expansion for lessening the anterior prominence was not practical. It was therefore necessary to extract a tooth on either side of both the upper and lower arches. It was found from general measurement, and from the anterior-posterior width of the bicuspids, that the removal of either the first or the second would not furnish sufficient space for the correction of the irregularity. Again, the structure of the bicuspids was good, while each of the first molars had several large fillings reaching near the pulp, therefore the interest of the patient demanded the preservation of the bicuspids and the removal of the defective teeth, even though it would add much to the work of regulation. The upper sixth year molars were first extracted

Fig. 468.

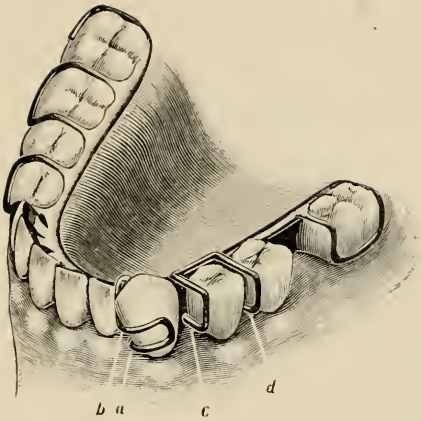

Fig. 469.

and wedges immediately inserted back of the cuspids, giving space to admit springs for the distal movement of the bicuspids.

An appliance was made with a palatine vulcanite plate, anchored with wire-clasps extending from the distal part of it around each of

Fig. 470.

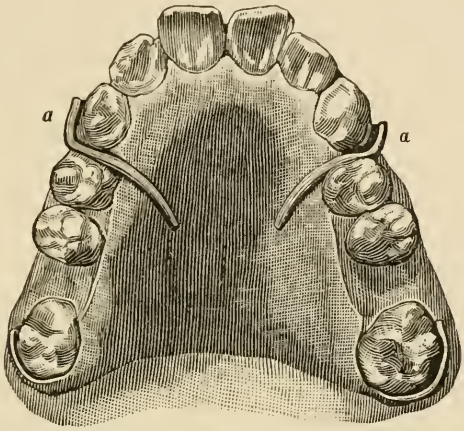

the second molars. The front part of the plate rested in contact with the lingual side of the incisors and cuspids, with short pieces of wire projecting from the plate into the interdental spaces back of the cuspids. Springs with the ends flattened were attached in the rubber near the centre of the plate, on a line with the junction of the bicuspids; the free ends were bent forward in a gentle curvé to pass through the space caused by the wedging to the buccal side, where they were bent forward at a right angle, leaving a little space between the end and the cuspid (Fig. 470, *a*, *a*). Force was given by bending the ends of the springs backward from time to time. It was foreseen

Fig. 471.

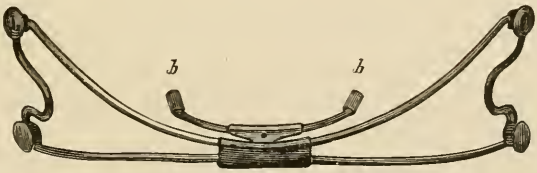

that the anchorage was liable to prove insufficient, and supplemental force with a cross-bar was employed. A large wire was shaped in a semicircle to conform to the anterior curve of the arch long enough to reach from the ends of the springs *a*, *a*, and to leave a

considerable space in front of the incisors. A thin piece of plate-metal was then wound around either end of the wire, broad enough to project about three-sixteenths of an inch, and soldered, forming cylinders (Fig. 471, *b*, *b*) to pass over the projecting ends of the springs *a*, *a*. The centre of the wire was hinged to a double cross-bar by bending around and soldering to each a suitably shaped piece of plate-metal, with the ends of one projecting between the ends of the other and held by a pin. The apparatus when adjusted appeared as seen in Fig. 472. It was worn at night, and when convenient during the day. The tension of the elastic bands from the cap imparted additional force to the springs *a*, *a*, causing the rapid backward movement of the bicuspids bodily, closing the spaces caused by the extraction of the first molars without any apparent change in the position of the anchorage teeth. The result is shown in Fig. 473.

This case illustrates the advantage in not extracting teeth that are to provide space until the time of the commencement of the regulation. There being a comparatively open socket, the teeth are moved more rapidly and are more likely to be moved bodily in the direction desired.

The upper incisors and cuspids were moved backward with a similar palatine plate anchored with wire-clasps. Springs were attached in the vulcanite, one on either side, shaped to extend through the space in front of the first bicuspids and curved forward to rest on the mesial surface of the incisors, terminating a little beyond the median line, one above the other (Fig. 242). With the springs in this form the bicuspids were retained in position. When they were sufficiently firm the anterior edge of the plate was dressed away at regular intervals, and the springs curved to give slight pressure on the incisors for moving them and the cuspids backward. The force was effective without the application of a cross-bar, and did not change the position of the teeth used for anchorage; but generally with these conditions a cross-bar should be employed. At the same time an apparatus was applied for correcting the position of the lower teeth, first forcing bodily backward the bicuspids. The first molars were extracted, and a wedge was applied back of each of the cuspids to get space for the springs of an apparatus (Fig. 474). A strong lingual base-wire was anchored to the second molars, cuspids, and incisors in the usual manner, excepting that the anchorage back of the cuspids consisted of a curved wire extending from the

Fig. 472.

base-wire *c*, *c*. A U-shaped double spring, *d*, *d*, was attached to the base-wire on each side of the arch near the molars, extending forward in a curve to exert force on the mesial surfaces of the bicuspids from the lingual and buccal sides, the spring being shaped to allow for metal caps which were subsequently cemented to the bicuspids. Action of the springs was caused by bending the ends towards one another, shortening them as required. When the position or shape of the tooth is such that the action of the springs tend to elevate it, the springs should be supported, either by having the end of one or both left sufficiently long to curve slightly on to the grinding surface, or by a suitably shaped clip soldered to the end of one of them or to the metal caps for that purpose.

Fig. 473.

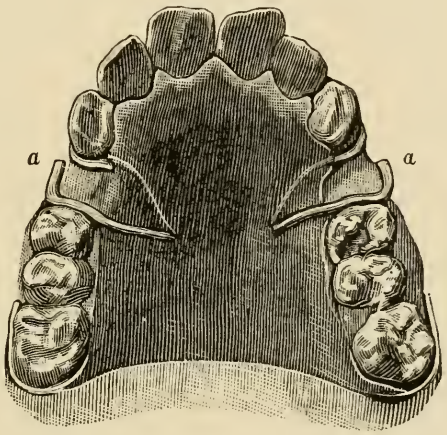

Supplemental force was applied to the bicuspids by means of a double cross-bar, cementing to them on each side of the arch a swaged metal cap with a wire eyelet, *f*, *f*, soldered on the bucco-distal surface, and utilizing the cross-bar previously employed in the upper arch, by hinging to it in the same manner another large wire formed into a semicircle to follow the labio-buccal curve. Two large U-shaped loops bent downward were arranged in the semicircular wire, one on either side opposite the bicuspids, with the ends extending backward, *e*, *e*, to pass through the eyelets (*f*, *f*) of the metal-caps; the wire being sufficiently long to leave a space about one-eighth of an inch between it and the front teeth when in position. As the bicuspids moved backward, the semicirclar wire approached

the incisors, and was necessarily lengthened to prevent it coming in contact with them. This was done by opening the loops *g*, *g*, that had been provided for the purpose. The bicuspids were moved backward in a limited time, and when in good position they were retained by cementing to them and to the second molar on each side of the arch a swaged metal cap, with an eyelet on the buccal surface (Fig. 475).

The incisors and cuspids were forced backward by adjusting a wire bar, *h*, *h*, to follow the labio-buccal surface near the gum, the ends extending backward and passing through the eyelets on the caps. To this bar opposite the first bicuspid on each side was

Fig. 474.

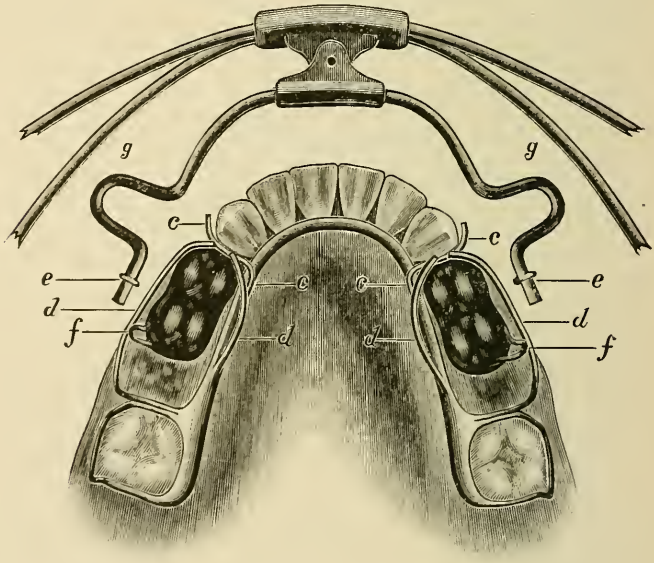

soldered a wire eyelet for the readjustment of the ends of the semicircular wire of the cross-bar *e*, *e*, for causing supplemental force on the teeth; and at the same time there was attached by the eyelets a looped spring-wire shaped to project downward, as shown at *i*, *i*. When the bar was adjusted in the eyelets of the metal-caps *k*, *k*, the distal part or free ends of the U-shaped loops were sprung back of the metal eyelets. The bending together of these spring loops a little at a time caused a steady, light force inward on the incisors and cuspids, without materially interfering with the anchorage teeth, and the cross-bar furnished the necessary additional force in the

Fig. 475.

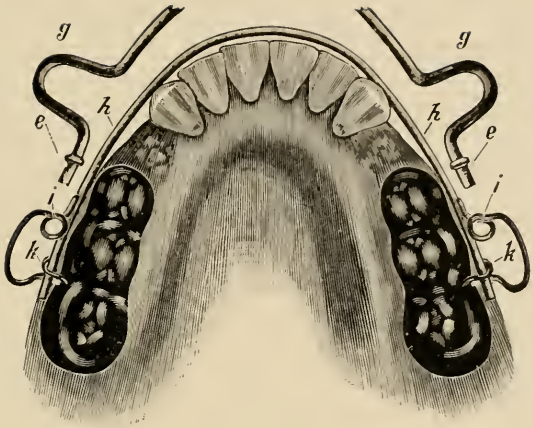

Fig. 476.

same manner as in moving backward the bicuspids. The regulation of the upper and lower arches were completed about the same time, giving a good occlusion. Fig. 476 shows the improved condition.

In moving molars or bicuspids distally in this manner, broad collars cemented to the teeth can be used in place of the metal-caps by soldering to the buccal surface an eyelet, tube, or spur projecting forward about three-sixteenths of an inch, to engage with a cross-bar apparatus. The direction of the force for moving backward bicuspids and molars of the lower or upper arch is sometimes better controlled by an apparatus with an infralabial or a supralabial bar (Figs. 212 and 240). It can be used for moving backward all of the teeth of the arch, or, when desirable, for moving one or more on one or both sides.

CHAPTER XXVI

BICUSPIDS, TO MOVE FORWARD—TO RELIEVE IMPACTION—ELEVATE—DEPRESS—ROTATE

Moving Bicuspids Forward in the Line of the Arch.—The operator is not often called upon to move the bicuspids forward, but occasionally this change of position is required,—moving them forward with other teeth in cases of improper development with receding jaw; for correcting malocclusion and closing objectionable interdental spaces. The spaces may be caused by migration backward of the bicuspids, owing to the injudicious extraction of the first permanent molars, or spaces may remain between the cuspids and second bicuspids after the extraction of the first bicuspids to give room for the regulation of prominent incisors and cuspids. These conditions can be corrected by moving the bicuspids forward with an apparatus, or by wedging.

Fig. 477 illustrates a device that has been used for moving the bicuspids forward and closing interdental spaces. A palatine base-wire is anchored with spring-clasp attachments to the second bicuspids. A spring-wire is shaped into a semicircle to cross the labial side of the incisors, with a loop extending upward under the lip opposite each of the cuspids; the ends are soldered to the spring-clasps on the buccal side of the bicuspids, by first passing underneath them a narrow piece of thin plate-metal contoured similar to a partial-clasp. The second bicuspids are moved forward by gradually narrowing the loops in the semicircular spring. For closing an interdental space at the median line, a flat spring made of a narrow piece of spring plate-metal is shaped to cross the labial side of the incisors, its ends curved backward to rest on their distal surfaces and soldered in the centre to the semicircular spring. The incisors are forced together by curving the ends.

Another apparatus for moving the bicuspids mesially can be made by anchoring a base-wire strongly to the molars, and attaching a spring to the base-wire to pass back of the bicuspids, force being got by bending the springs forward. A plate strongly anchored,

similar to Fig. 470 can be utilized, by arranging the springs *a*, *a*, to project back of the bicuspids.

In a receding upper jaw, the anchorage is sometimes insufficient to move the front teeth and the bicuspids forward. In the case of Mr. C., aged thirty-eight years, these conditions were presented in the upper arch. The teeth of the lower arch were in good position, but the upper incisors and cuspids closed back of the lower ones, interfering with mastication and presenting an unpleasant appearance, with apparent prognathism. The upper incisors and cuspids were first moved outward to proper place and retained for a time. An apparatus was then inserted, both to retain them and to move the bicuspids forward. For this, force was applied, but it was soon

Fig. 477.

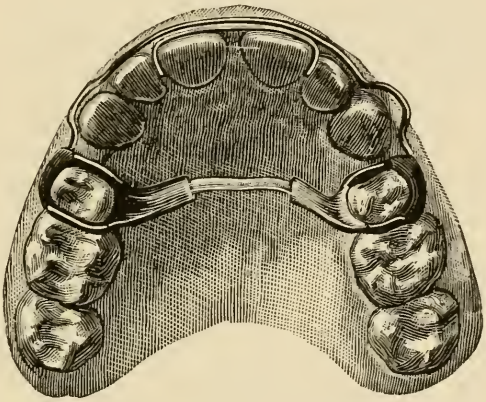

found that the anchorage teeth were moving backward, and finally to such an extent as to encroach on the tissues of the cheeks and throat, causing serious inflammation and swelling, and necessitating a change in the form of anchorage. None of the teeth of the arch could be utilized, as all of them had been moved.

Two sources of anchorage remained available; the teeth of the lower arch, and external anchorage. The upper bicuspids were separated, and an appliance was strongly anchored to the teeth of the lower arch (Fig. 478). It was made with a lingual base-wire retained by spring-clasp attachments, and a spring like a continuous spring-clasp extending from the base-wire to rest on the labial faces of the incisors and cuspids. To the base-wire of the appliance, opposite the upper bicuspids on each side, was soldered a

spring-wire, No. 18 gauge, bent into a loop to project upward into the space back of each of the bicuspids in occlusion, forming inclined planes. As the loops were made of spring-wire, they yielded somewhat to pressure. They were bent forward and reshaped from time to time to change the force, moving the upper bicuspids forward rapidly. Although the wire loops projected about three-sixteenths of an inch above the grinding surface of the lower teeth, the patient

Fig. 478.

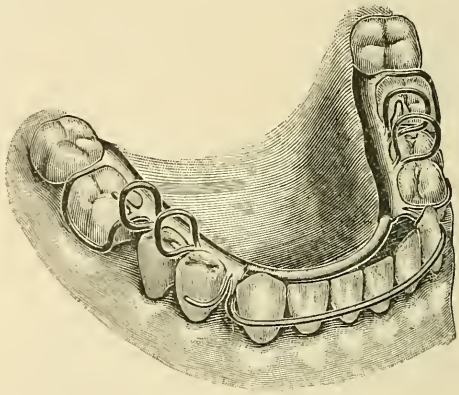

was able to masticate with comparative comfort. When this apparatus was inserted, the appliance was removed from the upper arch. The molars receded to their natural position, relieving the inflammation; after the regulating was completed, a palatine plate (Fig. 499) was inserted as a retainer. A very desirable result was obtained.

I have devised and used many forms of apparatus in one arch to cause the movement of the teeth of the opposite arch, some of which are described.

When it is desirable to move the bicuspids or other teeth forward bodily, see description in connection with Fig. 483. If the usual anchorage is insufficient, supplemental force can be employed. For correcting the lower arch, see description of apparatus Fig. 144; for the upper arch, Fig. 373.

Relieving Impaction of Bicuspids.—When from the too early extraction of a deciduous molar or other cause the adjoining teeth move towards one another, narrowing the space, it generally interferes with the normal eruption of the bicuspid, and if its eruption is entirely arrested it is termed impaction. Impaction of the bicuspids may

occur in either the upper or lower arch. Cases are not infrequent where a second deciduous molar has become impacted and is retained in a similar manner by the early eruption of the first bicuspid, holding the deciduous tooth between it and the first permanent molar long after the complete absorption of its roots.

Fig. 479.

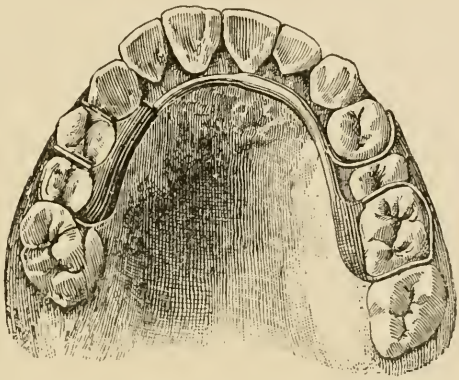

Fig. 479 shows a device that was used for liberating an impacted left upper bicuspid for Miss C., aged fourteen years. It was made by forming to the inner curve of the arch a lingual base-wire, anchored on the right side to a first bicuspid and on the left to the first molar. A spring was joined to the base-wire opposite the left cuspid,

Fig. 480.

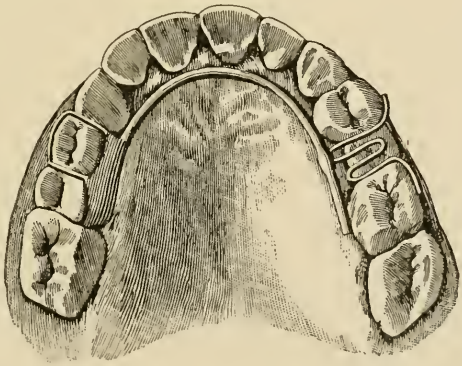

and made to extend in a curve to the distal side of the first bicuspid. The spring was bent forward twice weekly to give force for broadening the space, permitting the bicuspid to take a normal position.

In Fig. 480 is illustrated a modification of the appliance de-

scribed, the action of which is like a wedge. It is made by forming a single- or double-looped spring for the space, held in place by attaching the end of one of the loops to the base-wire. The spring is elastic, and is suited to cases that cannot be seen frequently.

Another method that has been used to advantage for increasing the space for an erupting second bicuspid is made by anchoring a medium-sized lingual or palatine base-wire with a spring-clasp attachment over the first bicuspid on either side of the arch. One end of a spring-wire bent into the form of a U-shaped loop is soldered to the partial-clasp with the base-wire; the free end of the spring is shaped to extend into the space in contact with the mesial surface of the first molar, the loop portion pointing towards the roof of the mouth. Force is applied by bending backward the spring. If the end is not well retained it can be held in position by attaching to it a broad partial-clasp projecting slightly onto the grinding surface of the molar.

In the adult, with this form of appliance, it may be necessary to improve the anchorage by cementing to one or more of the incisors a collar with a suitably shaped lug to engage with the base-wire.

Figs. 159 and 177 illustrate devices employed for moving upper molars backward in the line of the arch to relieve impacted bicuspids, at the same time moving the incisors outward.

Elevation of Bicuspids.—Elevation of the bicuspids is sometimes necessary in correcting lack of lateral occlusion and for encouraging natural eruption. The latter procedure is especially for young patients: with the adult the elevation of bicuspids in their sockets for correcting lack of lateral occlusion is not always practicable, as the teeth are liable to return to their original position. Sometimes the process wastes away, and they settle to a lower level than before operating.

A device for the elevation of a bicuspid may be made by anchoring a base-wire in the usual manner. Attach to it a curved finger-spring to engage with a tube, hook, or pin on the lingual or buccal side of a collar that has been cemented to the tooth to be elevated, supporting the apparatus with curved metal flanges projecting from the base-wire onto the adjoining teeth to prevent it pressing on the gum when force is applied. When this support is required from an incisor, plate-metal should be formed into a hook to hook over the morsal margin. After the teeth have been drawn to position they should be retained.

For the elevation of bicuspids, Dr. M. L. Fay cements to each tooth to be elevated a spring-clasp attachment with partial clasps arranged on the lingual and buccal sides, in this manner doing away with the adjustment of collars, which, even though thin, interfere by taking up more or less space in the arch. When two or more adjoining teeth are to be elevated, the spring-clasps are made with but one arm extending over the arch, which proves sufficient. To each partial-clasp on the lingual and buccal sides are soldered hooks for the adjustment of small rubber bands to pass over an elevating bar. The bar is usually made of three small wires of German silver united with silver solder. It is arranged to pass over the grinding surface of the teeth, and to be supported by bending the distal end at an obtuse angle to rest on the grinding surface of the second or the first molars. The front part of the bar is soldered to a swaged metal cap resting on the incisors, principally on the lingual side. The centre wire of the bar rests a little higher than the others. In this notches are cut where the rubber bands pass over, for protecting them in occlusion. Dr. Fay has used the apparatus for elevating the first lower molars and the bicuspids at one time.

For other apparatus suitable for the elevation of the bicuspids, see Incisors, to elevate; Cuspids, to elevate.

Depression of Bicuspids.—The bicuspids are sometimes elevated in their sockets by the eruption of adjoining teeth. When extreme force is applied for retracting the arch, the bicuspids are occasionally raised in their sockets by the lateral pressure on them, especially when external force is applied. Not infrequently they are elevated by improperly anchored regulating appliances. When the appliance is removed they usually settle in their sockets again from natural causes. If force is required for their depression, an appliance with springs anchored to the adjoining teeth is applicable; or an apparatus similar to Fig. 345 can be utilized; or a chin-cap applied as shown in Fig. 408.

Rotation of Bicuspids.—Rotation of the bicuspids requires more force than for rotating incisors, but similar apparatus can be used. For examples, see Figs. 298 and 320.

CHAPTER XXVII

MOLARS, TO MOVE OUTWARD—INWARD—FORWARD—BACKWARD—DEPRESS—ELEVATE

The molars in their eruption generally take a good position in the arch, but sometimes it is necessary to depress, elevate, or move them in a buccal, lingual, mesial, or distal direction.

Outward Movement of Molars.—Fig. 481 illustrates the case of Miss M., aged fourteen years. The second right lower molar did

Fig. 481.

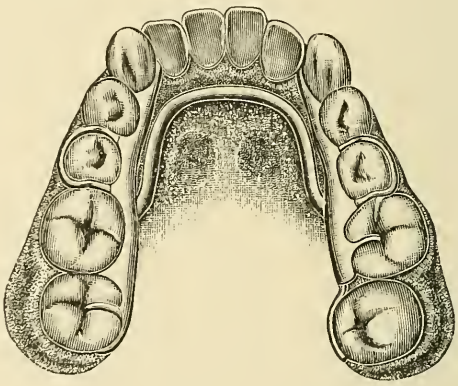

not occlude with the teeth of the upper arch, but had taken a position considerably inside the normal line. An appliance for its outward movement was made with a rigid lingual base-wire anchored with spring-clasp attachments to the first bicuspids, and partial clasps on the other anchorage teeth. To prevent the appliance from slipping towards the gum, spurs were arranged to extend from the anchorage portion onto the grinding surface of some of the molars. A small spring-wire shaped to extend on the lingual side of the instanding molar was soldered to the partial-clasp with the base-wire. Force was applied by bending the end of the spring outward from time to time.

One or more molars on each side of the arch may be moved outward, when required, with a spring attached to an apparatus in this manner.

When the position of a tooth causes the spring to slip towards the gum, or it is not well retained, it can be supported by soldering to it a short partial-clasp, or a narrow piece of plate-metal shaped to project a little onto the grinding surface of the tooth. The outward or buccal movement of molars for improving occlusion is further described and illustrated in Chapter IX., Expansion of the Dental Arch.

Inward Movement of Molars.—Fig. 482 illustrates the case of Miss W., aged eighteen years. The second and third upper molars

Fig. 482.

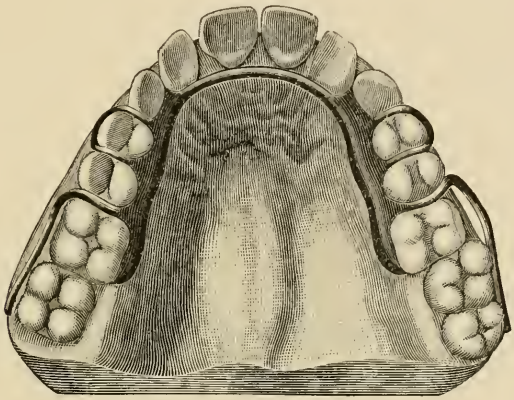

did not occlude with the lower molars, but had assumed a position entirely outside of the normal line. The first molars and the bicuspids articulated well. For forcing the irregular teeth into position, an appliance was made with a rigid lingual base-wire anchored to the first molars and bicuspids. A spring was attached to the partial-clasp by the end of the base-wire on each side of the arch and shaped to extend over at the junction of the second bicuspid and first molar, where it was bent backward, terminating on the buccal surface of those to be moved. Force was applied from time to time by bending the springs to press inward on the irregular teeth.

Other suitable apparatus for moving molars inward is described in Chapter X., Contraction of the Dental Arch.

Forward Movement of Molars.—Owing to the natural tendency of the molars to move forward in the line of the arch, an apparatus is seldom employed, but its application is occasionally necessary to close objectionable spaces and improve the occlusion.

When there are spaces in front of the molars of the upper arch, a device similar to Fig. 477 is applicable for their movement. A palatine base-wire is anchored with spring-clasp attachments to each of the teeth to be moved. A semicircular spring with two U-shaped loops is fitted on the labial side of the front teeth, the loops being placed opposite the first bicuspids, with the ends soldered to the spring-clasps on the buccal side. The closure of the loops of the spring gives the necessary force, but generally the molars are so firmly set in the process that it is advisable to apply wedges back of them for several weeks to encourage their movement.

Fig. 483 shows a device for moving forward a lower or upper molar on one or both sides of the arch, and for correcting molars

Fig. 483.

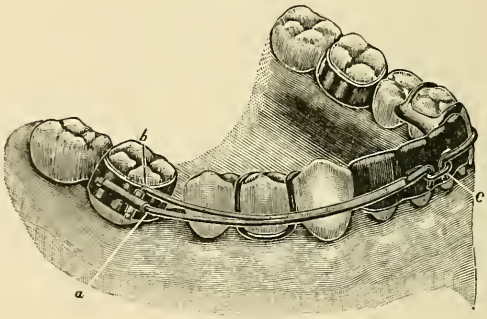

that are tipping forward by forcing them to an upright position. To each of the molars to be moved is fitted a strong broad collar with a tube soldered horizontally on the buccal side near the gum. Another short tube is soldered perpendicularly to the mesio-buccal surface of the collar; the end extending a little above the horizontal tube and in contact with it. A swaged metal-cap with a small wire eyelet attached horizontally on the labial surface near the gum is adjusted to the incisors. The cap is anchored by a lingual base-wire and spring-clasp attachments passing over the first bicuspids. A spring is shaped to enter the horizontal tube on the collar *a*, extending forward and following the curve of the arch to the median line, with the end bent at a right angle to enter the eyelet *c*, of the cap. Another spring of similar curve is bent at a right angle to enter the perpendicular tube on the collar *b*, either from below or above, extending forward; both springs are joined with solder

opposite the incisors and cuspid. A similar combination spring is applied when a molar is to be moved on the opposite side of the arch. Force to move the molar forward is exerted by withdrawing the spring from the tubes *a*, *b*, and curving it outward more in the centre opposite the cuspid and first bicuspid. The hooked portion of the spring that enters the eyelet *c* can be curved more, or, for this purpose, the portion of the spring opposite the incisors may be formed into a U-shaped loop projecting downward. Close the loop a little from time to time, and readjust. For tipping the crowns to improve the occlusion and drawing the roots forward bodily, the end of the long wire at *a* should be bent downward, and the short wire entering the tube *b* bent more acutely before its insertion, the spring being shortened as described for causing forward traction when required. If but one molar is to be moved forward in this manner, It is sometimes advisable to cement the cap to the incisors.

In moving the molars bodily forward, when desirable, supplemental force can be employed (see Figs. 144 and 373).

Backward Movement of Molars.—The backward movement of the molars is required to give space for impacted bicuspids, prominent bicuspids, or cuspids, for correcting the position of malerupting third molars, and for improving occlusion; sometimes moving backward the whole arch.

Figs. 159 and 454 show appliances for moving backward the molars to relieve impacted bicuspids, the appliances being suitable when there is space back of the first molars and before the eruption of the second molars. After the eruption of the second and the third molars, supplemental force for moving them backward is generally required, applied with a cross-bar similar to Figs. 471 and 474, or by a chin-cap and wire standards similar to Figs. 212 and 240.

For relieving an interlocked or impacted third molar (Fig. 484), an appliance is made with a lingual base-wire well anchored to the teeth on each side of the arch. To the base-wire in the distal part is soldered a small spring bent into a long U-shaped loop projecting towards the median line, following the palatine curve. The free end of the spring is shaped like a hook, to engage with the mesial surface of the impacted molar at any point accessible; even extending below the gum, or shaped to project into a pit provided in the grind-

ing surface of the tooth. Action is caused by opening the loop. Forcing the tooth backward at the same time elevates it. The appliance can be used in either the upper or the lower arch.

Depression of Molars.—The depression of molars is required in correcting lack of anterior occlusion, and when the molars have

Fig. 484.

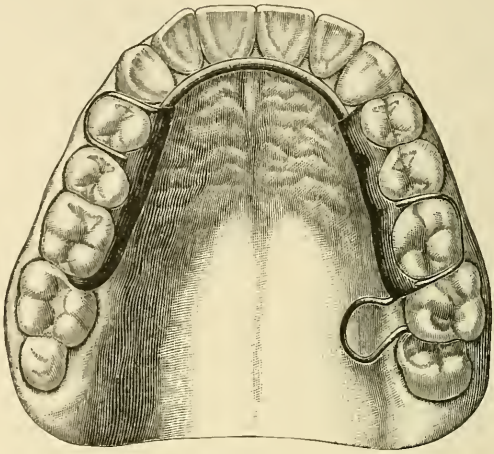

been drawn from their sockets with improperly anchored regulating appliances. Their depression is usually accomplished by the continued application of a chin-cap (Fig. 408).

Elevation of Molars.—When the incisors and cuspids are extruded, the molars and bicuspids usually rest deep in their sockets. In the process of depressing the lower incisors and cuspids all of the pressure in occlusion is placed on these teeth (Fig. 337), and the molars, owing to their lack of occlusion, gradually become elevated, especially with young patients. The wedging of these teeth encourages their elevation. Apparatus used for the elevation of the bicuspids is suitable for the elevation of the molars, but special apparatus is seldom required.

CHAPTER XXVIII

RETENTION OF THE TEETH

Methods of retaining teeth after their regulation, and teeth loosened from accident, pyorrhœa alveolaris, or other cause.

The object of retention of the teeth is to hold them steady in position until the alveolar process becomes sufficiently recalcified about their roots to properly sustain them.

Not infrequently cases are presented that require more skill in retaining the teeth than for regulating them.

Much harm may arise from interrupting the retention of teeth, as from the carelessness of the patient in leaving out the appliance after cleansing, which leaves them without a support; from the use of an imperfect retaining device that permits the teeth to move back and forth in their sockets, either of which causes irritation, interferes with the normal deposit of bone, and may, when continued, result in a thickening of the peridental membrane, permitting a movement of the tooth; in extreme cases the movement almost amounting to a false joint, and finally causes the wasting away of the alveolar process by absorption.

The retaining device should be made in a manner thoroughly adapted to hold the teeth in their new position without changing the occlusion or interfering with enunciation. It should not be conspicuous, nor prevent the proper care and absolute cleanliness of the teeth. Especially is this necessary if the retaining device is to be worn a considerable length of time. When the teeth are moved rapidly in regulation the alveolar process is sprung more or less, as its absorption is necessarily gradual, and generally on account of this the retainer needs to be strong and the teeth retained a longer time than when moved more slowly. A strong retaining device is required when the occlusion of the teeth interferes with those being retained. Excessive force with removable retaining devices, sometimes moving the teeth too far, rotating, depressing, or elevating them abnormally in their sockets, is objectionable. Usually but slight pressure is necessary for the retention of teeth that have been moved.

Length of Time that Teeth should be retained.—This is a perplexing question to the inexperienced. No definite rule can be laid

down that will include all cases; but it is almost always an advantage to wear the retaining device a longer rather than a shorter period. The usual time ranges from four months to a year. Long retention of the teeth of the young is sometimes required to prevent them again being moved out of position by the wedging of erupting teeth adjoining them; and again, with persons of more advanced years, it is sometimes necessary that the teeth be retained a considerable length of time. Nearly all cases of expansion of the arch require long retention.

It is essential that the cause of the irregularity should first be removed when possible. If the same influences that accompanied the irregularity are allowed to continue after the removal of the retainer, the teeth will usually return to an irregular position. With hereditary tendencies existing in some instances, it is necessary that the device be worn continuously for several years, to hold the teeth until the bone and process become thoroughly calcified for their support, and in others worn indefinitely, particularly at night, to accustom to the new conditions the developing tissues, the tongue, lips, and cheeks. These form a matrix which exerts a considerable influence in shaping the jaw during its development. Their influence in shaping the arch is especially apparent in cases of mouth-breathing, when an appliance for retaining the teeth does not always prove sufficient. If the conditions that induce mouth-breathing cannot be entirely removed, an apparatus should be employed to assist its prevention. Usually the application of a properly constructed chin-cap for supporting the jaw will be sufficient to establish nose-breathing by causing the lips to rest in contact, and when, from excessive development of the alveolar process or extrusion of the teeth from their sockets, the jaws are separated to an extent preventing the natural closure of the lips, which is common in these cases, the continued use of the chin-cap, with properly directed force, will depress the teeth in their alveoli and correct the conditions by permitting the lips to close, encouraging nose-breathing. The time required for its application, depending on the density of the bone and alveolar process, is shorter in the case of the young.

Teeth that have been rotated generally need to be retained a considerable length of time, and it is advisable that in their regulation they be moved farther than it is intended that they shall remain, and retained there. To prevent the tendency of the teeth to change their

position after the removal of the retainer, it has been suggested that after they have been rotated as far as desired, the soft tissue be separated freely from the neck of the tooth and allowed to reunite in the new location, depending on the cicatrix thus formed to prevent their retrograde movement.

There are other conditions, especially in young patients, that require no apparatus for retaining after regulation, as when the upper incisors or cuspids have recently erupted back of those in the lower arch, or when the lower incisors or cuspids have assumed a position in front of the teeth of the upper arch; either of which, after correction, if there is sufficient lap, are generally retained by their natural occlusion. Bicuspids or molars that have been moved backward, forward, lingually, or in a buccal direction, are sometimes retained by their occlusion, the cusps of those having been moved fitting into the depressions and at the junction of the teeth of the opposite arch; but in these cases it is always advisable to continue the use of the regulating appliance, or to insert a retaining device for supporting the teeth. With the bicuspids or molars in the adult, in similar cases, it is sometimes justifiable to reshape the surfaces of their crowns by dressing the enamel to improve their planes of occlusion.

When it is thought that the teeth have been retained sufficiently long, before removing the retaining appliance permanently, it should be left off for three or five days, and the teeth examined carefully to see if there has been any change in their position. This can usually be determined by replacing the device. When there has been a perceptible change, it should be worn for a longer time, otherwise the teeth should be examined again in about twelve days, and later at stated intervals, or the appliance can be worn at night.

Devices recommended for the retention of the teeth will be referred to as the *Removable*, *Fixed*, *and Permanent.*

Removable Retaining Devices.—Removable retaining devices include those that can be taken from the mouth by the patient for cleansing, etc. An appliance that has been used for the regulation of the teeth, or made in a similar manner, is often equally applicable for their retention. Many styles of suitable apparatus are portrayed in the previous chapters in connection with the regulation of the teeth. The patient should be directed to cleanse the appliance and the teeth thoroughly at least twice a day, in the morning and at night.

Fig. 485 illustrates a device for retaining incisors and cuspids that have been moved inward. It has a labio-buccal bar, made by shaping a wire to rest on the teeth, usually near the gum, but sometimes near the incisive edge. Its ends are anchored one on either side of the arch with a spring-clasp attachment over a bicuspid or molar, having the partial-clasp on the buccal surface.

Fig. 485.

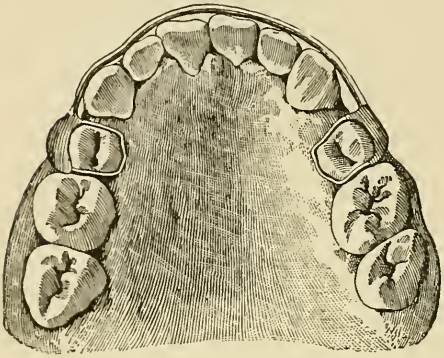

It has been found from experience that one bicuspid on each side of the arch that has not been moved in regulating will generally afford sufficient anchorage for retaining six front teeth that have been moved inward.

In some instances, after a retainer is applied, it is found that a better general result can be brought about, improving the occlusion, etc., by moving the front teeth a little farther inward, and in other cases by letting them recede some towards their original position. When it is apparent that any change of this kind may be needed, one or more U-shaped loops should be formed in the labio-buccal bar (Fig. 486), with the loops arranged to project under the lip on the sides of the arch where they will be the least conspicuous, the loops being opened or closed by bending to change the length of the bar for causing more or less pressure as required.

Fig. 486.

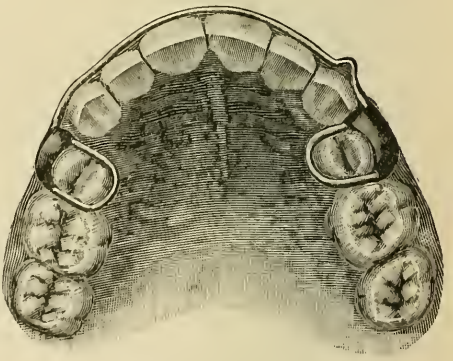

If much inward traction is needed, the anchorage should include one or more molars on each side of the arch.

When preferred, the device can be held by collars cemented to the teeth (Fig. 487), the collars having a tube soldered to the buccal surface in a horizontal or in a perpendicular position, and the ends

of the bar bent into the shape of a hook for hooking into the horizontal tube in the manner shown at *a*, or bent at a right angle to pass into the perpendicular tube, as seen at *b*. The loops projecting under the lip should be made rather small and properly adjusted.

With this style of retaining device, occasionally more force than necessary is exerted, which is objectionable. When too much force

Fig. 487.

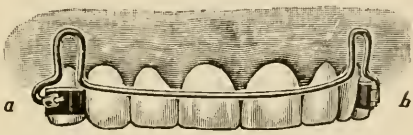

is applied to the upper incisors, it will crimp them; or if in occlusion they rest against those of the lower arch, they are moved outward, which necessarily causes excessive forward traction on the teeth used for anchorage. This device is used for moving front teeth inward by placing collars on the molars.

The labio-buccal bar, with a loop on either side, is used in connection with a lingual or a palatine base-wire for the regulation or retention of the teeth (Fig. 488). The distal ends of the looped

Fig. 488.

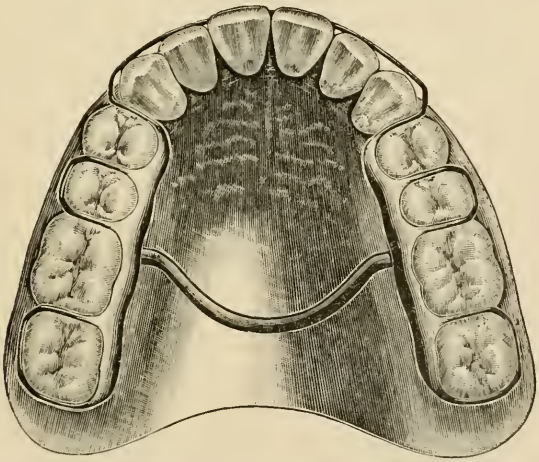

portions are shaped to extend over the arch at the junction of two of the teeth and attached to the anchorage. The figure shows a palatine base-wire.

Fig. 489 illustrates a similar device for retaining incisors, or incisors and cuspids made without the adjustable loops in the bar.

A lingual base-wire is anchored to two or more teeth on each side of the arch with partial-clasps and spring-clasp attachments. A bar

Fig. 489.

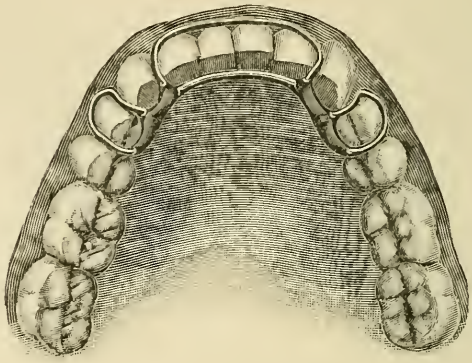

is shaped to rest on the labial faces of the incisors usually near the gum, and the ends are passed directly over the arch just in front or back of the cuspids to be soldered to the base-wire.

When incisors have been rotated, their retention with this device can be made more complete by shaping to their lingual surfaces a continuous partial-clasp, attaching it to the base-wire.

Fig. 490.

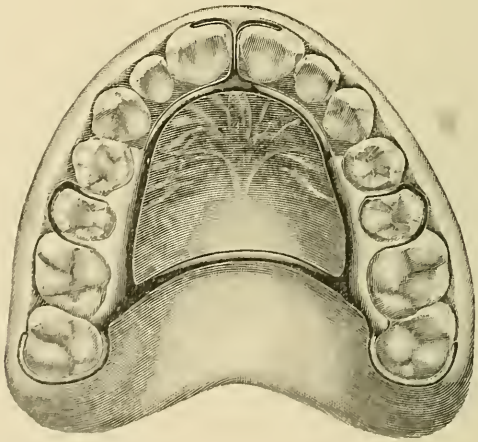

Fig. 490 illustrates a device with a T for retaining corrected prominent upper incisors, the major part being arranged inside of the arch. It is made by first uniting a small-sized lingual base-wire with a palatine base-wire, and anchoring them with partial-clasps

and spring-clasp attachments. The T is usually made by fitting a short bar of metal to the labial side of the incisors to be retained. To the centre of the bar is soldered another short bar that is flattened sufficiently to pass between the teeth. The other end is united with solder to the lingual base-wire. Sometimes the T is made by attaching to the base-wire, side by side, two thin narrow strips of spring plate-metal to pass between the incisors, with the ends curved outward to rest on their labial faces.

Similar T's anchored with a rubber plate have been in use for many years.

Fig. 491 illustrates a device used for forcing outward an instanding incisor, and at the same time drawing inward a prominent incisor

Fig. 491.

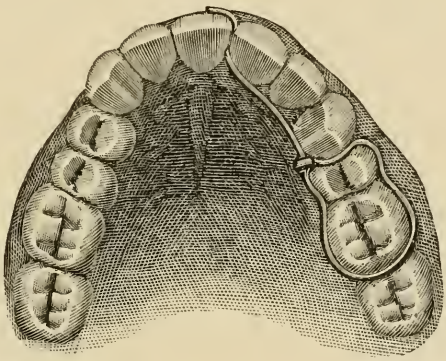

that was overlapping it, the same device being used afterwards to retain them. It was made of wire, one end being bent into the form of a continuous spring-clasp for anchorage, extending around a molar and a bicuspid near the gum, passing over the arch at the junction of two of the teeth, and the end soldered to the body of the wire. The other end was shaped to extend forward, following the lingual curve of the arch, passing back of the instanding incisor, through the interdental space at the median line, and terminating in a curve on the labial face of the prominent incisor. The device was removed by pressing downward on the anchorage portion, then rotating it and drawing it backward from between the teeth.

Fig. 492 illustrates a device used for moving into line and retaining a prominent incisor. A lingual base-wire is anchored with partial-clasps and spring-clasp attachments. A spring-wire shaped to extend

over the arch at the junction of the incisors, with the end bent at a right angle to rest on the labial side, is soldered to the base-wire

Fig. 492.

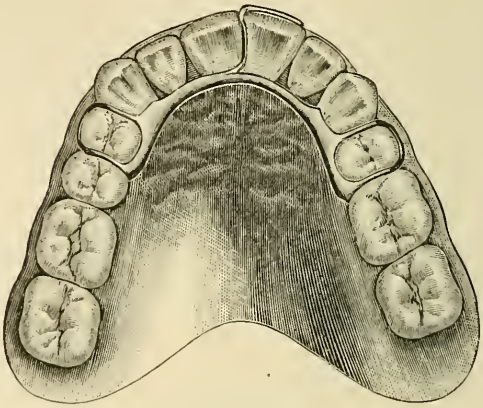

near the median line. Two or more springs of this shape may be used, or a continuous spring employed (Figs. 223–225).

When one or two incisors have been moved outward or inward to line and need to be retained but temporarily, they can sometimes be sufficiently supported with a small-sized wire ligature of platinum, silver, or copper, passing it back or in front of them as need be and around the adjoining teeth when they are in good position, drawn tight, and the ends fastened. When the centrals have not been moved, the laterals can be retained by fastening a ligature to them in a similar manner.

Fig. 493

Fig. 493 shows a simple device that was worn by Miss B. for four years for supporting a right upper central incisor that had been rotated.

As the torsion was hereditary, it was known that the retainer would need to be worn a long time. A narrow strip of spring gold-plate was bent in the form of a clasp to surround the tooth, with one end resting on the labial face, and the other end bent outward to rest on the labial face of one of the adjoining teeth. A spur was attached with solder to the lingual side for projecting onto the surface of the other adjoining tooth. Being made in this manner it was less conspicuous than a collar would have been. When preferred, both ends may clasp the tooth.

A similar device can be made to retain two or more teeth by joining two clasps and cementing them to place.

Fig. 494 illustrates a plate with a labio-buccal bar for retaining six anterior teeth. It is made with rubber covering the roof of the mouth and fitted well to the necks of the teeth. A semicircular wire is shaped to pass in front of the incisors and cuspids near the gum, the ends being curved to extend over the arch usually at the junction of the cuspid and first bicuspid to be embedded in the vulcanite. If the plate interferes with the tongue in enunciation, in some cases the front part can be cut away; but for retaining teeth that have been crimped or rotated, as in the V-shaped arch, the rubber should cover the whole palatine surface, resting in contact with all of the teeth, and the bar should cross the labial side of those to be retained rather near their incisive edge.

Fig. 494.

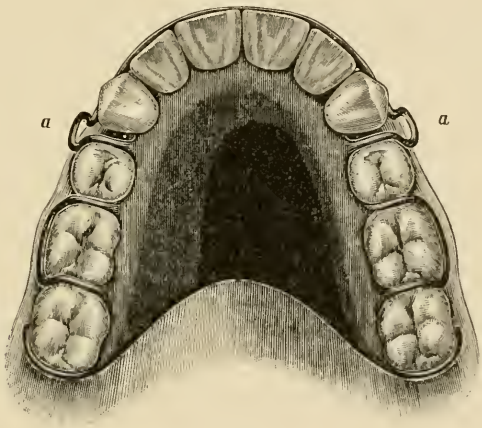

With this form of retaining plate it is generally an advantage to have the labio-buccal bar adjustable for causing more or less force as the case requires. This is accomplished by arranging in the bar, on one or both sides of the arch, a small U-shaped loop (*a*, *a*), which can be opened or closed by bending. I have also used this form of bar in connection with a plate many years for the regulation of teeth.

When there is insufficient space for the wire-bar to pass between the bicuspids and cuspids it should be curved up well over their coronal surface, as, if the teeth have been drawn together, and the wire is permitted to rest heavily at this point, it will gradually wedge the teeth apart again.

A round wire for the bar is generally preferable to the half-round or flat. It can be bent more readily into form, and, being round,

it has less surface contact with the teeth, and is not so liable to retain the secretions and food-particles, thus lessening the tendency to decay. The plate may be retained by a suction chamber, by wire-clasps or plate-clasps extending around the distal molars in the arch, or by spring-clasps passing over the bicuspids or molars.

I have devised and used successfully a great variety of spur and spring attachments in connection with metal and vulcanite plates for retaining as well as for moving the teeth in different parts of the arch. Incisors that have been moved laterally towards or from each other may be retained with metal points extending from a plate or a base-wire into the interdental spaces either side of them. Teeth that have been rotated can be retained in the same manner where there are interdental spaces by having the metal points project through or over at their junction and terminate in a curve in front of them.

For retaining upper incisors that have been too prominent and depressed in their alveoli, sheet-metal can be shaped and attached in the front part of the plate in a manner to pass over the incisive edge and rest on the labial side of them without interfering with the occlusion.

Bicuspids that have been moved forward or backward may be retained with a flat or round metal spur projecting from a plate, or the plate may be made to extend into the space.

In some instances it is an advantage to have the projecting portion between the bicuspids sufficiently thick from above downward to extend to the coronal surface, so that in occlusion the teeth of the lower arch will rest against it, affording an additional means of holding the plate in place.

Metal plates can be used for retaining, as for regulating, anchored when desired by a suction, clasps, springs, etc.

Fig. 495 illustrates a wire retaining device, which in 1887 I described and termed a "crib." (See *Dental Cosmos*, 1887, page 375.) It was used to retain teeth of the lower arch after its expansion, for the purpose of admitting instanding lateral incisors, with apparatus as illustrated. The arch was expanded and the teeth regulated in the manner shown in Figs. 141 and 142. The retaining device was made of round platino-iridium wire shaped to clasp the teeth on the labial and lingual sides, extending around the entire arch. It was formed to a plaster model, starting at a given point on the

lingual surface of the molars, following the line of the gum and making sure that the part fitted was held in the same relationship and not allowed to slip. The wire was bent sharply by the fingers and clasp-benders to clasp the necks of the teeth, con-

Fig. 495.

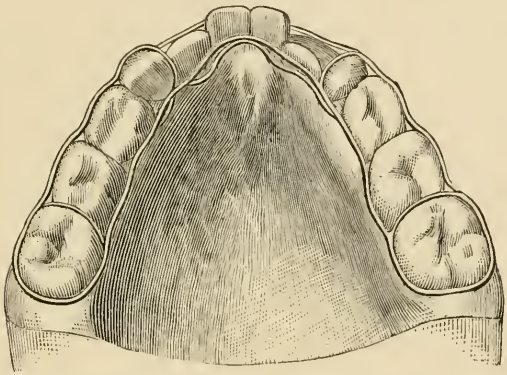

tinuing to the starting-point. The ends were soldered with pure gold. The appliance was strengthened and prevented from pressing on the gum by connecting the labial and lingual wires at different points of the arch with short pieces of similar wire material, arranged to pass over the coronal surface at the junction of two of the teeth and soldered. It was further stiffened by soldering to the lingual side an additional wire bent into two partial U-shaped loops located to project downward back of the lateral incisors. The appliance with this and other spring attachments has been used for the regulation of the teeth.

Sometimes the conditions require the wire to be extended around only a portion of the arch, following the line of the gum and passing over at the junction of the teeth at any place the occlusion will permit. Fig. 496 shows a device made in this manner for retaining the teeth of the upper arch after expansion and the movement outward of an instanding lateral incisor (Figs. 198 and 199). The labial and lingual wires were connected with only one bar, which was flat and passed between the central incisors. This form of device is applicable for retaining prominent teeth that have been corrected in the upper or lower arch.

Under the conditions of this and the previous case, a lingual base-wire, with springs properly anchored, or a plate, is applicable.

Many years ago Dr. Richardson described an appliance for retaining the teeth of the lower arch. It was made of vulcanite, extending on the labio-buccal and lingual sides of the teeth, and passing between some of them and back of the last molars, leaving the

Fig. 496.

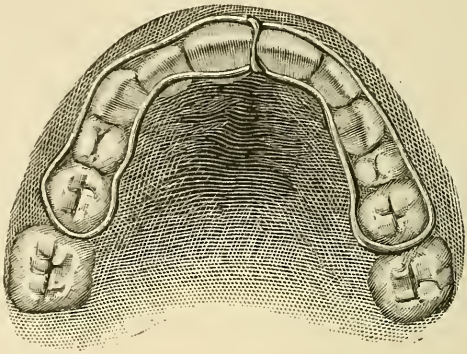

crowns exposed. In other cases the rubber on the labial and lingual sides was united with pieces of metal anchored in the vulcanite, being shaped to extend through interdental spaces. When there are no spaces, the metal can pass over the grinding surface at the junction of two of the teeth.

In Fig. 497 is shown a similar device made of metal, which owing to its weight is less liable to become displaced. It can be made by

Fig. 497.

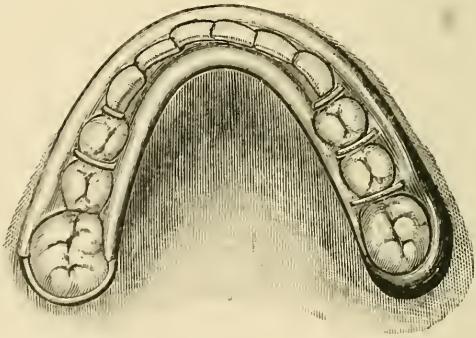

fitting partial-clasps to the teeth, and passing several U-shaped pieces of wire over the arch at different points to connect the outer and inner parts. Other wires can be passed around the distal molars when desired.

The parts are united with soft solder, using a considerable amount of it, or by casting fusible metal in a mould, using a correct plaster model. For casting, form a wax try-plate on the labial and lingual sides of the teeth covering the ends of the wires. Then take an impression with mouldine, or plaster, after which the try-plate is to be removed, and the mouldine or plaster replaced, forming a matrix. An aperture for pouring the heated metal is made by inserting a small-sized metal funnel, three or four inches long, into the mould opposite the last molar in the arch on one side; a small vent-hole is made opposite the last molar on the other side of the arch. The mould is then well dried out, heated, and the metal poured, surrounding the ends of the wires and uniting the parts of the appliance. Enough metal should be used to fill both the mould and the funnel. The higher the metal rises in the funnel, the more pressure is caused for distributing the metal in the mould, thus insuring a sharp cast. The appliance is finished in the same manner as a cast metal plate.

Fig. 498 shows a device that is serviceable for retaining the teeth of either the upper or lower arch after expansion, or for sup-

Fig. 498

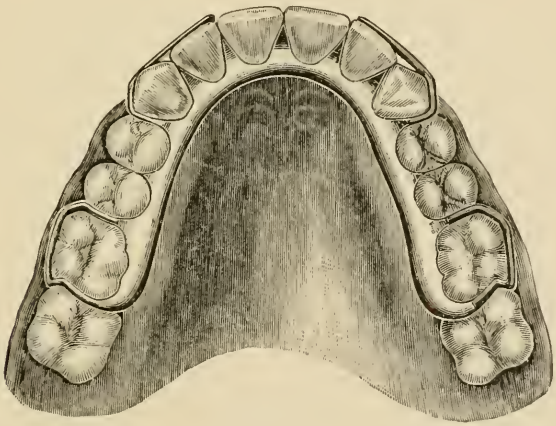

porting one or more that have been moved outward or rotated. A lingual base-wire is fitted well and anchored by spring-clasp attachments, and partial-clasps usually on all of the teeth.

When the device is to be used for retaining incisors, especially in the upper arch, it is advisable to cement to one or more of them a collar with a lug on the lingual side to engage with the base-wire for retaining that part. The lug should always project at a right

angle with the long axis of the tooth, or curve somewhat towards the neck, and at an obtuse angle, as with the latter shape the tooth is likely to move forward and the lug become disengaged from the retaining device.

After expanding, or moving outward one or more of the incisors of the upper arch, a palatine rubber plate is suitable for retaining (Fig. 499). The plate is generally held firmly enough by fitting it carefully to the necks of the teeth. In some conditions, it is ad-

Fig. 499.

visable to have the plate provided with suction, or with one or more spring-clasps extending from the rubber on either side to clasp a bicuspid or molar.

Incisors that have been moved outward, especially those that have been elevated, can generally be best retained by cementing to each of them a collar with a lug, the lug being suitably shaped to hook over the edge of the plate or base-wire. A skeleton plate can be utilized in this manner, and when necessary made firmer by cementing a collar with a lug to a bicuspid or a molar on each side of the arch, the lug being shaped to project slightly over the edge of the plate.

After expansion of the arch, especially in cases of mouth-breathing, it is generally advisable to apply a chin-cap for improving the occlusion. It should be worn regularly at night, and more or less during the day in some cases.

Fixed Retaining Devices.—Fixed retaining devices are usually in the form of a collar or a cap, with suitable attachments, and properly cemented to the teeth. They are generally more conspicuous than the removable devices, but are comfortable to the patient. The

cement is liable to wear away, and an examination should be made at regular intervals to see that there is no wasting away of the cement from under the retainer. Repair it when necessary to prevent the accumulation of food or secretions which would decompose and cause decay of the tooth.

In retaining, it is essential that the tooth be held absolutely firm. It can be supported by fitting accurately to it a thin collar, to which is soldered a spur or bar, projecting onto either the labial or the lingual surface of one or both adjoining teeth in such a manner as to prevent it from returning to its original position.

When the occlusion will permit, and other conditions are favorable, the spur should be arranged on the lingual side, it being less conspicuous.

Fig. 500 illustrates the case of Mr. N. The left upper central and lateral incisors were twisted outward, lapping one another as in the

Fig. 500.

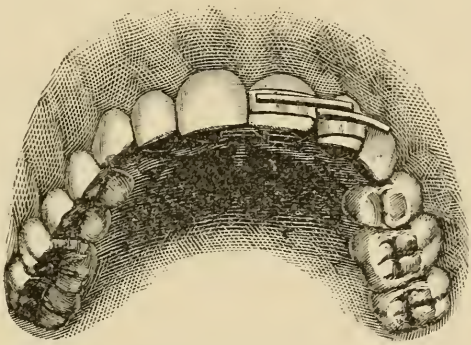

V-shaped arch. A first bicuspid was extracted to gain space for their correction. The incisors were rotated to position, and retained by cementing to each a collar with a spur projecting onto an adjoining tooth, the spur from the lateral resting on the labial side of the cuspid, and the one from the central resting on the labial side of the collar on the lateral. To prevent the left central incisor from moving outward, another spur was soldered to the lingual side of the collar, being shaped to project back of the adjoining central.

Two spurs attached to a collar, one projecting from the lingual and the other from the labial side, in this manner, are generally required for retaining corrected cases of extreme torsion. The spur should always be strong and well soldered. Make it of spring plate-

metal, half-round or round wire, lapping well on the collar; otherwise the collar, if thin, is liable to stretch.

A retaining collar with one spur can sometimes be made to advantage by fitting the metal to the tooth in such a manner that the lap will be on the side where the spur is required, leaving the ends long, shaped to rest together, and soldered, after which the projecting part can be made narrow. When the retaining device is to be worn a considerable length of time, the part of the spur that rests in contact with the adjoining tooth should be formed into a point, the spur being made small and bent forward slightly, or a point made by flowing on to it a small ball of solder. Otherwise, the spur, being left flat, and covering a considerable surface of the tooth, is liable to retain the secretions and cause decay.

The three following devices are recommended by Dr. Guilford: * For retaining two central incisors, or a central and lateral that have been rotated, two platinum or gold collars, properly fitted and united, as seen in Fig. 501, are firmly cemented on the teeth. A gold-bar

Fig. 501.

Fig. 502.

Fig. 503.

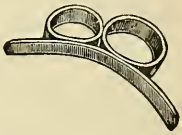

or spur attached to the labial or lingual side of one or more collars, so as to project onto the adjoining teeth, as shown in Figs. 502 and 503, is utilized for retaining teeth after rotation, and for preventing them from moving out of the circle after their correction, especially when the teeth of the opposite arch rest heavily against it. Sometimes, to make the retainer less conspicuous, a portion of the front of the collar can be dressed away.

Fig. 504.

In Fig. 504 is illustrated a similar device for retaining a cuspid that has been moved outward. A collar is accurately fitted to the tooth, and a spur or bar soldered to the labial side of the collar, with the ends shaped to rest on the adjoining teeth.

A collar with a tube attached to the labial or lingual side has been found an effective and convenient method of retaining after rotation,

* Guilford's Orthodontia, 1898, p. 91.

by passing through the tube a wire-bar. Two incisors can be retained in the same manner by cementing a collar with a tube on each. (Several figures showing collars with tubes suitable for retaining will be found in Chapter XIV., Incisors, To rotate.) This means of anchorage has been employed for retaining incisors after being moved laterally together, by inserting a headed pin and bending the end downward sufficiently to prevent its withdrawal.

In Fig. 505 is shown a device that was employed for retaining a partially erupted upper lateral incisor that had been moved out-

Fig. 505.

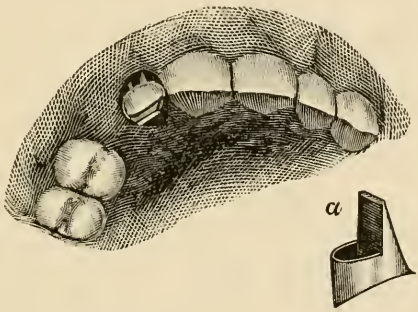

ward from a lingual occlusion. The lateral had been pressed inward by a non-erupted cuspid. The tooth was not long enough to be retained by the natural lap in occlusion, and a collar with a flange on the lingual side, as seen at *a*, was cemented to it, the flange being made of plate-metal shaped to project downward, and sufficiently long to close in front of the lower teeth. This part of the metal was dressed away from time to time as the tooth became more fully erupted.

Fig. 506.

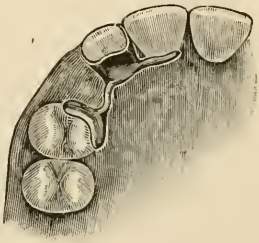

After broadening the space for a non-erupted cuspid or bicuspid, it is generally important that the space be preserved to encourage its eruption. A device for this purpose is shown in Fig. 506. A collar is fitted to one of the adjoining teeth, and a partial-clasp or collar to the other, to which the ends of a wire bent into a partial U-shaped loop are soldered and the device cemented to place.

Teeth that have been regulated, or teeth that have become loosened from pyorrhœa alveolaris, from accident, or other cause, can be re-

tained by cementing to them a metal cap (Figs. 507 and 508). The cap should be swaged with accurate dies in form to pass over the teeth, either covering them entirely, extending to the margin of the gum, or, where the conditions will permit, it may be made less con-

Fig. 507.

Fig. 508.

spicuous by covering only a portion of the labial and lingual sides. When the teeth are very loose the cap should usually include two or more adjoining teeth that are firm in their sockets.

Fig. 509 shows a gold-cap that was used to retain four upper incisors that had been moved bodily outward, and the cuspids that were too prominent and had been moved into the circle of the arch. (For method of making cap, see page 92.) A cap made in this manner is occasionally required for retaining lower incisors. It is especially desirable in cases where the lower incisors have been forced outward, carrying with them, by their pressure in occlusion, instanding upper teeth.

Fig. 509.

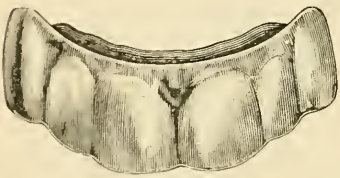

In such a case the pressure of the upper incisors against the lower ones is so great that the ordinary retainer is not always sufficient for supporting them in good position. It is also advantageously used for retaining the line of the lower incisors when forcibly contracting the anterior upper arch. The excessive inward pressure of the upper incisors against the lower ones when not supported is liable to crimp them. The cap can also be utilized for retaining cases of corrected extrusion or retrusion of the teeth.

I have in many instances made similar caps of German silver and of platinoid, uniting the parts with silver or gold solder. These metals are harder to swage, but are sometimes less conspicuous than gold, and generally when they are kept well polished their oxidation does not become objectionable. A cap covering the teeth (Fig. 510), with a projecting shoulder swaged or soldered on the lingual side (*a*), was used for depressing the lower and upper incisors and retaining them. (For description of a similar case, see page 322.)

A shoulder curved downward in the form of an inverted trough is also utilized for preventing abnormal occlusion. The lap of the teeth, when excessive, can sometimes be controlled by attaching a trough to the labial side of a cap cemented to the lower incisors and cuspids.

Extruding lower incisors can be driven downward and retained by a plate covering the palatine arch, made as shown in Fig. 337.

A fixed device with a labio-buccal bar that has been in general use for many years is illustrated in Fig. 511. It was utilized for retaining six front teeth of the upper arch that had been moved

Fig. 510.

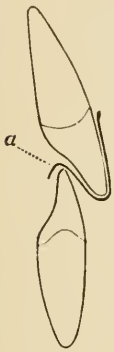

Fig. 511.

inward, the first bicuspids having been extracted. Thin gold collars were fitted to each of the second bicuspids, and a bar of half-round gold-wire was formed accurately to the labial side of the teeth to be retained, the ends crossing the collars near the gum and soldered. The collars were then cemented to the bicuspids, and three of the incisors that had been rotated were bound to the bar with ligatures of wire.

Gold crowns and clasps have been used in place of collars for anchorage. A removable appliance anchored with spring-clasp attachments (Fig. 486) is usually preferable, as the teeth and appliance can be kept more cleanly.

In Fig. 512 is illustrated a fixed retainer with a lingual base-wire for supporting four or six front teeth that have been moved outward. At the same time an attachment can be added at the median line for retaining one or more central incisors that have been rotated. A collar is adjusted to each of the cuspids or first bicuspids, and a stiff round or half-round wire fitted to the lingual side of the incisors, with the ends soldered to the collars. For retaining the rotated

incisors a short piece of wire is soldered to the centre of the base-wire; it is shaped to pass over the arch at the junction of the

Fig. 512.

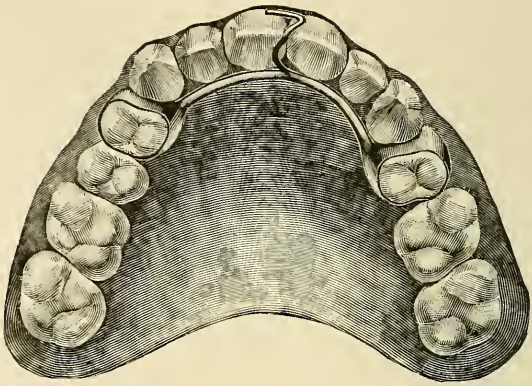

incisors. The end is bent approximately to a right angle to rest on the labial side, being arranged to retain one or two teeth. Sometimes in retaining two incisors it is preferable to attach with solder underneath the outer end of the wire a piece of plate-metal to cross the labial side. When desirable, two or more attachments of this character can be extended from the base-wire.

In Fig. 513 is shown a device employed for the retention of a first bicuspid that had been elevated. A collar was fitted to the bicuspid, to which it was finally cemented. To the mesial surface of the collar was soldered a piece of plate-metal, from the front edge of which was cut a deep U-shaped groove, leaving projecting arms to embrace the labial and lingual side of the cuspid above the cingulum. To the distal side of the collar was soldered a wire-arm projecting backward to rest on the grinding surface of the second bicuspid. Two arms of wire, properly shaped and soldered to the mesial surface of the collar, would have the advantage of being equally strong and less bulky.

Fig. 513.

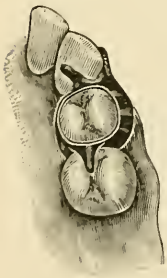

Permanent Retaining Devices.—Permanent retaining devices generally consist of an excessively contoured gold filling, a metal spur, a bar, a crown, or a bridge attached to one or more of the teeth. The permanent retention of teeth is occasionally required to prevail over hereditary tendencies, to retain teeth that have been rotated,

to maintain equal spaces between teeth after expansion and regulation, and to maintain spaces caused by loss or non-eruption of teeth.

A corrected torsion of the incisors in an arch naturally contracted can in some instances be permanently retained by bevelling the approximal surfaces in a suitable manner to rest under counter-bevelled surfaces of the adjoining teeth, as shown in Fig. 514. This method was adopted in the case of Mr. K., aged twenty-four years. The dressing of the surface of the enamel was accomplished with a diamond disk. Care should be exercised not to cut through the enamel, but in some conditions it may be necessary. Dressing of the teeth should not be undertaken in the case of young patients.

Fig. 514.

When there is cavity in the lateral surface of a tooth that has been rotated, or in the adjoining tooth, a gold spur can be cemented into the cavity in position to permanently retain it; or screwed into a hole provided for it in a filling. When there is no cavity, the spur may be screwed into a hole made in the structure of the tooth.*

For retaining teeth that have been rotated, and for keeping space, as between incisors, a filling of gold can be inserted in a cavity, having it excessively contoured and properly shaped for the purpose.†

Fig. 515.

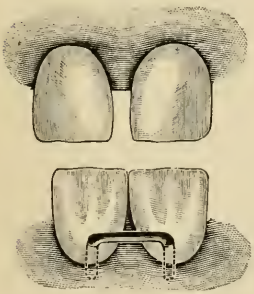

When there are broad spaces between the teeth, as is commonly seen with the incisors, a permanent retainer may be applied after their correction, in the form of a staple device, as shown in Fig. 515.‡ A deep pit is drilled in the lingual surface of each of the teeth, avoiding the pulp. A wire is then bent twice at right angles, forming a staple; the ends are roughened and cemented to place. Several teeth have been joined in this manner. When desirable the device can be used for holding teeth apart. Dr. Niles recommends a link connection, permitting a more free movement of the teeth.

A metal-bar anchored with fillings in cavities in teeth is some-

---

* Baker, Guilford's Orthodontia, 1898, p. 93.

† Farrar, Irregularities of the Teeth.

‡ Case, Dental Review, 1904, p. 86.

times employed for preserving their proper spacing. When the space is broad, the application of a bridge sustained by a collar or a crown cemented to one or more of the teeth is applicable. A removable plate has been utilized.

Fig. 516.

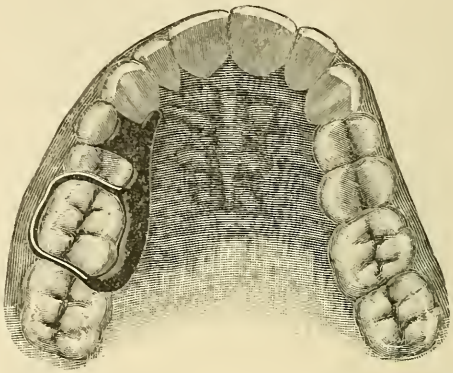

Removable Bridge.—Fig. 516 shows a removable gold bridge with porcelain front supplying a first right upper bicuspid that has been worn with comfort over eight years and is still doing good service. It is held in place with a spring-clasp attachment passing over the first molar, and a partial-clasp fitting the lingual surface

Fig. 517.

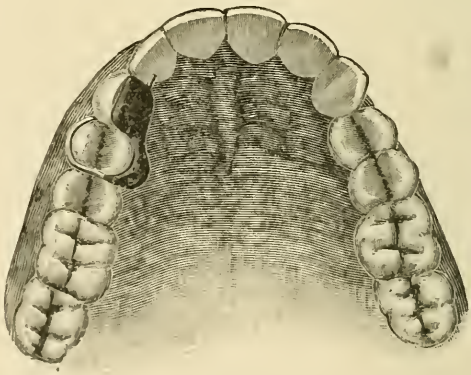

of the second bicuspid, the artificial tooth and the metal being shaped to fit accurately the interdental space.

Fig. 517 shows a similar removable bridge supporting a cuspid, being anchored with a spring-clasp attachment to a first bicuspid. The apparatus should be kept constantly in place, being removed

only for cleansing, otherwise the changing of the position of the teeth would narrow the space and prevent its readjustment.

In Fig. 518 is seen a removable device for retaining teeth that have been regulated, or that have become loosened from pyorrhœa

Fig. 518.

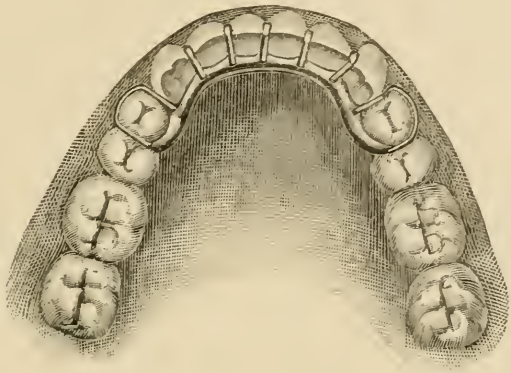

alveolaris. When used for the latter purpose it should be worn continuously. Before making the model on which to form the appliance, any of the teeth that are elevated should be dressed with a carborundum stone to correspond in length with the adjoining ones, taking care not to injure the pulp. A model of the arch of teeth is then to be made and trimmed accurately; and when only the lower incisors are to be retained, form a lingual base-wire, either round or half-round, to the curve of the arch, not touching the gum, and extending to a bicuspid on either side, to which the ends are anchored with spring-clasp attachments. Then make a mark on the model about one-sixteenth of an inch above the base-wire from one side of the arch to the other, and remove the base-wire. Fit a thin piece of metal, about one-eighth of an inch wide, and long enough to reach from the anchorage on one side of the arch to the anchorage on the other, to the lingual side of the teeth to be retained just below the line marked on the incisors. Use a pointed piece of wood or ivory to bend it into the depressions between the teeth. In effect this metal is similar to a partial-clasp, and is termed a continuous partial-clasp. The base-wire is now to be replaced with the partial-clasp between it and the model, the upper edge projecting a little above the base-wire. Arrange a short piece of small wire or flat metal, with the end curved in the form of a hook, to pass from the

base-wire over the incisive edge at the junction of two of the teeth, and to rest on the labial side, extending about one-sixteenth of an inch towards the gum, or as far as is necessary to retain them, fitting into the natural depression formed by their convex surfaces. If the appliance is to be worn constantly, as in cases of pyorrhœa alveolaris, the groove at the junction and cutting edge of the incisors can be deepened, if desired, sufficiently to let the curved portion of the wire rest flush with the edge, or the wire can be flattened with a carborundum stone on the outer or inner side for the same purpose.

As many arms of this kind as required can be fitted to place in the same manner, one end always extending onto the continuous partial-clasp to touch the base-wire. When the teeth are close together, one arm at the junction of two teeth will hold that side of each of them. An arm thus extending over the arch, on either side of each loose tooth, will prevent the teeth separating or rotating.

The arms and base-wire are joined with solder to the partial-clasp. When soft solder is used for the purpose, the arms may be held by pressing down on the curved portion with mouldine or a wad of cotton, and the soldering done with the soldering iron. If gold or silver solder is to be used, the model should be made of plaster and marble-dust (or their equivalent), and the several parts held in position by flowing some of the plaster mixture over the wires at any point that will not interfere with the soldering.

If the teeth have become separated, as is often the case in pyorrhœa alveolaris, they can be drawn together and the arms arranged to hold them in position in this manner. An extra arm may be added, or the end of an arm may be broadened by soldering a flat piece of metal to it in form to rest on the labial side of each of the adjoining teeth. When preferred, a short arm can be shaped to extend through the space and terminate in a slight hook to rest on the labial surface.

This appliance can be utilized for retaining cuspids, bicuspids, or molars.

Suspension Plate (Fig. 519).—When a loose incisor that has been retained with an appliance like the one last described becomes entirely separated from its alveolus, a plate tooth can be made to fill the space, and fastened with solder to the base-wire, by making a backing for it, and united with solder as in making the appliance.

Occasionally patients prefer to have the natural tooth replaced.

This can be done by sawing off the root, leaving the crown the proper length, and filling the nerve-canal. A backing is then fitted to the crown, holes drilled through the backing into the tooth, and long pins inserted.

If soft solder is used for uniting, the natural tooth will not be injured by the heat required, but if gold or silver solder be used,

Fig. 519.

which requires a higher temperature, the backing and pins should be held in place with wax and the tooth removed. Plaster and sand are then run about the parts to hold them in position while soldering. After soldering, the pins should be serrated with a sharp instrument, and the tooth cemented to place with oxyphosphate of zinc. When a plate tooth is used it should have a backing, and be held in place for soldering, as in making a metal plate.

This device I have termed a "suspension plate."* When the gums are unhealthy, it has several advantages over the ordinary plate. It is suspended from the teeth, stimulating the tissues by use, but causes no pressure on the gums, which should be avoided in cases of pyorrhœa alveolaris, especially while under treatment. It holds the loose teeth in position, making them useful, at the same time supporting the artificial ones.

When incisors have become elevated and much too prominent, as from pyorrhœa alveolaris, generally after their correction an appliance is required to be worn constantly or at night for their retention (Fig. 520).† For drawing them into position and retaining them, the appliance is made by cementing to each a collar with an eyelet; or a small wire eyelet can be cemented into the lingual side of the tooth as near the gum-line as practicable. For this a broad shallow pit is first cut into the concavity of the lingual surface of the tooth at the median line, as near the gum as the shape of the tooth will permit. In each side of the pit a small hole is drilled, pointing outward laterally towards the sides of the tooth to avoid the pulp, the holes being large enough to admit the ends of

* Jackson, Dental Cosmos, 1894, p. 904.

† Jackson, Trans. World's Columbian Dental Congress, 1893, vol. ii. p. 680.

the eyelet. This is made of wire, with the ends bent outward to extend into the pits, then serrated and cemented to its place; or in making the eyelet, the ends can be passed through a hole in a small round piece of metal, properly separated and soldered. A small-

Fig. 520.

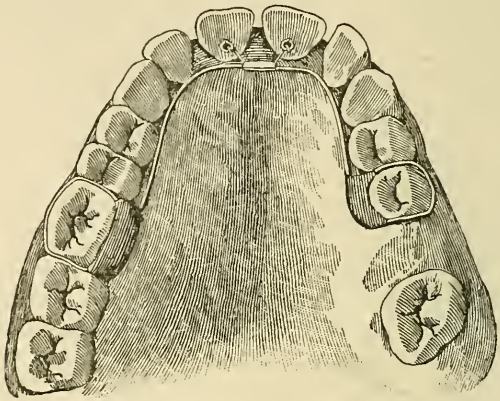

sized lingual base-wire is arranged at the gum line, following the curve of the teeth on either side, and held with spring-clasp attachments passing over the bicuspids or molars chosen for anchorage. Small wire hooks formed to pass through the eyelets described are soldered to the base-wire. A fixed device is applicable.

A permanent retaining device is usually objectionable in appearance. An inconspicuous appliance that is suitable in some cases for retaining teeth loosened by pyorrhœa alveolaris is shown in Fig. 521. It is made by swaging a continuous partial-clasp of thin metal to rest

Fig. 521.

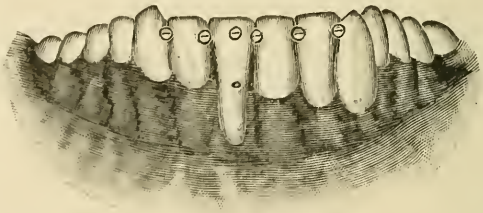

on the lingual side of the incisors extending near their incisive edge, crossing the loose teeth and passing on to adjoining ones that are sufficiently firm to support them. Solder is then flowed over the partial clasp to stiffen it.

A small hole is drilled with a pointed enamel drill between the teeth that are to be retained, the hole being rather near the incisive edge when the shape of the teeth will permit. In some cases when the tooth is especially loose, a hole can be drilled through the upper part of it. The partial-clasp is then applied, and by means of a slightly smaller drill the hole is extended through the metal while it is held in position. A small round or oblong head, similar to that of a common pin, is formed on a wire, the wire being of suitable size to enter the hole drilled between the teeth. A thread is cut on the wire, and in the hole in the continuous partial-clasp into which it is to screw. A small groove is made in the head of the screw to assist in turning it to place. In cutting the holes, those at the extremity of the continuous partial-clasp should be cut first, and screws applied to hold it in place, then other holes are drilled between the intermediate teeth and screws prepared. After all of the parts have been fitted to place, a rubber dam is applied, and a thin, slow-setting, oxyphosphate cement spread on the inner part of the continuous partial-clasp which is put in place. The screws should be speedily adjusted before the cement hardens.

If there is a separation between the teeth, a thin piece of metal can be drilled for a screw, arranged to span the space and project slightly onto their labial surface.

When there is to be much occlusal force, the metal of the continuous partial-clasp should be swaged to extend over the incisive edge of the teeth, and stiffened by flowing solder over it.

A similar device, more easily adjusted, was employed for Mr. C. The gum was much receded, the incisors loose and irregular. They were drawn into line and an accurate impression taken. A die was made and plate-metal swaged forming a continuous partial-clasp covering the lingual surface of the teeth in front of the first bicuspids, extending from the gum to the incisive edge. The metal was held in place and holes were drilled opposite the interdental spaces, some of the holes being above and others below the line of the cingulum of the teeth. Platinum wire was threaded loosely through the holes back and forth around the incisors and cuspids. Oxyphosphate of cement was forced downward, covering the front surface of the partial-clasp, which was pressed to place and the wire drawn tightly around each of the teeth from side to side and fastened. The device has given excellent satisfaction in holding the teeth firmly.

CHAPTER XXIX

GENERAL ORTHOPÆDIA OF THE FACE

The improvement of the contour of the features discussed in previous chapters include all changes that we are usually called upon to make, but sometimes other orthopædic treatment is necessary for improving the lips, nose, eyes, ears, and other parts. We should be thoroughly conversant with the methods of treatment of these conditions, but they are best treated by their respective specialists, and at this time will be only briefly described.

The Nose.—In general orthopædia of the face, probably the most important, after operations on the teeth and jaws, is the improvement of the shape of the nose, both for increasing the apertures for breathing, and for getting symmetry and facial harmony. This includes plastic operations on the cartilaginous and bony portions, and treatment with paraffin.

As has been pointed out, the shape of the nose is often much improved by the regulation of the teeth and alveolar process.

Fig. 402 illustrates a case with turned up, or retroussé nose. Pressure inward on the tissue just below the nasal septum drew the point of the nose downward, improving its shape and the general expression. A plastic operation was recommended to bring about this result, consisting in the removal of some of the redundant tissue from underneath the lip, the result being the binding of the parts at this location closer to the bone.

Dr. Roe* has devised a subcutaneous operation for correcting nasal deformities, doing away with the necessity of laying open the skin, which usually results in an unsightly blemish. With Dr. Roe's approval I quote the following from his writings:

"The importance of correcting nasal deformities, as well as other deformities of an unsightly nature, is evident from the conscious effect of such deformities in influencing the habits and thoughts of the person. On account of this distinguishing mark many are deterred from participating in the enjoyment of social life by the

* John O. Roe, American Medical Quarterly, June, 1899.

consciousness of the disadvantages under which they are continually laboring. So universally recognized are the disadvantages of a deformed and unsightly nose, that, even in ancient times, much attention was given to the shape and appearance of this important feature. It is said that among the ancient Persians no man who had a crooked or deformed nose was allowed to sit upon the throne, and children of royal blood were accustomed to have their noses moulded into perfect shape by the eunuchs who had charge of the royal offspring.

"Nasal deformities are usually divided into two main classes,—(1) idiopathic or congenital, and (2) traumatic or acquired. . . . But, from a surgical point of view, nasal deformities may more properly be divided into (1) the deformities which affect the bony portion of the nose, and (2) the deformities which affect the cartilaginous portion. This division can be clearly understood by reference to Fig. 522, which illustrates the anatomical conformation of the different parts of the nose. Deformities of the bony portion may be subdivided into (*a*) vertical, that is, those which distort the dorsal profile, in which the dorsal line is too convex, or too concave, and (*b*) lateral, that is, those which, when viewed from the front, present unusual deviation from the normal contour, whereby the bony portion may be either spatulated, or deflected. Deformities of the cartilaginous portion may be confined to the tip of the nose, to the shield-cartilages, or to the wings of the nose. They may therefore be subdivided into (*a*) those which affect the tip of the nose, whether excessive or defective in the amount of tissue, or distorted from its normal direction; and (*b*) those which affect the wings of the nose, which may be either collapsed or abnormally expanded.

FIG. 522.

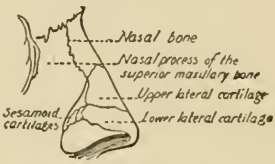

"In correcting deformities of the nose, we have to study the symmetrical relations of the different portions of the nose to one another rather than its proportionate relation to the face. A nose which is originally proportionate to the face will, if deformed by loss or displacement of tissue of any portion, appear very unsightly, while the same nose, made one or two sizes smaller, will, if its different parts are made perfectly symmetrical, have a more or less handsome appearance. Therefore, in correcting deformities of the nose, it is symmetry and not size that is to be considered.

"In this way it will readily be seen that the causes and conditions of the different deformities of the nose are so various that the operations required for the correction of these deformities must be equally varied, nor will any two cases be found exactly alike, and requiring the same operation.

"There are, however, general underlying principles governing the different operations which must be observed in order to secure the desired result. Thus, in the convex vertical deformity of the bony portion of the nose and excessive development of the tissues of the tip of the nose, the excessive or redundant tissues must be removed; whereas, in the concave vertical deformity of the bony portion of the nose or of defective development of the tip of the nose, the low portions must be filled in. Usually this can be done with tissue taken from the elevated portions, so as to make the nose symmetrical, or when this cannot be accomplished by the transfer of tissue from the elevated to the low portions, the latter can be filled in by tissue taken from some other portion of the nose, where it can be spared, and the elevated portions lowered so as to make the nose symmetrical.

"In many forms of distortion of the nose, especially those resulting from injury, there is almost invariably a displacement rather than a destruction of tissues, which require only to be replaced in their original position. It is important, however, that all of these operations be performed subcutaneously, in order to avoid the wounding of the skin and the consequent disfigurement. In some instances fracture of the nasal bones and of the septum, too, may also be necessary in order to restore the parts to a normal condition.

Fig. 523.

"Fig. 523. The convex vertical deformity consists of an undue projection of the anterior process of the nasal bones, giving to the nose an angular appearance.

"This deformity is the one most often found uncomplicated, and the operation for its correction is in the main performed as follows:

"The skin is first raised from the projecting portion by incising the wall of the nose from the inside of the nostrils through to the under side of the skin, care being exercised not to wound the skin. The opening is then enlarged sufficiently to admit the instrument required, which may consist of bone-scissors, rongier forceps, a

slender saw, or such other instrument as may be necessary according to the conditions present.

"In removing the projecting portions, great care must be exercised not to remove too much of the redundant tissue, lest a depression be left in the top of the nose which may be more unsightly than the original deformity. This mistake more readily happens in those cases in which the upper portion of the nasal passage extends all the way up into this projecting portion. In these cases the nasal passage is very easily opened on removing the projecting angular portion.

"Fig. 524. The concave deformity, sometimes termed saddle-back nose, consists in a lowering or flattening of the bridge of the nose, and may be either idiopathic or traumatic.

"The operations for the correction of this deformity are entirely different from the last, and consist in filling in the depressed por-

Fig. 524.

Fig. 525.

Fig. 526.

tions with flaps of tissue taken from the unduly prominent portion, subcutaneously, thereby lowering that portion at the same time.

"Fig. 525. The spatulated deformity may consist in a flattening of the dorsum and bulging outward of the nasal bones, or in a deflection of this portion of the nose to one or the other side.

"The correction of this deformity usually consists in sawing off portions of the bulging nasal bones, and placing these bone flaps, together with the attached soft tissues, in the median line in such a position as will fill in the depressed portion. This deformity is almost always associated with an enlarged condition of the end of the nose, which requires a corresponding amount of reduction in order to make the nose symmetrical.

"Fig. 526. Deflections of the bony portion of the nose may be due to an unequal growth of the two sides of the nose, or to injuries causing dislocations of the nasal bones, which, at the time of the injury, were not properly reduced.

"This deformity may be corrected by two different methods. First, by refracturing the bones and holding them in the desired position until firmly fixed. Second, by a subcutaneous osteoplastic operation, which consists in elevating the skin from the dorsum, sawing off with a slender saw the projecting portion, and placing it in the depression on the other side of the nose.

"Fig. 527. The abnormal enlargement of the tip or anterior portion of the end of the nose may be due to an excessive development of the tissues of this region, consisting of a redundant amount of cartilaginous tissue, or to an excessive amount of fatty tissue, or to both combined. This enlarged condition of the end of the nose is what is commonly known by the term 'snub-' or 'pug-nose,' and is frequently associated with the concave vertical deformity of the bony portion.

Fig. 527.

Fig. 528.

Fig. 529.

"The so-called pug- or snub-nose is corrected by removing the redundant tissue from the end of the nose subcutaneously. The operation is performed from the interior of the nostril. . . . The sensitiveness of the part is first deadened with cocaine, then the tissues are brightly illumined.

"Fig. 528. When the tissue of the lower portion of the nose is deficient in amount, there is a corresponding flattening of the end, termed 'frog-nose.' In extreme cases the end of the nose is completely flattened upon the face.

"This deformity is corrected by filling in the deficiency with tissue taken from adjacent parts, by plastic operations, performed subcutaneously, varied according to the requirements of the case.

"Fig. 529. Deviation of the cartilaginous portion of the nose may be due to the unequal vertical growth of the alæ, forcing the nose over to one side; or there may be unequal development in the thickness of the two wings, distorting the nose, and giving it the appearance of being deflected.

"The correction of this deformity consists in loosening the nose by subcutaneous incisions so that it can be placed in its normal position in the median line of the face, and held there until firmly fixed.

"Fig. 530. In the collapsed condition there is an undue flattening of the sides of the nose, interfering seriously with the nasal respiration. This may be due to defective or distorted development of the alæ, or to paralysis of the dilatores naris muscles, cicatricial contraction, etc.

"The operation in these cases consists in incising the lower shield-cartilage, and in some cases the upper shield-cartilage also, suffi-

Fig. 530.

Fig. 531.

Fig. 532.

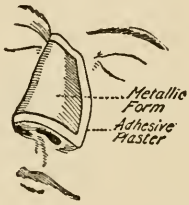

ciently to overcome their elasticity, and then to hold them in the desired position until fixation of the tissues has taken place.

"Fig. 531. Expansion or spreading of the wings of the nose is usually of congenital origin, and consists of a marked distention or bulging outward of the lower shield-cartilages, giving the end of the nose a very broad, prominent, and inordinately flat appearance. On examination, however, it will be found that there is but little thickening of the tissues, the concavity of the interior being proportionate to the extreme bulging.

"The operation for the correction of this condition consists in overcoming the elasticity of the wings by incisions through the shield-cartilages simultaneously with a slender knife in several places, and then holding them in place by an external form until they are firmly fixed in the desired position. In some instances the cartilage is so redundant that a portion of it must be excised."

In order to maintain symmetry, after any of these operations it is important that the tissues be held in the desired form until healing has taken place. Adhesive plaster and a metallic form are usually applied to the surface of the nose, as illustrated in Fig. 532. An internal splint is sometimes employed, as after an operation on the

septum and nasal bones. A dressing is applied to the interior of each nostril in the form of a splint wound with cotton, so as to maintain the bone in an elevated position, and at the same time to hold the fractured septum in a vertical position until healed.

In Dr. Roe's writings may be found many photo-engravings illustrating cases before and after correction.

Fig. 533 shows the case of a young lady with angular deformity of the nose.* The improved condition after operation is shown in Fig. 534. Fig. 535 illustrates a young man with a "pug-nose."† Fig. 536 shows the improved condition.

Paraffin Treatment for Deformities.—Some malformations of the nose and other parts are corrected by the subcutaneous injection of paraffin. It must be admitted that the matter of paraffin treatment is yet in a tentative state. In 1900 Gersuny, of Vienna,‡ first described the operation in the treatment of other portions of the body, stating that he had been conversant with the method a number of years. Quinlan says that solidifying oils were introduced subcutaneously for the relief of pain by Dr. Corning, of New York, in the eighties. Smith,§ Quinlan,‖ and others have described methods of building up and correcting deformities, as filling congenital gaps, overcoming changes resulting from cicatrices following loss of tissue, congenital, traumatic, and specific affections of the external nose, hollow cheeks, and the various depressions attended by facial deformity.

Heath, of St. Paul, describes in "American Medicine" its use in the treatment of a case where the entire cartilaginous septum was destroyed.

Haskins employs paraffin prosthesis to prevent deformity after mastoid operations.

Quinlan describes the technique and shows an instrument for the injection of paraffin. He points out the difficulty of introducing it into the desired part, and the danger from embolism of the lungs when the paraffin is injected in a liquid state. This they claim to obviate by injecting it in a solid or semisolid form.

---

* Roe, Medical Record, July, 1891.

† Ibid., June, 1887.

‡ Moskowitz in Wiener Klinische Woch., No. 25, 1901.

§ Smith, New York Medical Journal, May, 1902.

‖ Quinlan, Laryngoscope, August, 1902.

Fig. 533.

Fig. 534.

Fig. 535.

Fig. 536.

Hollow Cheeks.—When the cheeks are deficient in fulness, the contour can generally be improved by the insertion of a *plumper*, attached to the teeth on one or both sides of either the upper or lower arch. If the natural teeth are absent, plumpers can be made by forming an extension of rubber in connection with a full or partial-plate, but when the natural teeth are *in situ*, a spring-clasp can be fitted to one or more of them on the lingual surface, with the ends extending to the buccal side to enter a pad of vulcanite shaped in any form desired. Both the upper and lower surfaces of the pad may be made convex, or be concave on the occlusal side. Fig. 537 illustrates a device that was used in the upper arch for Dr. C. One cheek was considerably depressed, and the application of the plumper caused the cheeks to harmonize.

Fig. 537.

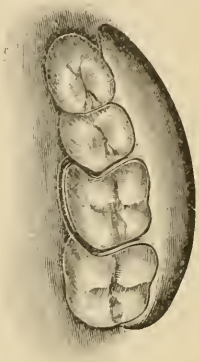

Eye.—Plastic operations upon the eyelids for improving the facial expression are principally employed for Mongolians. Canthoplasty is an operation on the canthus of the eye, recommended by Ammon, when the eyelids are not sufficiently cleft.

A fold of skin is sometimes formed over the inner angle of the eye termed epicanthus. This is corrected by the removal of a rhomboidal piece of skin, about an inch in length and nearly two-thirds of an inch in width at its greatest part. It is excised from the side of the nose. The skin at both sides of the wound is carefully raised, approximated, and held together by silk sutures. Immediate union is encouraged by the use of plaster strips.*

The correction of squint, or strabismus, and applying artificial eyes after enucleation should be mentioned.

Ear.—Deformity of the auricle is sometimes improved by surgical treatment. When the ear is too prominent, some of the cartilaginous concha can be removed, for depressing the helix and antihelix. In young children the application of bandages is effective.†

Kingsley describes in detail the making of artificial lip, nose, and ear.‡

---

* Knapp, Archives of Ophthalmology, vol. iii. p. 53.

† Dench, Diseases of the Ear, 1903, p. 173.

‡ Kingley's Oral Deformities.

Cleft Palate and Harelip.—Staphylorrhaphy, an operation for uniting a cleft palate, was first performed by a dentist, Le Mounier, in 1764. Such a small percentage of cases have proved successful, that some surgeons oppose the operation, claiming it to be impracticable; but it is now encouraged and performed successfully, notably by Brophy.* When cleft palate is accompanied with harelip, the fissure of the lip and the nasal and maxillary bones are united. Kingsley † treats of these defects surgically, and mechanically by the use of obturators and artificial vela.

---

* Brophy, Transactions of the World's Columbian Dental Congress, vol. ii. p. 532; Dental Cosmos, 1901, p. 867.

† Kingsley's Oral Deformities.

APPENDIX

The following page plates illustrate appliances that have been used in practice for the regulation and retention of the teeth. There are many variations in the anchorage, location, and combination of the base-wires, and arrangement of the springs. They are brought together, classified, and presented, that their examination may assist the operator or the student by suggesting methods of procedure. The descriptions are necessarily brief. The anchorage of some of the appliances would be improved by additional partial-clasps.

LIST OF PLATES

PAGE PLATES OF APPARATUS USED IN PRACTICE

PLATE I

Arch, Lower, Expansion of, Laterally

A. An appliance for the lateral expansion of the lower arch, anchored by spring-clasp attachments over the first bicuspids and first molars, with partial-clasps fitting other teeth. A lingual spring base-wire enters the centre of the anchorage portion, permitting a change of angle for expanding either the distal or front part of the arch.

B. A device for lower lateral expansion. It is retained by spring-clasp attachments to the second bicuspids and partial-clasps fitting the adjoining teeth. Two springs are attached in the anterior portion of the anchorage for moving incisors outward.

C. An apparatus for lower lateral expansion, with a spring base-wire bent into loops located back of the incisors.

D. An appliance with a spring base-wire shaped into loops, anchored to the permanent molars. A spring is attached for moving the incisors outward.

E. A device for the lateral expansion of the arch, with a finger-spring attached for moving the incisors outward.

F. An appliance with cast-metal sides connected with a lingual spring base-wire having a U-shaped loop arranged at the median line and anchored by wire-clasps. Action is caused by opening the loop from time to time. To each anchorage portion a spring is attached extending in a curve to the opposite side of the arch for moving the incisors outward.

Plate I

A

B



C



D

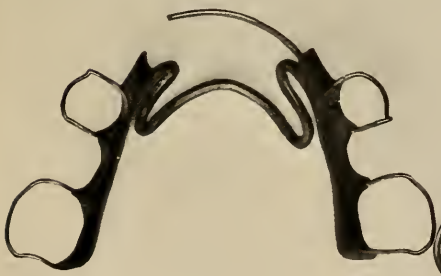

E

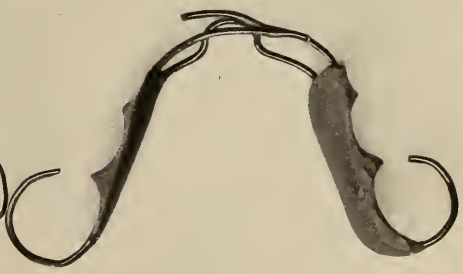

F

Plate II

A

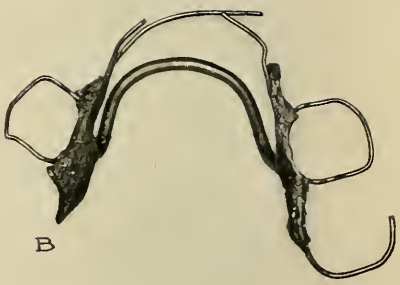

B

C

D

E

F

PLATE II

Arch, Lower, Expansion of, Anteriorly

A. An appliance with a lingual spring base-wire resting low in the arch, the ends entering the centre of the anchorage portion from below upward. A finger-spring is attached in the anchorage extending forward to expand the anterior part of the arch. The free end of the spring was retained in position by passing under a lug on a collar cemented to one of the incisors. Springs for this purpose should always be retained, using collars on one or more teeth as required.

B. A device with a lingual base-wire. A long and a short finger-spring extends forward from the anchorage for expanding the arch.

C. A lingual base-wire is anchored by spring-clasp attachments to a first permanent molar and a second deciduous molar. Two springs extend forward from the anchorage in a curve, terminating on the opposite side of the arch for moving incisors outward.

D. An apparatus anchored by spring-clasp attachments over the first permanent molars, with two springs extending forward for anterior expansion.

E. A device anchored to the second deciduous molars, with springs extending forward to force the incisors outward.

F. An appliance with a lingual base-wire anchored by spring-clasp attachments to the second bicuspids. The anterior part of the base-wire was arranged to leave a little space between it and the gum. A semicircular spring with two U-shaped loops was formed to the lingual side of the incisors, passing under lugs on collars, the loops resting between the base-wire and the gum, and the ends soldered by the ends of the base-wire in the anchorage portion. Action was effected by opening the loops from time to time.

PLATE III

Arch, Upper, Expansion of, Laterally

A. An appliance with a palatine spring base-wire crossing the distal part of the arch. The ends of the wire were bent forward forming arms and shaped to enter the anchorage. The arch was expanded by bending outward the arms as required.

B. A device with a palatine base-wire located in the distal part of the arch. Force is got by bending outward the anterior portion, or arms.

C. An appliance with a palatine base-wise arranged to cross the distal part of the arch where the arch is broad enough, the ends bent forward and soldered in the anchorage. Action is exerted by bending outward the front parts of the anchorage.

D. A palatine spring base-wire with a U-shaped loop for the lateral expansion of the arch. The loop points backward and the ends of the base-wire are bent backward to enter the anchorages. Force is caused by opening the loop a little at a time.

E. A looped spring base-wire. The loop at the median line is arranged to point forward. The ends are bent forward in a gentle curve to be soldered in the anchorage. The ends of a looped spring are attached in the anterior part of the anchorage for moving incisors outward.

F. A jack-screw arranged for the lateral expansion of the arch, anchored by partial-clasps and spring-clasp attachments.

Plate III

A

B

C



D

E

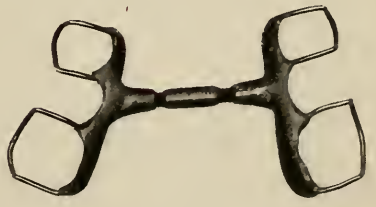

F

Plate IV

A

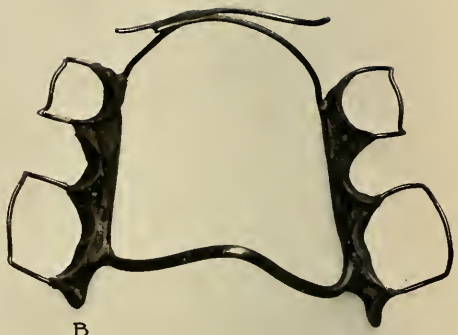

B

C

D

E

F

PLATE IV

Arch, Upper, Expansion of, Anteriorly

A. An appliance with a palatine base-wire anchored by spring-clasp attachments over the second bicuspids. A spring extends forward from the anchorage on either side of the arch to rest on the lingual side of the incisors for moving them outward. The springs are retained by lugs on collars cemented to the teeth.

B. A palatine base-wire arranged to cross the distal part of the arch with the ends bent forward. A spring is attached to each anterior anchorage portion and formed to follow the lingual curve of the arch to the opposite side where it is retained by a lug on a collar. Action is caused by bending the springs forward. The anterior part of the arch is expanded laterally by bending outward the anchorage portions.

C. A device with a palatine base-wire and a semicircular spring with U-shaped loops. The loops are opened slightly at a time for getting force, expanding the anterior part of the arch. An artificial tooth is supported by the anchorage.

D. An apparatus with a palatine base-wire and semicircular spring with loops. To the anterior part of the spring is attached a curved spring which was utilized for evening the circle of the incisors.

E. An appliance similar to the one last described, with a spring attached to the semicircular spring for moving outward incisors and cuspids.

F. An appliance for expanding the anterior part of the arch similar to the ones previously described. The palatine base-wire is arranged to cross the distal part of the arch, and the anterior portion of the anchorage is bent outward for expanding the arch laterally.

PLATE V

Arch, Expansion of, Unilaterally

A. An appliance having a lingual spring base-wire with a loop arranged on one side for expanding the lower arch unilaterally.

B. A palatine spring base-wire with one end curved backward to be attached in the anchorage, and the other end curved forward for moving outward bicuspids, the end being retained by spring-clasp attachments.

C. A palatine spring base-wire with a U-shaped loop at the median line.

D. A lingual spring base-wire strongly anchored on one side with spring-clasp attachments and a metallic plate shaped to cover a portion of the palatine arch. The other end was anchored by a spring-clasp attachment over a bicuspid to be moved.

E. An expanding device with a palatine spring base-wire in the form of a loop. Plate metal was shaped to cover a portion of the palatine arch to strengthen the anchorage on one side for moving outward a bicuspid and a molar on the opposite side.

F. A palatine base-wire in the form of a loop, strongly anchored to the teeth by spring-clasp attachments and plate metal covering a portion of the arch, used for moving outward a molar and two bicuspids on the opposite side of the arch.

Plate V

A

B

C

D



E



F

Plate VI

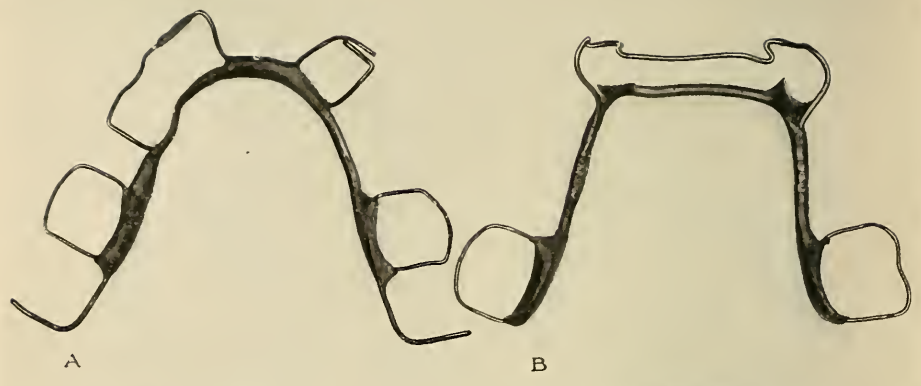

A

B

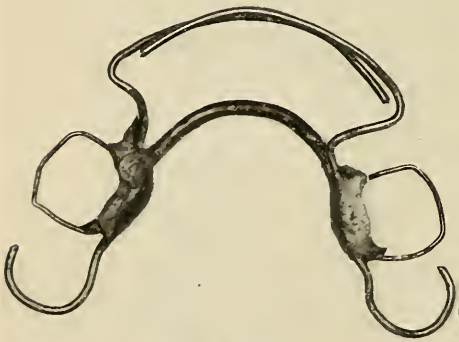

C

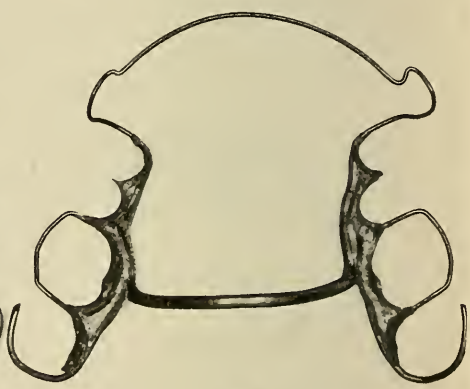

D

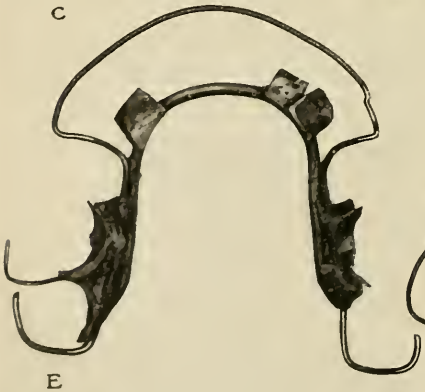

E

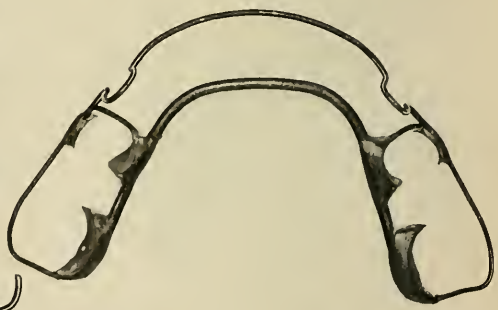

F

PLATE VI

Arch, Contraction of

A. A lingual base-wire device with a continuous spring-clasp arranged for moving inward a cuspid and the bicuspids on one side of the arch. A prominent cuspid on the opposite side was moved inward by a spring bent twice at right angles with the parallel arms extending over the arch either side of the cuspid and bent towards each other to rest on the labial surface near the gum. The teeth were moved inward by bending the outer parts of the springs nearer to the base-wire.

B. A lingual base-wire with a semicircular spring and U-shaped loops, for moving lower incisors inward.

C. A device for contracting the anterior part of the lower arch. Two finger springs are arranged to extend from a lingual base-wire to the buccal side, then forward in a curve to the opposite side of the arch.

D. An appliance with a palatine base-wire and semicircular spring with loops for the contraction of the upper arch.

E. A lingual base-wire with looped spring. To the anterior part of the base-wire are soldered pieces of plate-metal for assisting the anchorage and evening the teeth as they were moved inward.

F. An apparatus with a lingual spring base-wire, continuous spring-clasps and a semicircular spring with U-shaped loops for the general contraction of the arch. The front teeth are moved inward by closing the loops of the spring a little at a time, and the arch contracted laterally by bending together from time to time the sides of the base-wire.

PLATE VII

Incisors, Lower, to move Outward

A. A lingual base-wire device. A curved finger-spring is attached in the anchorage on one side. The free end of the spring is arranged to pass under a lug on a collar cemented to one of the incisors to be moved.

B. A lingual base-wire and finger-spring, anchored by spring-clasp attachments to the second bicuspids.

C. A lingual base-wire and finger-spring arranged for moving outward the lower incisors and a cuspid. A second spring is attached for moving inward a bicuspid.

D. A lingual base-wire with the arms projecting backward and upward to enter the anchorage portions. From the front of the anchorage on the right side a spring extends forward to move outward a deciduous cuspid and a biscupid. A spring is attached in the anchorage on the left side for moving outward instanding incisors. The arch is expanded laterally by bending outward the arms of the base-wire.

E. An appliance with a lingual base-wire, a finger-spring for moving outward the incisors, and two short springs for moving outward the cuspids.

F. A lingual base-wire, a curved spring for moving outward the incisors, and two springs extending forward for moving outward the cuspids and bicuspids.

Plate VII

A

B

C

D

E

F

Plate VIII



A

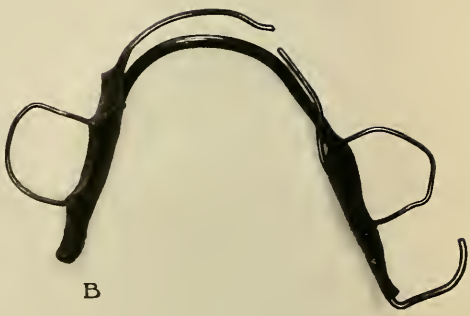

B

C

D

E

F

PLATE VIII

Incisors, Lower, to move Outward

A. An appliance for moving a crowded incisor outward. It has a lingual base-wire and a finger-spring. To the finger-spring is attached a secondary spring with arms passing over the arch either side of the tooth to be moved; the arms are separated to broaden the space. The ends of the spring are bent outward and backward to press on the adjoining teeth to assist the action of the finger-spring.

B. A lingual base-wire with two finger-springs attached, one for moving outward the incisors, and the other for moving outward a cuspid and bicuspid.

C. A device with a lingual base-wire and two finger-springs extending forward in a curve, one from either side of the arch. The ends of the springs in this and in similar devices are retained by passing under a lug on a collar cemented to one or more of the teeth.

D. A lingual spring base-wire with the ends attached in the centre of the anchorage portion. Two finger-springs extend to the front of the arch for moving the incisors outward. A curved spring is arranged to move outward a cuspid, at the same time the arch is expanded laterally by the action of the spring base-wire.

E. An appliance with a semicircular spring and U-shaped loops. The loops are arranged to rest between the base-wire and the gum. Action is caused by opening the loops.

F. A lingual base-wire and semicircular spring with U-shaped loops for moving lower incisors outward.

PLATE IX

Incisors, Upper, to move Outward

A. An appliance with a palatine base-wire. A spring extends forward from the anchorage on one side to pass under a lug on a collar cemented to one of the incisors for moving it outward.

B. A broad palatine base-wire with a curved finger-spring extending forward from the anchorage on one side to be retained by a lug on a collar.

C. An appliance with a long curved finger-spring extending from the anchorage over the arch at the junction of two of the teeth to the buccal side, then forward to pass under a hook on the labial side of a collar cemented to the tooth to be moved. This appliance was used for moving outward an incisor in case of close bite.

D. A device with a palatine base-wire and a long finger-spring extending forward to rest on the lingual side of incisors, passing under a lug on a collar.

E. An appliance with a long finger-spring for moving incisors outward. To the end of the spring is soldered an additional spring for lengthening it.

F. An apparatus with a palatine base-wire for moving incisors outward and expanding laterally the anterior part of the arch. After the incisors are moved outward by the finger-spring the anchorage portions are bent outward, effecting the lateral expansion.

Plate IX

A

B

C



D

E

F

Plate X

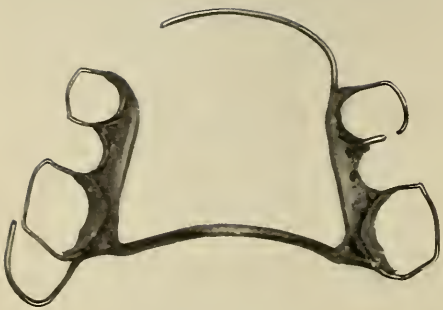

A

B

C

D

E

F

PLATE X

Incisors, Upper, to move Outward

A. An appliance with a palatine base-wire. To the anterior portion of the anchorage is attached a curved finger-spring for moving the incisors outward.

B. An appliance with a curved finger-spring and a palatine spring base-wire with a U-shaped loop in the centre. After the incisors are moved outward with the finger-spring, the loop is broadened gradually for the lateral expansion of the arch.

C. A palatine base-wire located in the distal part of the arch with the ends projecting forward in the anchorage portions. To the front of the anchorage on each side is attached a curved finger-spring for moving the incisors outward. The anchorage portions are then bent outward for expanding the arch laterally.

D. An appliance with finger-springs for moving outward lateral incisors and cuspids.

E. A device with a rigid palatine base-wire and two long curved finger-springs for moving incisors outward.

F. A palatine base-wire with curved finger-springs. The anchorage consists of spring-clasp attachments and wire-clasps.

PLATE XI

Incisors, Upper, to move Outward

A. A device with a palatine base-wire and semicircular spring with loops for moving incisors outward. The spring is retained by collars with lugs cemented to the incisors.

B. A palatine base-wire and semicircular spring with loops, anchored by partial-clasps and wire-clasps around the deciduous molars.

C. A device with a semicircular spring and loops. The base-wire is arranged to cross the distal part of the arch. When the incisors were moved outward, the anchorage portions were bent slightly outward for expanding the arch laterally.

D. An appliance with a palatine base-wire and semicircular spring. The anchorage is arranged to include several teeth. Generally this is essential.

E. A palatine base-wire and semicircular spring for moving incisors outward, anchored by spring-clasp attachments and a finger-spring extending from either side.

F. A palatine base-wire and semicircular spring with loops. To the spring was soldered a wire clip to rest on the distal surface of a cuspid for moving it forward at the time the incisors were moved outward.

Plate XI



A

B

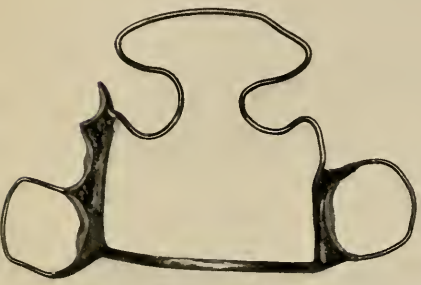

C

D

E

F

Plate XII

A

B

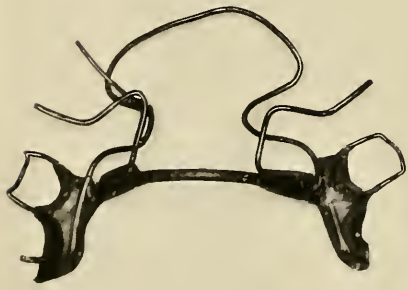

C

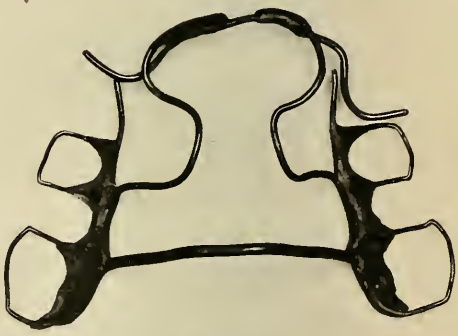

D

E

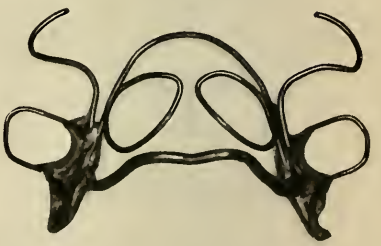

F

PLATE XII

Incisors, Upper, to move Outward

A. An appliance with a palatine base-wire located back in the arch. To the anchorage in the anterior part is attached the ends of a semicircular spring with U-shaped loops. The spring is held in position on the incisors with collars and lugs. Two finger-springs are also attached, one on either side, for moving outward the first bicuspids.

B. A strong palatine base-wire supporting a semicircular spring with loops, and also two springs for moving bicuspids outward and backward.

C. A palatine base-wire anchored to the second bicuspids and molars. Springs are attached on either side for moving the first bicuspids backward, or forward, as the incisors are moved outward.

D. An appliance with a palatine base-wire and semicircular spring strongly anchored. A secondary spring is attached to the front of the semicircular spring for moving the cuspids outward with the incisors.

E. An apparatus with a palatine base-wire. A semicircular spring with U-shaped loops and a finger-spring are attached for moving outward a central and lateral incisors and a cuspid on one side of the arch that had a lingual occlusion. The anchorage portions were built up for opening the bite.

F. A device with a palatine base-wire and a semicircular spring with complete or circular loops for moving incisors outward. Two finger-springs are also attached for moving inward prominent cuspids.

PLATE XIII

Incisors, Upper, to move Outward, to move Outward Bodily

A. An appliance for increasing the space and moving outward an incisor when there is a close bite. It is made with a labio-buccal spring base-wire having a U-shaped loop. To the base-wire is attached a spring, bent twice at right angles with the width between the parallel arms equal to the width of the tooth. These pass over the arch and the ends are bent towards each other to rest on the lingual side. Force is caused by curving the ends of the spring closer to the base-wire a little at a time.

B. An inclined plane attached to a lingual base-wire. It was applied in the lower arch for moving outward an upper incisor.

C. A device with a palatine base-wire and semicircular spring with loops. The spring is retained by lugs on collars cemented to the incisors to be moved.

D. An appliance with two finger-springs for moving incisors outward. The arch was expanded laterally by bending outward the ends of the base-wire.

E. An apparatus for moving incisors outward bodily. Two looped springs are attached in the anchorage, with the ends shaped to rest against spurs for moving forward a sliding lingual base-wire. The front of the base-wire passed between two horizontal planes soldered to the lingual side of a metal cap that was cemented to the incisors.

F. An appliance for the outward bodily movement of the incisors. After the incisors were moved outward the arch was expanded laterally by opening the U-shaped loop in the palatine spring base-wire.

Plate XIII

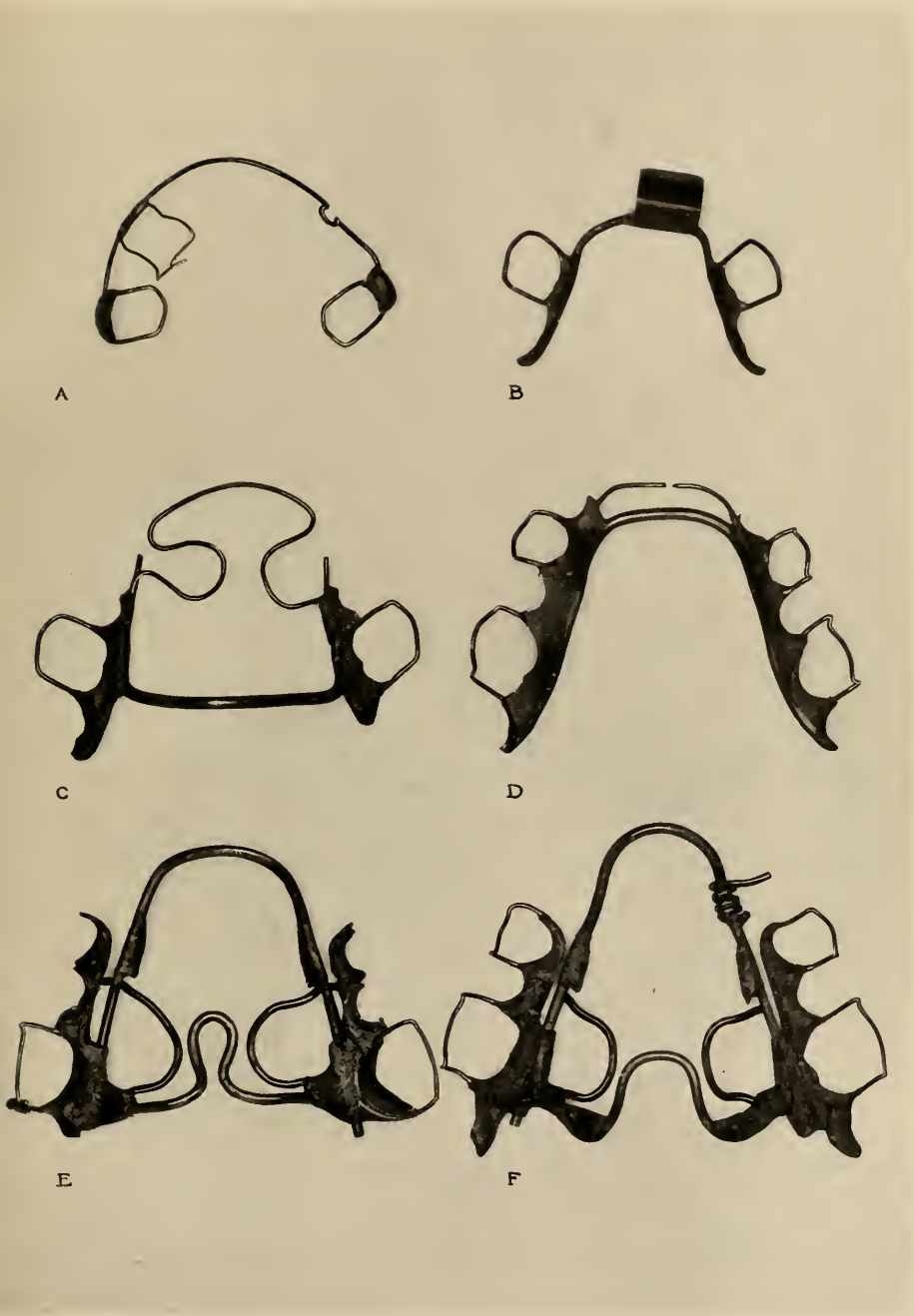

Plate XIV

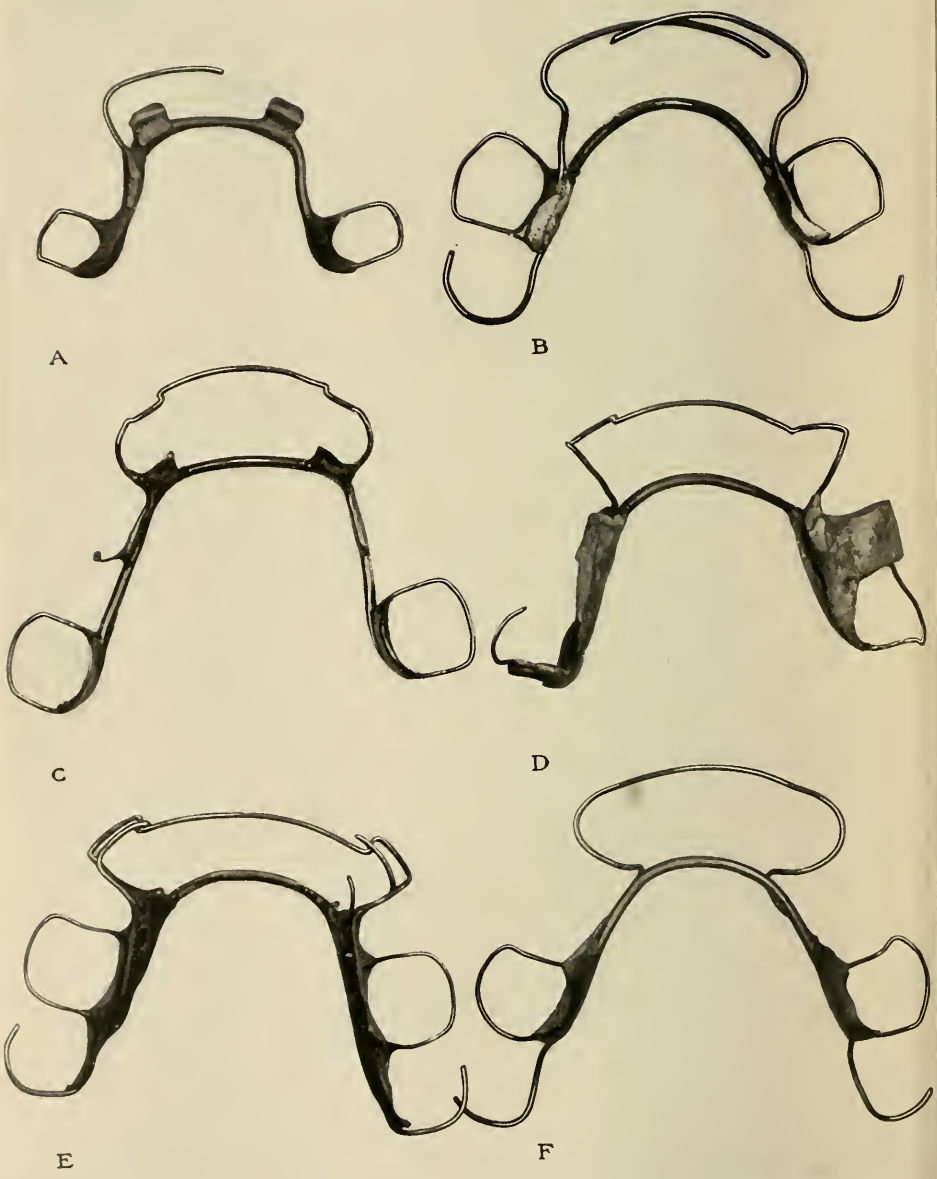

PLATE XIV

Incisors, Lower, to move Inward

A. A lingual base-wire anchored by spring-clasp attachments and pieces of plate-metal projecting forward to rest on the lingual faces of the laterals. A curved spring is attached on one side shaped to pass over the arch following the labial curve to cause force on prominent incisors.

B. A device with a lingual base-wire, and two finger-springs extending over the arch to force inward prominent front teeth.

C. A lingual base-wire anchored by spring-clasp attachments in the distal part of the arch. To the base-wire in the front are attached pieces of plate-metal for strengthening the anchorage. Additional partial-clasps should be employed. Force for moving inward the incisors is got by a labial-spring with U-shaped loops passing over the arch to be attached to the base-wire.

D. An appliance with metal extending on to the grinding surface of the anchorage teeth for opening the bite. To the anterior part is attached a semicircular spring with loops for moving inward lower incisors that had a labial occlusion.

E. An apparatus with a lingual base-wire and semicircular spring with loops for moving inward incisors and cuspids. Additional force was caused on the cuspids by curved finger-springs extending from the base-wire, one on either side to rest on their mesio-labial surface.

F. A lingual base-wire, and a semicircular spring passing in front of the incisors and cuspids for moving them inward. The loops of the spring were arranged to rest inside of the arch between the base-wire and the gum.

PLATE XV

Incisors, Upper, to move Inward

A. An appliance with a double-curved spring shaped to pass over the arch and rest on the labial side of a prominent incisor for forcing it inward.

B. An appliance with a lingual base-wire, and spring for moving inward a prominent incisor, at the same time retaining teeth on the sides of the arch that had been moved outward.

C. A lingual base-wire with a double-armed spring attached to the anterior part. The arms of the spring are passed over the arch either side of a prominent incisor at the junction with the adjoining teeth, with the ends bent towards each other to rest on the labial side for forcing the tooth inward.

D. An appliance with a lingual base-wire ; the ends are formed to enter the centre of the anchorage. To the anterior part of the base-wire is attached plate-metal shaped to the circle it is desired the incisors shall assume. To the plate-metal is attached a double-curved spring extending over the arch at the median line and resting on the labial side of the incisors. Action of the spring is caused by bending the end backward. The arch is expanded laterally by bending outward the ends of the base-wire.

E. A device with a palatine base-wire. To the anterior part of the anchorage is attached a spring shaped to pass over the arch at the junction of the teeth to the buccal side, then forward to rest on the labial faces of the incisors for forcing them inward.

F. A palatine base-wire with a finger-spring passing to the front of the incisors. For anchorage, wire-clasps are used on one side of the arch and spring-clasps on the other.

Plate XV

A

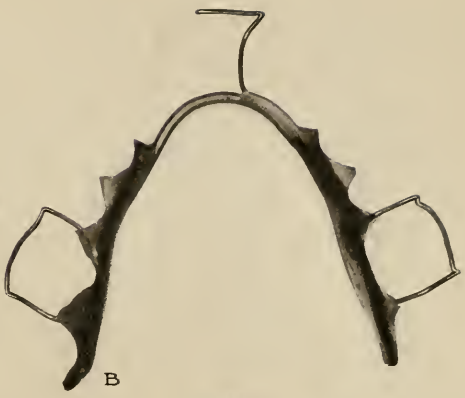

B

C

D

E

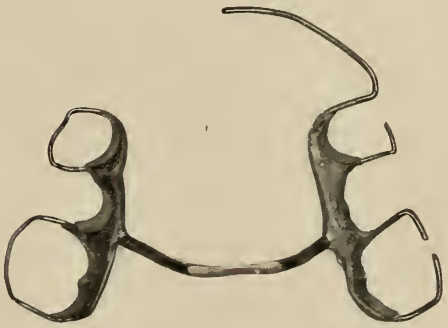

F

Plate XVI

A

B

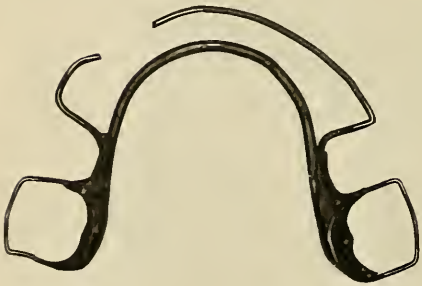

C

D

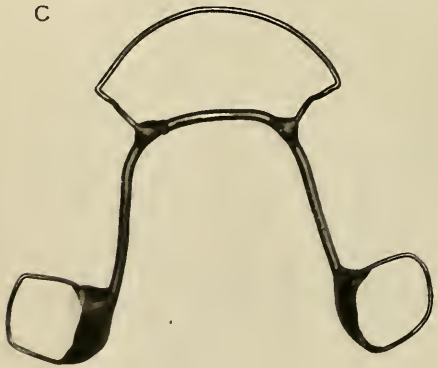

E

F

PLATE XVI

Incisors, Upper, to move Inward

A. An appliance with a palatine spring base-wire in the form of a loop. To the anchorage is attached a finger-spring, shaped to pass over the arch to the buccal side, then to extend forward following the labial curve of the teeth to the opposite side of the arch. The incisors are moved inward by reshaping the spring from time to time. When required, the arch is expanded by opening the loop of the base-wire.

B. A palatine base-wire, with a finger-spring attached to the anterior part of the anchorage, shaped to extend to the opposite side of the arch following the labial curve. To the free end of the spring is soldered a piece of plate-metal bent into an S-shape for hooking over the edge of one or more of the incisors to prevent the spring from pressing against the gum as force is applied. A spring with a partial-clasp is attached on the opposite side of the arch for moving outward a first bicuspid.

C. A lingual base-wire with a spring attached on either side of the arch, shaped to extend to the buccal side, then forward to move prominent incisors and cuspids inward.

D. An appliance with a lingual base-wire, and semicircular spring with loops for moving inward four incisors.

E. A lingual base-wire and semicircular spring with loops used for moving inward six front teeth. The anchorage should generally be strengthened by additional partial-clasps.

F. A palatine base-wire with semicircular spring and U-shaped loops for moving inward six upper teeth. The loops are arranged to extend upward under the lip. Action is effected by closing the loops a little at a time. The anchorage is fortified by extending wire-clasps to the distal side of partially erupted molars.

PLATE XVII

Incisors, Upper, to move Inward

A. An appliance with a semicircular spring and U-shaped loops for reducing upper anterior protrusion before the eruption of the first bicuspids. It was anchored to the first permanent molars and second bicuspids.

B. A device with a semicircular spring and U-shaped loops for moving inward the six front teeth, the first bicuspids having been extracted. It was anchored to the second bicuspids, first and second molars. Action was caused by closing the loops of the spring slightly at a time.

C. An apparatus for moving inward incisors, at the same time expanding laterally the anterior part of the arch. A palatine base-wire is arranged to cross the distal part of the arch where it is broad enough. To the anchorage on each side is attached one end of a semicircular spring with U-shaped loops. The loops are closed for forcing the incisors inward, and the front part of the anchorage is bent outward for expanding the arch as required.

D. A palatine base-wire is arranged to cross the distal part of the arch, with the ends extending forward in the anchorage portion for anterior lateral expansion ; at the same time prominent incisors are moved inward by a semicircular spring.

E. An apparatus with a lingual base-wire, used for moving inward prominent incisors and cuspids. It was strongly anchored. The incisors were moved inward, at the same time rotating them by a semicircular spring with U-shaped loops, arranged to cross the labial faces of the incisors with the ends extending over the arch to be attached to the base-wire. The cuspids were moved inward by finger-springs.

F. A device with a lingual base-wire and springs, used for moving inward incisors, at the same time moving inward and backward prominent cuspids.

Plate XVII

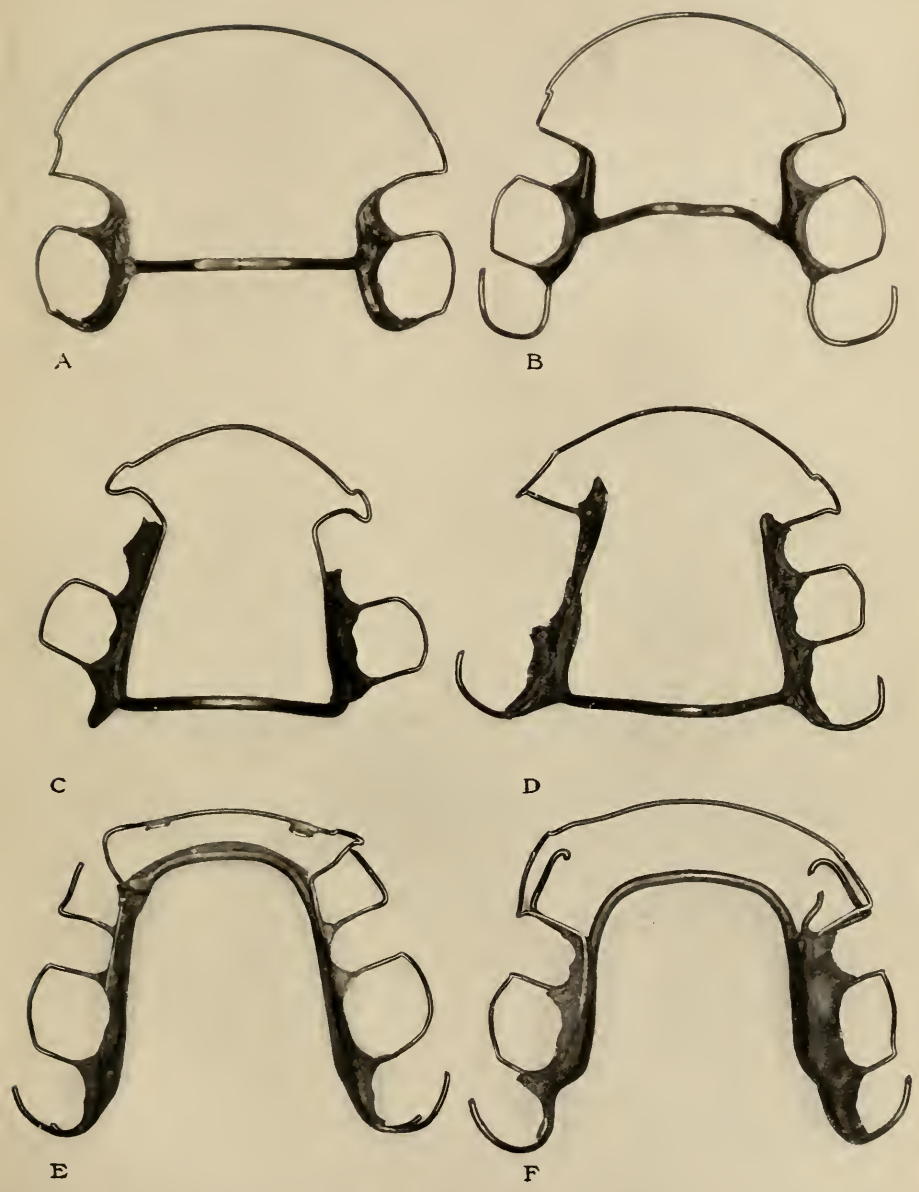

Plate XVIII

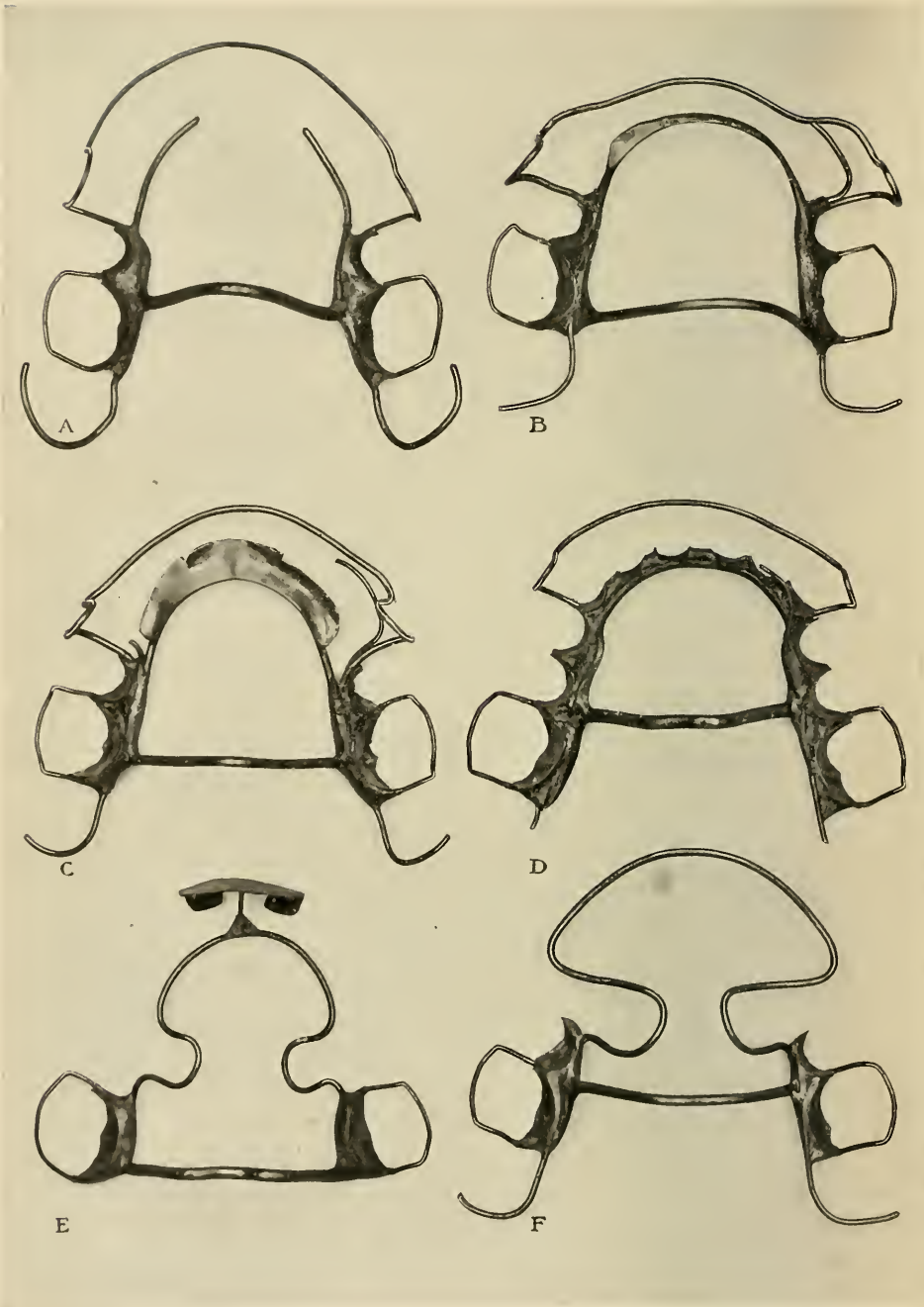

PLATE XVIII

Incisors, Upper, to move Inward

A. An appliance with a palatine base-wire and semicircular spring for moving incisors inward. Action is caused by closing the loops of the spring. Two finger-springs are attached in the anterior part of the anchorage to rest on the lingual side of the incisors for evening them.

B. A device with both a palatine and a lingual base-wire. A semicircular spring is arranged to move the incisors inward and to rotate them by forcing them against the lingual base-wire.

C. An appliance for moving inward prominent incisors and rotating them, made with a lingual and a palatine base-wire, and a semicular spring with U-shaped loops. To the lingual base-wire is attached a thin piece of plate-metal, suitably shaped to project forward and rest on the lingual side of the teeth for evening them as pressure is caused by the spring.

D. A device with a lingual and a palatine base-wire for moving incisors inward and rotating them. It has a partial-clasp fitted to each of the teeth.

E. A T attached to a semicircular spring with U-shaped loops resting over the palatine arch.

F. An appliance with a semicircular spring and U-shaped loops. The spring is arranged to rest on the labial faces of the incisors and pass to the lingual side, where the ends of the loops are attached to the anchorage.

PLATE XIX

Incisors, Rotation of

A. An upper appliance with a lingual base-wire ; a double-curved spring is attached to the anterior part arranged to pass over the arch and rest on the labial side of an incisor for forcing it against the base-wire and rotating it.

B. A lower appliance with a lingual base-wire and spring. The spring is shaped to extend over the arch and press inward on an incisor for its rotation.

C. Two springs, anchored by spring-clasp attachments. Each is used independently for the rotation of a tooth in connection with a tube and collar. The one on the left side is shaped to the labial side of the arch, and the one on the right for the lingual side.

D. Two lingual springs used in connection with a collar and tube for the rotation of the incisors. One of them is provided with a U-shaped loop to assist in adjustment.

E. Two lingual springs with U-shaped loops supported by spring-clasp attachments. The free ends of the springs are bent into hooks to engage with eyelets on the mesio-lingual or disto-lingual sides of collars cemented to the incisors to be rotated.

F. A lingual base-wire, to the anterior of which is attached two small looped springs arranged to hook into eyelets on the disto-lingual side of collars cemented to the central incisors for rotating them.

Plate XIX

A

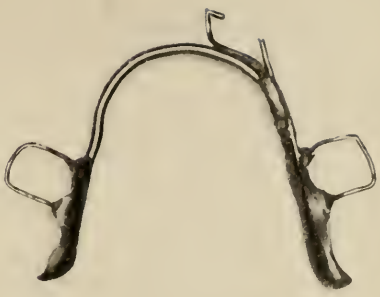

B

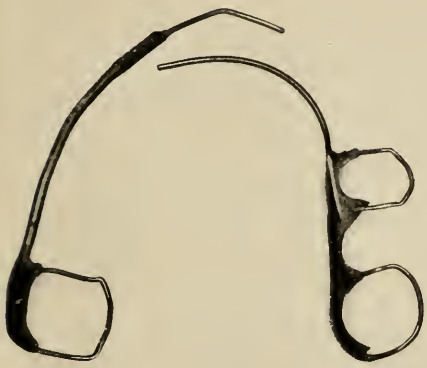

C

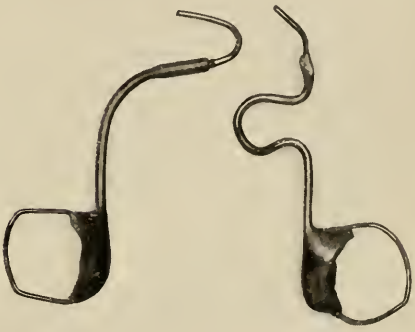

D



E

F

Plate XX

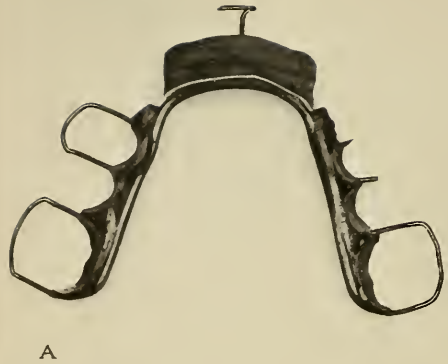

A

B

C

D

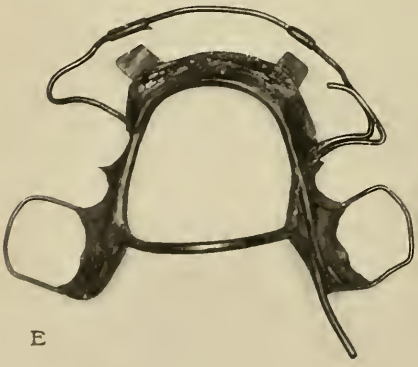

E

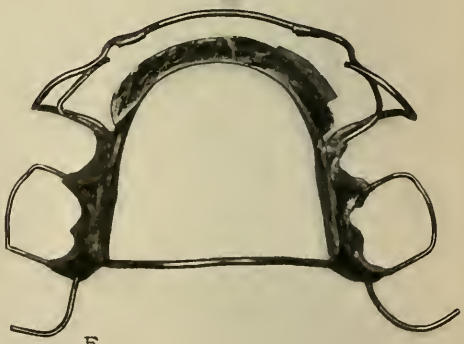

F

PLATE XX

Incisors, Rotation of

A. A device for the upper arch with a lingual base-wire well anchored. To the front of the base-wire is attached a piece of sheet-metal projecting forward to rest on the lingual side of the incisors. To this a spring-wire is attached, shaped properly to pass over the arch at the junction of the teeth, and bent at an acute angle to rest on the labial side of an incisor for moving it inward and rotating it.

B. An apparatus similar to the one described. A spring is attached to the metal in the anterior part for rotating and moving incisors inward.

C. A base-wire with a finger-spring on either side shaped to extend over the arch and project forward in a curve to rotate and move inward prominent lateral incisors.

D. A base-wire with plate-metal attached to the anterior part. A semicircular looped spring is arranged to force the teeth against the metal for rotation, and to even them.

E. An appliance for rotating lateral incisors by causing pressure on the labial and lingual sides. To the anterior part of the base-wire are attached short projecting strips of plate-metal to rest on the lingual side of the teeth, and similar projecting pieces are attached to a semicircular spring to press on the labial side.

F. A device with a lingual and a palatine base-wire strongly anchored. A curved piece of metal is attached to the anterior part of the base-wire shaped in the circle it is desired the teeth shall assume when regulated. A semicircular spring with loops is arranged to press the incisors against the metal for their rotation.

PLATE XXI

Incisors, Rotation of

A. An appliance with a lingual base-wire, to the anterior part of which is soldered two clips arranged to press on the lingual side of the lateral incisors. A finger-spring is attached to the base-wire on one side, shaped to extend outward and forward in a curve to the front of the arch, where it presses the incisors against the metals rotating them. A short finger-spring is also attached to the base-wire on the opposite side for moving inward a prominent cuspid.

B. To the anterior part of a lingual base-wire several strips of spring plate-metal are attached, arranged to rest on the lingual side of the irregular teeth. A semicircular spring forces the teeth inward against the metals, the latter being shaped or bent to rotate the teeth.

C. A lingual base-wire with a broad piece of plate-metal attached to the anterior part, arranged to rest on the lingual side of some of the teeth to assist in their rotation. A long finger-spring is attached to the base-wire on one side, shaped to project over the arch and extend forward to rest on the irregular teeth for forcing them against the metal. This reduced the rotated condition and forced some of the teeth backward in the line of the arch.

D. A device with plate-metal attached to the anterior part of the base-wire. On one side is soldered two finger-springs, one of them for pressing the incisors against the metal evening them, and the other for moving inward and backward a prominent cuspid.

E. An appliance with a lingual and a palatine base-wire anchored with spring-clasp attachments over the second bicuspids. To the anterior part of the lingual base-wire a T was attached which passed between the central incisors and pressed on their labial faces for rotating and retaining them.

F. A T-device with a lingual and a palatine base-wire strongly anchored, made similar to the one previously described.

Plate XXI

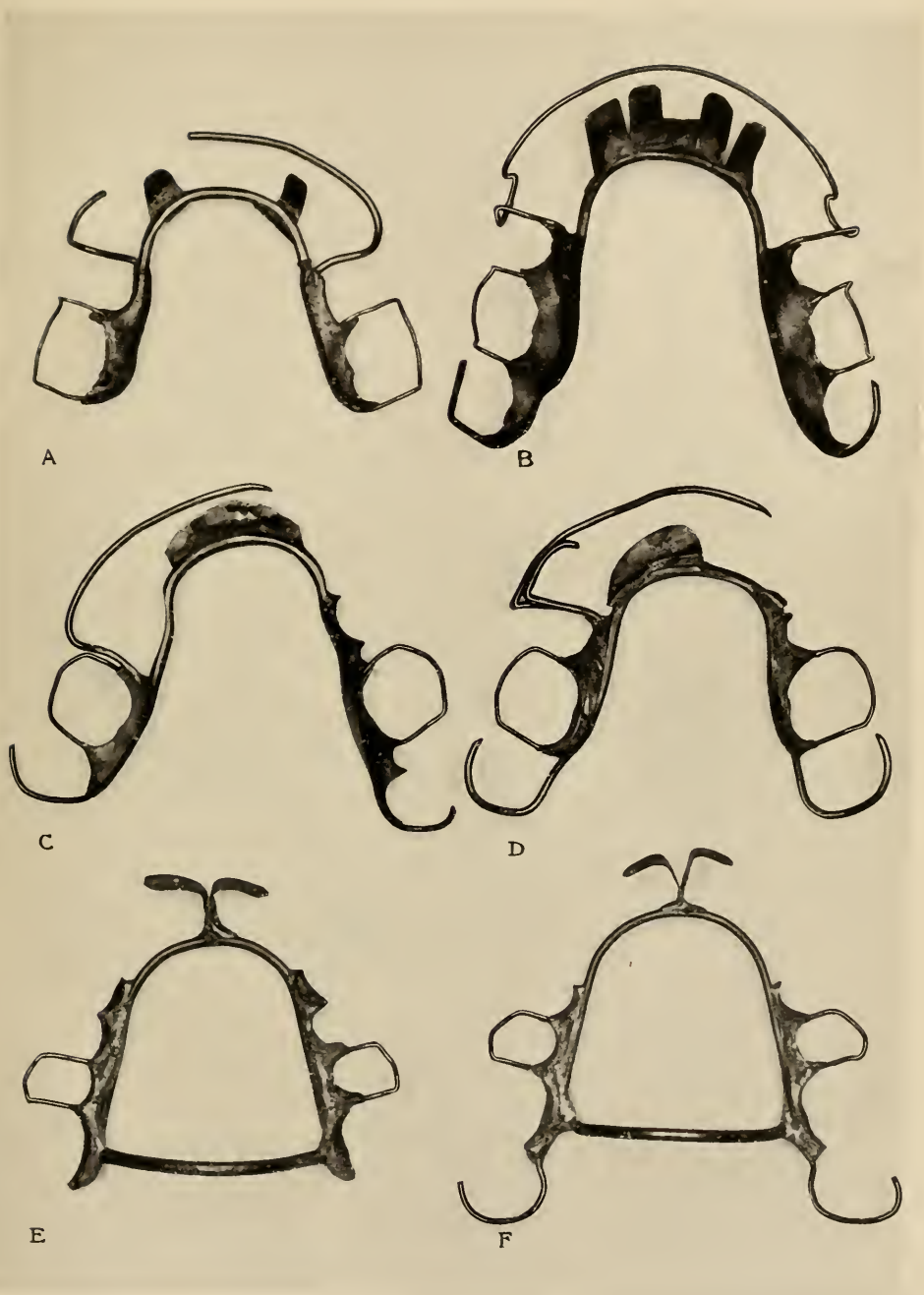

Plate XXII

A

B

C

D

E

F

PLATE XXII

Incisors, to move Laterally

A. An appliance with a lingual base-wire and two finger-springs for moving incisors laterally towards each other.

B. A device with a palatine base-wire and semicircular spring with loops. To the anterior part of the semicircular spring is attached a curved spring with arms to move the incisors towards each other.

C. An appliance with a palatine base-wire. A spring is attached in the anchorage on one side with a U-shaped loop made to rest at the median line. The free end of the spring was bent into a curve to rest back of the lateral incisor for moving it and the central incisor towards the medium line closing a broad interdental space.

D. An apparatus that was used for moving incisors together closing a broad interdental space, at the same time the bicuspids were moved forward by closing the U-shaped loops in the semicircular spring.

E. Shows an appliance with a spring of plate-metal attached to a lingual base-wire. Action is caused by separating the ends of the spring.

F. A lingual base-wire with gold springs attached for spacing and evening the teeth, at the same time supporting an artificial tooth.

PLATE XXIII

Cuspids, to move Outward

A. For moving outward two cuspids, a collar with a lug on the lingual side is cemented to each. A small spring is bent into three U-shaped loops of sufficient width to pass under the lugs. The ends of the spring are shaped to extend backward on each side of the arch to be anchored with spring-clasp attachments. Action is effected by opening the U-shaped loops by bending.

B. An appliance with a lingual base-wire for moving outward a cuspid. Two springs are attached to the base-wire, each shaped to cause force for its movement.

C. An appliance with a palatine base-wire. A finger-spring extends forward from the anchorage on one side to pass under a lug on a collar cemented to the cuspid to be moved.

D. A device with a broad palatine base-wire. A finger-spring is attached in the anchorage on each side of the arch, formed to pass under a lug on a collar cemented to each of the cuspids.

E. An appliance is shown with a lingual base-wire arranged for expanding the lower arch. To the anchorage on each side is soldered a finger-spring, shaped to extend forward and pass under a lug for moving outward the cuspids.

F. A jack-screw device is shown for moving a cuspid. The anchorage with partial-clasps and spring-clasp attachments can be made to include all of the teeth on one side of the arch. To the anchorage is soldered the nut of the jack-screw. The other end is anchored in a socket on a collar cemented to the cuspid to be moved.

A device with two looped springs is also shown. It is anchored to a bicuspid on one side of the arch. The front spring is arranged to move outward a cuspid, as the other draws inward a bicuspid. The ends are retained by eyelets on collars cemented to the teeth.

Plate XXIII



A



B

C

D

E

F

Plate XXIV

A



B



C

D

E

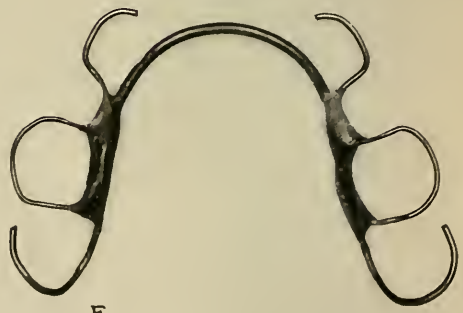

F

PLATE XXIV

Cuspids, Lower, to move Inward

A. An appliance with a lingual base-wire and a double-curved spring, used several years since for moving inward a right lower cuspid. The spring is arranged to extend over the arch at the junction of the teeth to rest on the mesio-labial surface. Additional partial-clasps for anchorage should be employed.

B. A lingual base-wire device, with a spring for forcing a partially erupted cuspid into the circle of the arch.

C. A lingual base-wire with a spring for moving into line an erupting left cuspid.

D. An appliance with a finger-spring used for moving inward a very prominent cuspid.

E. An apparatus with one curved spring and one looped spring for moving inward both lower cuspids.

F. A lingual base-wire strongly anchored with two curved springs moving the lower cuspids inward.

PLATE XXV

Cuspids, to move Inward

A. A device anchored on one side of the arch, with a spring formed into a U-shaped loop at the median line. The spring extends to the opposite side of the arch, passing over at the junction of the teeth and curved to rest on the labial side of the cuspid where it is attached to a carefully fitted partial-clasp for retaining it. Action is caused by changing the shape of the spring closing the loop as required.

B. An appliance similar to the one previously described, except that the end of the spring is shaped into a complete U-shaped loop, the lateral arms passing either side of the prominent cuspid with the free end terminating on the lingual side of the first bicuspid. The space in the arch for the cuspid is increased by broadening this loop, after which the cuspid is moved inward by closing the loop at the median line.

C. A lingual base-wire with a looped spring attached. The spring was arranged to pass either side of a prominent cuspid to the buccal side, where it crossed the cuspid at the gum line. The opening of the loop increased space for the movement of the cuspid, while curving the end of the loop towards the base-wire forced it inward.

D. A lingual base-wire with a spring attached at the median line formed into two U-shaped loops, one projecting into the palatine arch and the other passing over the arch to the buccal side, where it rested on the prominent cuspid at the gum line. Space for the cuspid was increased by opening this loop, and force for moving it inward was effected by changing the palatine loop.

E. An appliance with two springs used for moving prominent cuspids inward and backward.

F. A strongly anchored device arranged for moving inward and backward prominent cuspids.

Plate XXV

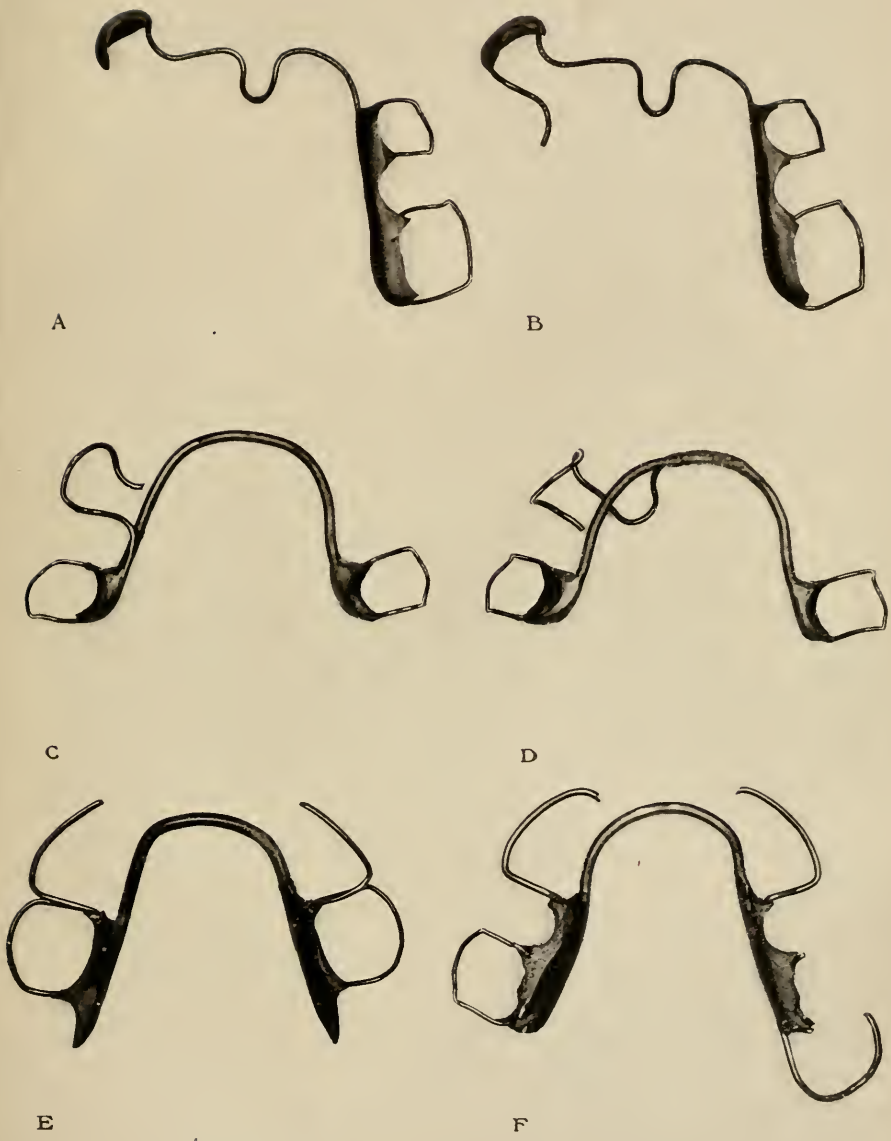

Plate XXVI

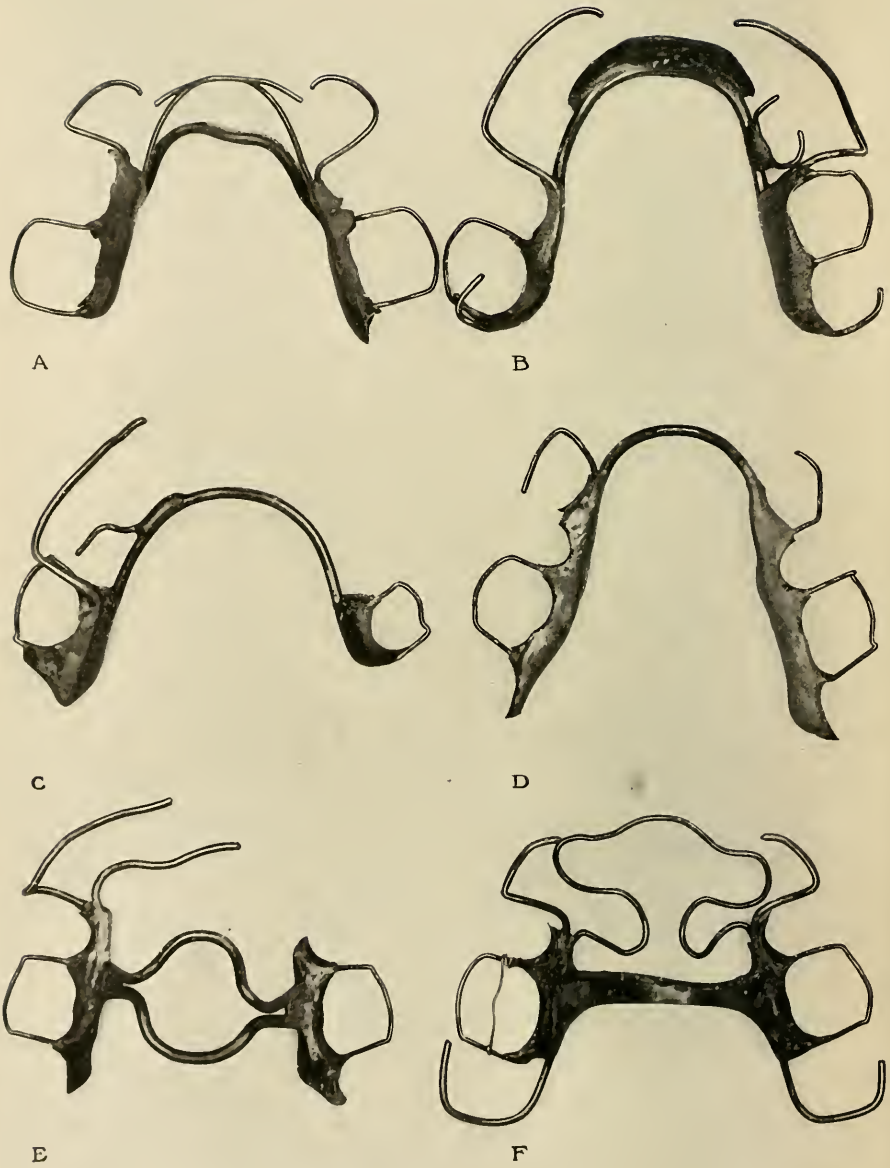

PLATE XXVI

Cuspids, to move Inward

A. An appliance with a lingual base-wire and two curved springs for moving cuspids inward. Also two finger-springs extend forward from the anchorage for forcing the incisors outward.

B. A lingual base-wire with plate-metal attached to the anterior portion to assist the anchorage and even the teeth. Two long finger-springs extend laterally from the base-wire to the buccal side, then forward to rest on the mesio-labial side of the prominent cuspids, for moving them and the bicuspids inward and backward.

C. A device with a long finger-spring extending from the base-wire over the arch to the buccal side for moving inward a prominent cuspid. A clip was attached to the base-wire and shaped to extend on to the grinding surface of a bicuspid to prevent the appliance from pressing on the gum.

D. An appliance with two finger-springs of different shape, one extending forward in a curve, the other passing from the base-wire over the arch in front of the prominent cuspid, with the end shaped to cross it at the gum line.

E. An apparatus with a double palatine base-wire and two springs attached. The base-wire is shaped similar to a loop, each pointing in an opposite direction. This arrangement gave rigidity to the appliance and facilitated the expansion of the arch. One spring passed over at the junction of the teeth to the labial side for moving the prominent cuspid and lateral inward. The lingual spring was shaped to force outward the central incisor for evening them.

F. A palatine base-wire is strongly anchored. Two finger-springs are attached for moving prominent cuspids inward, and a semicircular spring with U-shaped loops arranged for moving outward the incisors.

PLATE XXVII

Cuspids, to move Inward and Backward

A. An appliance with a lingual base-wire. A finger-spring extends to the buccal side and forward for moving inward a prominent cuspid. A finger-spring is attached to the base-wire on the opposite side of the arch following the lingual curve towards the prominent cuspid for moving outward an instanding lateral and central incisor.

B. A lingual base-wire device with springs attached for moving cuspids inward and backward. This form of anchorage with wire-clasps projecting backward to rest on the distal surface of the second molars is an advantage when the second molars are erupting and more anchorage is required, as the ends of the clasps can be bent to rest more towards the necks of the teeth.

C. A lingual base-wire with several springs attached for moving inward prominent cuspids and a prominent first bicuspid, at the same time moving outward some of the incisors.

D. An appliance with double springs for moving prominent cuspids inward and backward, and a finger-spring for moving inward and evening the incisors.

E. A device with a long finger-spring shaped to hook over a pin on a collar for the elevation of an impacted cuspid or for moving it backward or forward for encouraging its eruption. If used for the former purpose, two or more clips should extend from the base-wire to rest on the morsal surface of some of the adjoining teeth, to prevent the appliance from pressing on the gum.

F. A device with a spring properly curved to pass under the gum to move a partially erupted prominent cuspid backward and inward.

Plate XXVII

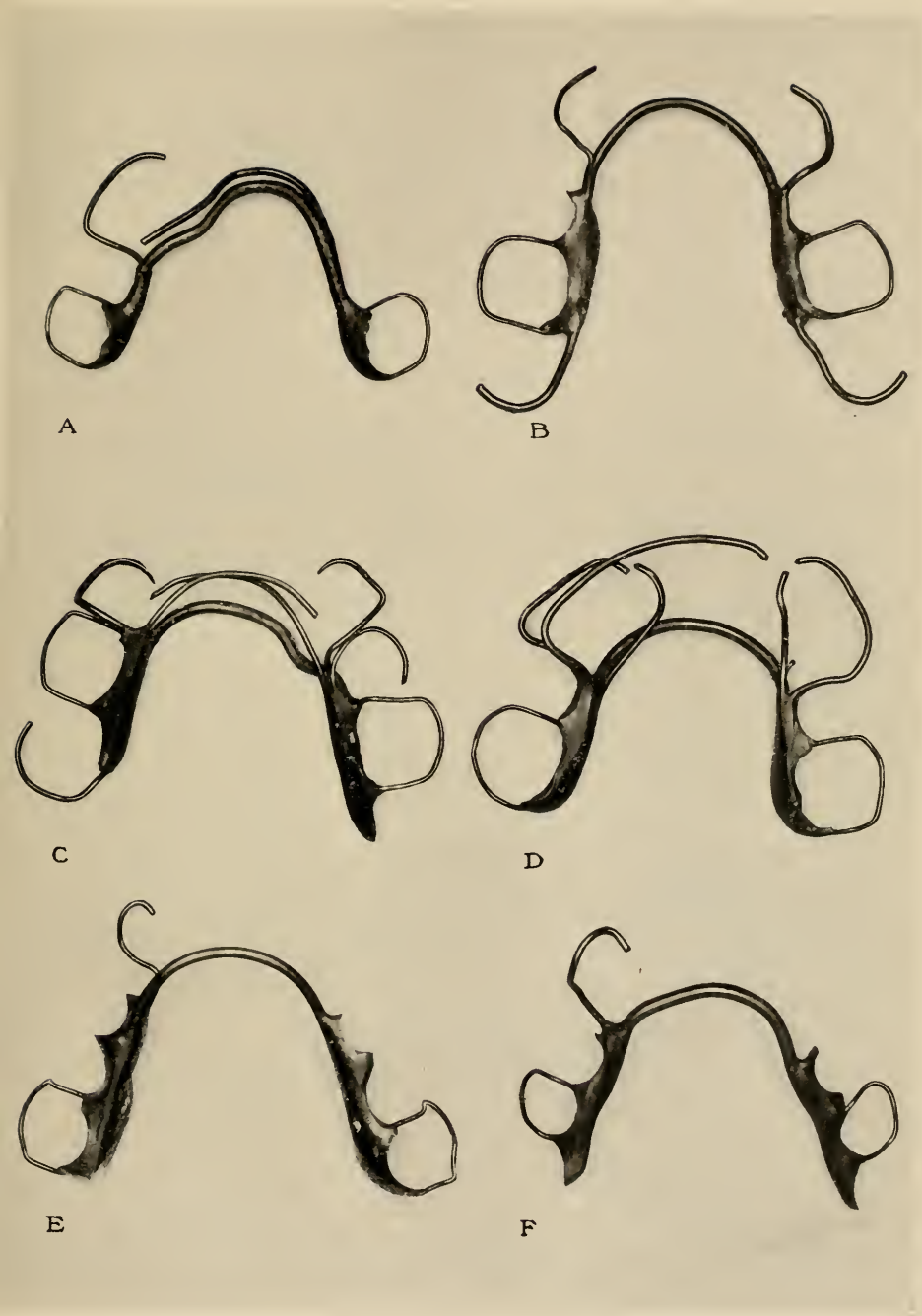

Plate XXVIII

A



B

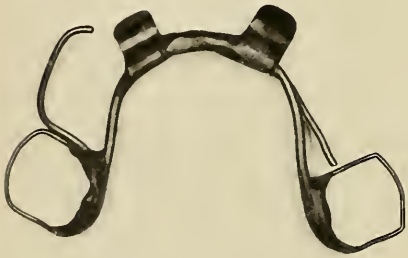

C

D

E

F

PLATE XXVIII

Cuspids, to move Inward and Backward

A. An appliance with a palatine base-wire. From the lingual anchorage short looped finger-springs extend over the arch for forcing prominent cuspids inward.

B. A palatine and a lingual base-wire device with a clip attached to the anterior part shaped to prevent the lateral incisor being pressed out of position as the cuspid is forced inward by a curved spring.

C. A lingual base-wire with flanges or inclined planes attached to rest against the lateral incisors for moving them outward, as a prominent cuspid is being moved inward and backward, and a bicuspid moved outward on the opposite side of the arch.

D. A device with plate-metal attached to the anterior portion of a lingual base-wire to assist the anchorage for moving a prominent cuspid inward.

E. A lingual base wire with plate-metal attached to the anterior part to assist the anchorage for moving a prominent cuspid inward without crimping the incisors.

F. An appliance with a palatine base-wire and arms projecting inward to rest on the lingual side of the lateral incisors to assist the anchorage as the cuspids are moved inward with curved springs.

PLATE XXIX

Cuspids, to move Backward in the Line of the Arch

A. An appliance with a lingual base-wire used for moving a cuspid and two bicuspids backward in the line of the arch. A clip was attached to the anterior part of the base-wire to assist the anchorage and prevent the appliance from pressing against the gum.

B. An apparatus with a long finger-spring attached to a lingual base-wire for moving backward a prominent cuspid and two bicuspids. Two pieces of plate-metal forming inclined planes were attached to the anterior part of the base-wire to assist the anchorage.

C. A device anchored to only one side of the arch, with springs attached for moving backward a cuspid and a bicuspid.

D. An appliance with a lingual base-wire strongly anchored for moving a cuspid and two bicuspids backward.

E. A lingual base-wire with a long and a short spring attached for moving cuspids backward. Straight springs are arranged to prevent the cuspids being forced inward too far.

F. A cast metal-plate with a long finger-spring for forcing a lower cuspid and two bicuspids backward.

Plate XXIX

A

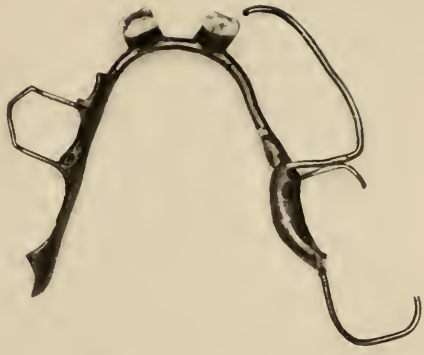

B



C

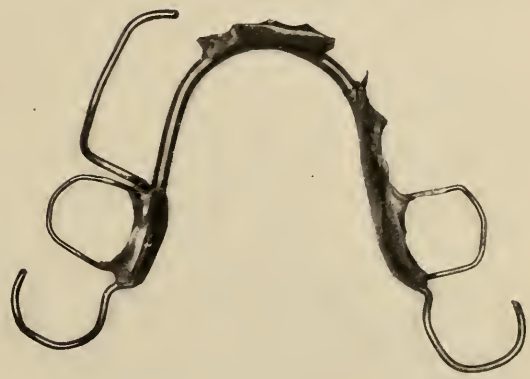

D

E

F

Plate XXX

A

B

C

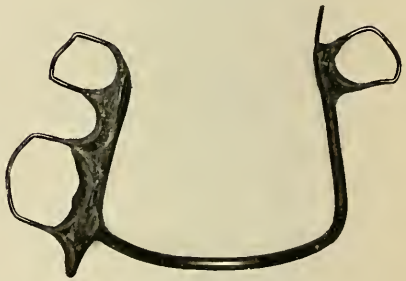

D

E

F

PLATE XXX

Bicuspids, to move Outward.

A. A lingual spring base-wire that was used for moving outward two bicuspids in the lower arch. It is suitable for retaining the teeth.

B. An expanding device for moving outward the lower bicuspids. A lingual base-wire is arranged to extend backward to be attached in the anchorages which project forward. With this arrangement a considerable movement can be brought about.

C. A palatine spring base-wire with arms shaped to project forward, and retained by spring-clasp attachments passing over the bicuspids to be moved. Action is caused by bending outward the lateral arms.

D. An appliance anchored to several teeth on one side of the arch and to one tooth on the other. A palatine spring base-wire has the ends bent forward forming arms to be attached in the anchorage. Force is caused by bending outward the arms a little at a time.

E. A device similar to the one described. A palatine spring base-wire with arms projecting forward. To the anterior part of the anchorage is attached a semicircular spring with two U-shaped loops for moving incisors outward.

F. A device with a palatine spring base-wire in the form of a U-shaped loop for moving outward a bicuspid on each side of the arch.

PLATE XXXI

Bicuspids, to move Outward, and Inward

A. A lingual base-wire for moving outward a bicuspid. A spring is attached for increasing the space for its movement. The arms of the spring extend over the arch where the ends are bent outward to rest on the buccal side of the adjoining teeth.

B. A device similar to the one described. The arms of the spring that pass over the arch are separated for increasing the space for the bicuspid, and the ends are curved inward to press on the buccal side of the adjoining teeth to assist the action of the base-wire.

C. A simple spring device for moving outward a bicuspid. A partial-clasp is fitted to one side of the tooth to be moved. A spring is arranged to cross the partial-clasp to which it is finally soldered. The arms are shaped to pass over the arch and the ends bent outward to rest on the adjoining teeth. They are curved inward for getting force.

D. A lingual base-wire anchored to the bicuspids not to be moved. A spring is attached to the base-wire extending over the arch like an arm to rest on the buccal side of a prominent bicuspid for forcing it inward.

E. An appliance with a lingual base-wire for moving a bicuspid inward. To the base-wire is attached a spring, with the ends shaped like arms to extend over the arch at the junction of the teeth either side of the bicuspid to the gum line, with the ends bent to cross the buccal surface. Action is effected by curving the ends more towards the base-wire.

F. A lingual base-wire strongly anchored. A spring extends from either side over the arch at the junction of the teeth like an arm, the ends crossing the teeth to be moved. Pressure is caused by curving the ends towards the base-wire.

Plate XXXI



A

B

C

D

E

F

Plate XXXII

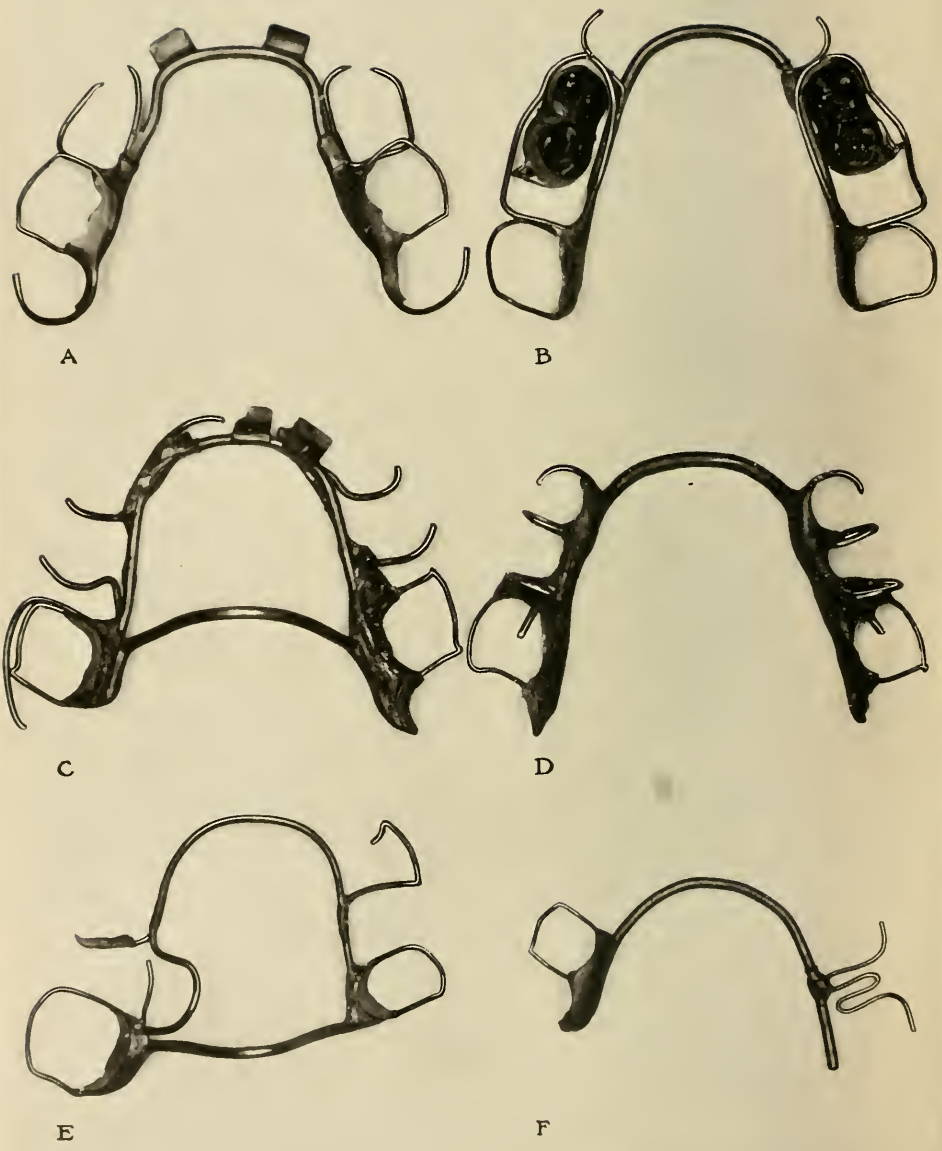

PLATE XXXII

Bicuspids, to move Backward, to move Forward, to relieve Impaction

A. A device with a lingual base-wire, to which a U-shaped spring is attached on either side of the arch for moving bicuspids backward.

B. An appliance with U-shaped springs attached to a lingual base-wire for moving backward the bicuspids. A swaged metal-cap with an eyelet soldered on the buccal surface, was cemented to the bicuspids on each side of the arch, to provide means of attachment for applying supplemental force to move the teeth bodily.

C. An appliance for moving bicuspids forward. A palatine and a lingual base-wire is strongly anchored. To the lingual base-wire is soldered curved finger-springs to rest back of the bicuspids to be moved. Force is applied by bending the springs forward as required.

D. An apparatus with a lingual base-wire and looped wire-springs, anchored in the lower arch and arranged to move bicuspids forward in the upper arch. The springs are placed at an angle suitable for making an incline to pass back of each of the upper bicuspids to cause force on them in occlusion.

E. An appliance for causing space and moving outward an impacted or instanding bicuspid at the same time forcing a prominent cuspid inward.

F. A device with a lingual base-wire. A double-looped spring is attached for relieving an impacted bicuspid.

PLATE XXXIII

Molars, to move Backward, Forward, Outward, Inward, Equalizing the Jaws, Retaining

A. An apparatus with two palatine base-wires, one of them strongly anchored to the bicuspids and the other to a molar on each side of the arch. The parts are connected with two U-shaped loops of spring-wire for moving the first molars backward in the line of the arch. It is applicable for moving the molars forward.

B. A lingual base-wire spring device for moving molars inward. To the base-wire on each side is soldered a spring-wire shaped to extend over the arch to rest on the buccal side of the molars to be moved, near the gum. Action is caused by bending the springs inward. The base-wire is strongly anchored to the teeth not to be moved.

C. An appliance for moving molars outward or an impacted molar backward, righting its position.

D. An equalizing device. A lingual base-wire is strongly anchored. At the distal part of each end an inclined plane is shaped to project back of molars in the opposite arch.

E. A retaining appliance made from one used for regulating the teeth. The spring was made rigid by attaching the free end to the base-wire.

F. A lingual base-wire for retaining, anchored on each side of the arch with spring-clasp attachments.

Plate XXXIII

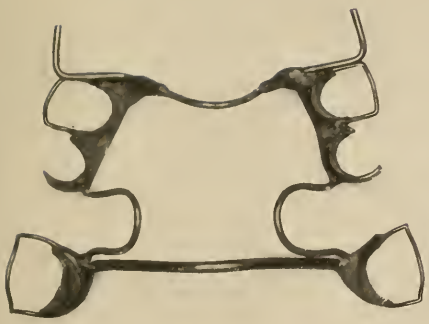

A

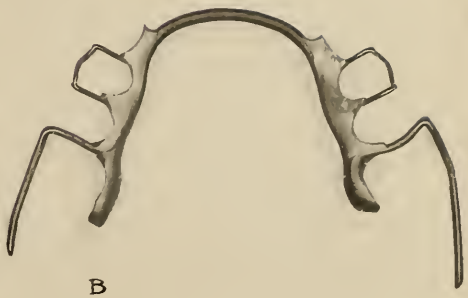

B



C

D

E



F

Plate XXXIV



A



B

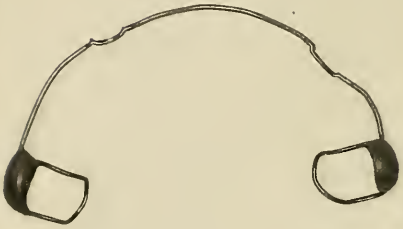

C

D



E

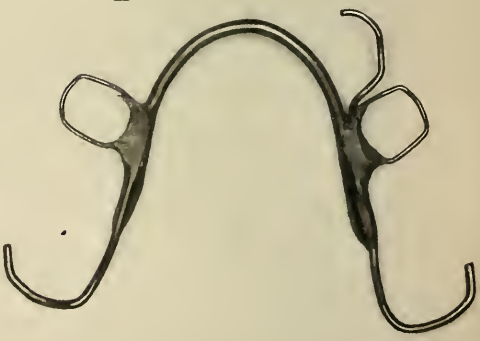

F

PLATE XXXIV

Retaining

A. A labio-buccal base-wire for retaining incisors and cuspids that have been moved inward. The ends are anchored by spring-clasp attachments over a first or second bicuspid on each side of the arch.

B. A labio-buccal base-wire with a U-shaped loop arranged to rest under the lip on one side of the arch. The loop is of advantage in permitting desired changes.

C. A device with a labio-buccal base-wire and two U-shaped loops, anchored by spring-clasp attachments over the bicuspids ; used for retaining six front teeth that have been moved inward.

D. A lingual base-wire strongly anchored, for retaining six front teeth that had been moved outward.

E. A device with a lingual base-wire for retaining teeth that have been moved outward, with a spring passing over the arch to retain a tooth that had been moved inward. Additional partial-clasps should be employed.

F. A lingual base-wire used for retaining teeth on the sides and front of the arch that had been moved outward. A finger-spring is attached in the anchorage for retaining two teeth that had been moved inward.

PLATE XXXV

Retaining

A. An appliance for retaining teeth that had been crimped, some of them moved outward, others moved forward. It was made with a lingual base-wire and a semicircular spring with U-shaped loops, the ends of which were attached to the spring-clasps.

B. An apparatus used for retaining incisors and cuspids that had been moved forward.

C. A lingual base-wire with plate-metal attached to the anterior part for retaining lower incisors that had been moved outward and rotated.

D. A lower retainer that was used for supporting bicuspids and molars that had been moved outward.

E. A device used for retaining teeth after the expansion of the arch.

F. An appliance with a palatine and a lingual base-wire. The latter was fitted to the teeth to retain them.

Plate XXXV

A

B

C

D

E

F

Plate XXXVI

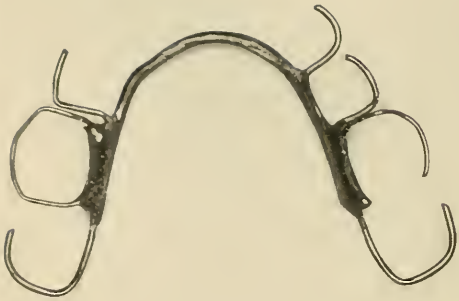

A

B

C

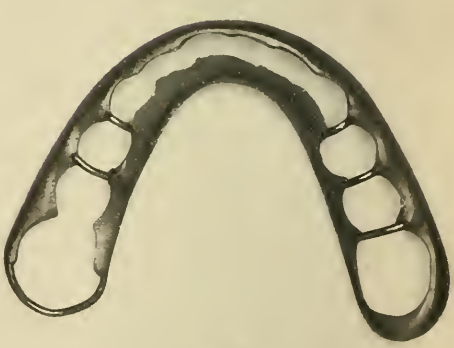

D

E

F

PLATE XXXVI

Retaining

A. An appliance used for retaining bicuspids that had been moved inward.

B. A device with a lingual base-wire and labial-spring for retaining incisors that had been rotated.

C. A lower appliance used for retaining incisors that had been crimped.

D. A cast-metal retainer for supporting the teeth of the lower arch, made similar to one described by Dr. Richardson.

E. A device with a lingual base-wire for retaining lower teeth loosened from pyorrhœa alveolaris. It was anchored to the bicuspids with a continuous, partial-clasp fitting the lingual side of the teeth. To the continuous partial-clasp are soldered spring-wires which are shaped to hook over the edge of the teeth at the junction of those to be retained, passing on to the labial side to support them.

F. A suspension plate for retaining teeth loosened from pyorrhœa alveolaris and holding an artificial tooth. It is made similar to the one previously described.

PLATE XXXVII

Arch, Expansion of

A. A vulcanite palatine plate for expanding the arch, connected with a U-shaped spring and anchored with wire-clasps.

B. A plate used for the lateral expansion of the arch, at the same time rotating the central incisors inward with two gold springs passing to the labial side of the teeth.

C. A plate for the lateral expansion of the anterior part of the arch. The halves of the plate were connected with a simple looped spring-wire located in the distal part where the arch was broad enough.

D. An appliance used for the unequal expansion of the arch to cause room for an instanding lateral incisor.

E. A divided plate connected with a U-shaped spring, that was used for expanding laterally the anterior part of the lower arch, at the same time moving outward instanding incisors.

F. An appliance used for the unilateral expansion of the arch. The plate was anchored to the teeth not to be moved. The other side of the arch was forced outward by a long S-shaped spring anchored in the rubber, the other end of the spring being attached in a metal anchorage including the teeth to be moved.

Plate XXXVII

A

B

C

D

E

F

Plate XXXVIII

A

B

C

D

E

F

PLATE XXXVIII

Incisors, to move Outward

A. A palatine plate and finger-spring used for moving incisors outward. It is retained by spring-wires extending from the margin of the plate over the arch at the junction of the teeth reaching towards the gum, the ends resting in the interdental spaces.

B. A plate retained by wire-clasps passing over the arch to rest on the buccal side of the molars.

C. A vulcanite plate retained with wire-clasps. A finger-spring is attached in the front part to move incisors outward.

D. A palatine plate supporting two artificial teeth, and a finger-spring attached in the anterior part for moving incisors outward.

E. A vulcanite plate with two looped springs attached in the front part for forcing lateral incisors outward. The free ends of the springs pass under lugs on collars cemented to the laterals.

F. A cast-metal plate with two finger-springs extending from the anterior part, used for moving outward instanding incisors.

PLATE XXXIX

Incisors, to move Inward

A. A palatine plate anchored by wire-clasps. A semicircular spring passed over the arch to rest on the labial faces of prominent incisors for moving them inward.

B. A plate with two finger-springs for moving backward prominent cuspids, and a semicircular spring for moving inward the incisors.

C. A palatine plate with a finger-spring attached on each side to extend over the arch at the junction of the teeth, then forward to rest on the labial faces of the teeth to be moved. The ends of the springs are left long to pass one another at the median line.

D. A plate with springs made similar to the one last described for moving inward prominent incisors and cuspids. It is retained by wire-clasps.

E. A rubber plate with two finger-springs. Plate-metal is soldered to the wire-clasps and arranged to press above the margin of the gum when the teeth are not fully erupted.

F. A palatine plate anchored with spring-clasps. Two finger-springs are arranged to pass over the arch at the junction of two of the teeth that are in correct position. The ends of the springs rest on prominent teeth that are to be moved inward.

Plate XXXIX



Plate XL

A

B

C

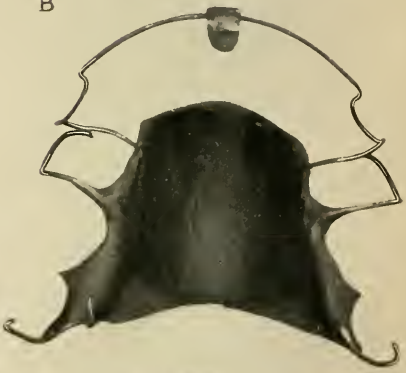

D

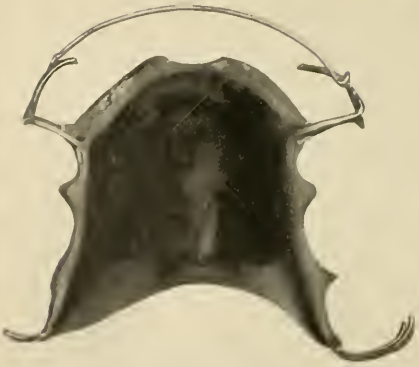

E

F

PLATE XL

Incisors, to move Inward

A. A palatine plate with a semicircular spring and U-shaped loops for moving inward prominent upper incisors and cuspids. Action is effected by closing the loops of the spring. The sides of the plate were dressed away for the regulation of the bicuspids.

B. A vulcanite plate for moving inward the six front teeth, retained by wire-clasps around two of the molars and two of the bicuspids.

C. A plate with semicircular spring and U-shaped loops arranged for moving inward the incisors. Force is caused by bending inward the front portion of the spring, twisting the wire in the loops.

D. A palatine plate with a semicircular spring. To the spring is attached a curved clip to pass over the edge of the incisors to prevent the spring from slipping towards the gum.

E. A palatine plate with a semicircular spring for correcting incisors, and two curved finger-springs for moving cuspids backward.

F. A rubber plate and semicircular spring for moving inward prominent upper incisors. The anterior part is shaped into an inclined plane for depressing lower incisors.

PLATE XLI

Incisors, to depress

A. A vulcanite palatine plate with the anterior part thickened, forming an inclined plane for depressing extruded lower incisors.

B. A palatine plate and inclined plane anchored with wire-clasps.

C. A vulcanite plate and inclined plane anchored with wire-clasps and spring-clasps.

D. A rubber plate with an inclined plane of plate-metal riveted to the anterior portion.

E. A plate with a metal inclined plane attached by rivets. Additional layers of plate metal are attached when necessary by soldering carefully with soft solder, using a soldering iron.

F. A palatine plate and metal inclined plane with a finger-spring attached in the anterior portion for evening the upper incisors.

Plate XLI

A

B

C

D

E

F

Plate XLII

A

B

C

D

E

F

PLATE XLII

Cuspids, to move Outward, and Inward

A. A vulcanite palatine plate with a finger-spring used for moving outward a cuspid.

B. A palatine plate with a spring, employed for moving inward and backward a prominent cuspid.

C. A rubber plate with two looped springs for moving inward prominent cuspids.

D. A plate with an inclined plane for depressing lower incisors, at the same time moving backward and inward upper bicuspids and prominent cuspids.

E. A palatine plate with a long finger-spring passing over the arch at the junction of the teeth and extending forward to move inward and backward a prominent cuspid.

F. A vulcanite plate with two finger-springs arranged for moving the bicuspids backward and a prominent cuspid inward and backward.

PLATE XLIII

Bicuspids, to move Outward, Inward, Backward, and Forward

A. A palatine plate with springs attached in the lateral sides of the distal part projecting forward to move outward bicuspids.

B. A vulcanite plate with a spring attached in the anterior part projecting backward, to move outward a bicuspid and a molar, at the same time the incisors are moved inward by a finger-spring.

C. A palatine plate with springs attached in the central portion projecting outward for moving bicuspids backward or forward. It also has a semicircular spring with a loop for evening the incisors.

D. A plate with springs attached in the central part, projecting outward for moving bicuspids backward in the line of the arch. Supplemental force was given by a cross-bar.

E. A rubber plate with a metal inclined plane, and springs attached in the lateral sides for moving bicuspids outward and forward.

F. A plate used for moving inward prominent cuspids and evening the bicuspids.

Plate XLIII

A

B

C

D

E

F

Plate XLIV

A

B



C

D

E

F

PLATE XLIV

Retaining

A. A palatine vulcanite plate for retaining. It is held in place by a suction and fitting the necks of the teeth.

B. A plate fitting the necks of the teeth supported by wire-clasps passing over and around the first bicuspids.

C. A palatine plate used for retaining when there are spaces between the bicuspids.

D. Shows a vulcanite plate used for retaining when there are broad interdental spaces between the bicuspids and molars.

E. A retaining plate supported by wire-clasps passing around the second molars.

F. A palatine plate with a semicircular spring and U-shaped loops, anchored by spring-clasps. It was used for retaining corrected prominent incisors.

INDEX

A

B

C

D

F

J

K

L

M

N

O

P

S

T

U

V

W

Z

THE END

Orthodontia nd orthopaedia of the face.