

DENTAL SURGERY:

INCLUDING SPECIAL ANATOMY AND PATHOLOGY.

*A MANUAL
FOR STUDENTS AND PRACTITIONERS.*

BY

HENRY SEWILL, M.R.C.S., L.D.S.ENG.

PAST PRESIDENT OF THE ODONTOLOGICAL SOCIETY OF GREAT BRITAIN;
FORMERLY DENTIST TO THE WEST LONDON HOSPITAL.

THIRD EDITION.

LONDON: BAILLIERE, TINDALL & COX,
20 AND 21, KING WILLIAM STREET, STRAND.

1890.

RK501

Se 8

1890



DLG

1946

9

DLG

TO

JONATHAN HUTCHINSON, LL.D., F.R.S.,

PRESIDENT OF THE ROYAL COLLEGE OF SURGEONS,

WHOSE LABOURS HAVE CONTRIBUTED

TOWARDS ELUCIDATION OF MANY PROBLEMS

IN SURGICAL AND DENTAL PATHOLOGY,

THIS BOOK IS DEDICATED WITH SINCERE REGARD

AND IN GRATEFUL ACKNOWLEDGMENT OF LONG CONTINUED

FRIENDLY KINDNESS.

medical
46-1885B

PREFACE
TO
THE THIRD EDITION.

ENCOURAGED by the success of previous editions, and guided by the kindly criticism and suggestion which they evoked, I have endeavoured to extend the original design and scope of this work in the hope that it might adequately fulfil the requirements of a complete Manual of Dental Surgery and Pathology.

My aim has been to supply all the information on these subjects which can be needed by the surgeon or practitioner of medicine, and to provide a solid foundation of knowledge from which the dental student may proceed to that fuller study which ought to be undertaken by everyone intending to devote himself to the practice of Dental Surgery.

Although I have not neglected to collate authorities, I have personally investigated many of the subjects of dental physiology and most of the problems of dental pathology. Into the nature of Caries I have particularly made a thorough research.

Numerous obligations for assistance must be acknowledged. To Mr. Arthur Underwood and Mr. Charters White I owe an equal debt. From the former, whose

labours with Mr. Milles did so much to clear away obscurity from the subject, I have received great help in the study of caries; from the latter I have obtained friendly aid in examination of physiological questions, and from both I have derived most material assistance in free use of the extensive cabinets of microscopical preparations which they possess.

My research into the pathology of Caries would probably have been far less complete and conclusive had I not fortunately secured the co-operation of Mr. Pound, of the Bacteriological Laboratory, King's College; an expert of experts in bacteriological microscopy, he furnished me for examination with a vast number of exquisitely prepared sections.

A considerable number of original illustrations have been added to this edition, amongst which are *facsimile* reproductions of photo-micrographs by Mr. A. Pringle and Mr. Charters White. Mr. England has contributed a series of diagrams illustrating the operation of stopping. The engravings of syphilitic and honeycombed teeth are taken from original drawings, for the loan of which I have to thank Mr. Jonathan Hutchinson. For several valuable cuts from "Notes on Dental Practice," I am indebted to Mr. H. Quinby. Other wood-cuts have been obtained from various sources, all of which have been duly acknowledged.

Whilst it is hoped that no fact of importance has been omitted, the anatomical chapters are intended to be merely introductory to Pathology and Surgery, not exhaustive of the subject.

In this edition, as in the preceding, I have striven to keep closely to the proper theme of the work and

not to enter into purely surgical topics further than seemed necessary to make clear questions in the pathology, diagnosis, and treatment of diseases connected with the teeth.

I have thought it well not to encumber the pages and needlessly add to the bulk of the book by insertion of a great number of wood-cuts of instruments. Every practitioner can provide himself with the illustrated catalogues published by the principal manufacturers. All the classes of instruments mentioned are fully figured in the lists published by Messrs. Ash, of Broad Street, Golden Square; Messrs. White, of Philadelphia, U.S.; and the Dental Manufacturing Company, of Lexington Street, Golden Square. Messrs. Ash and the Dental Company have supplied numerous new illustrations for this edition.

WIMPOLE STREET.

June, 1890.

PREFACE
TO
THE SECOND EDITION.

THIS Edition has been revised throughout, re-written, and amplified where necessary. In its preparation the author has had the advantage of the assistance of Arthur Underwood, M.R.C.S., L.D.S., Assistant-Surgeon to the Dental Hospital of London. Mr. Underwood's investigations of dental pathology, and his work with Mr. Milles in elucidation of the phenomena of caries, are well known as among the most valuable contributions within late years to our knowledge of these subjects.

Abundant evidence has been forthcoming that the First Edition of this book was useful to the practitioner as well as to the student ; and it is hoped that the alterations in the Second Edition may render it still more acceptable to both classes of readers.

WIMPOLE STREET.

March, 1883.

PREFACE
TO
THE FIRST EDITION.*

No department of physiology or surgery has of late years made greater progress than that connected with the teeth, and this advance has been necessarily attended by a corresponding increase in the literature of the subject, which has now become so voluminous as to form a source of embarrassment to those who are entering upon a course of dental education. Under these circumstances the projectors of the "Students' Guide" manuals have considered a work on Dental Anatomy and Surgery a desirable addition to the series. It is designed that these manuals should be free from needless technicalities; that they should facilitate the labours of the student; and that whilst each volume—although presenting merely an outline of the subject—should be complete in itself, it should at the same time lead the reader to desire, and direct him in seeking, the fuller knowledge afforded by more extended treatises. These designs I have striven to accomplish in this volume.

* This and the second edition were published in the "Students' Guide Series" (Churchill).

It must, however, not be supposed that the student can profitably peruse even the most rudimentary text-book on any special branch of pathology or surgery without an adequate knowledge of the fundamental principles of those sciences; and evidently it can but confuse him to encounter such terms as “nucleus” and “cell,” or “inflammation” and “abscess,” unless he have a clear conception of their signification. Such knowledge must be obtained previously from elementary works on physiology, pathology and surgery.

Whilst in a work of this kind it is essential that, as far as practicable, facts only should be laid before the student, it is not possible to avoid altogether the discussion of controverted points, or at least the description of subjects that have as yet been insufficiently investigated. Amongst these subjects must be placed the development of the teeth. The description of this process, which is found in physiological text-books, even the latest editions, is entirely based upon the investigations of Goodsir, which were published by him in the “Edinburgh Medical and Surgical Journal,” in the year 1838. Since that date the subject has been investigated by numerous physiologists, among whom may be specially mentioned Marcusen, Dursy, Köl liker, and Waldeyer, and they are agreed with regard to the main facts of the process. Aided by the advance of microscopical science since the time of Goodsir, they have traced the phenomena of dental evolution from a period of embryonic life much earlier than that at which it was supposed to commence by that renowned physiologist, and have thus necessarily overthrown much of his theory.

Messrs. Legros and Magitôt have issued the latest

monograph on the subject—a most elaborate and minute description, entirely based upon original observations—and the corroboration it receives from previous investigations leaves no doubt that it is substantially accurate. The section which I have in this manual devoted to the development of the teeth is merely a summary of the work of these physiologists.

The histogenesis of the dental tissues—the changes which take place in the tooth-germ by which its elements are gradually converted into these tissues—has been, like the preceding subject, investigated by numerous physiologists, and like it has given rise to considerable difference of opinion. The majority of more recent observers (Lent, Kölliker, Marcusen, Huxley, Robin, Magitôt, Tomes, and Waldeyer) are, however, in accord with regard to essential points, and in the account which I have given I have attempted to epitomize the main facts elucidated by these authorities without entering upon controverted topics.

The theory of the etiology and pathology of caries which I have adopted is entirely based upon generally admitted facts; it is that which I believe can alone be arrived at by reasoning upon such facts; it is that which recently has been enunciated by the best authorities, and eventually must be, in my opinion, universally accepted. It will be perceived that decay of the teeth is a process entirely dissimilar to caries of bone, and that although the term caries is retained for the sake of convenience, it is not really indicative of the true character of the disease.

No more than passing reference has been made to those injuries and diseases of the mouth and jaws that

are not intimately associated with dental pathology and surgery. Although these affections necessarily fall much under the notice of the dental surgeon, who is therefore required to possess a knowledge of their nature, their full discussion belongs more properly to works on general surgery than to those devoted entirely to dental subjects.

Knowledge having been obtained of the principles upon which operative procedures are carried out, and of the materials and instruments employed, the student cannot commence too soon to acquire skill by practice and experiment. This practice is easily obtained by the dental student. He may begin by plugging with tinfoil cavities cut in bone or ivory or in extracted teeth, each stopping after completion being carefully broken up to discover in what detail it has failed, or in what direction it is capable of improvement. In the same way such operations as capping the pulp, extirpation of the pulp and fang-filling may also be practised. For this purpose extracted carious teeth are best preserved in spirit, which prevents the pulp from drying and shrivelling. As soon as the student can with rapidity and certainty fill difficult cavities in extracted teeth fixed in a vice, he may safely proceed to operate upon simple cavities in the mouth of the living subject. Similar remarks may be made with regard to the operation of extraction. The anatomy of the teeth and of the parts around being understood, the student may proceed to apply the forceps to the different kinds of teeth, and familiarize himself with the mode in which the instrument is held, the tooth grasped, and the force applied. Every student should subsequently go through a course of extracting

operations on the dead subject, opportunities for which are afforded at every school of medicine.

Of the illustrations some are original, some are copied, and some are borrowed from works the property of the publishers. Those illustrating the development of the teeth are copied from Messrs. Legros and Magitôt's monograph. For some of the most valuable I am indebted to the admirable works of Messrs. Tomes, Mr. Christopher Heath, and Mr. Salter. Figs. 34, 36, and figs. 74 to 78, are taken by permission from the "Transactions of the Odontological Society." Among the original engravings, those in the sections on preparing cavities and gold filling have been most kindly contributed by my friend Mr. Howard Mummery.

WIMPOLE STREET.

Feb. 1876.

CONTENTS.

	PAGE
ANATOMY AND HISTOLOGY OF THE TEETH	1
DEVELOPMENT OF THE TEETH	17
GROWTH OF THE JAWS	28
ABNORMALLY FORMED TEETH	49
IRREGULARITIES OF THE TEETH	62
CARIES	111
PREVENTION OF CARIES	163
TREATMENT OF CARIES	171
EXPOSURE OF THE PULP. DISEASES OF THE PULP	228
DISEASES OF THE DENTAL PERIOSTEUM. PERIODONTITIS. AL- VEOLAR ABSCESS. PERIOSTITIS AND NECROSIS OF THE MAXILLÆ. DENTAL EXOSTOSIS. NECROSIS. ABSORPTION OF ROOTS OF PERMANENT TEETH. ABSORPTION OF ALVEOLI. PYORRHOEA ALVEOLARIS	259
CARIES AND ITS SEQUELS IN INFANCY AND EARLY CHILDHOOD	281
DISEASES OF THE GUMS AND BUCCAL MUCOUS MEMBRANE. RANULA. GLOSSITIS... ..	288
ABRASION. EROSION. INJURIES—CONCUSSION, DISLOCATION, AND FRACTURE OF TEETH	294
PIVOTING TEETH. PORCELAIN INLAYS. CROWN, BAR AND BRIDGE WORK	301

	PAGE
SALIVARY CALCULUS OR TARTAR	306
MORBID GROWTHS CONNECTED WITH THE TEETH	311
DISEASES OF THE ANTRUM	328
TOOTHACHE. NEURALGIA, AND DISEASES OF THE NERVOUS SYSTEM	336
EXTRACTION OF TEETH	348
DISLOCATION AND FRACTURE OF THE JAW. CLOSURE OF THE JAW	385
APPENDIX	391

LIST OF AUTHORS.

1. ARKÖVY . { Action of Agents for Devitalization of the
 Tooth-Pulp, Transactions, International
 Congress, 1881.
2. BÜDECKER. { Papers on Dental Physiology and Histology,
 Dental Cosmos, 1874-1880.
3. FERRIER . { Relations of Fifth Cranial Nerve, Transactions
 Odontological Society, 1889.
4. HEATH. { Injuries and Diseases of the Jaws, 3rd Edition,
 1884.
5. HUTCHINSON,
 JONATHAN. { Papers on Syphilitic, Stomatitic, and Mercurial
 Teeth, &c. Ophthalmic Hospital Reports,
 1859. Transactions, Pathological Society,
 1875. Transactions, Odonto. Society, 1889.
6. LEBER and
 ROTTENSTEIN } Caries der Zähne, 1867.
- 6A. KLEIN. . . . Histology, 1889.
- 6B. KLEIN and
 NOBLE SMITH } Atlas of Histology, 1880.
7. LEGROS and
 MAGITÔT . { Origine du Follicule Dentaire. Journal de
 l'Anatomie, 1873.
8. MAGITÔT . . . Traité de la Carie Dentaire, 1867.
9. MASON. . . { Irregularities of the Teeth, Transactions
 Odontological Society, Vol. V. New Series.
10. MILLER . . . Organisms of the Mouth, 1889.
11. NEUMANN, E. { Dental Caries. Archiv. für klinische Chirurgie,
 Bd. VI.
- 11A. QUINBY . . . Notes on Dental Practice, 1883.
12. SALTER. . . . Dental Pathology and Surgery, 1874.

13. SEMON. . . { Empyema of the Antrum, Transactions,
Odontological Society, 1889.
14. SUTTON, . . . { Dermoids, 1890. Numerous Papers on Dental
BLAND. . . { Pathology, Transactions Odontological So-
ciety, &c., 1883 to 1890.
15. SEWILL. . . Irregularities of the Teeth, Lancet, 1870.
16. „ . . { Alcohol in Dental Operations, Transactions
Odontological Soc. Vol. VII. New Series.
17. „ . . { Etiology and Pathology of Dental Diseases,
Journal of British Dental Association, Sep-
tember and October, 1882.
18. „ . . { Dental Caries and the Prevention of Dental
Caries, 2nd Edition, 1888.
19. TOMES, . . . { The Attachment of Teeth, Transactions
CHARLES S. { Odontological Soc. Vol. VII. New Series.
20. „ . . Dental Anatomy, 3rd Edition, 1889.
21. TOMES, Sir . . . { System of Dental Surgery, 3rd Edition, 1887.
J. and C. S. }
22. TALBOT. . . Irregularities of the Teeth, 1888.
23. UNDERWOOD, . . . { British Medical Journal, 1880.
A. . . }
24. „ . . Journal of British Dental Association, 1882.
25. UNDERWOOD, . . . { Effects of Organisms upon the Teeth, &c.
A., and . . . { Transactions International Congress, 1881.
MILLES, W. }
26. UNDERWOOD, . . . { On Erosion, Trans. Odon. Soc., 1888.
A. . . { Aids to Dental Surgery, 1889.
27. WALDEYER. . . { Structure and Development of the Teeth,
Stricker's Histology.
28. WEDL . . . Pathologie der Zähne, 1870.
29. WEDL (with . . . { Atlas zur Pathologie der Zähne, 1868.
HEIDER) . . }

DENTAL SURGERY:

INCLUDING SPECIAL ANATOMY & PATHOLOGY.

ANATOMY AND HISTOLOGY OF THE TEETH.

HUMAN TEETH are structures of bony character, implanted in the alveoli along the margins of the jaws for the purpose of triturating the food preparatory to its passage into the stomach. Two sets of teeth are developed during life; the first, the temporary, deciduous or milk teeth, ten in each jaw, and the second or permanent teeth, sixteen in each jaw.

The teeth are divided into classes according to their function and external configuration, but they have all certain characters in common. Every tooth consists of a *crown*, the portion which appears beyond the gum, a *root* or roots imbedded in the jaw, and a *neck*, the portion which unites the crown and root, and which is surrounded by the free edge of the gum.

The surfaces of the teeth are distinguished by appropriate names. That towards the lips is called the external labial or buccal; that towards the tongue the lingual or internal. The contiguous surfaces are best distinguished by the terms first used by Sir J. Tomes, namely, mesial for that nearest the middle line of the mouth—distal for that furthest away.

The permanent set is made up of four incisors formed for cutting, two canines for cutting and tearing, and four bicuspid and six molars for grinding the food.

The upper incisors have chisel-shaped crowns, the front surface convex, the back concave. Viewed laterally the crown is wedge-shaped, the base of the wedge being at the gum, the apex at the cutting edge. The cutting edge is horizontal, its distal angle being rounded, its mesial acute. Before becoming worn by mastication the edge is marked by three small tubercles which give it a serrated appearance. The root is single, conical, and slightly compressed laterally. The central are about one-third larger than the lateral incisors.

The lower incisors are similar in shape to the upper, but they are smaller, the root is more flattened at the sides, both angles of the cutting edge are acute, and unlike the upper teeth the lower central are less in size than the lateral incisors.

The canines, or eye teeth, are stronger than the incisors, to which they bear a general resemblance. The crown is convex anteriorly, concave posteriorly, and may be compared to that of an incisor with the angles bevelled off, and terminating in a sharp central cusp. These teeth have a single root which is stronger and longer than any other of the set. It is conical in shape and slightly more flattened laterally than that of an incisor.

The lower canines are smaller than the corresponding upper teeth, the cusp is more obtuse, the root more flattened at the sides.

The upper bicuspid viewed from the front, bear a close resemblance to the canines, than which however they are smaller. The crown springs vertically from the neck, its labial and lingual aspects being convex, its mesial and distal surfaces somewhat flattened; and its diameter across the jaw is thus the longer. The masticating surface is divided by a deep antero-posterior groove into two cusps, of which the inner is the smaller. The root is conical, and more compressed laterally than that of either the incisor or canine. It is deeply grooved

and often bifid, and the cleft, commonly in the first bicuspid, rarely in the second, divides the root throughout the greater part of its length.

The lower bicuspids in general characters resemble the upper, but are smaller. The internal cusp is less well marked, and the root is much compressed laterally, but very rarely bifid.

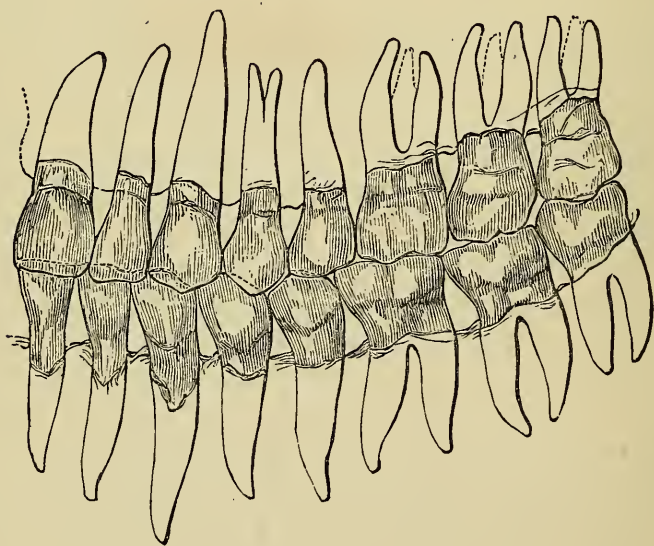
The molars have crowns of a cube-like form, the labial and lingual aspect rounded, the mesial and distal flattened. The grinding surface is divided by grooves into tubercles or cusps. The neck is rounded and well defined. The first molars of either jaw are the largest, the wisdom teeth the smallest of the series.

The masticating surface of an upper molar has four cusps, one at each angle, but in the third molar or wisdom tooth the internal cusps are blended into one mass. The first and second upper molars have three conical roots, two external spreading apart upwards towards the antrum, and one, the smallest, directed towards the palate. The latter is occasionally bifid. The root of the wisdom tooth is, as a rule, single, forming an irregular conical mass, which is often either deeply grooved or shows traces of subdivision into three roots. The crowns of the lower molars are a little larger than those of the upper jaw, and they are surmounted by five cusps, one at each angle, and the fifth between the two posterior cusps rather nearer the labial surface. The anterior internal is always much the largest, and is in the upper molars connected by a ridge of enamel with the posterior external cusp. Owing to the manner in which the upper teeth meet the lower, the inner cusps of the lower molars are higher (less worn down) than the outer, while the reverse is the case in the upper—*i.e.*, the inner cusps become always most worn down by use in mastication. The first and second lower molars have each two roots, one anterior and one posterior. In rare

cases a third root is present. The roots are broad, compressed, and grooved on the surfaces turned towards each other, and they have an inclination slightly backwards in the jaw. The root of the lower wisdom tooth, like that of the upper, is often connate, but occasionally it is bifid or divided into distinct fangs.

The entire set of teeth in each jaw are arranged in an elliptical curve, the incisors, canines and bicuspid forming an almost perfect semicircle, the molars and bicuspids continuing the lines backwards. The lower teeth are placed vertically in front and looking somewhat inwards at the sides and behind, whilst the corresponding upper

FIG. 1.



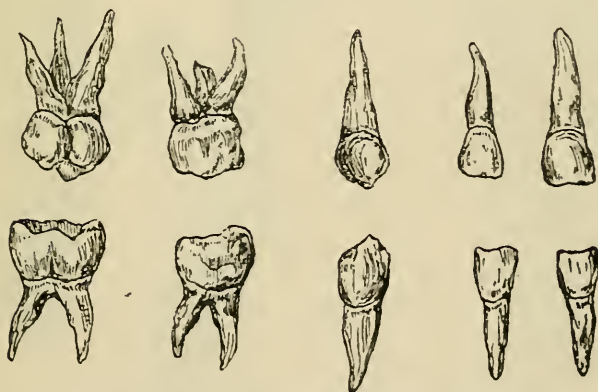teeth have an inclination forwards in front and outwards behind, so that the upper teeth slightly overhang the lower. In consequence of this arrangement and the difference in size between the teeth of the two jaws, each upper tooth on closure of the jaws impinges partly on the corresponding lower tooth and partly on the tooth

next following; but the upper dental arch being larger than the lower, and the upper molars being smaller than those of the lower jaw, the upper wisdom teeth do not extend backwards beyond the range of the lower teeth.

The teeth are fixed in position by implantation of their roots in the alveoli of the jaws, the bone, lined with periosteum, investing and accurately fitting them and providing a separate socket for each root. This form of articulation has been termed *gomphosis*, from its resemblance to the impaction of a nail driven into wood.

The annexed diagram from Wedl (27*) (fig. 1), shows at one view the form and character of a normal set of teeth, the direction and arrangement of the roots within the bone, and the relation of the upper and lower sets to each other when closed.

FIG. 2.



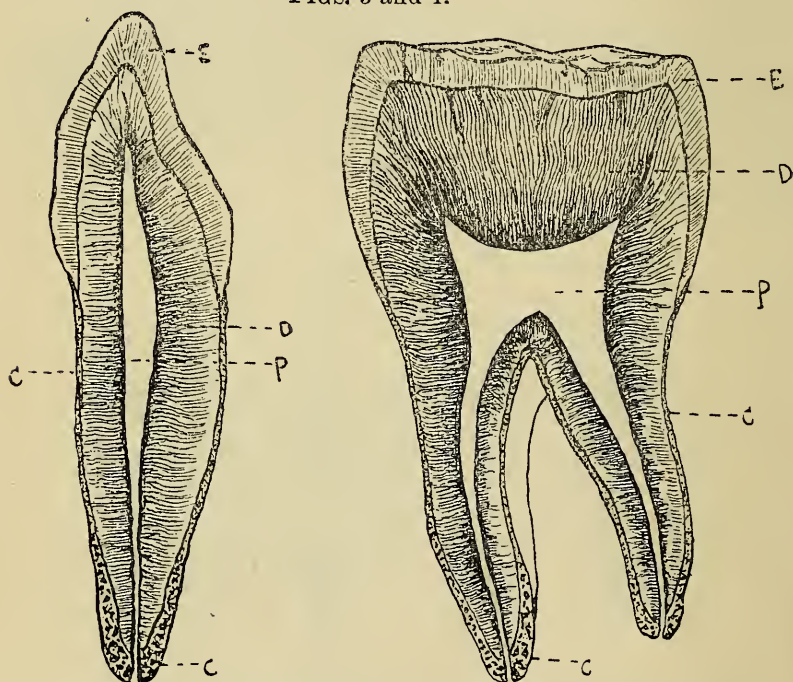
Upper and lower temporary teeth of right side.

The temporary teeth (fig. 2) resemble the permanent set, but are considerably smaller. There are no bicuspid in this set. It is made up of four incisors, two

* These numbers throughout the text refer to the list of authors at the beginning of the book.

canines, and four molars. The first upper molar is smaller than the second, and its crown has three cusps, two external, one internal. The second upper molar has four cusps. The first lower molar is smaller than the second, and has four cusps. The second lower molar has five cusps, three external, two internal. The roots of the temporary set are similar to those of the corres-

FIGS. 3 and 4.



Diagrams of vertical sections of upper canine and molar tooth.

E. Enamel.

D. Dentine.

C. Cement.

P. Pulp chamber.

ponding permanent teeth. The fangs of the molars are, however, more divergent from the neck of the tooth, and are hollowed on their inner aspect to afford space for the crypts of the developing bicuspid situated beneath them.

In the temporary set the enamel ends in an abrupt ridge at the neck of the tooth beneath the free edge of the gum.

The dental tissues.—On section (figs. 3 and 4), a tooth is seen to be composed of three tissues, distinct in structure, but intimately united with each other : enamel which covers the crown, cement which coats the roots, and dentine which forms the great bulk of the organ. When the teeth first make their appearance the enamel is covered by a thin layer of peculiar tissue, the *cuticula dentis* or Nasmyth's membrane, which, however, becomes soon worn off by mastication. In the centre of the tooth is the pulp cavity, a chamber similar in shape to the external outline of the tooth, and containing a vascular and nervous structure, the dental pulp. The vessels and nerves of the pulp enter through foramina in the apices of the roots.

Enamel forms a cap or layer adapted to the surface of the dentine. It attains its greatest thickness on the cutting edges and summits of the masticating surface of the teeth, whence gradually decreasing, it slopes towards the neck and terminates beneath the free edge of the gum, where it is slightly overlapped by the cement. It is an extremely hard translucent substance, either of a yellowish or of a bluish white colour. It is the hardest tissue of the body, ranking in density with limpid quartz, and emitting a spark when struck with steel. It contains not more than from one to five per cent. of organic matter, ninety per cent. of calcium phosphate, with a trace of fluorine, and four to five per cent. of calcium carbonate, the remainder being made up of traces of magnesium phosphate and other salts. Enamel is entirely soluble in acids, leaving but the smallest trace of organic matter. It is devoid of sensibility.

Examined microscopically (figs. 5, 6, 7, 8) enamel is found to consist of solid fibres or prisms mostly hexagonal, but some nearly square, others nearly circular

lying parallel side by side, probably without any intermediate substance. Klein (6A) describes the prisms as aggregated into bundles, not quite parallel, but more or less slightly overlapping one another; and he also believes the prisms are separated by a very fine hyaline

FIG. 9.

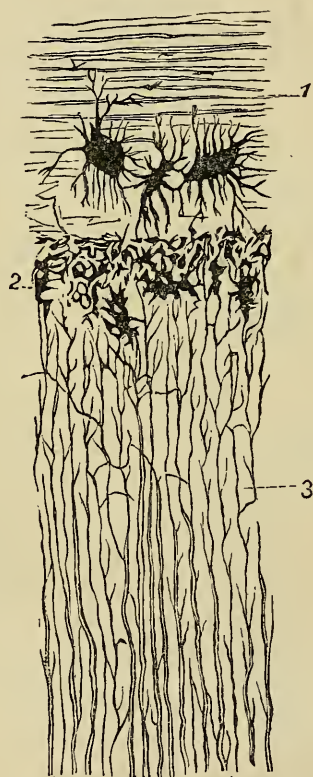



Diagram of transverse section of root of a canine tooth.
1. Cement. 2. Granular layer. 3. Dentine.

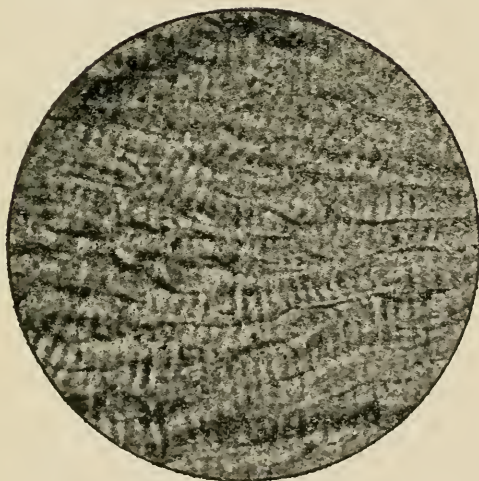
interstitial substance. Bödecker (2) some years ago stated that by staining enamel in thin section with chloride of gold, he had demonstrated the existence of "an active protoplasmic network" occupying minute spaces and forming an intervening substance between

FIG. 5.



Section of Enamel. $\times 75$, showing the general course of the prisms. The point of junction with Dentine is seen below.
Photo-micrograph by Mr. Charters White.

FIG. 6.



Section of Enamel, stained with chloride of gold. $\times 650$. The prisms are here seen under high magnifying power. Section cut by Mr. A. Underwood. Photograph by Mr. A. Pringle.

FIG. 8.

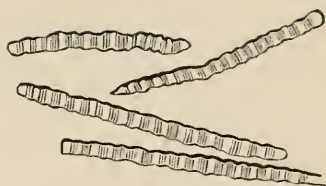

Diagram of Enamel Prisms separated and viewed laterally.

FIG. 7.

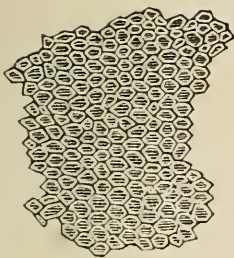


Diagram of Enamel in transverse section showing form of prisms.

the prisms. There is great reason to doubt the correctness of these observations, which have received no confirmation by other observers. The amount of organic matter in normal fully calcified enamel is so small that if equally distributed throughout it must be in a condition of such extreme tenuity that it is hardly possible it could be demonstrated or could have any physiological importance. Bödecker's observations served as a foundation for some speculations with regard to the etiology and pathology of caries, and they are therefore further discussed in the chapters on those subjects.

Enamel fibres spring from depressions on the surface of the dentine, and radiating outwards in an undulating course towards the exterior of the tooth, their direction varies between vertical at the masticating surface and horizontal at the sides. Most of the fibres extend through the whole thickness of the tissue; and although they cannot be demonstrated, there must exist, probably, shorter fibres to fill up the intervals which would otherwise exist in consequence of the divergence of the longer prisms in their outward course. The diameter of the prisms is about $\frac{1}{5500}$ of an inch. They are mostly marked at short regular intervals by transverse striæ, so that each fibre resembles a sheath containing a line of granular masses, but this condition is not very visible in young and in dense well-formed tissue. The prisms (figs. 6 and 8), also show at intervals slight bulgings or varicosities. No generally accepted explanation of the origin of the striæ and varicosities had yet been made. They perhaps constitute the remaining trace or expression of the soft cell elements in which the tissue existed before calcification: The apparent decussation of the prisms, a peculiar pattern exhibited by enamel in section beneath the microscope, is not real. The tissue is made up of many layers, the fibres in each layer being parallel, but the direction pursued by fibres


of different layers varying considerably. The appearance of decussation is visible only under a high magnifying power, in a thin section which is made up of several layers of prisms, and which is of course transparent. Hence the crossing of fibres, which actually lie on different planes, gives rise to the apparent free decussation of prisms lying on the same plane.

Dentine or ivory forms the great bulk of the tooth, and encloses the central cavity. It is a yellowish-white elastic tissue, presenting a finely fibrous fracture, and intermediate in hardness between enamel and dense bone, which latter it resembles somewhat in its general aspect and chemical characteristics. It contains twenty-eight per cent. of animal and seventy-two of earthy matter. Treated with acids the earthy constituents are dissolved, and there remains a material called dentinal cartilage, which retains the form of the tooth, and which is precisely similar to the animal basis of ordinary bone tissue. The seventy-two per cent. of earthy constituents are made up of 64 parts of calcium phosphate, 5 of calcium carbonate, and 3 of magnesium phosphate and other salts, with a trace of fluorine. It will perhaps assist the reader's memory to consider these chemical compositions side by side in a tabulated form:—

TABLE OF CHEMICAL COMPOSITIONS OF DENTINE, ENAMEL, AND BONE.

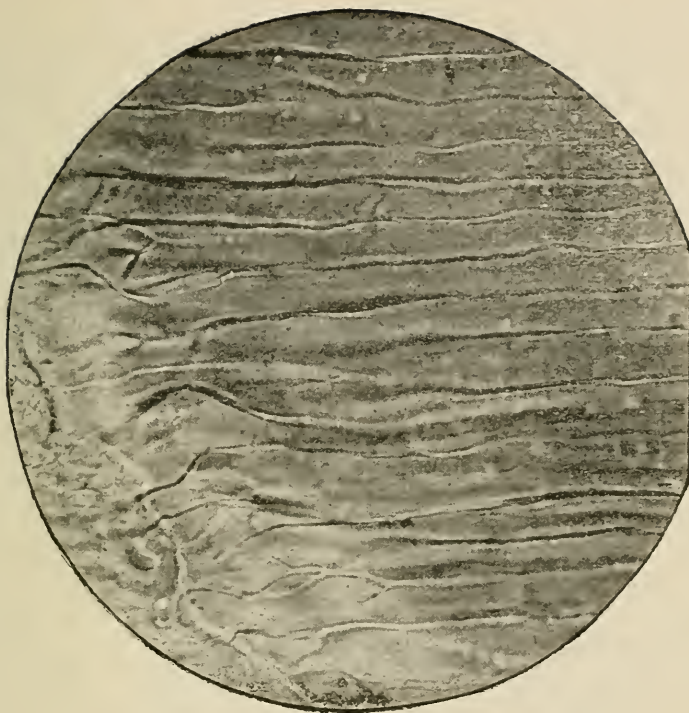
	Enamel.	Dentine.	Cement-Bone.
Organic matter	3.50	28.00	33.30
Calcium phosphate and fluoride	90.00	64.00	53.04
Calcium carb.	4.50	5.50	11.30
Magnesium phosphate ...	1.50	1.00	1.16
Other salts (chiefly sodium)	.50	1.50	1.20
	100	100	100

FIG. 10.



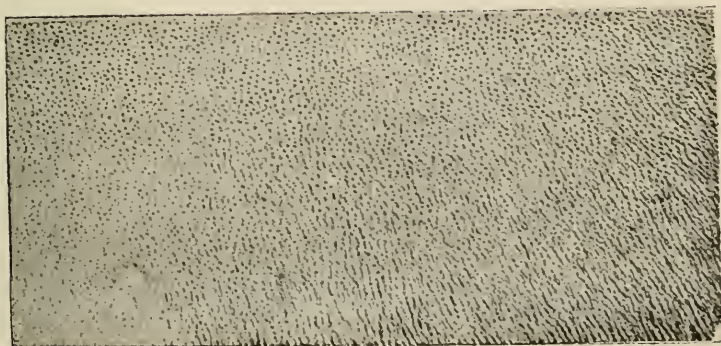
Vertical Section of Dentine.
× 175.
Photo-micrograph by Mr. Charters
White.

FIG. 11.



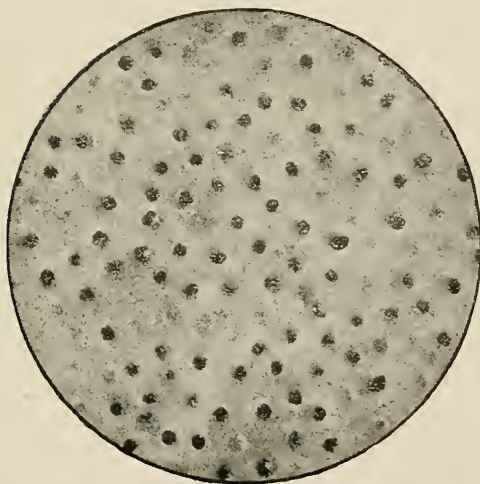
Vertical Section of Dentine, stained with carmine, × 650,
showing tubes. Above, on the left is the point of junction
with enamel into which tissue a few tubes are seen to penetrate.
Section cut by Mr. A. Underwood. Photo-micrograph by
Mr. A. Pringle.

FIG. 12.




Transverse Section of Dentine.
 × 50.
 Photo-micrograph by Mr. Charters
 White.

FIG. 13.



Transverse Section of Dentine. × 650.
 Photo-micrograph by Mr. A. Pringle.

FIG. 14.



Section of Cement. × 75, showing
 lacunae and canaliculi. The
 point of junction with Dentine
 is shown below.
 Photo-micrograph by Mr. Charters
 White.

Examined microscopically (figs. 9, 10, 11, 12, 13), dentine is found to consist of innumerable minute tubes having apparently distinct walls, and running close together through an intermediate substance—the intertubular substance or matrix. Commencing by open orifices on the walls of the pulp cavity, the tubes radiate outwards in an undulating course, giving off numerous branches, which freely anastomose. In the upper part of the crown they have a vertical direction, towards the sides they become oblique, then horizontal, finally incline downwards towards the point of the root. Each tube as a rule extends throughout the whole thickness of the tissue. Their diameter is about $\frac{1}{4500}$ of an inch, being larger at the inner ends than at a distance from the pulp cavity. They are also more close together near the pulp, there being less matrix between them. The distance between adjacent tubes is about two or three times their width. The tubes and their branches are occupied by soft fibrils which anastomose; and it can be shown, by staining with chloride of gold, that they form a continuous network. These fibrils seem to spring from the central pulp, and they appear to be continuous with elongated processes of the odontoblasts, the special cells of the pulp. The inner surfaces of the tubes surrounding the fibrils are called the dentinal sheaths or sheaths of Neumann. These sheaths are probably in an intermediate condition between the fully calcified matrix and the wholly uncalcified fibril. It is stated that the only difference between these three tissues, matrix, tube, and fibril, is that they represent different degrees of calcification of the same tissue. That there must, however, be some further difference is obvious from the fact that the tubes are plainly discernible in interglobular spaces where no calcification whatever has taken place. The sheaths can be demonstrated most clearly after removal of the fibres by maceration, and they remain as a white

fibrous felt even after boiling in strong muriatic acid, or in caustic alkalies. Vascular canals proceeding from the pulp (common in the teeth of some mammalia) sometimes occur as rare abnormalities in human dentine. They are usually minute.

The dentinal tubes terminate in the crown by fine processes (fig. 11) which either anastomose or become extremely minute, and are lost beneath the enamel, into which tissue, however, a few may penetrate. In the root (figs. 9 & 14) they end beneath the cement, by opening into the irregular spaces of the granular layer, and frequently passing through to anastomose with the contents of the canaliculi.

The intertubular substance or matrix is translucent and without any visible structure. It contains the greater part of the earthy constituents of the dentine.

The granular layer of the root (figs. 9 & 14), which exists between the dentine and cement, may be said to constitute the line of transition where these tissues blend. The layer is made up of granules or minute globules, and contains numerous spaces apparently due to imperfect coalescence of these elements. Into these spaces (as above mentioned) the dentinal tubes open, and the spaces are again connected with the lacunæ of the cement by fine canaliculi.

Dentine is endowed with a considerable amount of sensibility, due to the soft fibrils which permeate its tubes, and which, as we have seen, directly emanate from the pulp. The sensibility of healthy dentine varies very much in the teeth of different individuals and in different parts of the same tooth. It is always more marked immediately beneath the enamel than deeper, until the pulp chamber is approached. The sensibility disappears when death of the pulp takes place.

Owing to their minuteness it has hitherto been impossible to demonstrate the exact character of the dentinal fibrils, although the attempt has been made to prove

that they are really extremely fine filaments proceeding from the nerves of the pulp. It has however been conclusively shown that whatever their structure, to them the sensibility of dentine is due. Mr. Charles Tomes has pointed to some facts which establish this view, and prove that the sensibility is not, as has been suggested, due merely to transmission of vibrations through an inert conductor to the pulp. For instance, the peripheral sensibility of dentine can be allayed by applications which do not affect the pulp; and it often happens that a sensitive layer of dentine overlays a less sensitive portion placed deeper and closer to the pulp. These circumstances can only be explained by the supposition that the seat of sensibility lies within the tissue.

Cement (figs. 9 & 14) forms a thin layer, which, commencing at the neck, where it slightly overlaps the enamel, gradually increases towards the apex of the root. It is a true bone structure, having the same chemical and microscopical characters as that tissue. Existing only in a thin layer in man, cement is, however, destitute of Haversian canals. It contains, as a rule, canaliculi throughout, and lacunæ at its thicker parts, enclosing during life protoplasmic contents which form by anastomosis a continuous network. Canaliculi and lacunæ may be wanting where the tissue is extremely thin. In the latter case it presents on section a perfectly homogeneous appearance.

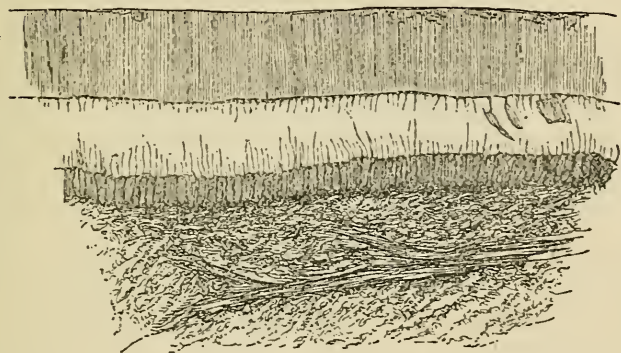
The cement is invested with periosteum which is directly continuous with the periosteum of the jaw. It unites the cement to the socket, and consists of a single layer, not two as used to be supposed. The fibres of this periosteum run obliquely upwards from the cement to the socket. It is a delicate connective-tissue membrane, containing abundance of vessels and nerves, which are derived from those of the submucous tissue, from those which supply the pulp, and from those of the contiguous alveolar wall.

Nasmyth's membrane is an extremely thin homogeneous layer, covering the enamel. It exists only on young teeth which have not been long used in mastication. It resists the action of the strongest mineral acids, but softens when boiled in caustic potash. Although other theories as to its nature exist, the majority of authorities are agreed that Nasmyth's membrane is merely a thin layer of cement modified in structure, and exactly homologous with the thick coronal-cement found on the teeth of herbivorous animals. This theory has been confirmed by the investigations of Mr. Charles Tomes (16), who has especially pointed out that coronal cement of well-marked structure, containing lacunæ and canaliculi, occasionally occurs in human teeth, and that when such a layer does not exist it may be often found that sulci or fissures of the enamel such as commonly exist between the cusps on the masticating surface of molars are filled with a bone-like tissue continuous with Nasmyth's membrane.

The dental pulp which occupies the central cavity consists of the remains of the original papilla from which the dentine was developed. It is composed of fine fibrous connective tissue, containing numerous cells, and is well supplied with blood-vessels and nerves, which enter through small foraminæ in the apices of the roots. Mr. Charles Tomes describes the pulp as being made up of "a mucoid gelatinous matrix" containing cells in abundance, and but little connective tissue. The outermost cells of the pulp—that is, those that immediately line the dentine—are of a special form, larger and more regular than the others, and are known as the *membrana eboris*, or odontoblast layer. Each odontoblast is oval or pear shaped, with a well marked nucleus at the end farthest from the dentine, and has several sets of processes; some of these processes seem to penetrate the canals in the dentine to become the fibrils, although (as above stated) some obser-

vers believe it probable the fibrils are really nerve endings derived from the pulp beneath the odontoblast layer through which they pass. Boll has especially supported the latter view. He was the first to point out the great number of non-medullated nerves in the superficial part of the pulp tissue, and to show that they ascend between the odontoblasts towards the tubuli into which he believed they entered as fibrils. Boll's opinion receives support from recent demonstrations of the peripheral terminations of intra-epithelial nerve fibrils of the skin, cornea and mucous membranes. These fibrils which

FIG. 15.



cannot be much less minute than those occupying the dentinal tubes, might be considered, perhaps, homologous with them.

Processes connect each cell with its odontoblast neighbours on either side while others again join the processes of underlying pulp cells. By means of these last mentioned anastomoses, it may be presumed the odontoblast layer is directly continuous with the terminal nerve filaments in the pulp, while, in the other direction, the fibrils extend through the dentine and anastomose with the protoplasmic network of the cement.

Fig. 15 from Tomes (20) illustrates the anatomy of the pulp. The drawing represents a section from a half

formed human incisor stained with carmine. From the surface of the odontoblast layer which in the preparation is detached from its connection with the wall of the pulp cavity project dentinal fibrils, torn ends of which hang from the orifices of the tubes above. A vessel ramifies close to the surface.

Lymphatics have not yet been demonstrated in the pulp.

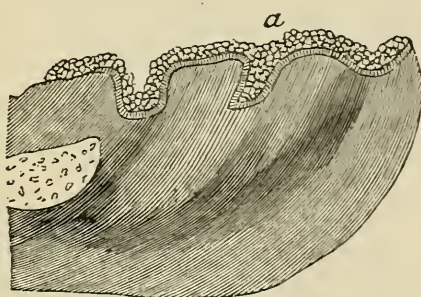
As age advances, gradual calcification of the pulp takes place, until at last it is reduced to a few fibrous filaments, with the remains of vessels and nerves. Mr. C. Tomes describes a process of degeneration which occurs in the remains of the pulp in advanced age, by which it becomes reduced to a shrivelled unvascular insensitive mass.

The tissue resulting from calcification of the pulp is called secondary dentine. In some cases calcification commences in the external layer of odontoblasts, and the new formed tissue coalesces from the first with the previously formed dentine, and the tubes of the two are continuous. In other cases secondary dentine is deposited in isolated nodules scattered through the pulp. These nodules sometimes unite and form larger masses, which again may become attached to the walls of the pulp cavity. The masses of secondary dentine are occasionally traversed by canals containing blood-vessels, and surrounded by concentric lamellæ, like the Haversian canals of bone.

DEVELOPMENT OF THE TEETH.

THE first trace of dental development in man is visible to the naked eye as early as the seventh week of intra-uterine life, when the embryo is not more than one inch and a quarter in length. This trace consists of a smooth oval ridge extending along the whole length of the

FIG. 16.



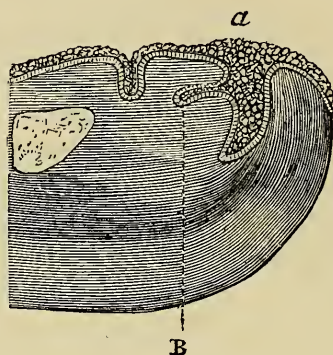
Section of the incisive region of the lower jaw of an embryo sheep, magnified eighty diameters. (Dental development in the sheep and in man is identical.)

a. Epithelial ridge or band which extends the whole length of the maxillary arch, but of which the section only is here visible. From this band the epithelial lamina will be given off later.

rudimentary alveolar border (*a*, fig. 16). Section of this ridge shows it to be a continuous vertical band composed of a thick layer of epithelial cells, and it is, in fact, a prolongation of the epithelial layer of the mouth which has sunk into the embryonic tissue of the jaw. Before the end of the eighth week there has become developed, at about the middle of the buried or deep surface of the ridge, a projection or lamina (*b*, fig. 17), which, like the

layer from which it is derived, extends the whole length of the maxillary border. Its shape is a little flattened

FIG. 17.

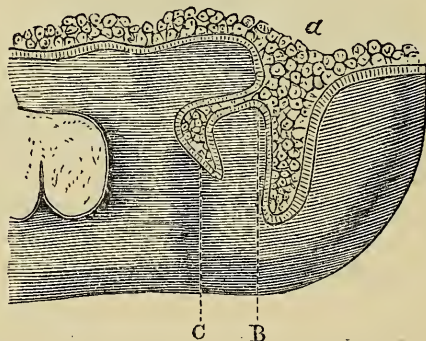


Section of the incisive region of the lower jaw of an embryo sheep, magnified eighty diameters.

A. Epithelial ridge.

B. Epithelial lamina originating from the epithelial ridge.

FIG. 18.



Section of the ramus of the lower jaw of an embryo sheep, magnified eighty diameters.

A. Buccal epithelium and epithelial ridge.

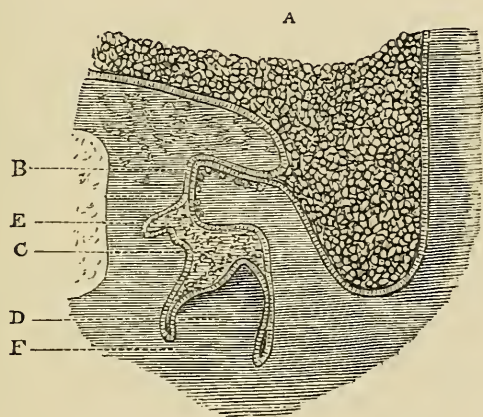
B. Epithelial lamina.

C. First appearance of the enamel organ.

from above downwards, with its extremity rounded and curved in the form of a crook. It is composed externally

of columnar cells of the deep or Malpighian layer of the mucous membrane, internally of squamous cells. Within a few more days there can be demonstrated along the border of the epithelial lamina in each jaw a series of ten small club-shaped enlargements (c, fig. 18). These enlargements or buds are the rudimentary enamel organs of the temporary teeth, and they are situated at intervals corresponding to the position of the future teeth. The

FIG. 19.



Section of the ramus of the lower jaw of an embryo sheep,
magnified eighty diameters.

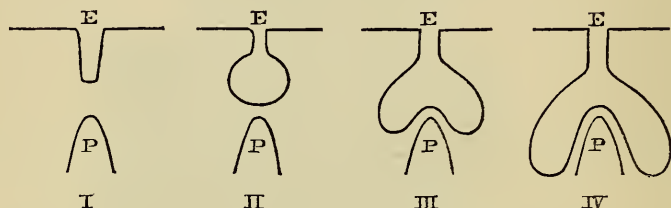
- | | |
|---|-----------------------|
| A. Buccal epithelium. | B. Epithelial lamina. |
| C. Enamel organ. | D. Dentinal pulp. |
| E. First appearance of the enamel organ of the permanent tooth. | |
| F. Fibrous tissue whence is derived the dental sac. | |

shape of each bud is at first like the finger of a glove pushed into the submucous tissue, then the end swells, becoming much bigger than the neck, and it is flask-shaped, with its central or lowest point directly over the future dentine papilla. The apex of the future papilla arrests the further descent of this central part, but the sides continue to descend all round the papilla, envelop-

ing it in a double layer, and assuming the shape that an india-rubber ball takes if a finger be pushed against it.

The annexed drawing (fig. 20) represents diagrammatically four stages of the descent of the enamel organ on to the dentine papilla. It must be borne in mind that this is supposed to be only a section of the object, and also that the papilla is not visibly differentiated so early.

FIG. 20.



The buds—the rudimentary enamel organs of the temporary teeth—are composed of the same epithelial elements as make up the lamina, and they are destined by subsequent deposit of calcareous matter to become the external or enamel layer of the crown of the tooth. They remain for some time united to the lamina by a narrow portion in the form of a neck, which grows longer as the enamel organ increases in size. The enamel organs soon begin to assume the form of the crowns of the future teeth, but at first their shape is not well defined, and resembles a cap with the concavity directed towards the depths of the jaw.

By this time (the ninth week) the first appearance of the dentinal pulp may be detected. This pulp (p, fig. 19) eventually becomes converted by calcification into the dentine or ivory forming the bulk of the tooth. Its elements first manifest themselves in the depths of the jaw independently of the enamel organ, but directly contiguous to its deeper surface. The pulp at first con-

sists of a small papilla composed of nucleated cells, and penetrated by a vascular loop, and it is, in fact, at this stage merely a special division of the mucous tissue unusually rich in vessels and cells. Later on, when it has assumed more definite shape, nerve filaments can be traced into it. It grows until it impinges upon the enamel organ, which becomes moulded upon it like a cap, whilst the papilla gradually assumes the form of the crown of the future tooth. Thus, for the incisors it becomes conical, and for the molars develops outgrowths corresponding to the cusps of these teeth.

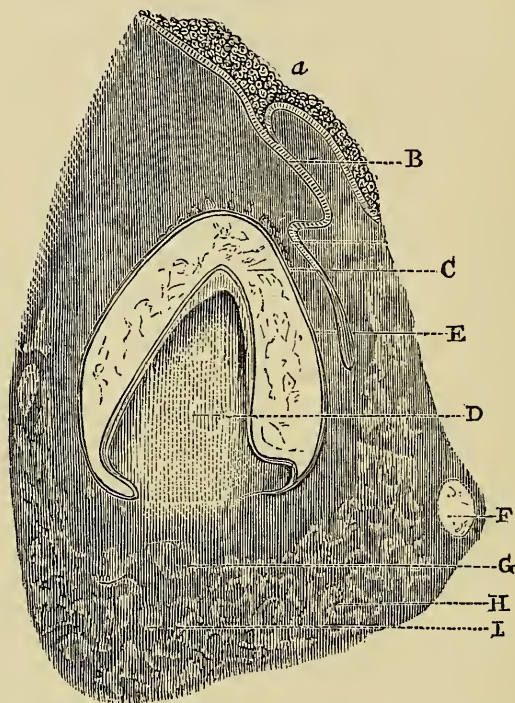
By the beginning of the fourth month each rudimentary temporary tooth has become enveloped in a distinct closed sac composed of sub-epithelial connective tissue. This sac begins to appear as soon as the dentinal pulp is slightly advanced in development. An opaque fibrous outgrowth springs from each side of the base of the pulp, and grows towards the summit of the tooth, where it unites with that of the opposite side, and so forms the dental sac. By this time the connection between the enamel organ and the epithelial process from which it emanated has become severed, owing to absorption of the uniting neck or band of epithelium at the surface of the sac, and this absorption slowly progresses until the whole of the process disappears, leaving the sac completely isolated.

The origin of the permanent set, consisting of sixteen teeth in each jaw, has now to be described. The enamel organs of the ten teeth which replace the temporary set—namely, the incisors, canines and bicuspid—originate from a bud for each tooth, which is given off from the elongated extremity of the epithelial lamina at its point of junction with the enamel organ of the temporary tooth (E, figs. 19 and 21).

The enamel organ of the first permanent molar is given off from the posterior extremity of the same

epithelial band as gave origin to the temporary teeth. From the epithelial process of this enamel organ a bud springs for the second permanent molar in exactly the

FIG. 21.



Section of the incisive region of the lower jaw of a human embryo.

(In this preparation the epithelial cord or process whence is developed the enamel organ of the permanent tooth, is seen partly isolated from its origin in the follicle of the temporary tooth.)

- A. Buccal epithelium.
- B. Epithelial process or cord of the temporary follicle.
- C. Enamel organ.
- D. Dentinal pulp covered by a small cap of dentine.
- E. Epithelial cord, whence is developed the enamel organ of the permanent tooth.
- F. Rudimentary cartilage of the jaw.
- G. Section of the dental artery.
- H. Traces of ossific matter in the jaw.
- I. Section of the dental nerve.

same manner as the permanent successors of the temporary set were evolved from the epithelial processes of that set. In a precisely similar fashion the enamel organ of the third molar, or wisdom tooth, arises from the epithelial process of the second molar.

These sixteen germs in each jaw constitute the first traces of the permanent teeth, and they each pass through the same phases of development as we have seen undergone by the germs of the temporary set, these phases being the appearance of the dentinal pulp, its junction with the enamel organ, and their enclosure in the sac. The only further difference to be noted between the development of the permanent and deciduous teeth is in the time which particular teeth take to pass through the successive stages of evolution. For example, the temporary teeth are usually all cut by the third year, whilst the first permanent molar, although its germ appears at the fifteenth week of foetal life, is not erupted until the sixth year. Similar remarks apply to the rest of the permanent set; but it will suffice now to give the dates of the phases of their development so far as above described. The enamel organs of the incisors, canines, and bicuspid make their appearance about the sixteenth week of intra-uterine life; those of the first permanent molars about the fifteenth week; those of the second molars about the third month after birth; and those of the wisdom teeth can be demonstrated towards the third year. The dentinal pulps of the ten first-mentioned teeth appear at the twentieth week of foetal life; those of the first molars at the seventeenth week; those of the second molars about the first year after birth; and those of the wisdom teeth towards the end of the sixth year. The complete closure of the sacs of these teeth is accomplished in the order in which they have been above mentioned at the following dates—9th month, 20th week, 1st year and 6th year.

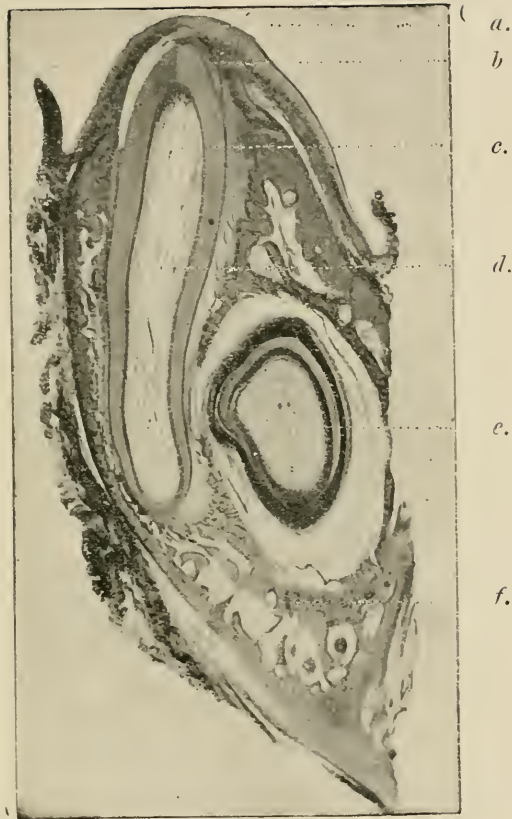
The preceding figures illustrating this subject, although sufficiently correct, are diagrammatic in character. The appearances and anatomical relations of the parts in the later stages of evolution of the teeth, are shown with exquisite clearness and exactitude in Mr. Charters White's photographs (figs. 22, 23 and 24).

The histological changes which take place in the tooth germ by which its elements are gradually converted into the dental tissues, must be now more fully described.

It has been seen that the enamel organ (figs. 18 and 19) when first formed is composed entirely of epithelial cells—externally of the columnar, internally of the squamous variety. It retains its epithelial nature throughout the process of calcification. This process begins at the surface of the dentine, and progresses outwards. Prior to deposition of earthy matter the columnar cells immediately in contact with the dentine increase greatly in length, and form six-sided prismatic bodies so arranged as to constitute a columnar epithelium, which, according to Waldeyer, is the most beautiful and regular found in any part of the body. This layer is called the internal epithelium of the enamel organ. The external cells of the enamel organ (termed external epithelium) are shorter and more cubical in form. Numerous vascular papillæ, arising from the contiguous tissue of the dental sac, penetrate to a slight depth the external epithelium, and serve doubtless to provide nutriment to the developing tissue. The cells forming the interior of the organ undergo transformation during the formation of the enamel. At first small and round, they soon become stellate in form, united with each other by their processes, and from the cells of this layer (called stratum intermedium), in contact and united with the internal epithelium, a continuous development of columnar enamel cells proceeds.

It has been just stated that the deposition of calca-

FIG. 22.



Section of Lower Jaw of Fœtal Kitten, with Temporary Tooth and permanent successor *in situ*. $\times 24$ diameters.

Photo-micrograph by Mr. Charters White.

a.—Gum.

b.—Enamel.

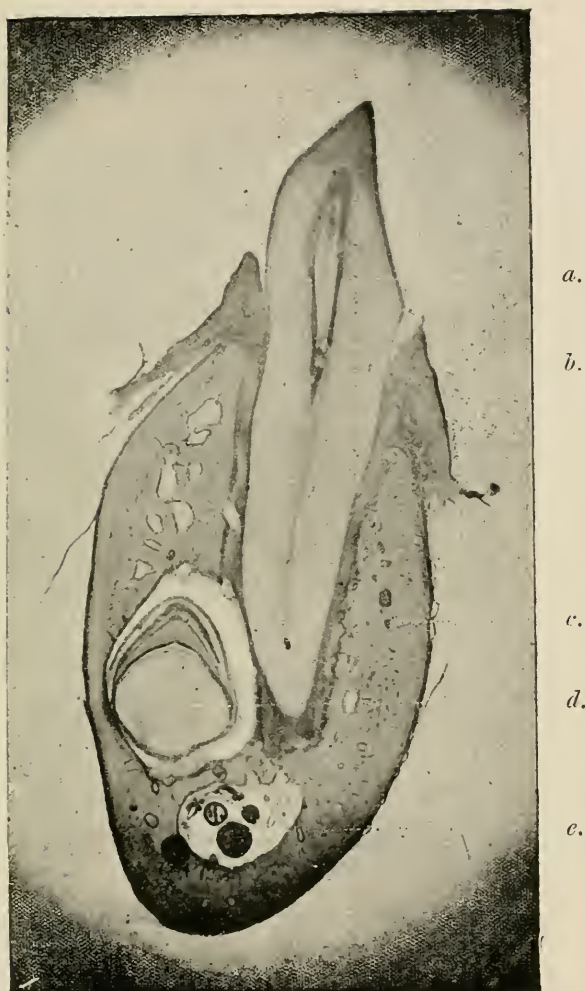
c.—Dentine.

d.—Dental pulp.

e.—Permanent Tooth enclosed in Sac.

f.—Jaw partly ossified : and Section of Inferior Dental Artery and Nerve.

FIG. 23.



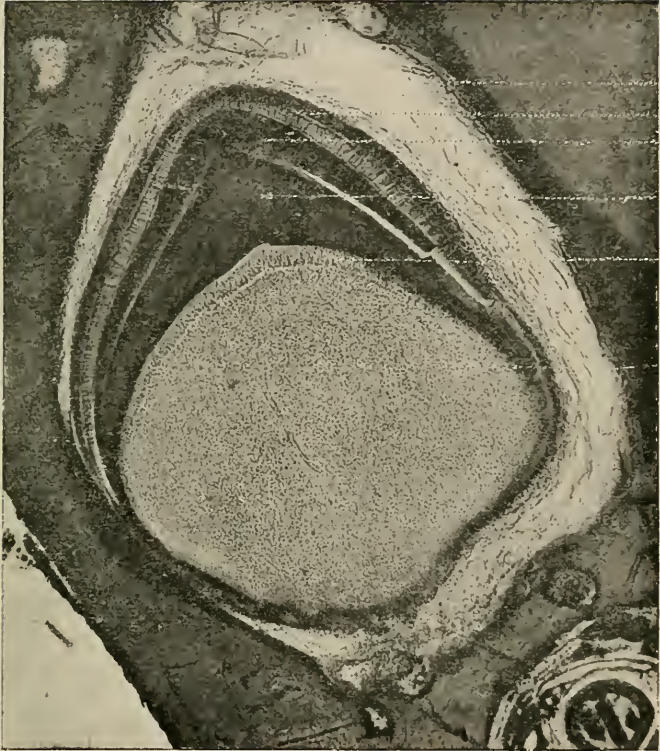
Section of Lower Jaw of Kitten, with Temporary Canine fully erupted and permanent successor *in situ*. $\times 10$.

Photo-micrograph by Mr. Charters White.

- a.*—Deciduous Canine.
- b.*—Mucous Membrane of Gum.
- c.*—Inferior Maxilla cartilaginous : with islands of forming Osseous Tissue.
- d.*—Permanent Canine in its sac.
- e.*—Inferior Dental Canal, and Section of Dental Artery and Nerve.

To follow plate 22.

FIG. 24.



Developing Permanent Tooth, shown in Fig. 23, more highly magnified. $\times 34$ diameters.

Photo-micrograph by Mr. Charters White.

- a.*—Dental Sac.
- b.*—Enamel Organ.
- c.*—Formed Enamel.
- d.*—Formed Dentine.
- e.*—Odontoblast layer.
- f.*—Dentinal Pulp with traces of Vessels.

reous matter commences in the enamel organ at the surface of the dentine and proceeds outwards. The completed tissue results from direct calcification of the internal epithelium. The calcification progresses from the periphery of each cell towards its centre, at the same time uniting together the contiguous columns. Prior to the completion of the enamel the external epithelium and remaining portion of the stratum intermedium undergo atrophy. These cells ultimately disappear, or perhaps, as some observers state, they take part in forming Nasmyth's membrane (*cuticula dentis*), the thin layer of tissue which envelops new-formed enamel.

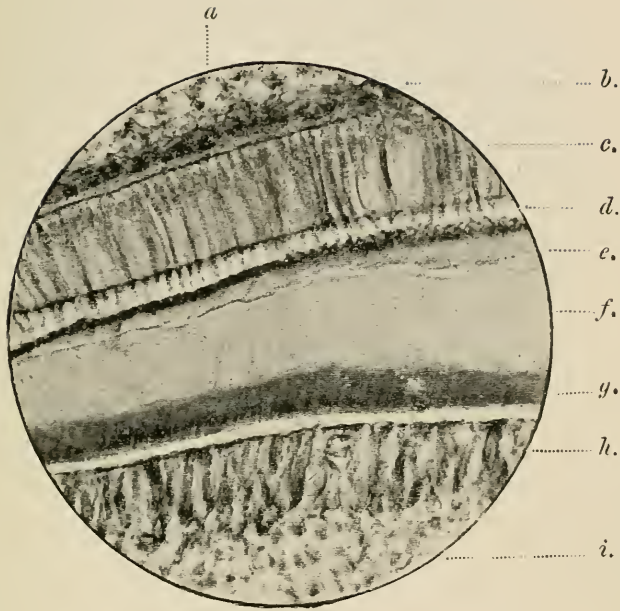
Although the difference of opinion has no practical bearing on dental pathology or surgery, since all observers are agreed on the main point, namely, that enamel is developed through the medium of the cells of the enamel organ, it may be mentioned that some investigators believe that the calcareous matter is deposited by the cells, and that the cells do not themselves undergo calcification.

Let it be here noted as a point the importance of which, in discussing the nature of dental caries, will be apparent later, that study of the histogenesis of enamel shows that the tissue once formed is entirely cut off by the intervening mass of dentine from direct vascular connections, and that when fully calcified, the completed tissue being devoid of cellular or protoplasmic elements, cannot afterwards be the seat of physiological processes or undergo any change due to influences arising from within. The later stages of the histogenesis of enamel are illustrated in figs. 25 and 26.

Calcification of the dentinal pulp begins before that of the enamel organ. The process by which the conversion is effected closely resembles the histological formation of bone. It commences at the external surface and proceeds inwards, the central portion with the vessels and nerves remaining to constitute the persistent dental pulp

or "nerve" of the tooth. The dentinal pulp (as already mentioned) at first consists of a special division of the rudimentary mucous tissue, rich in vessels and cells. Its fibrous elements consist of a fine connective tissue, through which the cells are scattered. When the pulp has arrived at a certain stage of development the cells begin to be specially organised and arranged. By this time the pulp contains numerous nerve fibrils besides blood-vessels. The latter form a plexus close to the surface. The specialized cells are termed odontoblasts. They are developed from the cells lying at the periphery, where they become arranged in a layer so as to form a kind of columnar epithelium. This layer is termed the *membrana eboris*. The cells are finely granular, have no membrane, and contain a large rounded nucleus. They are each provided with numerous processes, which unite them with the contiguous odontoblasts, and with subjacent developing cells. The nuclei of the odontoblasts gradually disappear, and the cells become converted into a gelatinous material which undergoes direct calcification, and forms the whole of the hard constituents of the dentine. The changes take place from the periphery of each cell towards the centre. It is believed by most investigators that the central portion of each cell remains uncalcified, and forms the soft fibril which occupies the completed dentinal tube. The other views regarding the nature of the fibrils have been given in previous pages. The *membrana eboris* is constantly fed from the deeper layer of cells, which, united with the odontoblasts by means of their processes, form an uninterrupted series; and provide for the continuity of the dentinal tubes and fibrils. The layer of matrix immediately around the fibrils becomes converted into the dentinal sheaths—the lining walls of the tubes. It has not yet been ascertained whether the sheaths are calcified or not, since their structure cannot be examined except after maceration.

FIG. 25.



Section of Developing Tooth of Dog. $\times 260$.

Cut and stained by Mr. A. Underwood.

Photographed by Photo. Company.

- a.* Outer layers of enamel cells.
- b.* Stratum Intermedium.
- c.* Enamel Cells.
- d.* Formed but Uncalcified Enamel.
- e.* Calcified Enamel.
- f.* Calcified Dentine.
- g.* Formed but Uncalcified Dentine.
- h.* Odontoblasts.
- i.* Pulp Tissue.

FIG. 26

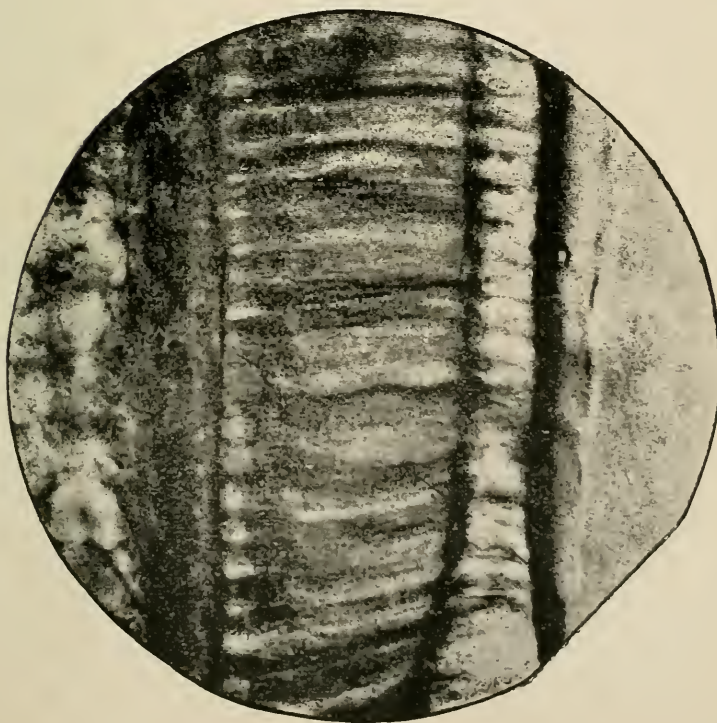


FIG. 27.

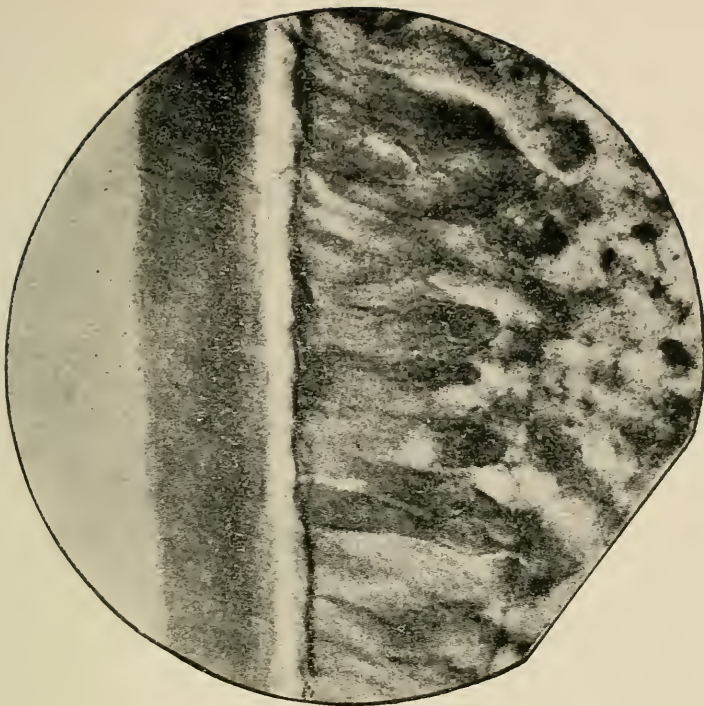


Fig. 26 exhibits, under higher magnifying power, the Enamel portion, Fig. 27 the Dentinal portion, of the section shown in Fig. 25. $\times 650$.

Photo-micrograph by Mr. A. Fringle.

The later stages of the histogenesis of dentine are illustrated in figs. 25 and 27.

By the end of the seventeenth week of intra-uterine life a cap of dentine may be demonstrated on the pulps of all the temporary teeth. By the sixth month the first permanent molar has advanced to a similar stage of development. By the first month after birth the permanent incisors and canines are advanced to the same stage; and at the third year and twelfth year respectively, calcification has commenced in the second molars and wisdom teeth.

The entire crown of each tooth is represented in soft tissue before deposition of earthy salts commences, and as the tooth elongates by growth of the pulp from below successive portions undergo calcification to form the root.

The development of cement has not been made out beyond dispute. It probably takes place in a matrix formed by the investing fibrous coat of the dental sac. A special cement pulp has not been demonstrated in man. Cement is, in fact, a thin layer of bone, and the process of its formation is in all probability similar to intra-membranous ossification of other bones.

The cuticula dentis (Nasmyth's membrane), is believed by some authorities to be formed from the residuum of the pulp of the enamel after the completion of that tissue. It is, however, much more probable, as stated on a previous page, that it is merely a thin layer of modified osseous tissue continuous with the cement, having a similar origin, and homologous with the coronal cement found on the teeth of certain herbivorous animals.

GROWTH OF THE JAWS.

FIRST AND SECOND DENTITION.

COMMENCING as early as the fifth week of foetal life, ossification of the maxillary bones proceeds rapidly, and is well advanced at birth. The lateral halves both of the upper and lower jaws at this period are, however, still united in the median line by cartilage, and the growing alveoli of the temporary teeth are indicated by a deep trench, divided by incomplete bony plates into large crypts, in which the teeth lie enclosed by the dental sacs and submucous tissue. The temporary teeth are represented by their partly calcified crowns, the stage of development varying in the different teeth according to the period at which their eruption is destined to take place. Thus the crowns of the central incisors are nearly complete, whilst, as yet, the apices alone of the rudimentary crowns of the canines have become converted into a cap of calcified material.

During the first few months after birth, the development of the maxillæ is most active at the surface adjacent to the connecting cartilages and at the alveolar border. The alveoli increase in depth, and by the growth of their free margins overhang and protect the contained teeth. A little later they become nearly closed.

The age at which eruption of the temporary teeth commences varies somewhat in different individuals, but it is rarely earlier than the fifth, or later than the ninth month. Eruption of the teeth is a process of gradual elongation of the teeth on the one hand, and of simultaneous absorption of the superimposed tissues on the other.

The absorption commences first in the overhanging margins and front walls of the alveoli, which gradually disappear until room is afforded for the free passage of the advancing tooth. The growth of the tooth keeps pace with this absorption, and the crown at length pressing against its membranous coverings these undergo atrophy, and, becoming by degrees thinner, and at last transparent, give way and disclose the advancing crown.

It occasionally happens that these various actions are not perfectly harmonious in their course, the advance of the tooth being more rapid than the disappearance of the enclosing bony and soft tissues. The tooth is thus mechanically held in position, and irritation is set up, which manifests itself by inflammation and induration of the gums, and even by reflex nervous disorders, and constitutional disturbance of various kinds. This explanation, which, it must be admitted is far from satisfactory, is perhaps the best that can be given of the occasional undeniable connection between "teething" and infantile disorders; for although the connection seems taken as proved by most writers on infantile diseases, it is rare to find any attempt to trace the nervous phenomena to their source, and to explain the correlation between eruption of the teeth and the varieties of trivial and grave disorders commonly ascribed to this physiological process. That eruption of the teeth is a physiological not a pathological process, and need not, more than other similar processes of growth and development, necessarily be attended with morbid phenomena, is however a fact which is commonly lost sight of; and there can be no question that in a vast number of cases infantile diseases are ascribed to "teething" which have no relation whatever to the process of dentition, many of them being due to such causes as improper food and feeding. It is, however, the opinion of physi-

cians who have had the opportunity of watching large numbers of children, that even in perfectly healthy and well-managed infants a certain amount of local irritation, manifested by more or less slight swelling of the gums and augmented flow of saliva, is noticeable in most instances at the time of eruption of each tooth, and it is not difficult to understand that in some instances an increase of the local irritation may give rise to reflex disorders of various kinds. It is for the relief of disorders of dentition that the operation of lancing the gums of infants is performed. This operation has for its object the division of the abnormally indurated gum, and the release of the advancing tooth. It is obvious that the utility of this procedure must be extremely doubtful when it is carried out prior to the passage of the crown through the contracted bony orifice of the crypt in which the tooth lies ; but that the operation may be reasonably expected to afford relief in cases where the advancing tooth can be distinguished beneath the tense and swollen gum.

The order in which the temporary teeth are erupted seldom varies. The lower central incisors are the first which appear. They are followed, after an interval varying between a week and two or three months, by the corresponding members of the upper set. After another similar lapse of time, the lower, quickly followed by the upper lateral incisors, present themselves. Next, after like intervals, the first molars, and then the canines are protruded. Lastly, the second molars take their places, and complete the series. The annexed diagram (fig. 28) from Dr. Louis Starr's well known work, "Hygiene of the Nursery," may be helpful in fixing in the memory the order in which the teeth appear, and the approximate length of the pauses which intervene between the eruption of the different classes.

By the time that the eruption of the temporary teeth

is completed (between the second and third years), considerable progress has been made in the development both of the jaws and permanent teeth. The maxillæ have increased in size, and the fibro-cartilages uniting the lateral halves are completely ossified; the alveoli which had been absorbed to give exit to the teeth, have since

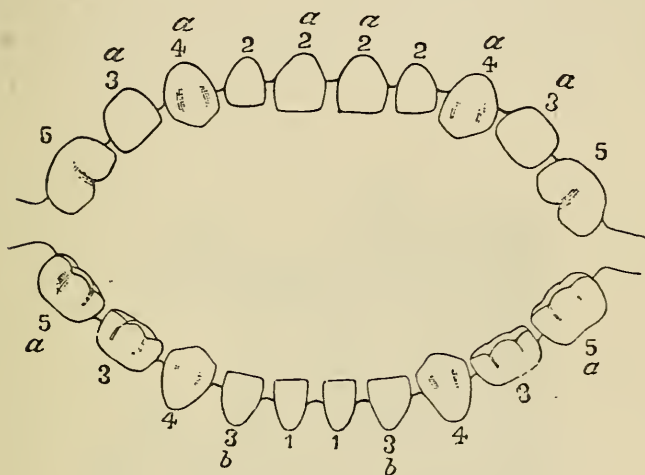


FIG. 28.

Diagram showing order of eruption of temporary teeth.

11, between fourth and seventh months. Pause of three to nine weeks. 2222, between eighth and tenth months. Pause of six to twelve weeks. 333333, between twelfth and fifteenth months. Pause until the eighteenth month. 4444, between eighteenth and twenty-fourth months. Pause of two to three months. 5555, between twentieth and thirtieth months. The numbers 1 to 5 indicate the order of eruption of the groups of teeth, and the letters *a* and *b* the precedence of eruption of members of each group.

grown up with the advancing organs, and now closely invest them; the angle of the lower jaw, which recently after birth is very obtuse, has become more acute, coincident with the development and lengthening of the ramus, and of the articular and coronoid processes.

Excepting those of the wisdom teeth, the crowns of the permanent set are all well advanced in calcification, their progress being, however, proportionate to the periods at which their complete evolution is due. The incisors, canines, and bicuspid are completely enclosed in bony crypts. The incisors are situated in the upper jaw above and behind, and in the lower jaw below and behind the roots of the teeth, which subsequently they respectively replace. The canines are deeply placed between the crypts of the lateral incisors and first

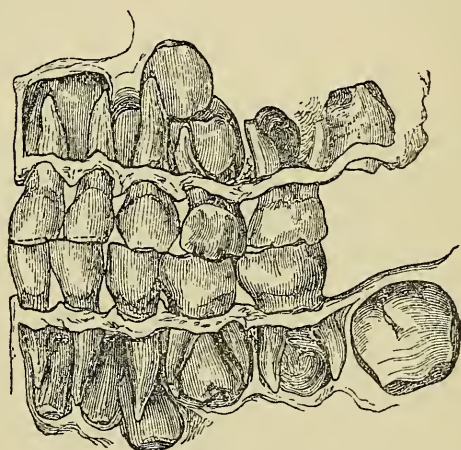


FIG. 29.

Well developed set of deciduous teeth (projected upon a plane), with crowns of permanent teeth enclosed in their crypts exposed by removal of alveolar wall. (Natural size.)

bicuspid. The bicuspid lie within the divergent roots of the temporary molars. The molars, surrounded by incomplete casings of bone, occupy the portion of jaw posterior to the temporary set, extending into the ramus of the inferior, and the tuberosity of the superior maxilla. The anatomy of the jaws at this period is admirably displayed in figs. 29 and 30 from Wedl. It may be noted that this is the epoch at which the greatest number of teeth are

held in the jaws at one time. The whole of the deciduous set, and the whole of the permanent set are present, and of these the wisdom teeth alone are still totally uncalcified.

Within two years after the completion of the temporary set a process is commenced by which their roots are gradually removed by absorption, until in time the teeth lose their attachment to the jaws, and are cast off one by one, to be afterwards replaced by the advancing members of the permanent set. The absorption does not begin simultaneously throughout the whole set, but attacks the teeth according to the order in which they are to be shed. It commences and proceeds, as a rule, at that part of the root towards which the permanent tooth is advancing, but occasionally it affects other parts at the same time. The wasting surface, which on examination is found irregular in outline and broken up into minute pits or depressions, resembles that seen in bone when undergoing absorption. Closely applied to the whole of this surface there is found a vascular papilla of slight depth, the absorbent organ, the active agent in the removal of the tissues. This papilla consists of a vascular and cellular structure, the portion in contact with the teeth being entirely made up of large multiform nucleated cells. These cells occupy the pits in the wasting tissues. The papilla originates from the contiguous vascular layer of the alveolar periosteum, and it constitutes a special provision in the economy for the removal of the deciduous teeth. Abundant evidence exists that the absorption is not (as was once supposed) due to the pressure of the advancing permanent teeth, and the following are some of the main facts composing this evidence:—1st. In some of the lower animals, notably in the serpent, conditions exist during the evolution of successive sets of teeth, which prove beyond doubt that absorption of deciduous teeth, similar to what occurs in man, takes

place independently of pressure. This fact has been clearly demonstrated by Mr. Charles Tomes (15). He has pointed out that the succession of teeth in snakes is endless, new teeth continuing to be developed at the inner side of the teeth already in place throughout the

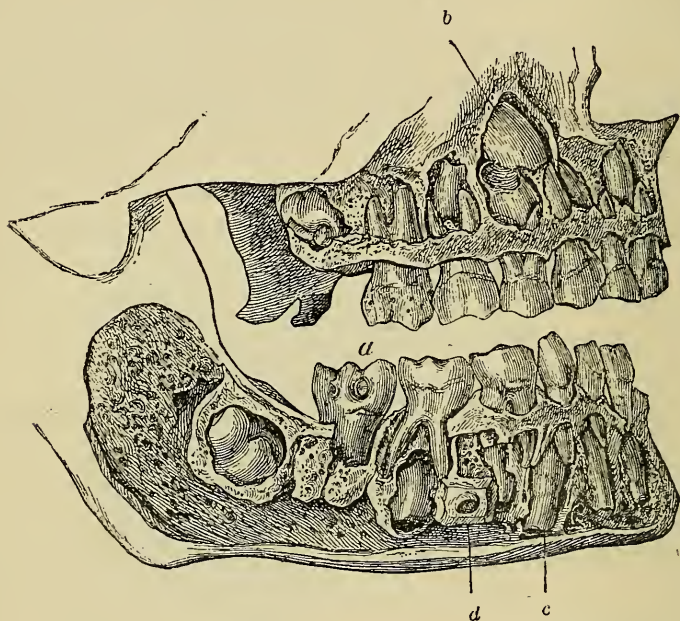


FIG. 30.

Commencement of second dentition. Profile view from right side ; front alveolar wall removed. (*a*) First permanent molars of upper and lower jaws erupted. (*b*) Upper permanent canine. (*c*) Lower permanent canine. (*d*) Mental foramen. Crowns of bicuspid are seen embraced by the roots of temporary molars. Second permanent upper and lower molars are (in their crypts) imbedded in the maxillary tuberosity and coronoid process. Considerable absorption of the roots of the temporary incisors has by this time taken place. (Natural size.)

lifetime of the animal ; that when a tooth is about to be shed, both it and the bone at its base are attacked by absorption, this taking place at its inner side before the outer side is at all involved ; and that the advancing

tooth moves forward, the delicate cells of its enamel organ remaining *in situ*, even after absorption has been effected to such an extent that the inner side of the old tooth has been cut away, and the successional tooth has passed into the space thus gained. "It is obvious that if the successional tooth had ever come into contact with its predecessor, these cells, at the point of impact, could not have escaped destruction."

2nd. Absorption of human temporary teeth frequently goes on at points remote from the permanent successors.

3rd. The permanent do not impinge upon the temporary teeth during their advance, and, on the contrary, are separated from them throughout by the bony walls of the crypts in which they are enclosed.

It happens occasionally without assignable cause that temporary teeth retain their positions long after the period at which they ought to be shed, and even until middle age. Sometimes they apparently form the sole obstacle to the eruption of their permanent successors, the presence of which may then be usually recognised from the contour of the external alveolar plate within which they are hidden. Every now and again an adult patient presents himself having one or more healthy looking and firmly fixed temporary teeth in position with absence of the members of the second set which should occupy the places. A reasonable time should be given for nature to take its course, but temporary teeth ought not to be allowed to remain beyond childhood—beyond the period when the second permanent molars are well in place. Extraction of such retained temporary teeth may be followed by one of two results—either the excluded permanent tooth will emerge, or the space which is left will become in time much diminished, and in a crowded set will be surely filled up by spreading of the teeth, which always takes place in these circumstances in youthful jaws.

Retained temporary teeth rarely endure beyond approach of manhood. In many cases in which long retained temporary teeth have been at last shed, artificial teeth are called for, to fill towards the front of the mouth unsightly gaps which have shown no tendency to close, but which might have become obliterated had the temporary teeth been removed during youth.

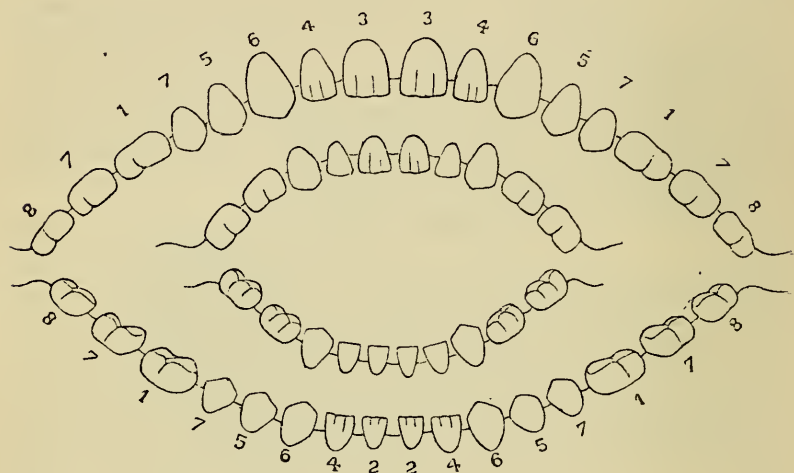


FIG. 31.

Diagram of second dentition, showing relation between permanent and temporary teeth. Figures 1, 2, 3, &c., indicate the groups of teeth and the order of their appearance.

Retained temporary crowns may be of good colour, and look healthy; they occupy usually a lower level than the adjacent permanent teeth, and sometimes a temporary molar seems held in place mainly by its neighbours, which, leaning towards each other keep it in position. On seizing such a tooth with forceps it will commonly be recognisable that the only resistance to its removal is formed by this condition. When the tooth comes away it is often found to have little or no roots, and the permanent crown may be perhaps seen or felt in the socket beneath.

The process of eruption of the permanent teeth closely resembles that which has been described as occurring in the first dentition. By the time each temporary tooth is shed, absorption has commenced in the plate of bone which up to this period has closed the crypt of the permanent successor, and this absorption proceeds until the opening is large enough to permit the free passage of the emerging crown. When the crowns of the teeth have become fully protruded the development of the alveoli again becomes active, and the bone in time closely embraces the necks of the teeth, and invests the roots in accurately fitting sockets.

The age at which second dentition commences varies like the first, in different individuals, but the order in which the teeth appear is rarely irregular (see fig. 31 from Dr. Starr). The following may be taken as average dates at which the eruption of the different teeth is completed. The teeth of each class appear somewhat later in the upper than in the lower jaw :—

	YEARS
First molars	} 5 to 7
Central inferior incisors . }	
Central superior incisors .	6 to 8
Lateral incisors	7 to 9
Anterior bicuspid	8 to 10
Canines	9 to 12
Posterior bicuspid	10 to 12
Second molars	12 to 14
Wisdom teeth	17 to 25

The eruption of the permanent teeth is very rarely, if ever, attended with constitutional disorders due to reflex nervous disturbance, such as commonly accompany first dentition; and local irritation is rare, except in the case of the lower wisdom teeth.

Impacted Wisdom Teeth.—The protrusion of the lower wisdom teeth is often attended by considerable

suffering. They make their appearance after the completion of dentition, at the time when, owing to insufficient backward development of the horizontal ramus of the jaw, crowding of the teeth in many cases exists, and the space which should remain for the wisdom teeth is encroached upon by the second molar. The wisdom teeth in their advance thus become wedged between the distal surface of the second molar and the coronoid process. This condition—commonly spoken of as “impaction” of the wisdom tooth—appears sometimes enough alone to give rise to considerable swelling and inflammation of the gum, and the mischief becomes aggravated when the opposing teeth of the upper jaw during mastication come forcibly in contact with the swollen tissues which overhang the emerging crown. In many cases the inflammation arises from cold, and it is sometimes difficult to determine whether it has commenced around the tooth or has spread forward from the tonsil or pharynx. The inflammation, starting at the gum, if allowed to run on, spreads to the alveolar periosteum, and to the uvula, soft palate, and tonsil; and the neighbouring lymphatic glands become swelled and painful. The wisdom tooth and often the molars in front become exquisitely sensitive to the touch. Movement of the lower jaw is always more or less impeded by the swelling, and sometimes force is needed to open the mouth. Closure of the jaws of this kind, whilst inflammation exists in connection with an impacted wisdom tooth, may endure for many weeks. The closure may be altogether due to inflammatory swelling in and around the muscles, but it is very often spasmodic in its nature. The masseter and internal pterygoid muscles are mainly affected in spasmodic closure. The nature of the case becomes apparent when the patient is put fully under the influence of an anæsthetic; for then in a spasmodic case the muscles relax and the mouth is easily opened,

whereas if the closure be due to inflammatory swelling or adhesions, force will be still necessary to separate the jaws.

The pain, which varies with the amount of inflammation, is often severe, and sometimes throbbing in character, and is increased by attempted movements of the jaw and by swallowing. During the acute stage the pain is mostly localised, but in chronic inflammation around impacted wisdom teeth, and even in cases where very slight or no traces of inflammation are detectable, neuralgic pain spreading over the side of the face, and particularly affecting the ear, is a very common symptom. The acute symptoms are attended with considerable febrile disturbance. If the disease run on suppuration takes place, and pus flows or may be pressed from within the gum and alveolus; or in some few cases pus may burrow and point externally through the cheek, or at some distant part. I have seen many cases of this kind. In one (reported in *British Dental Journal*, 1869) an abscess arising from an impacted lower wisdom tooth, formed, pointed and burst upon the cheek about an inch from the corner of the mouth. In some cases suppuration with extensive burrowing of pus through the tissues of the neck takes place. In all cases of inflammation of the face and neck in the region of the angle of the jaw in patients between the ages of seventeen and twenty-five, unless other sufficient causes be evident, a careful examination of the teeth should be made, lest the true origin of the mischief be overlooked.

On occurrence of suppuration the symptoms may slowly subside, or the inflammation may remain chronic, increasing again into the acute form from time to time, under the influence of cold or other irritation. In a few instances necrosis of the wisdom tooth results, and in rare cases others of the adjacent teeth, and more rarely again portions of the alveoli or jaw may also lose their vitality.

It must not be supposed that in every case of impaction—every case in which, owing to want of space, the full eruption of a wisdom tooth is rendered difficult or impossible—inflammation necessarily follows. It is only in a small minority of cases that inflammation at any time supervenes. Many cases occur in which lower wisdom teeth remain throughout life either partly hidden or completely buried behind the second molar, without the patient being aware of their presence. Examples where the tooth was rising vertically rather than those where it lay in a sloping or horizontal position have most often in my experience been attended by inflammation. On the other hand, the absence of inflammatory or other objective symptoms does not necessarily imply in these cases that the impaction is not a cause of irritation. On the contrary, the cause of neuralgia of the side of the face, and particularly pain referred to the region of the internal ear, is in a considerable number of cases clearly traceable to an impacted lower wisdom tooth, in the neighbourhood of which no inflammation or other sign of disease may be discoverable. The neuralgia in these cases seems really due to pressure upon or irritation of the trunk of the inferior maxillary nerve by the root of the wisdom tooth. The apex of the root is even in normal cases in very close propinquity to the nerve canal, and in some instances encroaches upon it.*

Treatment.—In a great number of simple cases of impaction immediate relief may be afforded, and, at the same time, a permanent cure effected by excising the thick flap of gum which overlays to a greater or less degree the posterior portion of the tooth. The mere lancing or division of the gum rarely does permanent good, as the divided parts fall at once again into apposi-

* See chapter on Neuralgia.

tion and become rapidly re-united. The flap of gum should be seized with a pair of strong narrow-bladed dissecting forceps, and cut away with a small bistoury or curved scissors. I have in some cases used an artery forceps to grip the flap of gum, pushing one blade beneath and then closing the forceps. The gum is usually tough, slippery and difficult to hold; and unless firmly fixed, it is often by no means easy to dissect the flap cleanly off, and at the same time to avoid cutting the cheek. Sometimes the fixing may be done with a small tenaculum or hook. The hæmorrhage on the first incision is enough usually to hide the part, and an assistant should be at hand provided with small sponges held in a dressing forceps, to wipe away the blood, and give the operator a view of the part. The operation is sufficiently painful to justify use of an anæsthetic. Nitrous oxide answers well and affords enough time, if the surgeon stands ready with instruments in hand. If a wisdom tooth, as sometimes happens, be mal-placed, and with the crown so directed as to render it useless in mastication, it should, if the cause of inflammation, be removed. The extraction of a tooth may also be called for in cases which take a rapid, bad course, or which have been neglected until extensive inflammation and suppuration are present. It often happens, however, in these instances, that the tooth is so impacted as to render its extraction extremely difficult or impossible. This is especially the case where the tooth is advancing in an oblique direction—sometimes it may be nearly horizontal—and with the anterior margin of the crown impinging upon the distal surface of the second molar. A careful examination must be made before an operation is attempted. In one or two cases of this kind, I have succeeded in breaking the crown from the root, the patient being under the influence of an anæsthetic, and extracting the root in a second operation.

But, with few exceptions, cases of impacted lower wisdom teeth, in which relief afforded by space is called for, are best treated by extraction of the second molar. This allows the impacted tooth to advance slowly into the vacant space. Where the second molar is extensively carious, there seldom need be hesitation in proposing this operation. A crown of a wisdom tooth advancing obliquely and impinging upon the distal surface of the second molar will in some instances be found partly lodging within a carious cavity, which is apt in these cases to form at the point of contact. This condition renders impaction more complete, and it will under these circumstances be found impossible in some instances to remove one without the other tooth. Extraction of the first molar or even of a bicuspid, which may be chosen if decayed, will give relief, but more slowly, to the crowding. To reach the tooth when the jaws are closed they must be carefully forced apart with a screw gag, the patient being anæsthetised. When suppuration has been going on for some time round an impacted wisdom tooth, it is often so loosened and extruded that it may be extracted with comparative ease.*

Beyond the operative procedures just described, the treatment of inflammation associated with impacted wisdom teeth is the same as that of ordinary dental and maxillary periostitis given in a later chapter, and consists mainly of assiduous use of hot fomentations, confined as much as possible to within the mouth, and incisions through the gum and swollen periosteum of the jaw, in order to relieve tension, to give exit to pent-up pus, and prevent it from burrowing or bursting externally through the skin.

In cases of intractable neuralgia (particularly in young

* See chapter on Extraction.

subjects) affecting the side of the face and the ear, in which no local cause can be discovered, but in which an apparently healthy although impacted wisdom tooth is present, it may be right to extract the tooth or the second molar, in the hope of relieving irritation of the nerve trunk, which may exist without recognisable local signs.

Throughout the entire period of their growth the process by which the maxillæ are moulded into their destined form is similar to that which takes place in all developing bones. It consists, on the one hand, of continuous deposition of bone, and on the other of occasional absorption. It has been already explained how the processes of growth and absorption alternate during dentition and the development of the alveolar border of the jaws. Enlargement of the maxillary arch is produced mainly by deposition of bone upon the facial surface, and as new layers of bone are deposited absorption takes place upon the lingual surface. In the same way in the development of the posterior portion of the lower jaw, whilst the ascending ramus is increasing in size by the deposition of bone upon the posterior surfaces of the coronoid and condyloid processes, absorption is going on upon these parts anteriorly, and thus the bones are moulded into their destined form. The deposition of new material is principally subperiosteal, but it also takes place beneath the articular cartilage of the lower jaw, and at the surfaces contiguous to the cartilages, which in the infant unite the separate portions of bone in both maxillæ; and the increase in the bulk of the jaws is thus entirely affected, not by interstitial growth or expansion of the bones, but by constant additions to the external surfaces.

Up to a certain period in the growth of the jaws, as

previously explained and illustrated, there is not sufficient room in the alveolar arch for the crypts of the developing permanent molars, which, therefore, are enclosed in the base of the coronoid process of the lower, and in the tuberosity of the upper jaw. The space taken up by the ten anterior permanent teeth almost exactly corresponds to that occupied by the milk teeth, and it is, therefore, in the backward direction that the required increase in size of the arch takes place. The depth of the bones becomes greater in accordance with the dental and muscular development. Examination of a large series of human maxillæ of different ages enabled Sir J. Tomes to demonstrate the fact, first pointed out by John Hunter, that the growth of the alveolar border, during both first and second dentition, follows and is dependent upon the growth of the teeth, and that the position of the teeth is not, as was once believed, predetermined by independent growth of the bone. This fact has also received confirmation from the observations of Mr. Chas. Tomes, upon the mode of attachment of the teeth in fishes and reptiles. He has proved that in the attachment of a tooth by simple ankylosis, or by ever so rudimentary a socket, as it takes place in the varied species, the bone is modelled to the tooth in full subserviency to the position of that tooth, and that the tooth does not come to take its place upon a spot predetermined for it by any disposition of the bone, made prior to its advent.

The portions of bone which give attachment to the muscles of mastication increase in bulk as these organs develop in size and power.

When the teeth are lost from age or other causes, the alveoli waste by absorption; and at the same time mastication being gradually discontinued, the muscles, together with the portions of bone to which they are attached, undergo atrophy, and the jaws assume the peculiar form characteristic of age.

It happens occasionally that permanent teeth remain imbedded within the jaws instead of making their appearance at the natural epoch of their eruption. It has been just explained, and illustrated in figs. 29 and 30, that at one period in the growth of the maxillæ, before the jaws have attained their full size, enough space for the extended arrangement of the set in an unbroken arch does not exist, and the teeth are crowded within

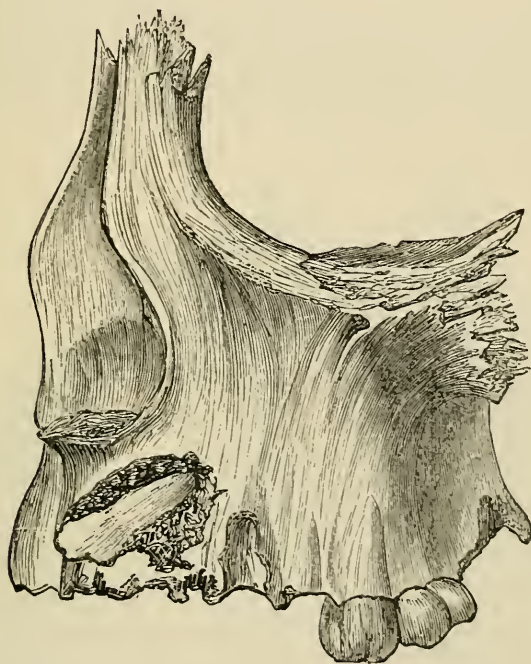

FIG. 32.

the jaw, the canines and bicuspid being deeply placed, whilst the upper and lower wisdom teeth are situated in the tuberosity of the upper and in the ramus of the lower jaw respectively. If, owing to arrest of development or other cause, the jaws remain unduly small or contracted, there may never exist enough room for the

entire set of teeth to take their places in the dental arch, and some of the set, although fully formed, may remain buried within the bone. This condition, although it may happen in the case of any tooth, most commonly arises, as might be expected, with those teeth—such as wisdom teeth, canines, and bicuspid— which are cut at a late stage of dentition, when the whole available space in an abnormally small maxilla may be taken up by the rest of the set. The eruption of such teeth may be also in the same way prevented by the presence of supernumerary teeth or by temporary teeth holding their position after the time at which they ought to be cast off.

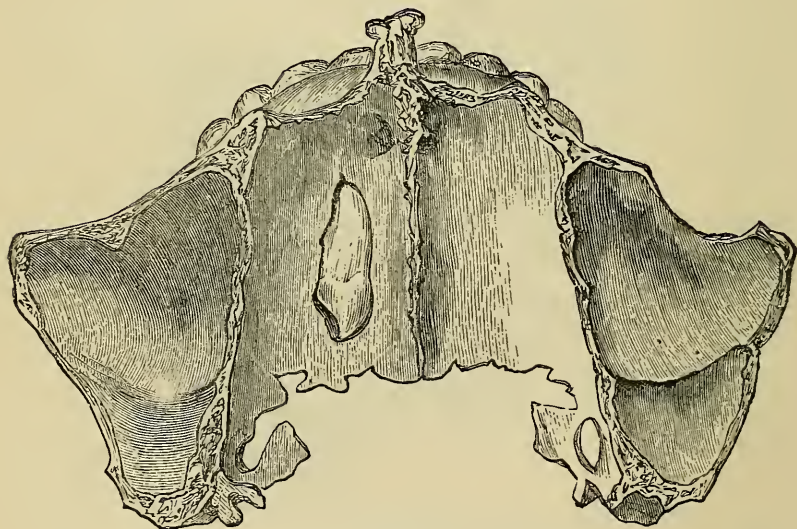


FIG. 33.

In another class of cases imbedded teeth hold such abnormal positions within the bone that, although room may exist for them in the dental arch, their eruption is impossible. In some of these instances there is evidence that the malposition is due to deflection of the growing tooth from

its normal course by obstacles, such as temporary teeth or supernumerary teeth, but in others the tooth is situated far from the alveolus, and its misplacement cannot be accounted for. Fig. 32, from Mr. Heath's work (4), shows an upper canine situated within the jaw in a position which it may have possibly assumed in consequence of want of space, whilst fig. 33 from the same work, exhibits an upper canine, lying horizontally in the floor of the nose, with the crown directed backwards—a misplacement which cannot be accounted for. Fig. 34 from Salter (12) shows an imbedded molar in the lower jaw. In all these specimens the bone has been cut away to expose the buried tooth. Similar specimens are pre-

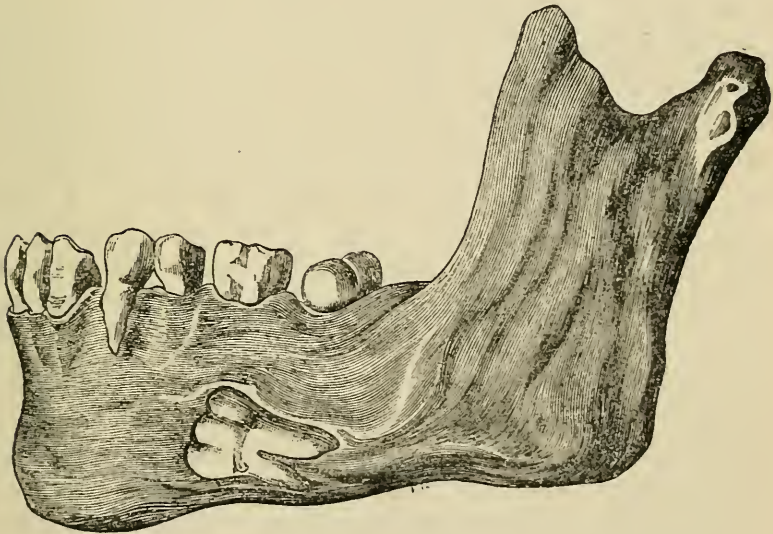


FIG. 34.

served in the Museum of the College of Surgeons, showing teeth imbedded in almost every position in the maxillæ. Imbedded teeth, especially those regularly situated within the bone, sometimes make their appearance after a lapse of time when room is afforded by the

loss of other teeth, and the eruption of such teeth late in life has given rise to the unfounded belief in the occasional occurrence of a third dentition. Every dental surgeon becomes familiar with cases in which in a patient with edentulous gums, and perhaps wearing a complete set of artificial teeth, one or other buried members of the set—most often wisdom teeth or canines—begin after a time to emerge or become exposed through the wasting of the alveolar border of the jaw.

In the majority of instances, imbedded teeth remain through life, without the patient being aware of their existence. In some cases, in consequence of extension of periostitis from around overlying or neighbouring teeth or other causes, inflammation may be set up in the cyst of a buried tooth; and in all cases of deep-seated inflammation within the jaws where the cause is not evident, possibility of the presence of a buried tooth must be therefore borne in mind. The diagnosis would be confirmed by exploration; and the thin external plate of bone covering the tooth can be easily penetrated for this purpose, if it have not at some point already given way to pressure of confined exudations or pus. A tooth being discovered its extraction presents as a rule no serious difficulty. The enclosing bone must be opened to the slight extent necessary, either with a dental drill, a small trocar, or bone forceps, and the tooth being gripped at a convenient point must be carefully detached and withdrawn. A cure will be hastened by antiseptic lotions, such as Condyl's fluid or carbolic acid (1 in 50), with which the mouth may be frequently rinsed and the cavity syringed.

In some few individuals buried teeth become the centre of cystic disease or of other morbid growths. Such growths connected with teeth are described in a later chapter.

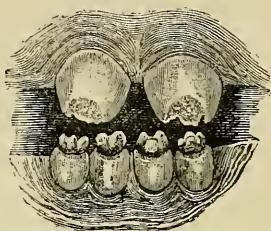
ABNORMALLY FORMED TEETH.

Abnormalities in Size of Teeth.—The size of teeth varies very much in different individuals. In the vast majority of cases teeth composing a set are of sizes proportional to each other; but a set may be disproportional relatively to the size of the jaw, being made up of comparatively very large or very small teeth. A large set in a small jaw gives rise to crowding—a condition discussed in the next chapter. Single members of a set may in proportion to the rest be abnormally large or small, but variations in this respect are very rare, except in the upper laterals and in the wisdom teeth. The laterals occasionally are very small, round, conical and pointed in shape, resembling a class of supernumerary teeth (figs. 50 and 51), with which they must not be confounded. In some uncommon cases the incisors and canines and, in still rarer instances, a whole set has partaken of this character. Such teeth have been likened to rats' teeth. Wisdom teeth are, above all, most variable in size. They are sometimes represented by stunted conical teeth, also not unlike in character the peg-shaped supernumerary teeth illustrated in this chapter (figs. 48 and 50). Wisdom teeth are less frequently of great size; every now and then, however, they are met with having crowns half as large again as the second molar. Such large teeth often—although by no means always—have stunted roots. It will commonly be found that teeth of any class with small crowns may possess roots

of full or great size and *vice versâ*—a point which must be borne in mind in several operations of dental surgery.

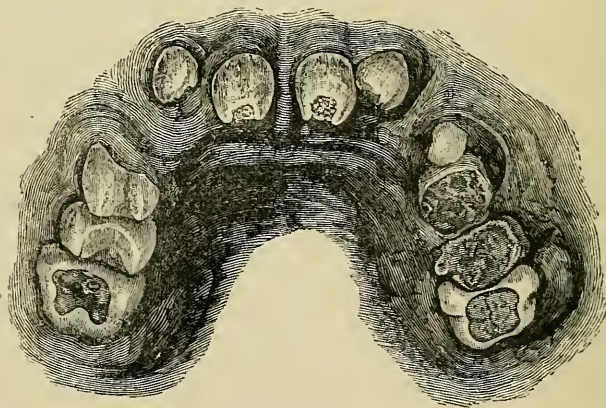
Syphilitic and Honeycombed Teeth.—A peculiar malformation associated with hereditary syphilis affecting the incisors and canines of the permanent set only, and

FIG. 35.



Typical syphilitic upper and lower incisors.

FIG. 36.



Syphilitic upper central incisors, and mercurial (honeycombed) permanent molars, carious, from boy æt. eleven. At one side the temporary molars, carious, are still in place.

being most marked in the upper central incisors, was first described many years ago by Mr. Jonathan Hutchinson (5). Syphilitic teeth (figs. 35 and 36) are short, small and peg-shaped. Their cutting edges are narrow and marked by a characteristic broad crescentic notch. Horizontal notches, or furrows, and honeycomb pits not of syphilitic

origin often exist on the same teeth. The colour of the teeth is bad—often a dirty grey shade. The central incisors Mr. Hutchinson considers the “test teeth.” The tissues of syphilitic teeth are soft and ill-made, so that they soon become worn down and lose in great part their characteristic marks. The enamel towards the neck is usually smooth and free from visible defect. A striking connection has been observed between this deformity of the teeth and a syphilitic disease of the cornea—interstitial keratitis. The subjects of inherited syphilis who present marked examples of interstitial keratitis, have almost invariably typically malformed teeth, and those who have such teeth scarcely ever escape interstitial keratitis; whilst syphilitic children who are liable to suffer in after life from phagadænic affections of the mouth and throat usually show nothing peculiar in their teeth. Although the characteristic appearances of true syphilitic teeth are of unequivocal significance, and can hardly be mistaken by an experienced observer, it must not be forgotten that many honeycombed and malformed teeth resemble syphilitic teeth; and caution is therefore necessary in pronouncing a diagnosis from the teeth alone. It is only in a small proportion of undoubtedly syphilitic children that teeth of this special type appear.

A considerable variety of malformed teeth with defective surfaces—pitted, rocky, ridged or spinous—are usually classed as “honeycombed” teeth. These teeth are almost sufficiently described by their names. In spinous teeth the cusps of molars seem pinched, drawn out and pointed, and the crowns of incisors and canines flattened and elongated into thin processes towards the cutting edge. The defects rarely involve the whole crown. They are mostly confined in the molars to the cusps and masticating surface. In the incisors and canines the markings may be confined to a narrow space along the cutting edge. At this point the disfigurement

always starts, thence extending to a varying degree over the surface towards the neck. The rest of the tooth is often well formed and of good structure. The defect is mainly confined to the enamel. These teeth have been styled by Mr. Jonathan Hutchinson "stomatitic" or "mercurial" teeth. He believes that, in cases in which great and general damage to the enamel of the permanent set of teeth is observed it ought to lead us to suspect that the patient has in early infancy passed through an attack of stomatitis, attended with inflammation of the tooth sacs. Mr. Hutchinson believes that if all the bicuspid have good white enamel, while all the first permanent molars show absence of enamel and spinous discoloured surfaces, it may with confidence be assumed that the child took mercury in infancy, or that some cause for a similar kind of stomatitis then existed. As to the cause of the stomatitis, although he does not assert that mercury is the only cause, he believes that by far the most important cause of defects in enamel development in the permanent set of teeth is the use during infancy of mercury in one or other form. The "test teeth" in these cases are the first permanent molars. The bicuspid often and the second molars usually are unaffected. The disease of the eye known as lamellar cataract, which is not congenital and not syphilitic, has been observed in concurrence with honeycombed teeth, particularly in children who have suffered from convulsions in infancy.

It is to some extent still an open question whether there is any correlation of development between the eyes and teeth, but Mr. Hutchinson holds to the belief that the connection between the two phenomena referred to is not to be so explained, but that the lamellar cataracts are due to convulsions in infancy, and the damage to the enamel of the teeth is due to stomatitis which may be caused by mercury given for the convulsions.

Mr. Hutchinson has found that some adult patients with honeycombed teeth display an unusual susceptibility to the action of mercury, and believes that it is owing to this idiosyncrasy that the teeth have suffered from what was given in infancy. If this view be correct, honeycombed teeth may rank as revealing symptoms, and may be of value in giving information as to individual susceptibilities which could not have been otherwise recognized.

To sum up the more important of these facts it would appear:—

1. That syphilitic teeth are mostly accompanied by other evidences of the inherited taint, such as skin affections and interstitial keratitis, while honeycombed teeth are frequently associated with a non-syphilitic eye disease, lamellar cataract, with infantile convulsions, and with stomatitis often but not always caused by mercurial treatment during the enamel forming period.

2. That in inherited syphilis the teeth most affected are the upper incisors, the honeycombed condition being most conspicuous in the first permanent molars.

3. That these conditions may both be present in the same individual.

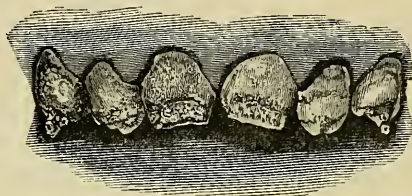
4. It by no means happens that every case of inherited syphilis is marked by typical mal-development of the teeth. Many instances occur in which no characteristic defect is visible.

5. Syphilitic teeth are due to causes acting upon the entire tooth germ during development, whereby not only the structure but the whole form of the tooth is modified. Honeycombed teeth are due to causes acting upon the enamel during calcification and interfering with the proper formation of the tissue.

Syphilitic and honeycombed teeth are well illustrated in the accompanying engravings, taken from patients at Moorfields Ophthalmic Hospital. Figs. 35, 36, show-

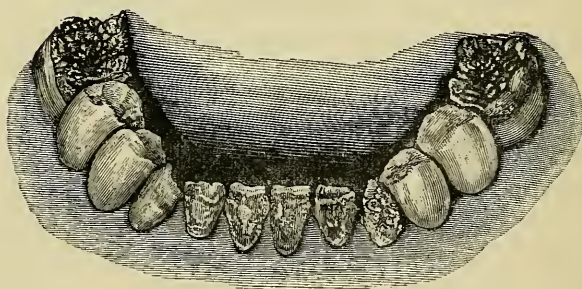
ing typical teeth, are from patients undoubtedly subjects of hereditary syphilis, and in one (Fig. 36) there is a history of mercurialism also. Figs. 37 and 39—honeycombed teeth—are from patients with lamellar cataract and to whom mercury had been given in large quantities in early childhood. Fig. 35 may be contrasted with fig. 39; the former syphilitic, the latter mercurial, or

FIG. 37.



Ridged and honeycombed teeth, boy æt. sixteen, subject of lamellar cataract. Had fits in connection with very late dentition in early childhood. Much calomel was given during a whole year (from one to two years of age).

FIG. 38.



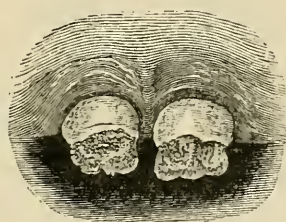
Honeycombed teeth, girl æt. nine, subject of lamellar cataract. No evidence as to fits or mercury.

stomatitic central incisors. Fig. 38 well illustrates the common occurrence of well-made bicuspiids in honeycombed sets of teeth.

Treatment.—Syphilitic and honeycombed teeth do not necessarily call for interference. Pits, fissures and grooves, especially if they extend to the dentine, are of course very apt to become the seat of carious action, which must be dealt with as it appears; but enamel-

covered pits and depressions often remain permanently unaffected. The flattened, pitted and drawn out or spinous edges of front teeth often as time goes on present an unsightly appearance. The surface becomes covered with discoloured tartar which, filling the small pits, is difficult to dislodge. It is a good plan in some cases at the approach of adult age to file or cut down and polish these ragged surfaces and edges, with care not to approach the pulp chamber. This may leave the teeth unnaturally short but will vastly improve their appearance.

FIG. 39.

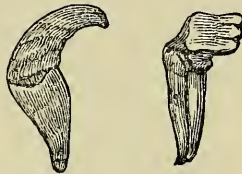

Stomatitic or mercurial teeth of type sometimes mistaken for syphilitic.

Dilaceration.—When the mode of development of the teeth is considered, and it is remembered that they are liable to injury at the period when they are but partially calcified, it is easy to understand why teeth are occasionally met with the crowns and roots of which are more or less distorted. In such cases some force—such as a blow—has been transmitted to the developing organ, by which a part or the whole of the crown has become displaced, without severance of its connection with the uncalcified portion of the pulp, and has become subsequently fixed in its malposition by completion of the process of calcification. This kind of injury has been termed dilaceration. Section of such teeth displays evi-

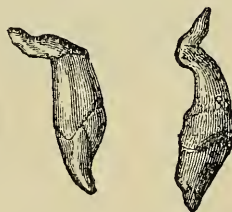
dent marks of the bending which the tissues underwent in the soft state. It is possible that a tooth might be distorted during growth to the extent of dilaceration in consequence of crowding and pressure within the jaw from want of space, and this opinion is strengthened by the fact that the deformity seldom or never occurs except in teeth situated at the front of the jaw where a crowded condition is common.

FIGS. 40 and 41.



Teeth which have undergone dilaceration are of course easily recognised when the injury affects the tissues of the crown, but when the crown is well formed and merely bent at an angle with the root, careful examination is sometimes required to distinguish the case from one in which a well formed tooth is lying in an abnormal

FIGS. 42 and 43.

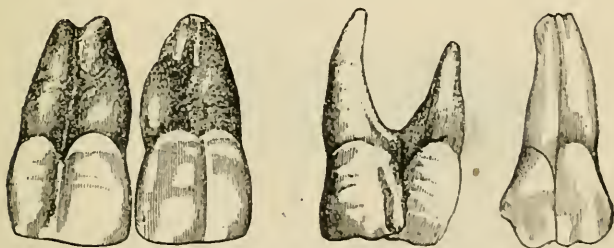


position. The latter case might be amenable to treatment, which would be inapplicable to dilaceration. Teeth the subject of dilaceration often present marked bulgings upon either surface close to the neck, which is frequently constricted and well defined; they occa-

sionally display marked mobility under slight pressure, and the distorted root may be in some cases traced by the finger through the alveolar wall. Fig. 40, from Wedl, represents a case of dilaceration or flexion occurring in an upper central incisor, of which a side view is presented. The crown is perfectly developed, but the root is short and thick and much curved, its apex being directed towards the lips. Fig. 41, from Wedl, shows a lower central incisor the seat of dilaceration. The crown is bent at a right angle to the root, and the cutting edge is directed towards the lips. Figs. 42 and 43, from Wedl, illustrate similar malformations of the roots of upper central incisors.

Gemination, apparently the result of organic union of two neighbouring teeth during development, sometimes occurs. It rarely affects any but incisors, and the union may extend through crowns and root, or may affect only a part of the teeth. Blended crowns contain as a rule a common pulp cavity, but in blended roots the chamber is divided or distinct. Gemination does not necessarily give rise to marked deformity in the appearance of the

FIGS. 44, 45, 46 and 47.

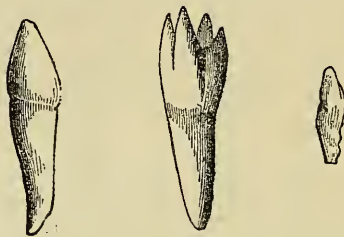


teeth. Figs. 44, 45, 46 and 47, from Tomes (21), show examples of these malformations.

Supernumerary teeth are frequently met with. They are as a rule easily recognised, being mostly of an irregular conical form, unlike any member of the normal

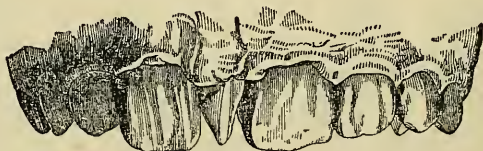
set of teeth. They may occur in any position, but their most common situation is towards the front of the mouth, where they are usually placed irregularly among the other teeth. Sometimes a supernumerary tooth is symmetrical in form, and placed within the dental arch, and hardly distinguishable from its neighbours—an individual in this way possessing an extra or supple-

FIGS. 48, 49 and 50.



mental incisor or canine. Figs. 48, 49 and 50, from Salter, illustrate common types of supernumerary teeth. Fig. 51, from Salter, and fig. 52, from the *Transactions of the Odontological Society*, show supernumerary teeth in position in the upper jaw.

FIG. 51.



Mr. Bland Sutton (14)—to whom I am indebted for the illustration fig. 54—believes that the origin of geminated teeth and of some supernumerary teeth is explicable on the theory that a dental germ or papilla may occasionally bifurcate, but it does not necessarily follow that two distinct teeth arise in consequence of the dichot-

tomy, for during development the two teeth may fuse and produce gemination. This opinion is supported by the fact that dichotomy of a similar kind is to be observed in the feathers of some species of birds, and has been occasionally noticed in the hairs of man. The dichotomy is not always equal or complete. In the case

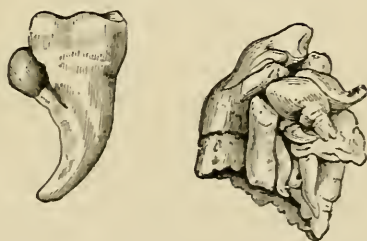FIG. 52.



of teeth when dichotomy is equal and complete the teeth are as like each other as twins, and difficulty arises as to which shall be regarded as supernumerary.

In such a specimen as Fig. 47 the dichotomy of the papilla was equal, but in the case represented in Fig. 53, from Tomes, a lower molar, with a small tooth projecting

FIGS. 53 and 54.



from its side, the dichotomy was unequal, and in both specimens probably only partial. Complete and unequal dichotomy would produce the small mis-shapen supernumerary teeth such as above described and illustrated.

Other abnormal teeth, presenting several forms, varying between so-called warty teeth, studded with nodules of enamel, and monstrous teeth, mere shapeless masses of dental tissue, must be considered identical with the morbid growths termed odontomes, the nature of which is more fully discussed in a later chapter.*

The specimen shown in fig. 53 recently described by Mr. Bland Sutton, throws some light upon this subject. This tooth was removed from a lad aged nineteen years; it was situated in front of the right upper bicuspid, displacing the lateral incisor and canine, so as to occupy their position in the dental arch. It has no fang, and appears to consist merely of a crown and neck, but the crown bristles with cusps, and as many as nine distinct enamel-covered eminences can be detected. The appearance of the specimen is as though a group of supernumerary teeth had become confluent. Had such a tooth been dislodged from a swelling below the gum, it would have been described as an odontome, and regarded as an odontome which had cut the gum and taken rank with the normal teeth. Mr. Bland Sutton has pointed out that odontomes resemble teeth in this way—for a time during their development they remain hidden below the mucous membrane, and give no evidence (or very little) of their existence. To this condition succeeds an eruptive stage, when perhaps suppuration, with the constitutional disturbance dependent thereon, draw attention to the part. If this view be correct, this remarkable structure must be regarded as an odontome which has cut the gum and taken a position in the dental series. This specimen is further interesting in that it consists of a conglomeration of denticles. Mr. Sutton has urged that those remarkable cases in which denticles have from time to time been erupted from a tumour connected with the jaw should be classed as odontomes. It is easy to imagine that if the cusps of

* See chapter on Morbid Growths.

this odontome remained distinct and each had been separately erupted, they would have been called supernumerary teeth. Indeed, many of the cusps can be easily detached from the main mass. This strange specimen serves to bridge the gap between what he calls compound fillicular cysts and composite odontomes.

The sole treatment available in each variety of the above described abnormalities is extraction, an operation which is of course not called for unless the faulty tooth is unsightly, a cause of deformity, or of disease.

IRREGULARITIES OF THE TEETH.

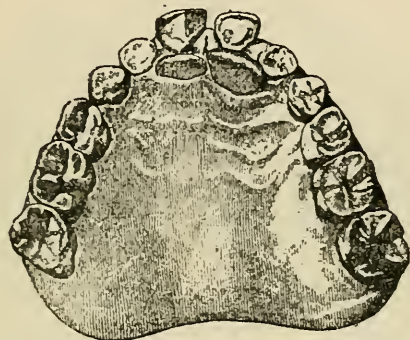
Irregularities of the teeth may, to facilitate description, be divided roughly into two great classes. 1st. Those in which teeth occupy abnormal positions in well-formed jaws; 2nd, those associated with malformation either of the alveolar border or of the body of the jaw.

The first class of irregularities rarely occurs in the deciduous set, for the reason that in this case a chief cause of irregularity—obstruction by preceding teeth—is absent. Instances of the second class in the infant, although seldom manifest to casual observation, are often perceptible on careful examination, especially when the deformity affects the jaw generally. Irregularities of the temporary teeth, whatever their character, are, however, of little practical importance, since the teeth are shed in early life, and the deformities do not call for treatment.

Irregularities of the First Class.—It was explained in a previous chapter that, during the process of eruption the teeth are not closely embraced by bone, and that it is not until some time after the crowns have fully emerged from the wide orifices of the crypts that the alveoli become fully formed, and invest closely the necks and roots of the teeth. During this stage of growth, when the advancing teeth are surrounded only by soft, readily yielding tissues, any slight obstacle to their progress suffices to deflect them from their proper direction, and to retain them in a wrong position. The most frequent of such obstacles consists of temporary

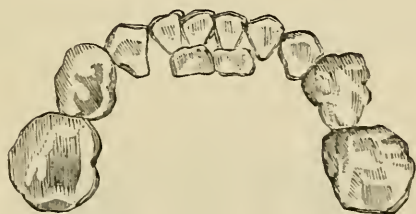teeth, or decayed portions of temporary teeth, which have retained their places, after the time at which they ought to have been cast off. The most common example of this kind of irregularity, is illustrated in fig. 55, from Tomes

FIG. 55.



(21), where the permanent incisors of the upper jaw are seen to occupy a posterior position, owing to the persistence of the temporary teeth. A corresponding irregularity occurring in the lower jaw, is shown in fig. 56.

FIG. 56.

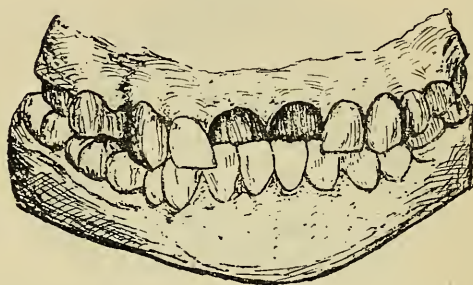


By similar causes teeth may be rotated upon their axes, crowded together so as to overlap, or deflected in almost any direction.

Other causes of this class of irregularities are to be traced to injuries, which may be due to blows upon the mouth, or may be inflicted during untimely extraction

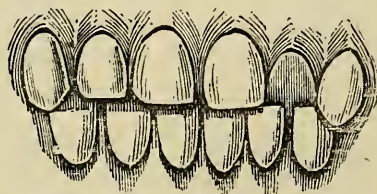
of temporary teeth. Supernumerary teeth form a frequent cause of irregularity. Then again, inflammation and alveolar abscess connected with a temporary tooth may cause displacement of the developing permanent successor; whilst lastly, some cases of simple displacement of one or more teeth in well-formed jaws can only

FIG. 57.



be ascribed to remote causes acting during development. Some in the latter category are undoubtedly hereditary—malposition of one or more in a set of teeth forming often a characteristic trait common to several members of a family. But the causation of irregularities of the class under discussion is, it must be acknowledged, often as difficult or impossible to discover as that of total

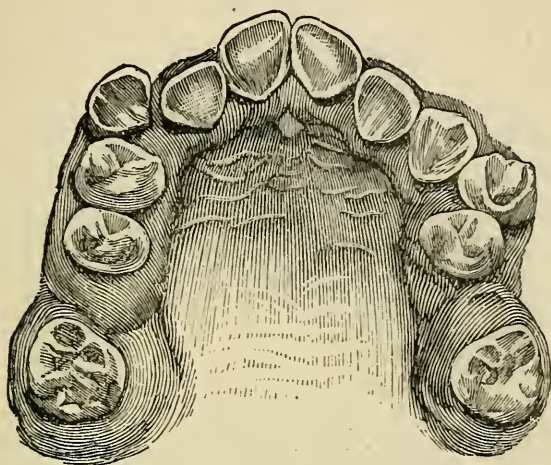
FIG. 58.



displacement of teeth buried within the bone, described and illustrated in a previous chapter.

Figs. 57 and 58 illustrate the typical variety of irregularity ultimately resulting from unchecked progress of the condition shown in fig. 55. Upper front teeth fully erupted inside the normal line pass on closure of

FIG. 59.

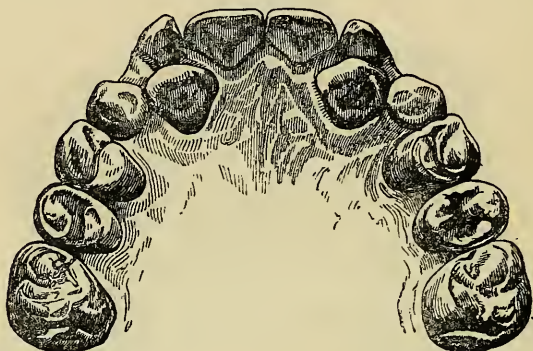

the jaws within instead of without the lower incisors, and the teeth being held in malposition by the bite,* a deformity is produced, which can only be overcome by the mechanical treatment presently to be described. Fig. 59, from Quinby (11A), illustrates general irregularity of incisors and bicuspids. Fig. 60, from Salter (12), shows a rare example of displacement of the upper canines, which appear within the dental arch and posterior to the persistent temporary canines which hold their places. Figs. 61 and 62, the latter from Quinby, show typical irregularities of upper canine and bicuspid. Fig. 63, from Wedl, exemplifies irregularity caused by presence of a supernumerary tooth (*a*) and a retained temporary tooth—the canine (*d*). The right permanent

* The arrangement of the upper and lower teeth when in completely close contact is termed the "bite."

central incisor (*b*) is displaced upwards and forwards; the lateral incisor (*c*, too large in the drawing), is twisted on its axis, and the permanent canine (*e*) pushed outwards. Other examples of this first class of irregulari-

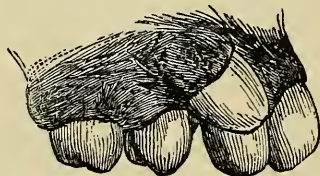
FIG. 60.



ties are shown in figs. 77, 78, and 81 from Quinby, figs. 82 and 84 from Mason (9), and in fig. 89 from Talbot (22).

A very fruitful source of irregularity is untimely extraction of temporary teeth, and therefore the first thing

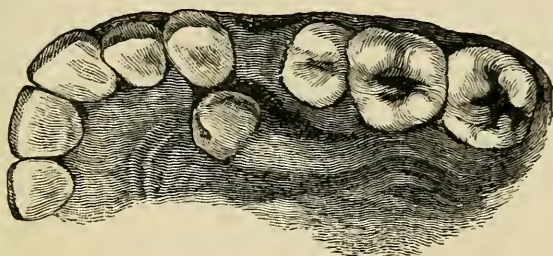
FIG. 61.



to be avoided by the young practitioner is unnecessary interference of this kind. It is very easy to sweep away temporary teeth and to produce a transient improvement in appearance; but it may be laid down as a rule subject to rare exceptions that it is extremely bad practice to extract any temporary tooth for the cure of irregu-

larity unless it be a direct cause of displacement, or form an evident obstacle to the regular advance of its proper permanent successor. During the progress of second dentition, in most instances a child's mouth necessarily presents a more or less unsightly appearance, and the

FIG. 62.

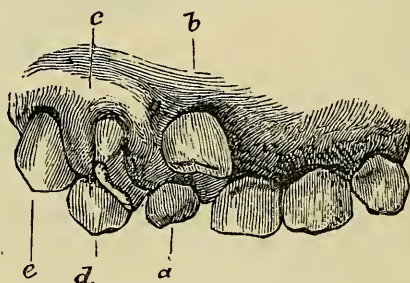


parents over anxious and ready to imagine that every passing irregularity may become a permanent deformity, will often urge that treatment should be commenced. Clear explanation of the nature of the case, and of the advantage either of delay or of total non-interference when one or other of these may be the proper course, will bring the young practitioner in the end more credit and profit than he could derive from any less ingenuous line of conduct involving the wanton infliction of unnecessary pain and injury upon the patient. Each tooth ought to be left until the last moment at which its presence can be safely allowed. Absorption of the roots progresses rapidly from week to week as the time approaches for shedding of the teeth. It is both right and expedient to spare a child unnecessary pain and terror. To push or pick from its weak attachment the crown of a temporary tooth of which the roots are completely absorbed need neither excite fear nor give appreciable pain; both of these are likely when the use of instruments becomes necessary.

The evils as well as the benefits which may arise from premature removal of temporary teeth, will be perhaps brought out more clearly by examination of some particular instances.

In the case shown in fig. 55 it would be right and expedient to extract the temporary central incisors even if still very firm, immediately the eruption of their permanent successors were impending; but the like haste would be by no means called for in the similar condition affecting the lower jaw seen in fig. 56. In the one case delay might lead to an irregularity incapable of spontaneous cure (fig. 57); in the other case the normal posi-

FIG. 63.



tion of the lower incisors being within the uppers, the obstructing temporary teeth might with safety be left for a much longer period with the certainty that in the end the displaced teeth would assume the correct position.

In neither of these cases would extraction of the temporary laterals be expedient for the purpose of increasing the space available for the forward movement of the centrals. Whatever relief might be given to the centrals, the effect of this operation would probably in the end be to give rise to more serious irregularity of the laterals, which deprived of room, would be forced backward or seriously deflected in some irregular direction.

Untimely extraction of the temporary canines is usually a very injurious procedure. The operation is one which is very often improperly performed at the urgent request of parents who, whilst ignorant of the evils which result from ill-timed interference are anxious to avert a deformity which may seem imminent. The first bicuspid comes into place from one to four years before the permanent canines. The effect of removing temporary canines soon after the appearance of the permanent laterals to relieve what is often only transient crowding of these and the central incisors, is to allow the first bicuspid to move gradually forwards until they come into contact with the permanent laterals, thus occupying the places which should be filled later on by the permanent canines. This happens in almost every such case but with more certainty in undersized jaws, and here in the end the mischief is commonly most serious. The ultimate result is that the permanent canines being excluded from their proper places become erupted more or less high up externally over the position through which they ought to descend, and in consequence occasionally assume so faulty a direction that their regulation becomes difficult, or even their extraction becomes necessary. In the lower jaw a corresponding condition may be in the same way induced. To make room after this mismanagement, sacrifice of permanent teeth which might perhaps have been avoided had the temporary canines been preserved for their full period, will be called for. In the majority of well-managed cases where owing to lack of space there is on completion of dentition merely general crowding as in fig. 70 and no other irregularity the only treatment called for is, as a rule, extraction of a first permanent molar or bicuspid at each side as soon as the second molars are fully erupted. A case of this kind will usually right itself in from a few months to a year by

the gradual spreading of the whole set after room is afforded. On the other hand, in instances aggravated by untimely extraction of the temporary canines long mechanical treatment may become necessary unless instead of the molars the first bicuspid are removed; but if the bicuspid as so often happens are sound and the molars badly decayed, the last named procedure can hardly be entertained. The extraction of permanent canines unless they are hopelessly mal-placed is unjustifiable, for these teeth are relatively among the strongest of the set and they contribute much to the character and symmetry of the front of the mouth. Mechanical treatment—long and tedious—which might have been avoided, thus becomes often, in these cases, necessary not only to force the canines in the desired direction, but as a preliminary step to make room by pushing back the bicuspid which may have besides become locked in their too forward position by the bite. It is, therefore, clearly preferable to allow continuance of considerable irregularity of the permanent incisors for a time rather than relieve it by removal of the temporary canines; for in any case in which the irregularity might be likely to remain after childhood it would not be cured by the operation, but on the contrary, the general condition of the set must be in the end made worse. Cases of an opposite character, in which evidently nothing but good could arise from removal of the temporary canines are exemplified in figs. 60 and 63.

Too early extraction of the temporary molars gives rise to evils similar to those just described; for then the first permanent molars move forward as they are erupted and encroach upon the space which should be occupied by the bicuspid, which appear later. This no doubt, besides causing displacement of the bicuspid, sometimes leads to crowding of the whole front range of teeth.

There seems good reason to believe that during untimely extraction of a temporary molar the bicuspid which lies in its crypt within the roots may be displaced. In this way the irregularity illustrated in fig. 62 might be accounted for. It has also been suggested that after premature extraction of temporary teeth the alveolus becomes filled up with dense osseous tissue, through which the permanent tooth when the period of its eruption arrives cannot penetrate and thus becomes deflected through the more yielding internal or external alveolar plate. Some of the evils which may arise from persistence of temporary teeth long after the period at which shedding ought to take place, were described in the chapter on dentition, and to these evils may be added the possibility of a permanent tooth being forced to take a course outwards or inwards through the alveolar wall.

Although it may be necessary to extract necrosed temporary teeth before their time for the relief of disease, the same rules apply to them as to healthy teeth in relation to irregularity, and they must not be removed as a rule until the period at which they ought normally to be shed. The physiological process of absorption described in a previous chapter, by which the roots of deciduous teeth are gradually removed, ceases on the death of a root. The cessation of the physiological process is, however, usually followed by absorption such as mostly affects dead teeth and bone, but this is slow and often ineffectual. Necrosed teeth and roots are therefore more than living teeth likely to be retained and form obstacles to the proper progress of their successors, and on this account they call for greater watchfulness.

All the reasons against ill-timed treatment must be kept steadily in view, and yet while uncalled-for interference should be guarded against with the utmost care, there need be no hesitation in extracting temporary teeth

the removal of which is demonstrably necessary for the cure of irregularities. It is a somewhat popular belief that the premature extraction of these teeth may act as a cause of contraction of the jaw, and thus of subsequent irregularity of the teeth of the worst kind; hence, as just pointed out, whilst some parents will urge treatment, others will strenuously oppose the performance of the most necessary operations. The belief is refuted by physiological fact as well as by practical experience. The growth of the alveoli of the permanent teeth (as explained on a previous page) goes on quite independently of the temporary set, and cases are on record in which even after the premature loss of the entire temporary set the jaw attained its normal development and the permanent teeth assumed their proper positions.

A knowledge of the order in which the teeth are erupted and of the characteristics which distinguish the permanent from the temporary set, will prevent the mistake against which it is necessary caution should be exercised, of extracting one of the former instead of one of the latter. An error of this kind is, however, hardly possible, except in the case of incisors and canines. The permanent molars may be known from their position at the posterior extremity of the jaw beyond the range of the temporary teeth; whilst the bicuspid may be easily recognized since no such tooth exists in the deciduous set. The permanent if present during the persistence of the temporary incisors will be found in the vast majority of cases behind the teeth which they replace, and their cutting edges are serrated, whilst those of the temporary set by this time are worn smooth. The permanent canines may be distinguished by their great size in comparison with the corresponding temporary teeth, and by their position, which is external and prominent the root being marked by a vertical projecting ridge on the external alveolar wall. The occasional

occurrence of anomalous cases must not however be forgotten—rare cases like that for example shown in fig. 60 where the permanent canines have presented themselves within instead of as is usual without the arch.

The presence of supernumerary teeth already referred to, forms an occasional complication which must not be overlooked; and a neglected mouth in which numerous temporary teeth also are retained whilst the crowns of the permanent set are appearing through the gums in various directions will sometimes need close examination, even by an experienced practitioner, before the real nature of the case can be determined.

A very large proportion of cases of simple irregularity of one or more teeth spontaneously recover in the course of time when room is afforded for the movement of the teeth, and if they are not locked in their malposition by the bite—as for example in the cases shown in figs. 57 and 58. The movements of the tongue, the pressure of the lips and the effects of mastication—all or either of these help to press the teeth in the proper direction to which they indeed tend in their natural growth. Unless, therefore, it be clearly evident that mechanical treatment is unavoidable—that the deformity cannot be mended, or may be aggravated by delay—the teeth are better left until about the twelfth year; or until the period at which the second permanent molars are in place. By this time it will have become possible to decide whether other teeth will need treatment and whether sacrifice of permanent teeth will be called for, and if so upon which the choice should fall; and the preliminary necessary operations having been completed an instrument may be constructed to act at once upon all those teeth which need mechanical treatment.

A tooth merely deflected in its course, the crown misplaced, but the apex of the root in its natural position can in a majority of even extreme cases be in time drawn

into its proper place. The nature of the case may be determined usually by careful examination, the outline of the root being often sufficiently indicated through the overlaying bone. The possible existence of dilaceration in these instances must be kept in view.

Numerous instances, however, present themselves in which one or more teeth are so far displaced as to preclude the possibility of their reduction by any means to their proper positions. Such instances are specially those in which not only the crown, but the entire root is out of its normal position. For example, an upper canine being erupted after the lateral incisor and bicuspid are in position, often presents itself external to and prominent over the space between these teeth, which is too narrow to contain it. When the direction of the canine is correct it will in time take its proper place if room be afforded, but should it appear in an oblique direction and with its root lying at an angle across the alveolar border and the apex far away from its right position, in the direction somewhat roughly indicated in fig. 61, it is unlikely that it could be brought into the desired position even were mechanical treatment employed. In such cases the extraction of the malplaced tooth is the sole resource. An example of irremediable displacement of a bicuspid—a kind of irregularity which is also frequently met with in the case of other teeth is shown in fig. 62 from Quinby.

In most cases where early mechanical treatment is called for, but particularly in the typical variety exemplified in figs. 57 and 58, it ought not to be commenced until the crown of the tooth has well emerged. Before that period the crown will be too short to overlap sufficiently its lower opponents, and although it may be easily pressed forward it will probably relapse into its old position as soon as mechanical treatment is withdrawn.

The main points in treatment of irregularities of the first class may be summed up as follows:—

1. Bearing in mind the cautions above given against indiscriminate and untimely extraction of apparently obstructive temporary teeth, real obstacles, whether formed by temporary or supernumerary teeth, must be removed.

2. Unless fixed in mal-position by adjacent permanent teeth or rendered incapable of movement by the bite, irregular teeth ought, after removal of obstacles, to be allowed time to assume spontaneously their normal position, to which when free they always tend.

3. Mechanical treatment ought never to be commenced before the full eruption of the second molars, except in such cases as evidently cannot spontaneously recover, or in which after lapse of time no tendency towards improvement is manifested.

The principles of mechanical treatment being the same in all varieties of irregularity the two classes in this connection are discussed together on later pages.

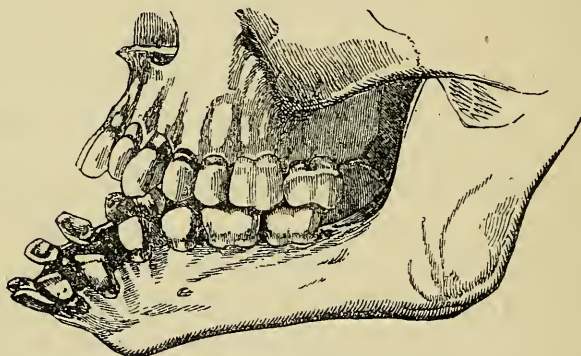
Irregularities of the Second Class.—Irregularities due to malformation of the alveoli or of the body of the jaws themselves have now to be described. It has been before stated that the normal dental arch is semi-elliptical in shape. The front portion of the figure, containing the incisors, canines, and bicuspid, forms an almost perfect semicircle; whilst the portions containing the molars continue the line backwards at each side. Flattening or contraction of this arch, or abnormal development of any part of it, necessarily gives rise to irregularities of the teeth. This class of irregularities is most commonly congenital, and at the same time often hereditary, a peculiar abnormality in the form of the jaws being in this manner sometimes reproduced in many members of a large family.

It is not necessary to dwell upon the fact that the jaw of civilised races has in course of ages become

greatly diminished in size, so that crowding and malposition of teeth in consequence have become, especially in women, the rule rather than the exception.

Deformity may exist in one or both maxillæ, or may be confined to one side only of the bone. Deformities may be due to injury or other accidental causes. The almost marvellous manner in which the jaws (like other bones) may be modified in shape, especially during early life, by the continued application of force in one direction, is not uncommonly exemplified in surgical cases.

FIG. 64.

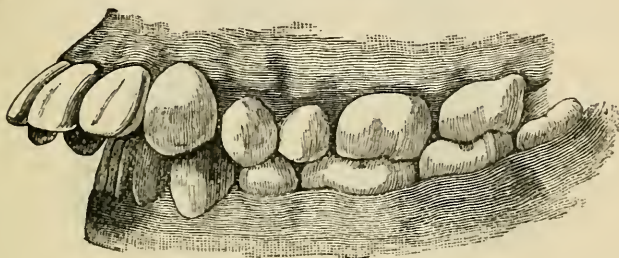


The sequel of extensive burns of the neck occasionally furnishes a striking instance in point. The cicatrix resulting from such an injury has a constant tendency to contract, and unceasingly drawing the chin towards the chest, causes the body of the jaw gradually to curve downwards. In cases from time to time met with, the curvature is so great that the alveoli are completely everted, and the teeth directed outwards, or even downwards. One of these cases is figured in the annexed engraving (fig. 64), taken from Mr. Tomes's work (21). Cases like this serve to show that any sufficiently prolonged constant slight strain or tension exercised upon a growing jaw will suffice to modify its

form. Causes of this kind, although often extremely difficult to trace, may be supposed to account for many common deformities.

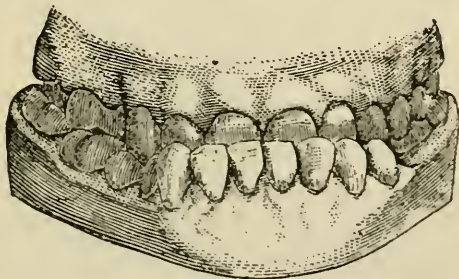
The nature of irregularities, associated with malformations of the jaw will be rendered more evident by typical examples. Fig. 65 represents an instance of

FIG. 65.



a common variety; protrusion of the central incisors apparently due to an abnormal outgrowth of the anterior portion of the alveolar processes. A somewhat similar deformity of the lower jaw depicted in fig. 66 from

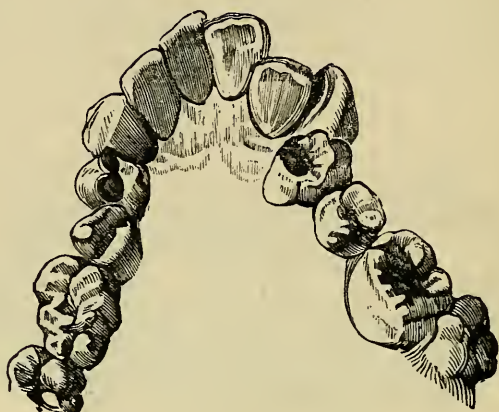FIG. 66.



Talbot, gives rise to projection of the lower beyond the upper front teeth. An individual affected with this deformity is said to be underhung. The V-shaped or contracted arch, instances of which daily present themselves,

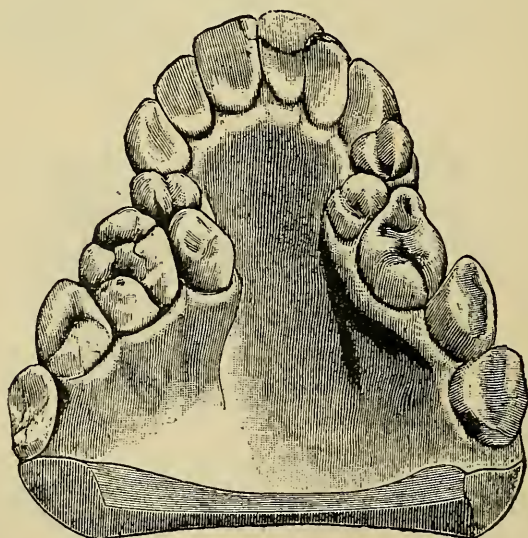
is illustrated in fig. 67. This deformity gives rise to an almost endless variety of displacements of the teeth.

FIG. 67.



The incisors or bicuspid are often forced inwards, and the canines, appearing after these are in position, remain

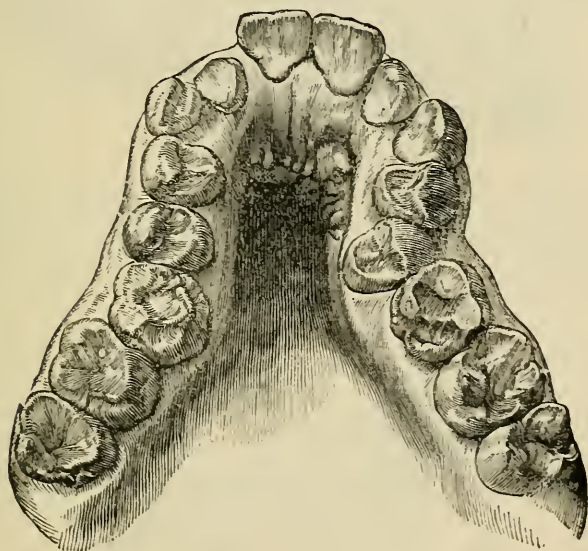
FIG. 68.



external and prominent. In the saddle-shaped jaw (figs. 68 from Talbot and 69 from *Transactions of The Odonto-*

logical Society), which in some ways resemble the V-shaped the incisors and canines may be prominent, whilst the alveolar region containing the bicuspid and first molars is compressed inwards. The displacements of teeth due to crowding in that class of case in which a relatively small though well-shaped jaw contains disproportionately large teeth (fig. 70 from Quinby), somewhat resemble those occurring in the V-shaped maxilla.

FIG. 69.

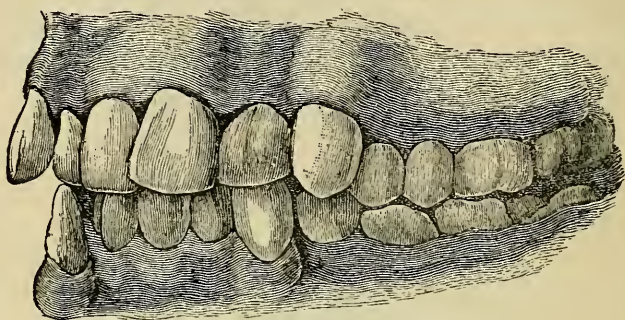


In a somewhat rarer example of deformity (fig. 71) (Tomes) the molars alone approximate on closure of the jaws, and the incisors remain apart and cannot be brought into contact. This is primarily in consequence of a malformation of the posterior portion of the lower jaw.

These examples will suffice to render manifest the distinction between the two great classes of irregularities, and little would be gained by multiplying them. In the great majority of cases of malformed alveoli or jaw, it is

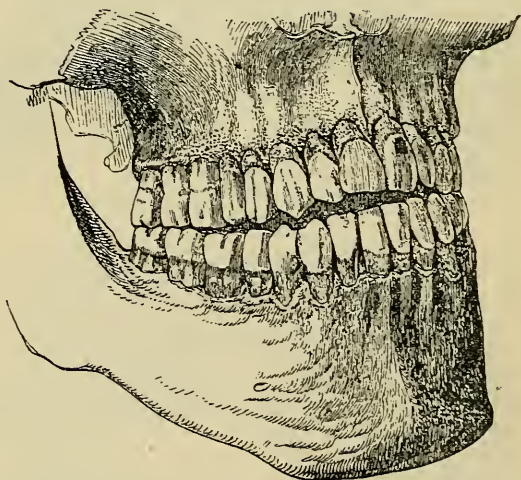
quite impossible to assign with certainty a cause for the deformity. As no two crania and no two bones of different crania are ever exactly alike, so not less there

FIG. 70.



seems infinite variation to a minute or greater degree in the size and shape of maxillæ in different individuals. Peculiarities are frequently hereditary, and occur in

FIG. 71.



several members of a family through generations. Where a local cause may have existed, the child is very often not brought to the dentist until the cause has disap-

peared. Some of these deformities are, however, undoubtedly acquired. Cases of protrusion of the upper front teeth and recession of the lower, as shown in fig. 65, are often ascribed to the pressure of thumb-sucking in infancy and childhood; but I have met with very few instances of the kind in which this cause was demonstrable. It is the exception to find an infant which does not habitually suck its thumb, and if this were a common cause the deformity in question would be much more frequently met with. The habit I believe acts injuriously only in cases in which it is prolonged from infancy into childhood, and up to or approaching the end of second dentition. Some few patients who continue "thumb-suckers" until the later years of childhood seem almost unconscious of their habit. In a few cases enquiry has elicited the fact that the child when in a drowsy condition and composing itself to sleep has habitually put its thumb into the mouth and has gone to sleep in the act of sucking—the thumb remaining there through the night. In such an instance a gradual bending outwards of the alveolar margin of the upper jaw from the pressure might reasonably be expected, whilst at the same time the lower front teeth would be inclined backwards.

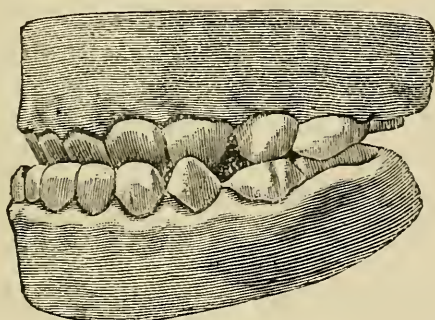
Deformity similar to that depicted in fig. 71 is very commonly found in patients with enlarged tonsils and adenoid growths in the naso-pharynx. These patients breathe with more or less difficulty, and are very often unable to respire at all through the nose. Such children have a characteristic expression. They go always with the lips slightly open and the teeth apart. The muscular tension, the pressure of the tongue, which is mostly kept down on the floor of the mouth with its tip against the incisors, and the unnatural constant slight muscular strain to which the conditions thus give rise are together enough when prolonged through years to account for the modi-

fication in the shape of the jaw. The ramus seems lengthened, the alveolar margin in front seems deepened, and the crowns of the molars in some examples occupy an unusually low level.

In some few cases of underhung jaw, a condition which is mostly innate or hereditary, the deformity is certainly acquired. I have seen several instances in which children through constantly practising a trick of thrusting forward the lower jaw, had caused in time the lower incisors and canines to slope outwards and the corresponding upper teeth backwards until at length the characteristic unnatural bite was produced. This condition is more easily produced in patients who have been deprived prematurely of the first permanent molars, and in whom the jaws have become in consequence unduly approximated. In one case which I treated, and which was very intractable, relapsing over and over again, the patient, a girl, at the commencement of second dentition, was affected with spasmodic twitchings of the muscles of the face and jaws with constant jerking forward of the chin. Although this case at first looked simple, the upper teeth alone appearing at fault, the growing bones seemed in the end gradually to become modified in form until at last a true underhung condition was produced. The case was cured at first by merely pushing outwards the upper teeth until they well overlapped the lowers, but after frequent relapses, during many months, it was found that the lower jaw had in the meantime really become more prominent, and it was then necessary to extract a tooth from each side of that jaw and draw the front teeth backwards. The bite of the teeth was in the end made natural, and the worst of the disfigurement was overcome, but there remained a decided projection of the chin, no trace of which had been observable before the commencement of the spasms. The appearance of this case when first

seen closely resembled that depicted in fig. 72 from Talbot. Where this kind of deformity is acquired it will be usually found that the upper front teeth—as appears in fig. 72—are almost alone affected, the incisors and canines sloping backwards, and the alveolar margins of both jaws being normal; whereas in congenital cases the upper front teeth are mostly in good position and the bone of correct shape, the fault seeming mainly to lie in maldevelopment of the lower jaw which is bodily protruded owing apparently to undue length of the horizontal ramus.

FIG. 72.



It may be presumed that some varieties of malformed maxillæ have a correlation in development with the base of the skull, and this opinion is supported by the fact that these varieties are chiefly confined to the upper jaw. It has been sought particularly to associate the V-shaped and saddle-shaped jaw with congenital idiocy. There cannot however be the least doubt that the V-shaped and saddle-shaped jaw occur in numerous individuals in whom no apparent malformation of any other part of the cranium is to be noticed. On the other hand, examination of great numbers of idiots has not discovered more than a small percentage showing to

any marked degree the maxillary peculiarities in question. The jaws in the microcephalic type as might be expected, are often undersized and the teeth crowded; whilst in the macrocephalic they are as frequently prognathous, and with the front teeth prominent and spread apart.

The principles upon which mechanical treatment of irregularities are based, being the same in all varieties of deformities, the two classes into which, for descriptive purposes, they have been here divided may in this regard be now discussed together. In entering upon treatment in cases where mechanical aid is called for it may be necessary in the first place to consider the expediency and desirableness of extracting permanent teeth for the sake of obtaining space; next comes the question of the extraction of such misplaced teeth as are not amenable to mechanical treatment—a question which has been sufficiently discussed in previous paragraphs—and lastly, there is the construction and application of a suitable apparatus.

Before deciding upon a line of treatment in these cases, unless of the simplest character, it is well to make casts of the mouth, and to study the relations of the teeth in either jaw, as well as the conditions—the bite—when the jaws are closed. The mechanical problem is often rendered much more evident, or distinct, by this means, and the favourable or unfavourable circumstances are often more easily recognizable than is possible by mere examination of the mouth.

With regard to the extraction of permanent teeth for the sake of affording room, it may be at once stated that the sacrifice of an incisor or canine is rarely necessary or justifiable. The most durable of the teeth they contribute most, or are most essential, to the symmetry of the dental arch; moreover a tooth may

generally be chosen, the removal of which will better serve towards the desired end. The choice will as a rule fall upon the first molar. This tooth is the most liable to decay, and even in early life is often so extensively carious as to require extraction, or at least is in a condition so defective that it cannot be expected to last many years. After the extraction of a tooth from a crowded jaw the pressure is relieved; and the teeth spread equally apart until in a comparatively short time (very rapidly in early life) the space previously occupied by a large tooth becomes obliterated. In most cases to relieve crowding it is desirable to remove a tooth at each side of the jaw. If only one tooth be extracted, the movement of the crowded members takes place towards that side, and the regularity of the dental circle is disturbed. It is in the highest degree advisable to postpone the extraction of the first molars until the complete eruption of the second molars at about the twelfth year. The first molars if carious must be filled and preserved till that period. If they be extracted earlier, as sometimes through neglect becomes unavoidable, it often happens that the second molars incline forwards as they advance, and thus occupying the place of the extracted teeth prevent the backward movement of the crowded front teeth, besides deranging the bite and giving rise to other evils.

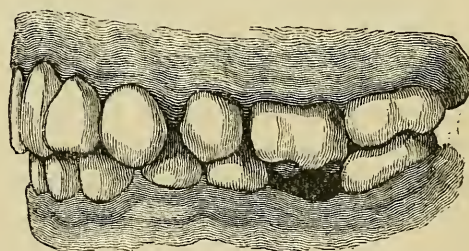
In cases where it becomes necessary to extract a tooth from each side of both jaws, it is, as a rule, advisable to remove antagonizing teeth. Fig. 73, from Quinby, exemplifies a difficulty which may arise if this course be not adopted. In the case depicted, a bicuspid has been extracted from the upper, a molar from the lower jaw. The upper molar having lost its opponent has dropped somewhat into the space beneath, and the resulting bite has effectually prevented the movement of the lower teeth.

Exceptional cases sometimes present themselves, in

which extraction of a tooth from one side may suffice. These are cases of asymmetrical development, in which deformity is confined to one side alone of the jaw.

Should the first molar be free from serious defect, any other back tooth which shows greater signs of decay, or of imperfect structure, may of course be chosen instead. Where doubt exists, the relative liability of the different classes of teeth to decay will largely govern the choice, but other important considerations must not be overlooked. Where the crowding is extreme a tooth smaller than a molar may not afford enough space. On the other hand it must not be forgotten that bicuspid's extensively carious are very difficult teeth to preserve. These teeth when attacked by decay in early life are most often

FIG. 73.



affected on their mesial or distal surfaces in a situation where a comparatively small cavity will nearly approach the pulp and render the insertion of a very permanent stopping exceedingly difficult. On the contrary, the first permanent molar, a large massive tooth, lends itself readily to extensive filling operations especially when decay has not gone rapidly towards the pulp, and there remains a basis of solid tissue upon which to securely found a stopping. Again, a molar which although slightly carious, has lasted from the sixth to the twelfth year, may be trusted if properly filled, to stand for many more; whereas the bicuspid at the twelfth year is a new comer of untried strength, which may show signs of rapid failure after a short time.

Few things conduce more to the onset and rapid advance of decay than a crowded, irregular condition of the teeth, and when this condition exists the removal of one or two even sound teeth has a highly beneficial influence over the future health of the rest of the set, and on this ground alone the operation is often advisable.

The relative liability of different classes of teeth to decay has been ascertained from carefully collected statistics. The first molars, as just stated, are much more often attacked by decay than any others of the teeth; next in this respect come the second molars; after these the second bicuspid; fourthly, the first bicuspid; fifthly, the lateral incisors; sixthly, the canines; and lastly the central incisors which are less frequently the seat of caries than any other teeth of the set.

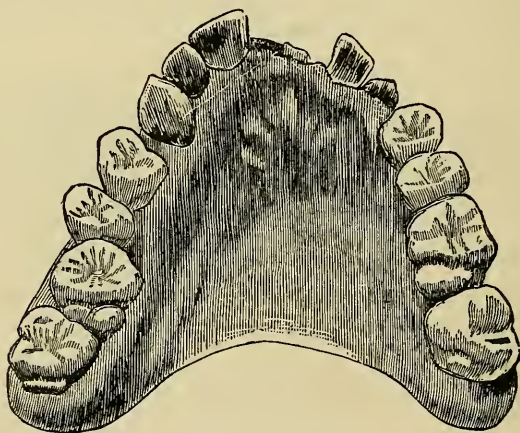It has been already more than once stated (and the fact cannot be too strongly emphasized) that space having been obtained by the extraction of teeth, Nature may be trusted unaided to effect a cure in a very great number of cases of irregularity, and particularly in those due to crowding alone, in which the general direction of the teeth is good, and where they are not locked in their mal-positions by the bite; but nevertheless in many cases, in any class, mechanical treatment will be necessary if perfect symmetry is required.

I have neither met with nor seen described any case in which extraction of an upper incisor or canine merely for the relief of crowding could be justified, but every now and then instances present themselves in which other circumstances combine to render this procedure desirable. For example, I have lately treated a case in which the upper lateral incisors in a neglected mouth were at the age of twelve so damaged by caries that their crowns were beyond repair, and the crowding in front being extreme the central incisor crowns had become forced into carious excavations on the mesial

surfaces of the laterals. The first permanent molars were also broken down to the level of the gums. These teeth, and also the lateral incisors, were therefore extracted. This gave enough, although not too much relief, and the space left by the extracted teeth became soon obliterated.

The following case, in which a central incisor was extracted, may be here interpolated. It illustrates as well several points in the treatment of irregularities. A young lady, aged fourteen, received a blow in the mouth from a stone, which caused a fracture extending through the crown of the left upper central incisor. A year later

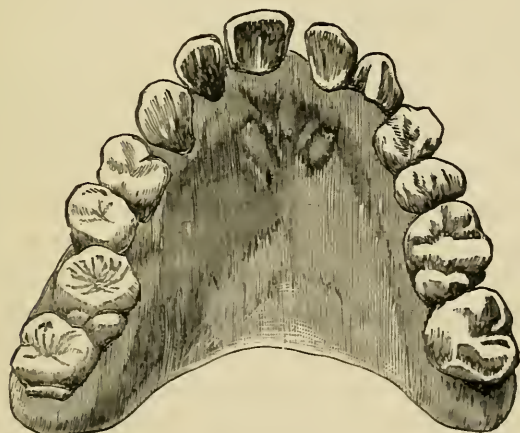FIG. 74.



she was seen by the author, who, finding the fracture deeply involved the root, and rendered its preservation impossible, extracted the tooth. The accompanying cut (fig. 74) shows the appearance of the upper jaw after this operation. There was considerable irregularity of the teeth. The right central and lateral incisors, and the left canine fell considerably beyond the range of the lower teeth on closure of the mouth, whilst the right canine and first molar were displaced backwards, the

cusps of the former locking within the lower teeth. Considering all the circumstances, it was deemed preferable to attempt to regulate the teeth, and to bring about at the same time closure of the gap in front, rather than to condemn the patient to wear an artificial tooth. An apparatus of the character to be described in the following pages was accordingly made to exert constant outward pressure, on those teeth which were within the normal dental circle, and flat springs of wire were brought round at each side in front, to act in the opposite direction upon the projecting incisors and canine. The next engraving (fig. 75) shows the effect produced

FIG. 75.



after three months of this treatment, and by the exercise of an amount of force so slight as to give rise throughout to no irritation, beyond a trivial passing tenderness of some of the teeth. The rapid favourable progress of this case was due to a great extent to the youth of the patient, and to the ample room which the loss of the incisor provided for the spreading apart of the crowded teeth, and their movement in the desired directions. The case under this treatment, showed in a short time

still greater improvement in the arrangement of the teeth.

The rule forbidding extraction of lower incisors admits of occasional rare exceptions. From time to time cases occur in which a single central or lateral becomes gradually forced either completely within or without the dental arch, the rest of the set both above and below being regular and also free from serious decay. This irregularity does not usually develop fully until towards the end of second dentition, before which time it ought not to be interfered with. In some such cases it is justifiable to extract the mal-placed tooth, rather than remove two back teeth, which would be the better treatment under other circumstances, particularly if the first molars were seriously decayed.

Instruments for the purpose of regulating teeth are constructed to fulfil several objects—to prevent locking together of the teeth of the opposing jaws on closure of the mouth, and, in accordance with the requirements of the case, to exert such continued pressure or traction on those that are displaced or on the bone, that the teeth may be gradually compelled to assume their normal positions or the alveolar margin slowly modified in form to the desired extent. It has been seen that irregularities vary between the simplest kind—mere slight displacements of growing teeth—and the severest form associated with malformation of the maxilla. It will be understood, therefore, that the effect required to be produced in different cases by mechanical treatment varies also considerably; and it will be perceived likewise that the treatment can be carried out much more rapidly and effectually in the child than in the adult. At the former period of life when the alveoli are in process of growth a malplaced tooth can be drawn into position in a short time, and with the exercise of but slight force, whereas at a later date, the jaw having become con-

solidated, the treatment becomes long and tedious. The ease with which a developing bone may by mechanical means be modified in shape has already been referred to. It will be evident that in the simplest cases an instrument is not required to do much more than guide the developing tooth in the desired direction, whilst in the more difficult it will be necessary to keep up such pressure as shall cause absorption of the bone which opposes the movement of the tooth. To give rise to absorption by continued pressure, it is well known, is not difficult either in the jaw or in other bones. The precaution must be taken in dental cases not to cause irritation sufficient to pass into destructive inflammation. Some amount of congestion or perhaps even inflammation of the slightest extent must necessarily accompany absorption, but it is not difficult to arrange the apparatus to exert with great nicety any amount of force required, without exciting inflammation of undesirable severity. The more slowly the teeth are moved the less danger will there be of mischief arising. It is only experience in each case that can determine the degree of force which may be safely applied, and it is well, therefore, to commence always with a small amount, and gradually increase it.

That the movement of teeth under the influence of pressure must be accompanied in some instances by absorption of bone seems beyond doubt, but from the fact that the opportunity for post-mortem examination never presents itself during the treatment of these cases, the exact mode in which the changes in the tissues are effected cannot be ascertained, and for a similar reason it is impossible to explain the well-known circumstance that even after the absorption of bone has been apparently induced, and the teeth have taken the desired positions, they tend invariably to fall back into their former situation unless naturally fixed by antagonism with the teeth of the opposing jaw, or mechanically retained for a con-

siderable time by an instrument constructed for the purpose. Thus in the cases shown on previous pages (figs. 57 and 58), the treatment might cease safely so soon as the upper teeth had been pushed into their normal position where they fall in front of the corresponding lower teeth whenever the jaws are closed; whilst in such a case as depicted in fig. 65, if after the reduction of the deformity treatment were discontinued a relapse would certainly take place, the teeth falling back into their old positions with a rapidity corresponding to that with which they had been made to assume the new. In all such cases as these, after the irregularity is cured, a plate must be arranged to hold the teeth in their new positions, and must be worn from six months to two years, according to the age of the patient and the severity of the deformity.

It must be by no means understood because mechanical treatment of irregularities is most effectually carried out in early life, that therefore treatment should be commenced in every case as soon as the deformity becomes recognisable. On the contrary, it is found in practice that the only cases in any class in which it is expedient to commence mechanical treatment at a period before the permanent canines and second permanent molars are well in place are those in which the deformity must evidently become either confirmed or aggravated by delay. Examples of the most common variety of this class of case is shown in figs. 57 and 58. Upper teeth, as in this instance, once locking within the lower on closure of the jaws, obviously can never assume their proper position without mechanical treatment. The inexpediency of too early treatment even in cases like this has been spoken of on an earlier page. There is besides this last class hardly any other malposition which front teeth can take during eruption which will not probably improve, or become spontaneously cured in the natural

process of development as time goes on. The movements of the lips and of the tongue, the pressure of adjacent teeth and the force of mastication—either or all of these usually suffice to direct the teeth towards their normal positions to which also they naturally incline. On the other hand misplaced teeth pushed too early into proper position will quickly relapse in most instances after treatment. Similar remarks apply with even greater force to cases where deformity is due to mal-development of the jaw. The cases in this category must be extremely rare in which it would be expedient to apply mechanical treatment before the period named.

Regulating Apparatus.—The simplest form of regulating apparatus consists of a plate accurately adapted to the teeth and gums, the crowns of the molars being covered when desirable with a sufficient thickness to prevent the upper and lower front teeth from meeting. A fixed point is thus provided to which screws, springs, or levers, elastic bands, or wedges of wood, may be attached to act upon the teeth in any desired direction. It is of the first importance that the plate really form a fixed point perfectly rigid, and distributing its strain as equally as possible over the teeth and gums which it envelops. The material of which the plate is constructed may be either metal, or vulcanized india-rubber or metal and vulcanite combined. Vulcanite has some great advantages over metal. It is easier to make it firm in the mouth. If a perfect model be taken—and this is of prime importance—and the plate vulcanized upon it, the accuracy of the fit alone in most instances will suffice to fix it in the mouth. Additional rigidity may be obtained by slightly paring the model before vulcanizing at the necks of the temporary molars if these are in place, and after this it is never necessary to attach the plate by ligatures or clasps, an expedient which must be adopted frequently where metal alone is used. Vulcanite

again affords a more congenial surface for mastication than metal, and is less liable to chafe the surface and injure the enamel of the teeth with which it is in contact.*

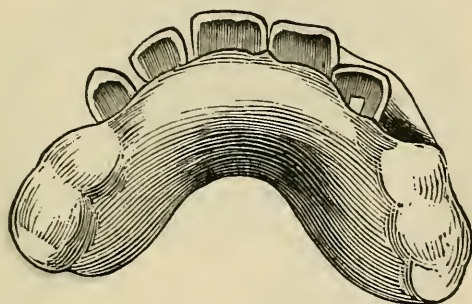
Of whatever material the plate is constructed it ought to be removed at intervals, as frequent as possible, for the purpose of thoroughly cleansing it as well as the crowns of the teeth which it envelops. The plate causes accumulation of particles of food over the surfaces of the teeth which it covers. These particles, if allowed to remain, speedily decompose, and thus give rise to decay of the teeth. Tooth-powder, such as prescribed on a later page, may be used with advantage during wearing of regulating plates; and the teeth may in addition be brushed with an antiseptic lotion, with which the mouth can also be frequently rinsed during the time the plate is in position.

Whilst it is not likely that even ill-made teeth would be seriously injured by a regulating instrument worn only for a short period, it must not be forgotten that in cases where teeth are of inferior structure, and particularly in unhealthy children in whom the secretions of the mouth are habitually vitiated, prolonged wearing of apparatus even when great pains are taken to keep the parts clean and aseptic, will result in most cases in some injury to the teeth. Caries may probably be started in delicate teeth on surfaces which become only to a slight degree abraded by friction of an instrument. Patches of defective enamel may be dissolved and disintegrated by weak acid which is formed by decomposing adherent *débris* during the daily periods, however short, through which the plate must be left in position. Long treatment also often becomes intolerable after a time to

* The details of impression-taking and the technicalities of dental mechanics proper, a knowledge of which is needed by every dentist, do not fall within the scope of this manual.

delicate or fretful children. All these considerations should be put plainly before the guardians of children before treatment is begun, and the advantages of regulating the teeth must be balanced against the discomfort of the process and the injury which long continued treatment may inflict. In cases where relapse is certain, unless treatment be long continued, nothing is more disappointing than to have to give it up when the deformity has already somewhat yielded. All these circumstances must be borne in mind, otherwise in the end these cases will in no sense of the word repay either patient or practitioner.

FIG. 76.

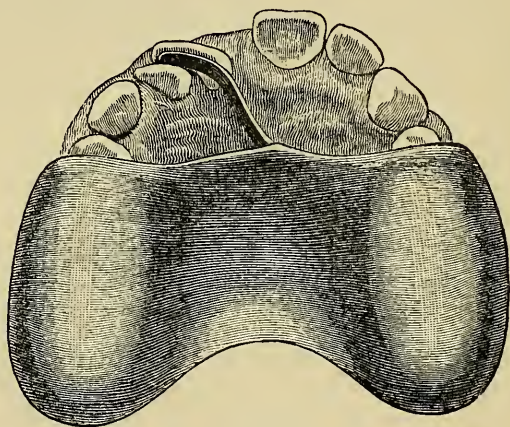


To make the character of regulating instruments clearly understood, the description of cases may suffice. Fig. 76 shows in position the instrument employed in the regulation of the case represented in fig. 58. This was an irregularity of a simple kind, one upper lateral incisor being displaced backwards, and held in malposition by the lower teeth. The vulcanite plate covering the molars kept the jaws sufficiently apart to prevent the front teeth from meeting, and the obstacle to forward movement of the tooth being in this way removed, but a slight amount of pressure was required to force it into right position. The pressure was obtained by a wedge of compressed hickory fixed in a chamber in the vulcanite

behind and in contact with the irregular tooth. The moisture of the mouth caused the wood to expand and in expanding to push the tooth slowly forward. The wood was renewed by larger pieces at intervals of a day or two, as the cure progressed, until the tooth having been driven sufficiently outward the patient was dismissed.

A similar effect may be produced by a metal spring.

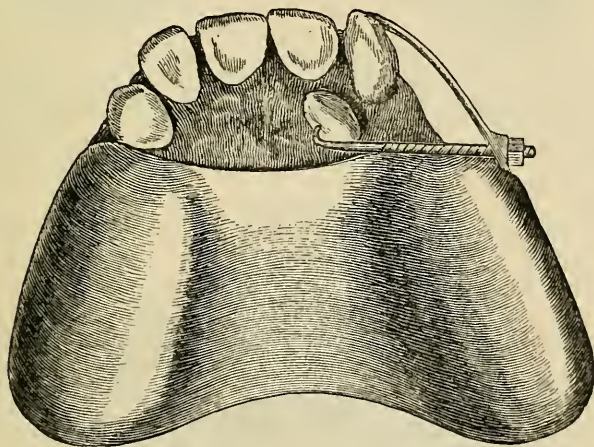
FIG. 77.



instead of a wedge of wood, and indeed this is as a rule the preferable mode. The spring is more cleanly, more certain, and its pressure is more easily controlled and adjusted. Springs may be made of gold or of piano-forte wire. The difficulty in obtaining much force from gold wire, owing to the unconquerable softness of the metal, has led in late years to the introduction of steel piano wire for springs. It possesses the qualities of elasticity and strength to a high degree, and is made in several thicknesses, which adapt it very well for the purpose. Plates with springs are shown in figs. 77, 79 and 81. Fig. 78, from a case of Mr. Quinby's, shows combined action of a spring directed upon a projecting

lateral, and a screw exercising traction upon a mal-placed canine. The spring was prevented from slipping by a small pit cut in the canine in which the point lodges. This pit was, on completion of the cure, filled with gold. The canine in this case readily yielded to treatment, although its crown lay so far from the proper position and although the patient had long passed the most favourable age of childhood. This case illustrates the great range through which a deflected tooth may be made to move when the apex of the root lies in normal position. It seems evident that to regulate this canine would have been impossible had the whole root been displaced to the same degree as the crown.

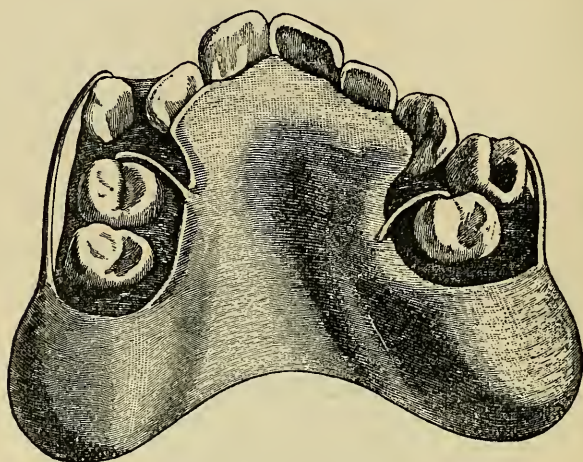
FIG. 78.



The next case is of a different character. The irregularity here consists of rotation of the central incisors on their axes. It was probably of congenital origin. The instrument with which it was treated is shown in position in fig. 80. It consisted of a vulcanite frame closely in contact with the inner angles of the twisted teeth, but clear of the rest of their surfaces.

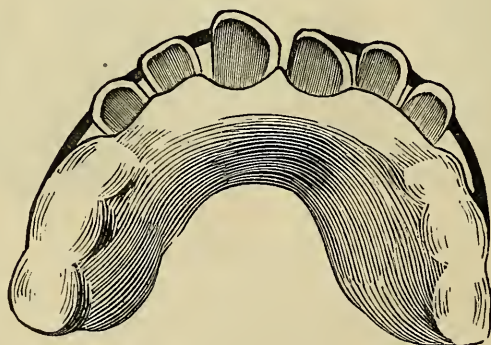From each side of this frame there proceeded a flat spring of gold wire, and these extending round in front

FIG. 79.



were so arranged, that their free extremities kept up constant pressure on the prominent edges of the in-

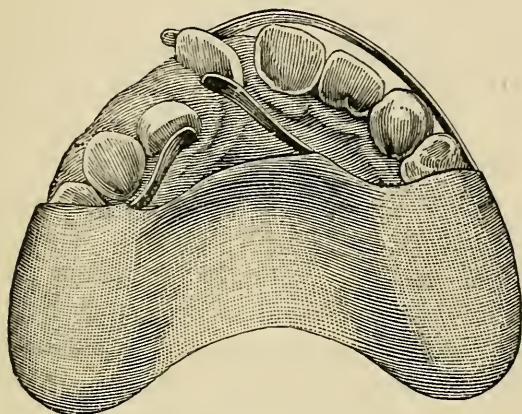
FIG. 80.



cisors. In this way the distorted teeth were compelled gradually to revolve, and the deformity was in time entirely removed. Fig. 81, from Quinby, shows a plate

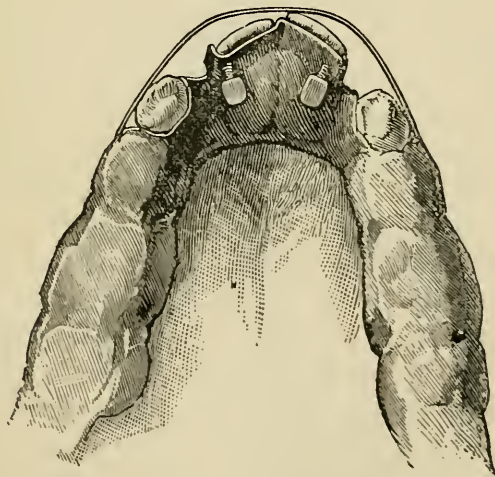
with springs, acting at once upon a twisted central and a misplaced lateral incisor; and fig. 79, from the same

FIG. 81.



work, represents the simple apparatus—vulcanite frame and metal springs—used in the treatment of the case

FIG. 82.



shown in fig. 59. Fig. 82, from Mason (9), illustrates yet another method of treating these irregularities. A

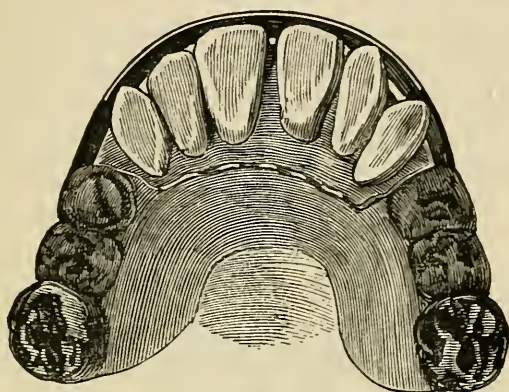
plate is fitted to the mouth, backing the twisted incisors and carrying screws to act upon the inverted angles, whilst a metal bar passing round in front, and pressing upon the prominent surfaces, causes the teeth to revolve instead of move forward.

Cases like the last, in which the teeth are merely turned in their sockets, are treated by some practitioners by an operation which has been called "actual torsion." This operation is performed by seizing each tooth firmly with a pair of forceps, and slowly and deliberately turning it until reduced to its proper position. By this means it is believed that the alveolar wall may be made to yield, and the tooth turned without permanent severance of its vascular connections, or injury to its vitality. The forceps ought to be specially constructed with broad flat blades lined with leather, or better with lead so as to avoid crushing the tooth or damaging the enamel. A plate previously prepared must be in readiness for insertion immediately after the operation, and must be worn for some few months to retain the teeth in the new position. The subjects of this operation should be young children in good general health, and an anæsthetic ought of course to be used. There must obviously exist, after the operation of "actual torsion," great danger of inflammation, perhaps involving the loss of the tooth, but such untoward results are stated to be in well-chosen cases rare. The advantage of "actual torsion" consists in the rapidity with which a cure is accomplished, but in proposing the operation it must be borne in mind that it involves unquestionably a serious risk, whilst the desired effect can be produced with certainty by other means, without any danger whatever.

Cases similar to that shown in fig. 65 may be treated by an instrument such as illustrated in fig. 83. From a vulcanite frame extend on either side flat gold wires made to terminate in front of the canine teeth, and each

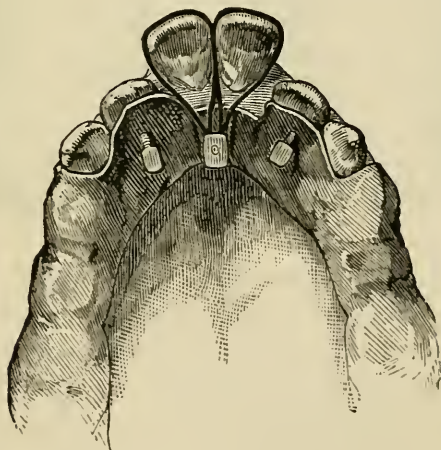has affixed at its extremity a small gold stud or hook. An elastic band] stretched between these hooks over the

FIG. 83.



faces of the protruding teeth affords the pressure necessary to reduce them in time to their proper position. The same effect may be produced equally well by means

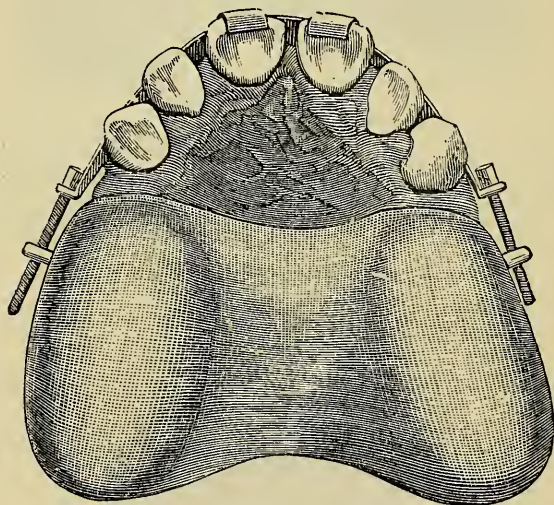
FIG. 84.



of elastic bands passed over the teeth, and attached behind to the surface of the plate, but this method sometimes causes discomfort by interfering with the move-

ments of the tongue, or with the lower teeth during mastication. An apparatus of this kind is depicted in fig. 84, from Mason. The plate is of metal. The projecting central incisors are acted upon by elastic ligatures attached to a stud on the lingual surface of the plate. The lateral incisors in this case being displaced backwards, are forced in the desired direction by screws passing through the plate, and pressing upon their posterior surface. Plates of this kind furnished with an elastic band (fig. 83), acting at once upon more than two

FIG. 85.



teeth, cannot be recommended for any but slight cases, and they are always somewhat objectionable from their uncleanness. I have mostly given them up in my practice in favour of such apparatus as shown in fig. 85, from Quinby. In this apparatus the bands are metal, and the force is obtained by screws which are tightened at frequent intervals. Screws may be used either for drawing or pushing, and a plate performing both of these operations at once is shown in fig. 89, from

Talbot. The traction is effected through a ligature, the propulsion by direct action of the screw on the malplaced tooth.

Elastic (india-rubber) bands, which often furnish useful means of applying traction in conjunction with a plate may in occasional cases be used alone to draw the crown of a tooth into good position; but they need caution and watchfulness. It is difficult to get a fixed point without ligaturing one end of the band to several teeth; and difficult to secure the other end in place over the crown to be acted upon. The bands tend to slip along the neck of the tooth beneath the gum giving rise to irritation and pain, and it is impossible to keep them clean when in position. For these reasons when rubber bands alone are used the patient must as a rule be seen daily.

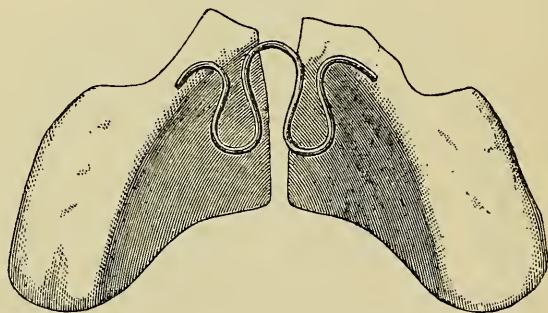
In cases where six to eight front teeth are to be drawn backwards it is best to commence with the more posterior teeth and get them into proper position before acting upon the front. It is very difficult to fix a plate securely enough to stand the strain involved in traction on so large a number at once. Besides this the operation always causes considerable irritation, with swelling of the gums behind the teeth, and this may probably become so extensive as to interfere seriously with treatment if too much is attempted at the same time.

Protrusion of the upper incisors in some cases is clearly due to abnormal development of the lower jaw, whereby the lower incisors in biting impinge on the posterior surfaces of the upper teeth in such a direction as to force the latter outwards. In such cases it is well to commence treatment by permanently preventing the pressure. This is to be accomplished by means of a plate fitted behind the upper teeth to receive the impact of the lower incisors, whilst at the same time the molars are left uncovered. The latter teeth are thus kept apart, and in young subjects, under this treatment, they

gradually rise, until they articulate again with their opponents. By the time this is accomplished the lower incisors which have been meanwhile prevented by the plate from advancing, no longer impinge behind the upper teeth, and these may then be acted upon and drawn inwards with comparative rapidity and ease.

By contrivances similar in action to those already described, the entire alveolar border of the jaw may be modified in form. For instance, in the contracted or V-shaped palate, an apparatus may be made to maintain equal pressure from within outwards along the alveolar margin of the jaw, until in time the required expansion of the arch could be accomplished. Perhaps the simplest apparatus for this purpose is that devised by Mr. Coffin

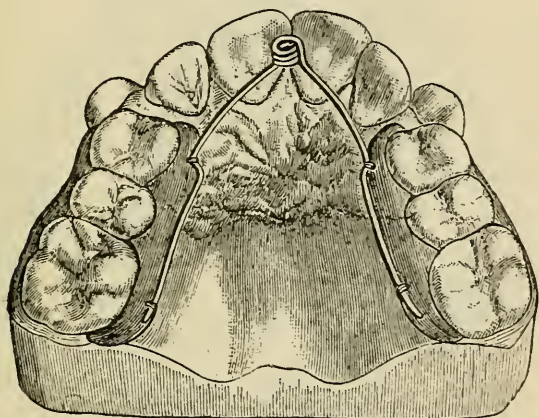
FIG. 86.



(fig. 86). It consists of a perfectly fitting vulcanite frame, capping the molars and covering the palate. The frame is divided into two equal parts along the central line of the palate. The halves are then connected by a spring of pianoforte wire. The spring is in shape like the letter W, and has its free ends attached one to each half of the divided plate, upon which it closely lies. The spring can be adjusted so as to exert with great nicety the slight outward pressure, which being sufficiently prolonged, is enough gradually to cause the needed expansion of the arch.

Expansion plates—as these instruments are called—are obviously intended chiefly for treatment of V-shaped and saddle-shaped jaws, and other cases where there is lateral flattening or compression of the alveolar borders. The deformity in a great majority of cases affects the upper jaw alone; the bicuspid and molars, and even the canines in some instances falling on closure more or less within instead of without the line of the lower teeth. In suitable cases of this character, expansion answers

FIG. 87.

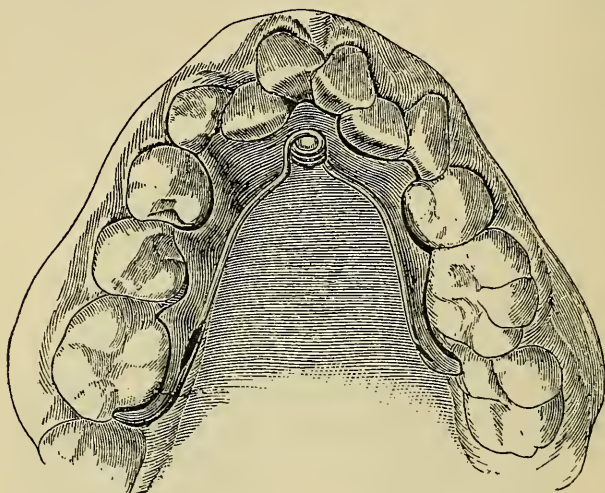


well, more particularly in that the teeth when pushed sufficiently outwards are prevented by the bite from relapsing. The question of obtaining space by extraction of teeth will have been of course first decided after careful study of the models, and in a considerable proportion of these cases room may be made by the treatment for all the teeth without sacrifice of any.

In deformities of this type, affecting the lower as well as the upper jaw, the same treatment, in well chosen cases, may be attempted. A typical case, upper

and lower jaw from the same patient, is depicted in figs. 87 and 88, from Talbot. The coil spring, the invention of Dr. Talbot, with which these plates is furnished is an admirable contrivance, not only for keeping uniform constant pressure through means of an expansion plate, but also for acting upon single teeth. For the latter purpose one end of the spring is secured to a

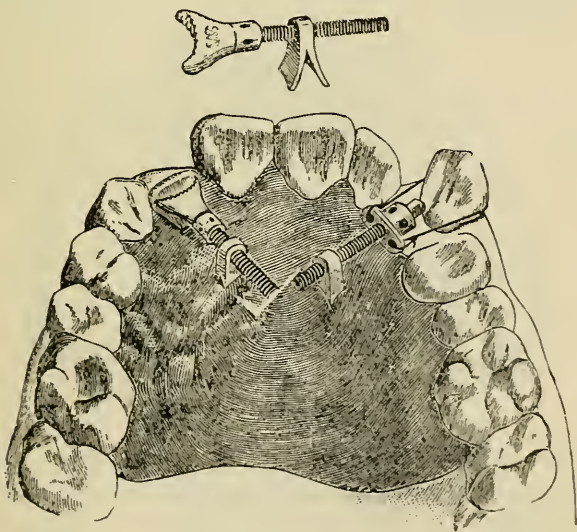
FIG. 88.



plate, the other being either made to act directly upon the crown, or to exert force indirectly through a ligature or lever affixed to the irregular tooth in accordance with the design to be achieved. For example, such a spring acting directly upon a tooth will push it in any desired direction; will exert drawing force if secured to a ligature; or pressing upon the extremity of a lever (a bar or collar) affixed to the crown, will effect rotation of a tooth with great ease and certainty. The force of these springs may be regulated with much nicety by merely bending the arms outwards or inwards. These springs, in different sizes of wire, are supplied by dental instrument makers.

The jack-screw and modifications of it (fig. 89) form a powerful means of applying pressure effectually across the jaw. Small screws are supplied by instrument makers for this purpose. They may be used in conjunction with a plate or may be made to act through the medium of gold bands or narrow gold frames fitted to the necks of the teeth. The screw is tightened from day to day by the dentist or the patient's attendant. A jack-screw across the palate, neatly and securely arranged, does not give rise to so much discomfort as a larger apparatus, the use of which it renders unnecessary.

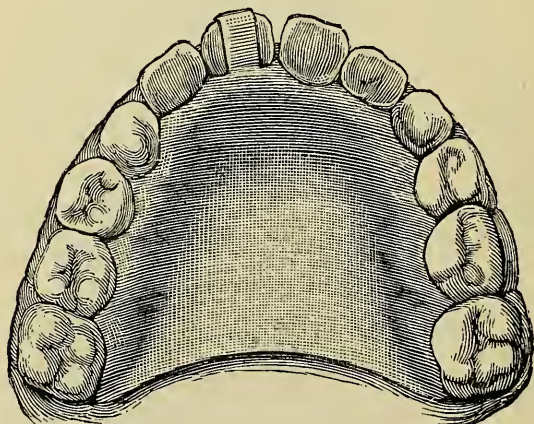
FIG. 89.



It has already been stated that in all cases in which a relapse after regulation is likely to occur—and this includes almost every case in which the teeth are not kept in position by the bite—a retaining plate must be worn for a period to prevent the teeth from falling back into

their faulty position. The slighter the movement of teeth caused in regulation, the more slowly they have been moved, and the more youthful the patient, the shorter will be the length of time during which a retaining plate need be worn ; but as these circumstances vary infinitely it is not possible to lay down any fixed rule. The time, as stated on a previous page, varies between a few months and one or two years. On discarding a retaining plate, the patient must be seen after a short interval, and if tendency to relapse appear, use of the plate must be resumed. Casts taken when the retaining plate is given up are useful to compare with the

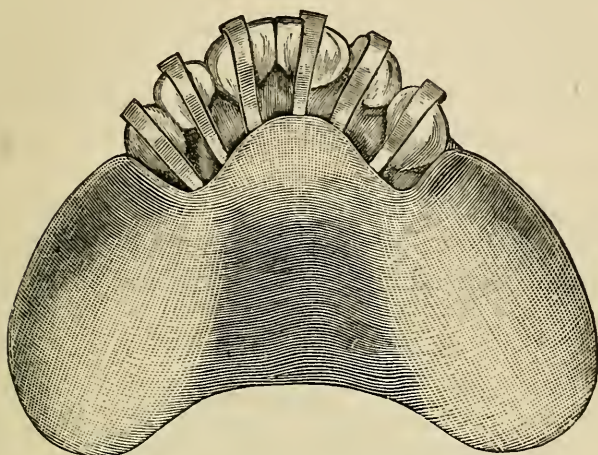
FIG. 90.



mouth for readier detection of relapse. The objections which apply to ordinary regulating plates apply also to retaining plates, but as the latter can be more frequently removed the danger from uncleanness is not so great. In some cases retaining plates may be dispensed with during the day and worn only at night or conversely ; and in many cases they may be left out during meals, so that the teeth may receive the salutary friction of mastication, besides undergoing a thorough brushing and

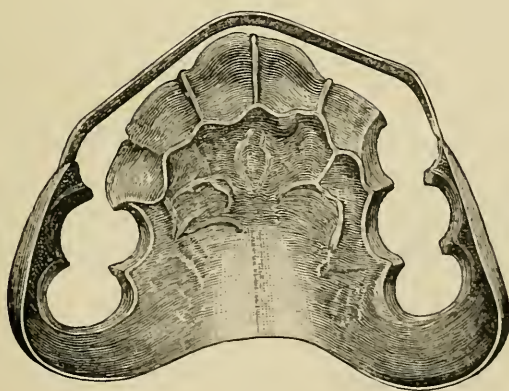
cleansing before re-insertion of the plate. The more free the surfaces of the teeth are left, the less the danger

FIG. 91.



of injury, and therefore plates forming closed cells for the teeth are to be avoided in favour of thin, carefully-adjusted, polished metal straps covering a small surface

FIG. 92.

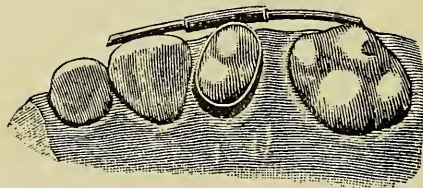


only. Good forms of retaining plates are shown in figs. 90, 91 and 92, from Quinby. In some cases a metal

(wire) splint secured by collars to teeth and moulded to the surfaces of those to be retained answers well. The fixing collars or bands are best cemented to the teeth to which they are attached, and they must be examined at intervals to guard against lodgment of *débris* through failure of the cement around the teeth. Retaining splints of this type are certainly not so likely as plates to cause injury. The cut (fig. 93) from Talbot depicts a splint of this kind.

It is not within the scope of this manual to enter further upon a description of all the numerous expedients which have been adopted in the devising of instruments

FIG. 93.



for regulating the teeth. Enough—it is hoped—has been said to make clear the principles upon which construction of apparatus is uniformly based, and indeed these principles alone being understood, there are few cases in which the designing of an instrument to fulfil the necessary objects can present serious difficulty to any operator having an adequate knowledge of dental mechanics and possessing a moderate amount of ingenuity.

CARIES.

CARIES, or decay of the teeth, is by far the most important of dental diseases. It is a malady universally spread—few individuals passing through life without an attack in one or more teeth—and with its sequelæ it furnishes the great majority of cases with which the dentist is in practice called upon to deal. Owing to the relatively simple structure of the dental tissues and to the external exposed position of the organs which allows the processes of disease to be closely watched, the phenomena of caries, compared to those displayed in the pathology of more complex parts, form an easy problem to investigate and to understand. There is nothing in the subject, whether as regards demonstrated facts or disputed points which cannot be mastered by a student of average capacity who comes provided with the necessary fundamental knowledge of physiology, chemistry and bacteriology. Without such knowledge he can neither understand dental caries nor the different problems of surgical pathology which he is obliged to master. The issues involved in controvertible questions concerning caries are few, narrow, and easily intelligible; and the student having the facts and theories fairly laid before him should have no difficulty in forming a correct judgment upon them. It is my purpose to give first that explanation of the nature of caries which is supported by the greatest mass of demonstrated and demonstrable fact, and which in its essential parts is

adopted and expounded by the great majority of investigators having valid claim to authority; secondly, to set forth from the writings of authorities such matters as may serve not only to make the preliminary explanation fuller and clearer, but also to expose the fallacies of other views which have been propounded; lastly, I propose to discuss at greater length objections to the theory, and to examine how far they affect its character as a true and sufficient explanation of the nature of dental caries, and this examination will include the discussion of additional facts which, it is hoped, may render the whole exposition more clear and exhaustive.*

Definition and General Description.—Caries is a process of disintegration, commencing invariably at the surface of the tooth, proceeding inwards, and due entirely to external agents. Dentine being a sensitive tissue, its exposure during the progress of caries sometimes, although by no means always, is attended by pain; but except in the manifestation of this one subjective symptom, both dentine and enamel are passive under the process of disintegration, and manifest neither pathological action nor vital reaction of any kind. By pathological action is here meant morbid changes in the tissues excited or produced through the influence of the vascular and nervous systems, and by vital reaction any change in the tissues not solely excited and produced by external agents.

Caries traceable to the same series of causes, both remote and direct, and accompanied by identical tissue changes may occur in natural teeth or in blocks of ivory refixed in the mouth by artificial means. By subjecting

* Research into the nature of caries is by no means difficult. I have myself examined and verified the facts—physiological, clinical and experimental—upon which the account of caries in this book is founded.

extracted teeth to the influence of agents, with imitation of the conditions existing in the mouth as to temperature, moisture and presence of micro-organisms, caries can be artificially produced indistinguishable from that occurring in living teeth.

The onset of caries is favoured, and its progress is hastened primarily by certain innate structural defects of common occurrence in enamel and dentine, and, secondarily, by some diseases of the buccal mucous membrane and some derangements of the general health. Crowding and irregularity of the teeth form also a predisposing cause of caries.

Except in some rare cases, caries, unless checked by art, having once attacked a tooth, advances towards the interior, forming a cavity which increases in size until the crown, and even the greater part of the root also, are destroyed. It is commonly attended with pain, which often commences in a mild form as soon as the dentine is slightly penetrated, and becomes most severe when the central chamber is closely approached or laid open, and the pulp, being exposed to the action of external irritants and to injury, becomes the seat of inflammation.

Etiology and Pathology. — To understand the nature of caries it is necessary first to bear in mind that enamel and dentine are soluble in acids which often exist in the mouth, and that inherent structural defects in enamel and dentine presently to be described, both furnish in a large number of instances, lodgment for acid-forming substances and render the ill-formed portions of the teeth easily acted upon and destroyed.

The active agents in caries are acids and micro-organisms. The acids, principally lactic, malic, butyric, and acetic, are mainly the products of putrefaction and fermentation, set up in fragments of organic matter,

food, mucus and epithelial scales, which are commonly present in the mouth.

These acids are often assisted by others derived from different sources. Some may be secreted by the mucous membrane. The normal secretion of the membrane is small in quantity and slightly acid. In health the acid is at once neutralised by the alkaline saliva, with which it mingles; but when the membrane is congested or inflamed, the mucus increases in quantity, and becomes more strongly acid in character. This was proved many years ago by the classical experiments of Sir J. Tomes. Again, acid is eructated in many gastric disorders. Saliva has an acid instead of an alkaline reaction in several diseases; in others acid mucus is secreted by the gums. The solubility of dentine and enamel in acids not more powerful than would be derived from the several sources named can be demonstrated.

The organisms active in caries consist of various species of bacteria and *leptothrix buccalis*. These organisms—except *leptothrix*, which is peculiar to the mouth—are such as are more or less frequently present in fermentation and putrefaction wherever occurring. Fermentation and putrefaction are produced in the mouth by the same causes which give origin to them elsewhere—namely, by the proliferation of micro-organisms. During these processes, as they take place in decomposing substances lodged about the teeth, acid is formed, capable of decalcifying dental tissues; and as this is the main source of acid, and as micro-organisms are essential to the process these germs must be looked upon as prime factors in causation of caries. The organic fragments and decomposing tissues occupying a carious cavity invariably exhibit a markedly acid reaction, and on analysis they yield an appreciable percentage of acid.

The factors in the direct causation of caries are, first,

a weak spot in the enamel, or the retention of acid-forming agents in contact with its surface; secondly, acids and organisms in sufficient quantity to effect disintegration of the tissues. That acids alone do not produce all the phenomena of caries is proved, not only by the presence invariably of micro-organisms, but also by the fact that in the progress of the disease destruction of dentine is more rapid than of enamel, whereas acid acting alone would completely destroy the enamel, but only partially destroy dentine. It is, on the other hand, inconceivable that micro-organisms could gain access to the dentine without the assistance of an acid capable of perforating enamel. In experimental decalcification and disintegration of extracted teeth by acids alone the tissue-changes present little resemblance to caries—the enamel being slowly destroyed first, and the dentine rendered gradually soft and elastic by removal of its lime salts.

Since putrefaction and fermentation must certainly occur in the matters lodging upon the teeth and within a carious cavity, and since decomposition of that kind cannot go on without the assistance of micro-organisms, the presence of these germs in caries might have been safely predicted. They are, in fact, not only present invariably so soon as carious action is established, but in every case, without any exception, they are found occupying the dentinal tubes during the progress of the disease. Of the organisms found in a cavity and within the tubes cocci are the most frequent; they occur in the form of groups (*staphylococcus*), pairs (*diplococcus*) and chains (*streptococcus*). Bacteria proper—rods of varying length—are less abundant. *Leptothrix* is found in all cases, especially on the surface of decay; but sometimes it appears almost alone in the cavity and dentinal tubes. Bacteria in the comma form and as spirilla and spirochæta

also occur, but not in relatively great numbers.* *Torula*—one of the true organisms of fermentation—is pretty frequent, appearing mostly on the surface among particles of food, but also occasionally in the tubes.

Caries often commences on a surface of a tooth perfectly free from inherent structural defect. This occurs especially on lateral aspects, or on interstitial surfaces bordering nooks and crannies formed by irregularity and crowding; for it is in these situations, where the shelter allows particles to remain undisturbed for lengthy periods, that organisms and acids are constantly generated during the decomposition of particles of food and irritation of the mucous membrane.

But caries most frequently has its starting-point at some part of the enamel and dentine, the seat of innate structural defect. Imperfections in structure, from which few sets of teeth are altogether free, may be owing to defect either in the quantity or in the quality of the tissues. Defects in quantity consist of pits and fissures in the enamel and dentine. These vary in extent between minute cracks perceptible only under the microscope, and cavities—as displayed, for example, in honeycombed teeth—plainly visible to the naked eye. They may penetrate the enamel alone, or may extend to a greater or less depth into the dentine also. The most common situation for cracks and fissures is in the depths of natural depressions in the contour of the tooth, as for example between the cusps of bicuspid and molars, but they are also not unfrequently found on the lingual surface of upper incisors, in the centre of the buccal surface of lower molars and in other positions. Minute cracks in enamel only visible under a low magnifying

* Recent researches point to the conclusion that in some instances various forms, apparently distinct, may merely represent phases in the life-history of a single organism.

power are often to be found here and there in teeth otherwise of perfect formation. Fissures which involve the dentine as well as the enamel are the most favourable to the attacks of caries.

Defects in the quality of the tissues may involve the whole body of the tooth, or may be confined to certain spots in the enamel and dentine. That the dental tissues vary infinitely in strength in different individuals is demonstrated daily in dental practice. In well-made teeth the sound enamel—as hard as quartz—tries the steel of the best tempered drill or chisel. On the other hand, badly formed teeth are commonly met with of which the enamel untouched by decay is throughout of chalk-like softness. If the enamel and dentine of delicate teeth unaffected by caries be examined microscopically, it will be found that both one and the other present well-marked evidences of imperfect formation. The enamel instead of appearing a densely hard, almost homogeneous mass, is comparatively soft owing to imperfect calcification and porous in consequence of incomplete coalescence of its formative elements. It retains a marked fibrous character. The fibres are imperfectly blended; their transverse striæ are clearly evident, and they are often penetrated at their centres by tubes or small cavities. At parts the fibrous character may be altogether lost, the tissue consisting of an imperfectly united granular mass.

The dentine exhibits at parts throughout its structure, and especially immediately beneath the enamel, patches of soft ill-calcified defective tissue similar in character to the globular layer, which, in well-formed teeth, exists only at the point of juncture with the cement. In the spaces within this defective tissue—sometimes called interglobular spaces—the tubes end, or they may even run on and terminate in dilated extremities within the substance of the enamel.

Innate structural defects of typical character are well

shown in the photo-micrographs, figs. 94, 95, 96 and 97. These sections are all taken from teeth unaffected by caries and presenting neither flaw nor blemish discoverable by the naked eye. In fig. 94 the enamel, tolerably sound on the surface, shows at intervals granular patches extending towards the dentine. The dentine displays large areas of globular (imperfectly calcified) tissue at short intervals. Fig. 95 exhibits a minute fissure at the surface, surrounded by a considerable area of granular tissue, in which the fibrous arrangement of normal enamel is quite absent. This surface under the microscope also presented a flaky appearance, such as on a larger scale is seen on the outer surface of an oyster shell. Fig. 96 shows a surface-fissure in enamel, also widely bordered by ill-made tissue—porous and granular. Such a fissure, although minute and invisible without the microscope, is large enough to allow penetration of fluid with minute organic particles which would form a nucleus for decomposition. In fig. 97 is beautifully displayed successive strata of globular dentine from the same tooth from which the section of enamel shown in fig. 96 was taken. In this tooth a slight thickness of tolerably well-made dentine underlay the enamel, but the globular strata extended widely in all directions at the depth and at the intervals seen in the photograph.

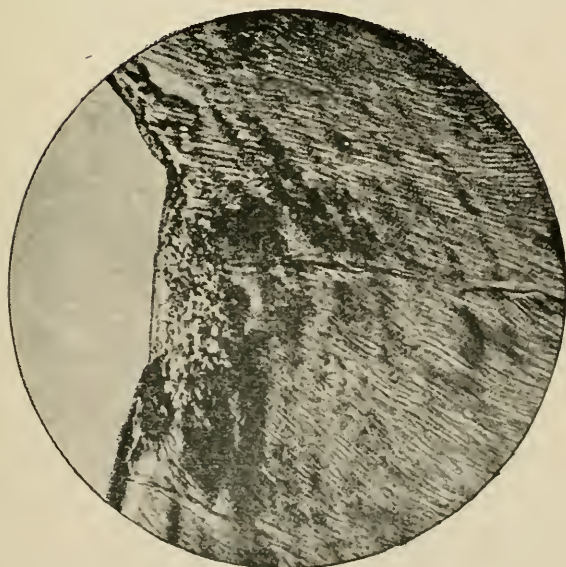
It does not always happen by any means that all the structural defects in the quantity and quality of the dental tissues, which have been just mentioned, commonly exist together in one tooth. Their degree and character vary infinitely. It would probably be very difficult to find a set of teeth of otherwise good organisation in the members of which one or two pits or fissures, or small patches of defective enamel were not discoverable; whilst in teeth of which the structure generally is inferior, there are often to be discovered isolated portions of still feebler formation. These facts

FIG. 94.



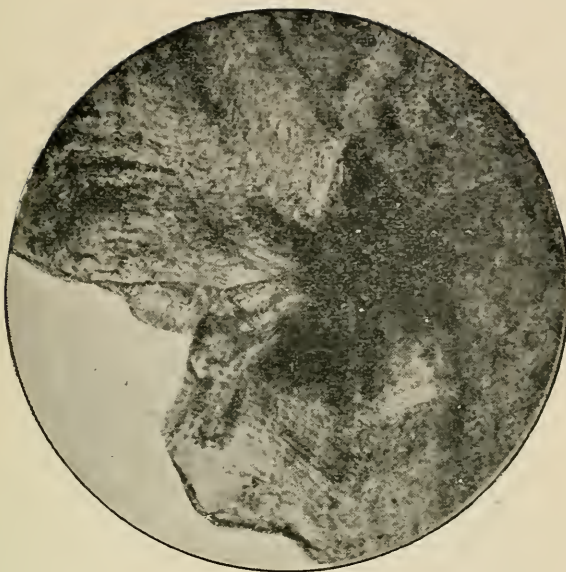
Section of enamel and dentine, showing inherent structural defects in both tissues. The dark shaded patches in enamel are granular portions; those in the dentine are globular structure—ill-calcified tissue containing lacunæ filled with organic matter. From a tooth free from caries and presenting no external mark of defect. Photo-micrograph by Mr. Charters White.

FIG. 95.



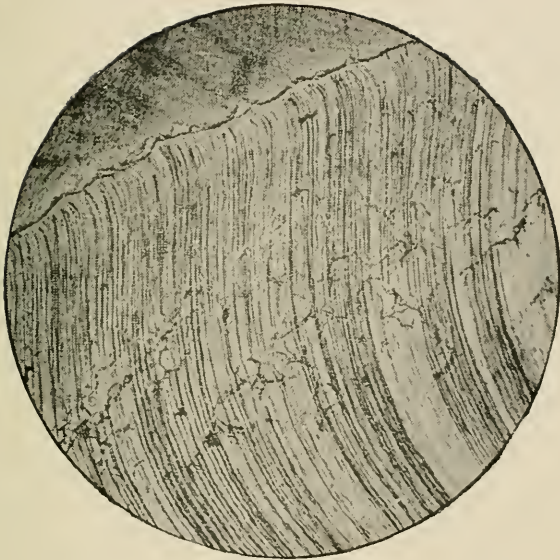
Section of granular enamel from the surface of a tooth free from caries, and displaying to the naked eye no apparent defect. $\times 150$. Section by Mr. Charters White. Photo-micrograph by Mr. A. Pringle.

FIG. 96



Fissure and granular enamel at the surface of a tooth free from caries, and without any blemish visible to the naked eye. $\times 150$. Section by Mr. Charters White. Photo-micrograph by Mr. A. Pringle.

FIG. 97.



Section of inherently defective dentine displaying at a slight depth beneath the enamel successive strata of globular tissue. From a tooth free from caries, and with no superficial defect visible to the naked eye. $\times 150$. Section by Mr. Charters White. Photomicrograph by Mr. A. Pringle.

must be borne in mind in considering both proximate and remote causes of caries.

Ill-made tissues—enamel and dentine—imperfectly calcified throughout or in part, constitute one of the main predisposing causes of caries. A second cause is crowding and irregularity of the teeth due to smallness and malformation of the maxillæ. Whilst it is the exception to find an individual of a civilised race with dental tissues in every tooth perfect in structure, it is equally uncommon to find one with jaws perfectly formed and of full size. In a well-developed jaw every tooth is subjected to the constant beneficial friction of the tongue, and of food during mastication; whilst all the dental surfaces are in health constantly washed by alkaline saliva. These conditions render impossible the prolonged lodgment of decomposing acid-forming products about the teeth, and so one potent factor in the causation of caries is absent. But it is the exception to meet with a case in which at least some crowding of teeth does not exist—most often there is a want of space, the teeth being closely impacted, and one or other of the set more or less overlapping its neighbours. Between such slight cases all degrees of crowding and irregularity are to be observed up to the extreme instances, described in a previous chapter, where the teeth at places are found leaning at all angles, wedged together in what looks like one confused mass. It is easy to understand how such conditions of crowding and irregularity make certain the accumulation of decomposing foreign particles in the unnaturally narrow interstices between the teeth, and in the nooks and crannies formed by irregularity. It is especially necessary to note the fact that the extent and character of irregularity and crowding of the teeth vary infinitely in different individuals.

To structural defects inherent in the tissues and irregularity and crowding of the teeth a third predisposing

cause of caries must be added. This is made up of all diseases accompanied by vitiation of the buccal secretions or which tend to the formation or deposit of acid and the accumulation of products of decomposition within the mouth. This is, perhaps, the most important of the predisposing causes of caries; and, indeed, Professor Wedl classes caries under "Anomalies of the Secretions," holding that it is not really a disease of the dental tissues, but rather disintegration of the tissues, due to the physical effects of the morbid secretions. It is evident that with a free flow of healthy saliva, and a due secretion of normal mucus there would be much less caries; but the effect of decomposing remains of food, and the opportunity which is afforded by structural imperfection of the tissues and irregularities of the teeth for the prolonged lodgment of *débris*, and its fermentation and putrefaction in contact with, or even within the substance of, the enamel, must not be ignored.

There is hardly a single derangement of health which is not attended by vitiation of the secretions of the mouth. The physician finds, as a rule, no surer indicator of a lowered standard of health than a foul tongue. From the occasional foul tongue and clammy mouth accompanying a transient attack of dyspepsia—from which probably even every robust individual suffers now and again—every degree of derangement of the secretions of the mouth is met with in disease, up to the severe condition associated with the zymotic fevers, such as smallpox or typhoid. During these diseases the secretion of saliva is scanty, often almost suppressed, and the teeth remain, perhaps for weeks, coated with sordes—accumulations of epithelial scales, viscid mucus and other foul secretions, crowded with bacteria and overgrown with *leptothrix*. The condition of ill-health accompanying pregnancy in some women furnishes another instance in point. In most of these cases the symptoms are due to or associated with

disorder of the digestive organs. The appetite is morbid and capricious'; vomiting and eructation of food frequent; the tongue is foul, and the gums very frequently in a condition of chronic congestion or sub-acute inflammation attended with erosion of epithelium and secretion of muco-pus or tenacious mucus around the necks of the teeth. Then in gouty attacks the saliva has often an acid instead of alkaline reaction. In scrofulous subjects there is commonly a characteristic condition marked by chronic congestion and swelling of the gums, with secretion of viscid mucus. Some phases of syphilis and of phthisis, diabetes, chlorosis, and chronic alcoholism, are marked by congestion and inflammation of the gums, by stomatitis in some form, or by distinct and easily recognisable morbid changes in the secretions of the mouth.* It is needless to multiply instances or to examine further or more minutely these affections. The main point to be observed is that like the other predisposing causes of caries, this last varies infinitely in different individuals; but unlike the other causes which are constant and persistent, vitiation of the secretions is marked by the utmost variability and inconstancy; for it attends throughout life, in corresponding proportion, the smallest, not less certainly than the greatest, departure from the standard of perfect health. If these facts upon the subject of predisposing causes of caries be kept in view, there need be no difficulty in understanding how the

* By directly acting upon the teeth and by augmenting the general acidity of the secretions, acid medicines — particularly tincture of iron and the mineral acids — may aid in causation of caries. Improper dietary may act in two ways; by deranging digestion it may give rise to foulness of the secretions; by introducing certain articles it may directly promote fermentation and putrefaction within the mouth. Sugar, the abuse of which in form of sweetmeats is so common with badly-managed children, no doubt acts in both these ways.

origination of this affection is often coincident with the outbreak, and its advance synchronous with the progress of constitutional disease; nor in understanding how caries when previously present in an incipient stage or slowly progressing may, under these circumstances, be accelerated, and run a rapid course. It is instances of this kind which have led to the assumption that the destructive process may be induced or hastened by morbid influences acting from within the teeth—an assumption about which more will be said presently.

The facts that enamel and dentine are soluble in acids, the existence of which in the mouth commonly arises from various sources, and that inherent structural defects in enamel and dentine not only furnish places favourable for the lodgment of acid-forming substances, but at the same time render some portions of the teeth more readily acted upon than others, suffice in many cases both to explain the origin of caries and to show why the disease commences at certain isolated spots, and does not affect uniformly and at once the entire surface of the crown of a tooth. The incidence of caries, its localisation in certain teeth is, as just explained, also often governed by conditions of crowding and irregularity. Consideration of these facts with the others bearing upon its etiology enables us not only to understand the common association of caries with various diseases and cachexiæ, but also makes clear why caries to a greater or less extent shows itself, sooner or later, in every individual whose dental development is not perfect and whose general health is not invariably at the highest level. Given, first, innate structural imperfection of the tissues varying infinitely in different individuals: secondly, crowding and irregularity of the teeth, equally varying in degree; and, thirdly, vitiation of the buccal secretions, not only varying in amount, but extremely irregular in appearance and in duration

through periods in the life of different individuals, and we account fully for the etiology of caries without needing to invent any questionable hypothesis. The mutual relation of these causes is of course often too subtle and too intricate to be traced, even if we had the patient under constant observation ; but these causes are demonstrable ; they suffice to account completely for the effects ascribed to them, and as will be presently seen these effects cannot be accounted for on any other theory unless based upon supposition irreconcilable with the anatomy of the dental tissues, and incompatible with clinical and experimental fact.

The stages in the progress of caries are as follows :—The enamel is first perforated by acid, and the resulting cleft, cavity, or roughened surface forms a *depôt* for the lodgment of decomposing particles. When dentine is reached the organisms proliferate in the fibrils along the tubes, and, producing acid, dissolve the lime salts from the matrix. As the organic basis of the tissue becomes decalcified, this also furnishes pabulum to the organisms, and the destruction of the dentine is thus gradually completed, whilst the enamel, partly dissolved and undermined, either remains as a wasting shell or breaks away for lack of support.

The Macroscopical Appearances exhibited by enamel and dentine in caries, consisting mainly of discolouration, softening and disintegration of the tissues, bear a general resemblance in every case. They differ only in consequence of the mode of onset, the situation and rapidity of the disease. The discolouration in the incipient stage on an unbroken surface of enamel usually amounts to no more than slight opacity of that tissue—a condition which also, as a rule, prevails throughout the later stages on the borders of the cavity of decay. When the disease begins in a fissure, and when a cavity is formed, the discolouration is more marked—the softened

dentine assuming a brown tint, or becoming stained to a blackish hue. This discolouration is due to the presence of pigment-forming bacteria.* It has been proved that bacteria produce pigment, and moreover that several varieties produce their own particular pigment, one kind black, another yellow, a third green. Cavities in which the disease is progressing rapidly show least discolouration.

This is often exemplified in decay of approximal surfaces; one tooth will in these situations frequently be found extensively carious, whilst the other shows only a discoloured—perhaps black—patch, due to merely superficial pigmentation of the enamel.

The softening and disintegration perceptible in the successive stages of caries vary considerably. When a surface of enamel is first affected it appears eroded, rough, and full of small holes, is readily scraped away by a steel instrument, and is evidently softened. The contrast between carious and sound enamel is most conspicuous in teeth of good formation. The carious enamel is easily cut through and broken down by the chisel or drill. It is chalky and friable, whereas the unaffected margins of the cavity offer great resistance to cutting instruments. When the mischief has commenced in a fissure, little softening may be apparent for a time at the surface, but at length the undermined enamel breaking down or being cut away, discloses a cavity in the dentine filled with disorganised tissue. Such a cavity is formed in most cases in the latter stages of the disease. The greater enlargement of a cavity in the deeper parts is due first to the fact that the dentinal fibrils and the organic basis of dentine help to

* It is not necessary to suppose the presence of special pigment-forming organisms where colouration appears such as at present in caries, since it has been proved that pigmentation is a very common occurrence during proliferation of organisms of every kind.

furnish pabulum for micro-organisms; secondly, micro-organisms produce acid, and this acid is obviously most abundant and active in the depths of a cavity where it is least disturbed and least diluted by access of saliva. Moreover, each tubule forms a channel through which the disease is conveyed onwards. To this circumstance is due the fact that cavities within the dentine are very commonly in shape like a cone with the apex deepest—this shape corresponding to the radiating arrangement of the canals. Such a cavity very often communicates with the surface by only a small opening in the undermined enamel.

Variations in the physical character of the disease, due to the different power of resistance of the tissues in different cases and to other accidental causes, have given origin to such distinctive terms as “spreading,” “penetrating,” “soft” and “hard” caries. Thus when caries invades a mass of interglobular substance, it is easy to understand how the disease advances with greater rapidity at that part than at the superficies. On the other hand, when the surface of a tooth is composed of defective enamel, as in honeycombed teeth, whilst the underlying tissue is of good structure, caries will spread faster than it penetrates.

A cavity on the grinding surface of a molar, of which the undermined margins of enamel become soon broken down, into which food is forced during each act of mastication, and which is perhaps as frequently cleared by a tooth pick, will, of course, present different appearances from those displayed by a cavity which from its position is left undisturbed for a prolonged period. Cavities of the latter class oftenest found in closely impacted mesial or distal surfaces will, when the investing thin shell of carious enamel is cut through, frequently be found filled with the organic frame of the dentine retaining its form, but in a more or less disorganised,

softened and moisture-soaked condition, the mass varying in consistency between soft deal and sodden cardboard. The softened tissue is easily cut and it comes away in large coherent flakes. This condition, which exemplifies in the gross the stage of preliminary softening prior to disintegration so often distinguished by investigators, is probably of most frequent occurrence in teeth with inherently soft ill-calcified dentine, and in which decay has run a rapid course.

Tobacco smoke, preparations of iron taken as medicine, and such-like ingesta, which the patient may be in the habit of using are apt to stain carious tissues and alter their appearance.

In some few cases carious cavities become completely filled and covered with tartar, owing to the patient having for a prolonged period avoided mastication upon the affected teeth through fear of pain.

Microscopical Appearances.*—The result of my research into the microscopical appearances of caries has been entirely to confirm the observations of Messrs. Underwood and Milles. I have fully verified the fact that caries in pulpless teeth and in dead teeth worn as artificial substitutes presents appearances identical with those found in living teeth.†

* For account of method of preparing and examining microscopical sections of carious teeth, see appendix. Many hundreds of sections were cut, stained and examined during preparation of this edition.

† Teeth in which through the action of disease the pulp has been destroyed are classed as pulpless teeth. A perfectly sound lateral incisor was knocked out by a blow a few years ago. The crown was afterwards mounted on a gold plate and worn as an artificial substitute. Recently, the crown showing signs of failure the patient returned. The tooth was found extensively carious, decay commencing around the cut margins of the crown where it rested on the plate and extending within upwards. A series of sections of the tooth which I have in my possession display all the usual microscopical appearances of caries. The tubes are filled with micro-organisms—

Examination of carious teeth and of carious dentine without any exception discovers the presence of micro-organisms, not only in the cavity but also invariably within the tubes.

The *débris* occupying a carious cavity made up of extraneous particles, fragments of food, &c., which have entered from the mouth, together with broken-down remains of disintegrated dental tissue, can be easily examined microscopically. Stained with fuchsine or methyl violet the organisms are easily distinguishable. The varieties of organisms met with have already been named, but among them in this part of a carious cavity more torulæ are found than deeper and within the tubes. Bacilli undergoing spore formation, which do not occur at all within the tubes are here also usually present.

The general appearance of carious enamel under minute examination does not widely differ from that produced by experimental decalcification out of the mouth, except that the affected tissue is usually more or less pigmented.

To cut a section of carious enamel sufficiently thin for examination under high microscopical power is impossible; it is too friable and breaks down before the necessary degree of tenuity is reached. The appearances seen under a low power vary very much in accordance with the structural character of the attacked surface and other circumstances. The tissue may have been of perfect quality, or the seat of a pit or fissure, or may present any degree of the inherent imperfections which have been just described and illustrated. The acid travels first along the lines of least resistance. I have not been able to verify the statement (made by Messrs.

chiefly cocci—the “zone” was visible under a low power, and „pipe-stem” appearance exists in the stratum of dentine where it is usually found.

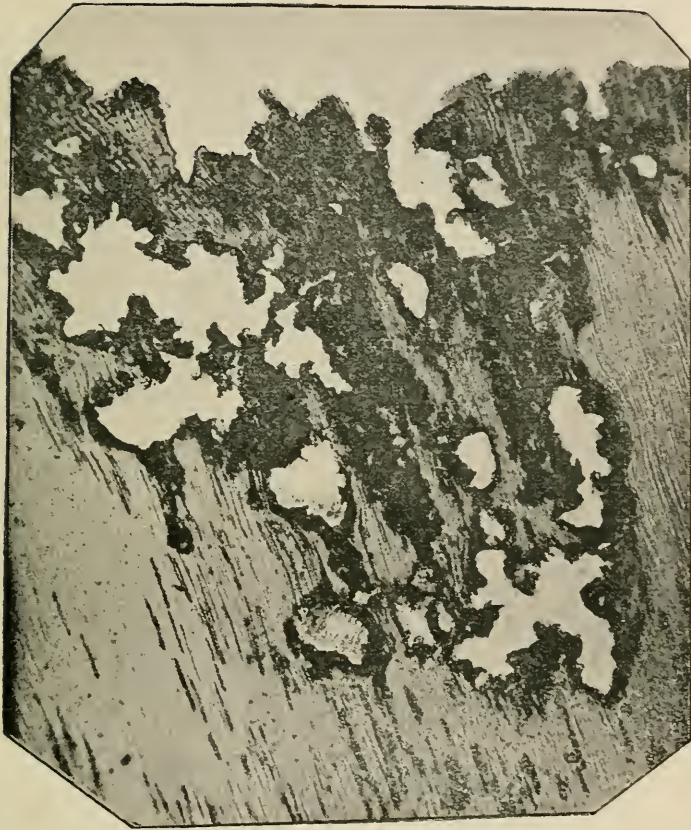
Tomes) that as a rule the centres of the prisms are first affected, but since the central portions of the prisms are often ill-formed—sometimes they are tubular—in inherently defective tissue, there need be no doubt that Messrs. Tomes' observation is in a large number of cases correct. Where a granular condition exists the fibrous character is of course absent altogether. As soon as porosities or perforations of sufficient size for the lodgment of foreign particles are formed by the action of acid, micro-organisms can be detected by scraping the surface: and where a pit or fissure (inherent flaw) exists, foreign particles with proliferating organisms may be present below the surface from the first.

At the outer margin of a cavity in the portion of carious dentine on the point of breaking down, but with sufficient coherence to allow of the cutting of a section, the tubes are almost indistinguishable. The whole seems made up of a mass of organisms matted together in zooglea form, and partly supported by a trace of the organic basis of the tissue.

Fig. 98 shows a typical section through the outer margin of a carious cavity* under low magnifying power. The black shaded portions are masses of organisms which can be distinguished under the microscope, but owing to the thickness of the layers cannot be differentiated in a photograph. At the blank spaces—probably where the weakest portion of dentine or globular structure had existed—complete destruction of tissue has taken place. The deeper dentine retains its form, the tubes being enlarged and filled with organisms. In fig. 99 are exhibited the microscopical appearances in ad-


* The sections illustrated were all prepared by the Gram method with some modifications. By this method the organisms alone are stained, the dentine left normal in colour. For full account of the method see appendix.

FIG. 98.




Section of carious dentine at the external margin of cavity of decay. Typical specimen of the appearances under low magnification of carious dentine in the later stages of disintegration. The dark portions above are composed almost entirely of micro-organisms—in this case micrococci. The blank spaces where the dentine is entirely destroyed were probably globular tissue. Below enlarged tubes filled with organisms extend towards healthy underlying tissue. $\times 86$. Photo-micrograph by Mr. A. Pringle.

FIG. 99.



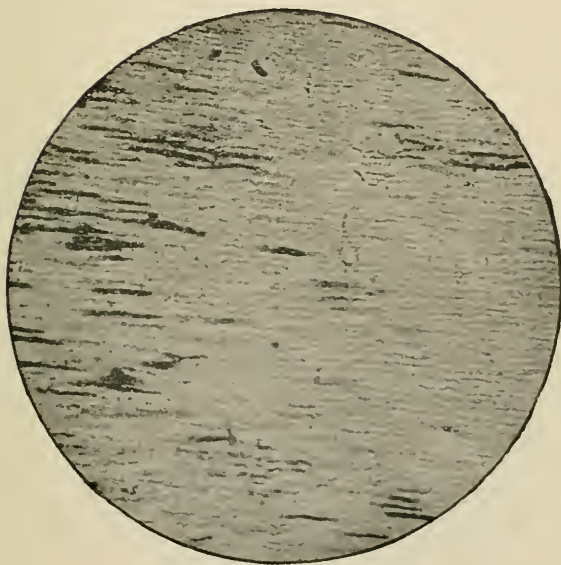
Section of dentine in advanced stage of caries seen under lower power in fig. 98. Tubes enlarged and filled with organisms, mostly micrococci. $\times 650$. Photo-micrograph by Mr. A. Pringle.

FIG. 100.



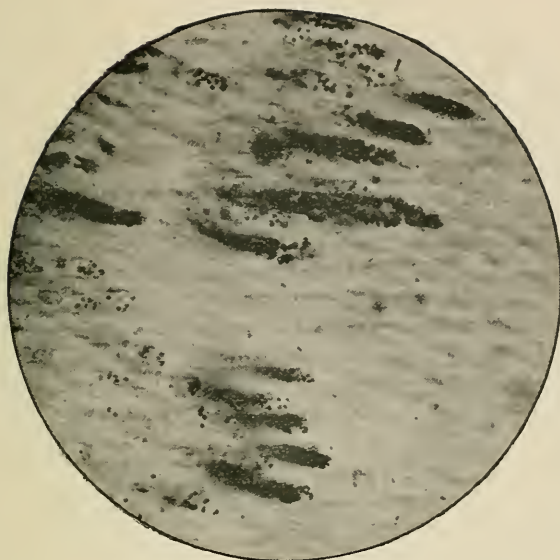
Section of dentine in advanced stage of caries. Tubes much enlarged and filled mainly with leptothrix. $\times 600$. Photo-micrograph by Mr. A. Pringle.

FIG. 101.



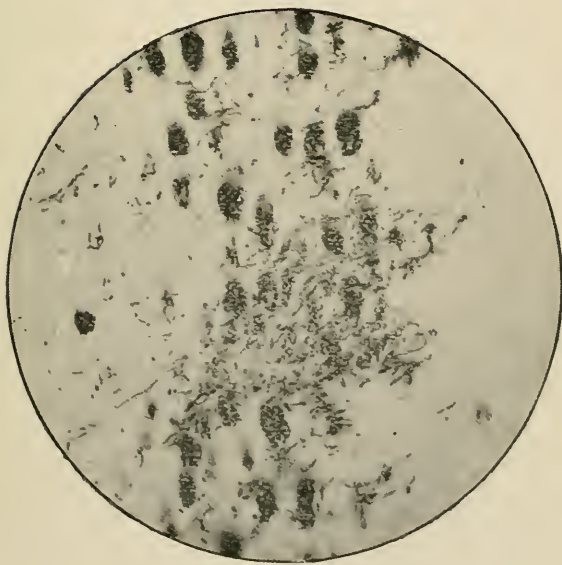
Deeper portion, less carious, of section shown in FIG. 98, but under higher magnifying power. Tubes at intervals filled with micro-organisms. This section to the naked eye appears unaffected. $\times 160$ Photo-micrograph by Mr. A. Pringle.

FIG. 102.



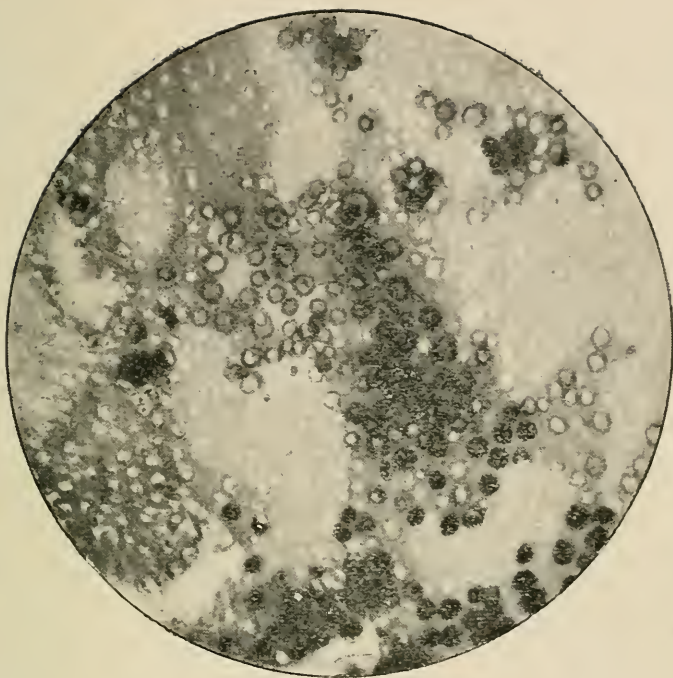
Section of carious dentine at point where diseased merges into healthy tissue showing micro-organisms—mostly micrococci—proliferating along course of tubes. Section similar to that shown in fig. 101. To the naked eye apparently healthy. $\times 650$. Photo-micrograph by Mr. A. Pringle.

FIG. 103.



Transverse section of carious dentine showing enlarged tubes filled with micro-organisms—mostly leptothrix. $\times 650$. Photo-micrograph by Mr. A. Pringle.

FIG. 105.



"Pipe Stem" appearance. $\times 375$. Photo-micrograph by Mr. A. Pringle.

vanced caries, but where the dentine is still far from broken down. The magnification ($\times 650$) is here large enough to allow micro-organisms to be clearly visible under the microscope, and many are distinctly individualised in the photograph. In this specimen they are mostly cocci. The dark-shaded patches are masses of organisms lying on different planes, so that to produce photographic distinctness of individual organisms is impossible. In fig. 100 there is shown a section ($\times 600$), in which the tubes are mainly occupied by leptothrix.

In the vast majority of carious teeth cocci form the great bulk of organisms within the tubes, and although leptothrix is invariably present on the surface it is only in rare cases that it alone occupies the tubes. In the photograph (fig. 101) are clearly exhibited the appearances of carious dentine at an early stage of decay. The less affected portions of such a section would present, to the naked eye, no evidence of disease. A similar section under a much higher power ($\times 650$) showing the point of junction of carious and healthy tissue is shown in fig. 102. Under this power micro-organisms are clearly differentiated, and in the photograph cocci (which predominate in this section) can be distinguished. In fig. 103 is seen a transverse section of carious dentine ($\times 650$). The organisms are so closely packed that they cannot be differentiated within the tubes; but in sections like this many organisms can always be seen at points where the tubes are breaking down.

The advance of organisms in caries may be likened to the progress of an invading army. On the surface are massed the main hordes, with smaller bodies pushed forward along every avenue (tube); whilst at the farthest limits of the invaded territory, beyond the sphere of decay distinguishable to the naked eye, a few narrow files of bacteria may be discovered by the microscope

penetrating like the advanced guard of an invading host. This simile was first suggested by Mr. A. Underwood, who also pointed out the fact that the tubes of dentine around the immediate sphere of decay were always penetrated by organisms before showing morbid changes recognisable without the microscope.


It was noticed by the earlier dental pathologists that certain changes apparently take place prior to actual disintegration in that portion of dentine through which the disease is advancing, and which is situated immediately contiguous to disorganised tissue. This altered dentine which has a translucent appearance, is however visible only under a low power, and forms either a regular zone, or exists in isolated patches around the walls of the cavity. This phenomenon was once thought to indicate invariably a vital or pathological action, a natural effort to arrest the disease by calcification of the dentinal fibrils. It is found, however, that a precisely similar alteration occurs in caries of dead teeth and is always produced during the gradual softening of dentine by acid, and to this softening, and not to consolidation, the effect is due.

Transverse sections of dentine at the deeper parts of a cavity, where carious action is in the incipient stage and before micro-organisms have penetrated, mostly exhibit in patches a peculiar appearance which has been likened to that which would be shown on section of a multitude of tobacco-pipe stems united by an intervening substance. This appearance also was once thought to indicate pathological activity, but it has been proved that it occurs in dead teeth, and can be produced by chemical reagents which render prominently visible the dentinal sheaths—the sheaths of Neumann. This appearance was first described by Sir J. Tomes, who characterised it in the manner which is here adopted. The drawing with which he illustrated his description is reproduced in

fig. 104. The exact appearances presented under the microscope are shown in the photograph, fig. 105.

Pain in Dentine during Caries and Reaction in the Pulp.—Enamel being devoid of sensibility, pain during caries does not begin before the dentine is affected, and it may be absent in the earlier stages of the disease. In these stages it is due solely to exposure of this sensitive tissue to sudden changes of temperature and pressure

FIG. 104.



of foreign particles and contact with irritating substances. In the later stages of caries pain arises from the transmission of similar irritation to the pulp, leading to inflammation, when that structure is either insufficiently protected by a layer of dentine, or actually exposed. Finally, if the disease runs on, there is added the pain due to extension of inflammation from the pulp to the dental periosteum.

The amount and character of the pain in all the phases

of caries are much diversified in different persons. In some individuals when dentine is reached, there is, almost from the beginning, constant pain of a dull aching character, which increases from time to time as decay advances into more severe attacks, whilst in others teeth are altogether destroyed without any suffering beyond slight occasional aching and uneasiness. It is the belief of many competent observers that carious dentine in some cases displays exalted sensibility—hyperæsthesia. It has also been shown that healthy dentine may present at parts areas displaying unusual sensibility, apparently due to presence of an abnormal amount of organic structure. Although the possibility of hyperæsthesia of carious dentine cannot be denied, my observation leads me to doubt whether it really occurs; and its occurrence certainly cannot be in any case demonstrated. Perfectly healthy dentine is sensitive, and the sensibility is much greater in some teeth than in others, and greater in some parts of a tooth than in others. All observers recognise, for instance, that the tissue is as a rule more sensitive immediately beneath the enamel than deeper. In cutting through carious dentine it is very common to pass through a highly sensitive layer into tissue displaying less feeling; but I have never observed the excitation of greater pain in this than commonly seems inflicted in many instances by excision of healthy dentine, whilst dentine the seat of incipient caries shows, as often as not, no increase of sensibility whatever. It is often difficult to distinguish pain referred solely to dentine from that which arises from irritation of a pulp when closely approached by decay.

It is impossible to account fully for the difference in the amount of pain arising during the progress of caries through dentine; but there can be no doubt pain is often due to irritation by vitiated secretions. The application of some substances—such as sugar—to carious dentine

notoriously excites pain. In some disorders of health, notably in pregnancy, for instance, where superficial caries so often gives rise to considerable pain, this may be presumably due to vitiated buccal secretions, such as in many of these instances are present.

Mr. Arthur Underwood has clearly shown that where extreme sensibility of dentine exists it may, in rare cases, be traced to the existence within the tissues of what he styles "aberrant filaments"—anomalous nervous filaments—radiating from the surface of the pulp even as far as the deep surface of the enamel. On the other hand, he has pointed out that in some cases the pulp may be insufficiently innervated, so that not only the dentine, but the pulp itself displays little sensibility.

Leaving out exceptional cases it may be broadly stated, however, that in the vast majority of instances there comes on from time to time, after dentine is affected, slight attacks of transient aching, particularly after entry into the cavity of irritating substances, such as sugar and salt, and a smart pang slowly subsiding is often inflicted when a hard fragment of food is forced in during mastication. The pain of this phase of caries is never of a throbbing character.

The etiology, symptoms and pathology of irritation and inflammation of the pulp and of dental periostitis associated with caries are discussed in a later chapter. It may be repeated that the most severe pain which arises during the progress of caries is due to inflammation of the pulp. It is by the extension of this inflammation that the dental periosteum becomes involved.

It must, however, be here noted that reaction in the pulp and vascular connections of the teeth are not necessary accompaniments of caries as they would be if this malady were of inflammatory origin. When they occur they arise in the later stages as the results—the sequelæ—of the disease, and they take no part in promoting or retarding the destruction of the hard tissues.

There need be no difficulty in believing that during progress of caries irritation may be communicated through the dentinal fibrils, and that in some cases the stimulus may excite calcification of the pulp. This belief is sufficiently supported by the fact that an occurrence of this kind is very common where sound teeth, in the course of years, become worn down by attrition, until the level of the pulp chamber is reached. In these cases the pulp almost invariably becomes converted into dentine over the surface in danger of exposure; and the new-formed tissue coalesces with the surrounding dentine, and is evidently the result of a natural reparative effort. It is, however, very rare indeed to meet with protective calcification of this kind in caries. There are few, if any, specimens in the museum of the Odontological Society, and though I have examined a vast number of carious teeth in hospital practice, I have never encountered a single example. It is very common to find isolated nodules of secondary dentine in the pulp of carious teeth, but such nodules are almost equally common after a certain age in teeth perfectly free from disease.

Cement in Caries.—Dental caries very rarely, if ever, has its starting place in cement, although the disease very often begins at the necks of teeth, in close contiguity to this tissue. Cement may become necrosed through stripping of its periosteum during inflammation, and the roughened surface, if exposed, at the neck of a tooth might, by giving lodgment to *débris*, lead to caries of the underlying dentine. Cement, be it recollected, is identical in structure with bone, but it forms so thin a layer until the apex of the root is approached, that it has little effect in influencing or modifying the progress of caries. It must also be remembered that cement is capable of pathological activity, and any morbid phenomena which it displayed would not be analogous to caries in enamel and dentine.

Owing, no doubt, to the vitality of cement and its investing periosteum, decay advancing along the exterior of a tooth usually becomes checked at the border of this tissue. The walls of roots hollowed to the depths by decay thus often remain until the supporting dentine within being nearly destroyed, the thin external shell enveloped by cement, becomes gradually crushed in or broken down.

Spontaneous Arrest of Caries.—Cases of spontaneous arrest of caries were alluded to further back, when it was implied that in rare instances the disease might come to an end without treatment. Such cases are of the following description:—The decay occasionally commences on the grinding surface of a tooth the external portion of which alone is of inherently defective structure. The occurrence is most common in honey-combed teeth, particularly in the first permanent molars. The decay spreads over the whole of the ill-made enamel composing the masticating surface, which gradually breaks down until the denser, better formed dentine beneath the defective tissue is laid bare. The surface so exposed being more or less used in mastication, constantly swept by the tongue and washed by saliva, becomes in time worn smooth and highly polished, and frequently endures for many years in that condition without any renewal of disease. The surface of dentine thus laid bare, often from the first, shows little sensibility, and in time frequently becomes insensitive. It is possible that in these cases, as in the analogous condition produced by simple wearing down of the teeth from attrition alone, the pulp becomes calcified over the surface towards which the waste of tissue is progressing. It is not uncommon to find caries on the mesial and distal margins of molars in the situation where foreign particles lodge, whilst over the greater part of the surface exposed to friction decay has become spontaneously arrested.

Epitome of Researches.--A large number of observers have demonstrated the fact, which is, however, very easy of verification by anyone, that acids which commonly exist in the mouth are capable of dissolving the earthy constituents of enamel and dentine. Many of the earlier investigators wrote at a time—not many years ago—when fermentation and putrefaction were believed to be purely chemical processes.

Magitôt's researches (8) were among the most valuable of this period, and they are interesting as foreshadowing future discoveries and presenting facts which, at the time, were inexplicable. He produced close imitation of caries by submitting teeth—sometimes protected at all but one part of their surface—to the action for prolonged periods of very dilute solutions of mineral and vegetable acids. He produced similar effects with fermentable solutions composed of sugar with organic matter. He incidentally proved that when an acid solution is kept from fermentation by the addition of an antiseptic, such as creosote, the enamel of an immersed tooth is entirely dissolved and the dentine gradually decalcified, but not entirely destroyed. We now know—what was not recognised at the date of these experiments—that the different results were due to the presence or absence of micro-organisms, the result being brought about in one case by chemical action, in the other by putrefaction and fermentation. Magitot held the opinion that caries is due to purely chemical action. He believed that he had produced experimentally in extracted teeth all the phenomena of the disease except the zone of translucent dentine. He considered the zone indicative of vital reaction—an attempt at natural arrest of the disease by calcification of the dentinal fibrils.

Leber and Rottenstein's work (6), written at a time when the study of bacteriology was in its infancy, formed a valuable and suggestive contribution, especially in directing attention to the development of one species of micro-organism in carious tissues, and to its effects in supplementing the action of acids. The initial stage of caries, they proved, is due to the solvent action of

acid, and when a breach of substance has been produced leptothrix penetrates into the interior of the tissues, and by proliferation, particularly in the dentine, occasions more rapid disintegration than would have been the case under the action of acid alone. They treated sections of dentine by staining with iodine, and demonstrated enlarged dental canals filled with what they described as minutely granular masses, composed of leptothrix and its developing elements. They clearly showed that masses of organisms proliferate within the canals and enlarge and distend them. They, in fact, described most of the phenomena which later discoveries have proved to be due to a great variety of bacteria, and they made a single mistake in classing all these as one species—leptothrix. They also proved that human teeth artificially inserted in the mouth, and also teeth manufactured of ivory blocks, displayed when carious all the microscopic changes which earlier writers had regarded as proof of a vital process in dentine.

Leber and Rottenstein's illustrations of sections of carious tissue under low magnifying power, although somewhat diagrammatic, correctly represent the appearances.

Professor Wedl,* in his great work (28) on dental pathology, classes caries under the heading "Anomalies of the Secretions." Caries, he believed, has its origin chiefly in abnormal secretions of the gums, of the oral mucous membrane, and salivary glands. He looked upon the secretion of the gums as most active, this secretion coming in immediate contact with and often forming a viscid covering on the teeth. In consequence of decomposition of the secretions, mingled with organic *débris*, acids are formed, which extract the calcareous salts from the hard tissues. The tissues are passive

* Written by one of the most distinguished professors of general pathology, this work is free from the narrowness so difficult for any specialist, however philosophical, to avoid. It is exhaustive, based on a foundation of original investigation beginning with anatomy, and it leaves no fundamental fact of any kind, no observation of any respectable investigator unexamined. To dispute the clearly demonstrated deductions which it formulates seems impossible.

under this disintegrating process, and show no vital reaction, and no change whatever of an inflammatory character

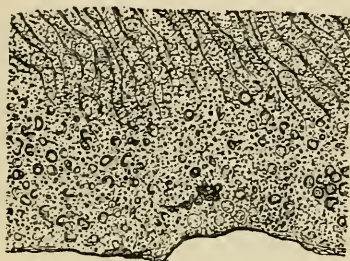
Wedl also noted that in certain conditions of health, such as pregnancy, there is an increased secretion from the gums of viscid mucus, which is frequently acid even without the presence of *débris* of food; and the action of this causes caries in many instances to assume a more or less acute character.

Wedl drew a clear distinction between dental caries and caries of bone, and pointed out why, on anatomical grounds, a process of ulceration resembling caries of bone is not to be looked for in enamel and dentine. The latter is an inflammatory process which originates in the soft parts of the bone and erodes its hard tissues. Dental caries, on the other hand, always commences in the hard tissues at a point furthest removed from the vessels, and spreads thence to the vascular pulp. The absence of acid (alleged by some observers) in some cases of well-marked chronic caries he disproves, and considers the absence of acid in any case of caries cannot be established. Wedl fully recognised the part played by inherent structural defects of the tissues, and especially dwells upon the occurrence of cracks or fissures in the enamel in connection with the development and extension of the disease. These flaws are observed very frequently in otherwise healthy sound teeth.

It is interesting to note the accuracy of Wedl's observations and to observe the truth of the drawings with which they are illustrated. Figs. 106 and 107 from his work may be compared with the photo-micrographs on another page (figs. 95 and 96), illustrating similar conditions—inherent structural defects of enamel. Fig. 106 shows granular enamel with numerous minute pits at the surface. Fig. 107 shows a cavity in enamel surrounded by solid tissue and communicating with the surface by a funnel-shaped depression, bordered by normal tissue. These are sections from teeth free from caries. Fig. 106 is $\times 400$, Fig. 107 $\times 250$; and these flaws would be therefore not recognisable by the unaided eye, to which the teeth would appear sound.

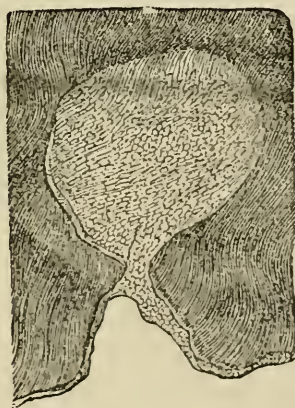
With regard to the minute phenomena occurring in the tissues in caries, Wedl observed in the enamel, as an early change, the presence of pigment of varying shade. The persistence of the contours of the prisms in places

FIG. 106.



—that is, the more rapid solution of their centres than periphery by acid—he could not explain, but thought it possibly due to proliferation of a mass of leptothrix into the decalcified enamel. In the dentine he recog-

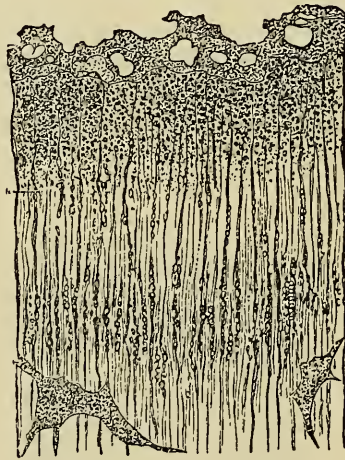FIG. 107.



nised two stages in the progress of the disease, which, however, could not always be nicely discriminated—a preparatory stage of decalcification and softening, and

a stage of direct disintegration. During the latter stage the tubes become enlarged and varicose and filled with leptothrix, which also he believed was to be found in all the ramifications of the carious cavity, although he had not discovered its presence in the earliest stages of the disease. Although Wedl, who also wrote before the science of bacteriology had far advanced, did not positively identify any form of micro-organism except leptothrix in carious dentine, he described the presence of minute bodies within the tubes, which he specifically referred to as highly suggestive of micrococci. It can hardly be doubted that these were really organisms of that kind, the presence of which is now easily demonstrable.

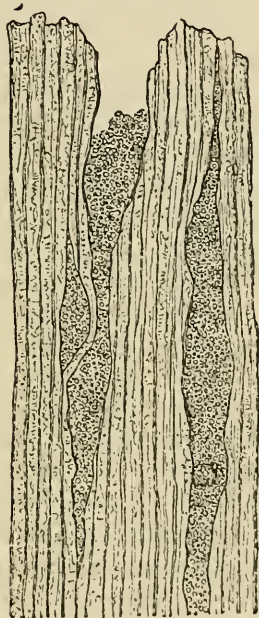FIG. 108.



Wedl pointed out that, although the living pulp does react against external agencies, still the interpretation of writers, according to whom an inflammation of the pulp can manifest itself by pathological effects in the dentine, is incorrect. Pursuing this subject further, Wedl clearly explained that irritation and inflammation of the pulp, when they occur during caries, form a sequel to and are caused by destruction of dentine, and he showed that there are no grounds for ascribing changes

in the dentinal fibrils to irritation of the pulp. The pulp seldom becomes implicated until the dentine has suffered a considerable loss of substance, and, indeed, in most cases is in no way affected until exposed to external irritation.

FIG. 109.



By an elaborate series of observations, completely illustrated by accurate drawings of the histological appearances of the tissues, Wedl conclusively demonstrated that carious dentine of dead human teeth, and of artificial teeth made of ivory, presents the same appearances as are formed in ordinary caries, in respect of pigmentation, granular condition of dentinal fibrils, and thickening and varicose enlargement of the tubes. Figs. 108, 109, may be taken as examples of these illustrations; these are sections of carious dentine $\times 500$ from human incisors reinserted as artificial substitutes on a gold frame. Their accuracy may be gauged by comparison with the photomicrographs on earlier pages. The difficulty of drawing

and reproducing truthfully microscopical sections of this kind is of course extreme.

It is now many years since Sir J. Tomes (21), basing his investigations on the exact knowledge of the dental tissues which his previous researches had largely helped to establish, demonstrated very clearly and laid it down as his belief, "that caries is an effect of external causes, in which so-called 'vital' forces play no part; that it is to a great extent due to the solvent action of acids which have been generated by fermentation going on in the mouth, the buccal mucus probably having no small share in the matter; and when once the disintegrating process is established at some congenitally defective point, the accumulation of food and secretions in the cavity intensify the mischief by furnishing fresh supplies of acid." This opinion still remains unchanged. It has been confirmed and adopted by Mr. Charles Tomes (21), who, however, recognises the share which micro-organisms take in production of fermentation—phenomena of which, for years after Sir J. Tomes first wrote upon caries, were regarded as purely chemical. The presence of globular masses of calcareous salts, which are sometimes found in dentinal tubes near a carious cavity, and which were relied upon by some of the older writers as evidence of vital action, they regard as probably depositions from solution of salts, and they maintain that even if it were conclusively shown that dentinal fibrils become obliterated by calcification, this would not be absolute proof of vital action; for they point out that albumen, even when out of the body, is able to form with calcareous salts combinations having a definite structure. They show that *all* the appearances of ordinary caries may be traced in the tissues of human teeth which have been inserted in the mouth on pivots or plates; and, therefore, inasmuch as no characteristic appearances can be found to distinguish caries occurring in living from that in dead teeth, the hypothesis of vital action in any way modifying the disease must be abandoned *in toto*, and "dental caries cannot, strictly speaking, be said to have any 'pathology.'"

Mr. C. Tomes points to the fact that caries occurs

in the same mouth in teeth with and without living pulps, and he suggests the impossibility of regarding such cases as belonging to two diseases "in their very essence different: that the caries of the living tooth is an internal inflammatory change, and that the caries of the dead tooth is an effect of external chemical and physical causes alone." He remarks that this difficulty has never been fairly faced by any advocates of the "vital" theory.

Messrs. Tomes regard as the main predisposing cause of caries structural imperfections in the tissues; and they recognise that the physical signs visible at the onset of the disease vary mainly in consequence of the disintegration commencing sometimes on an unbroken surface, sometimes on a surface the seat of congenital defect. The other great predisposing cause is vitiation of the secretions of the mouth.

The mucous membrane, when irritated or inflamed, throws out an acid secretion capable of injuring susceptible teeth. They prove by experiment that this secretion is alone enough to give origin to caries. If a small pellet of cotton wool, or other foreign substance, be forced between two teeth, and left so as to press upon the gum, the secretion from the mucous membrane at that point will be found in the course of a few hours increased in quantity and strongly acid; and it will be seen after a short time that the enamel of the adjacent teeth is undergoing slow solution.

Messrs. Tomes point to the fact that, in a superficial cavity subject to friction of mastication and swept by the tongue, decay will be slow, or may even be arrested, if the friction be made more thorough and constant, by the breaking down of the low walls. On the other hand, the mere persistent retention of decomposing products in contiguity with the tissue, is enough to originate and keep up carious action. This they prove by experiment.

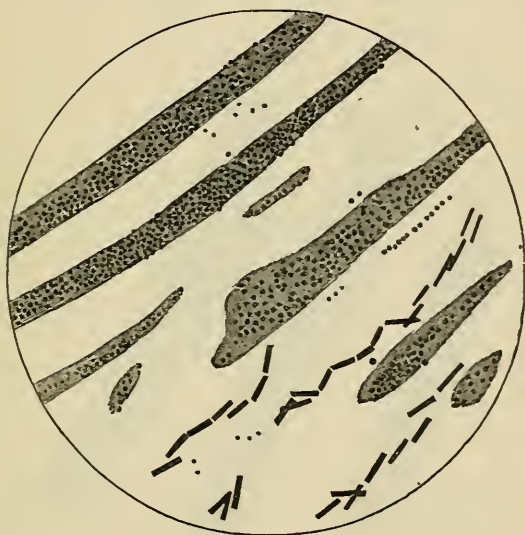With regard to microscopical appearances, Messrs. Tomes compare carious enamel to enamel which has been slowly decalcified, but it is pigmented in a manner that cannot be imitated artificially. The solvents in caries attack the axial portions of the prisms before the

periphery. In the dentine they describe as one of the earliest changes enlargement of the tubes, which become dilated to many times their original dimensions, and the parietes of the enlarged tubes having undergone partial decalcification, the so-called "tobacco-pipe" appearance is produced.

To Messrs. Arthur Underwood and Milles (25), of whose research (commenced some four years earlier) the fruits were presented to the International Medical Congress in 1881, belongs the great credit of having been the first thoroughly to investigate the subject of caries in the light of the then recently-established knowledge of the true nature of the processes of fermentation and putrefaction. They pointed out that although the old "vital" theory—the theory that caries is a real disease, a pathological process due to causes acting from within—had been abundantly disproved, yet the chemical theory—the theory which supposes mere solution of the tissues by acid—could not be considered wholly satisfactory. They proved that destruction of teeth by action of acids, without the aid of septic agents, does not result in producing naked eye appearances or minute tissue changes exactly like those occurring in true caries. Sections of dentine so decalcified show disappearance of the matrix, but not enlargement of the tubules, and there is an absence of pigmentation throughout. They repeated and confirmed the experiment first performed by Magitôt, who, however, at the date of his investigations could not, of course, account for the result—the experiment which proves that it is impossible to produce artificially caries resembling natural caries when septic influences are excluded. They from this assumed that two factors are in operation in caries—the action of acids and the action of germs. Their theory they put forth rather as an amplification of the chemical theory than a contradiction. The work of decalcification, they proved, is entirely performed by acids, but the acids are generated by germs, which, as is now known, are essential to the processes of putrefaction and fermentation. These considerations led the investigators next to seek for the presence of organisms

in carious dentine. They cut a vast number of sections from fresh carious teeth immediately after extraction without use of any softening or decalcifying reagent, and subsequently stained them with an aniline dye—methyl violet. Examination of these preparations under a one-eighth lens disclosed the fact that the tubes were invariably infiltrated with organisms, for the most part micrococci and oval and rod-shaped bacteria. The accompanying diagrams (figs. 110, 111 and 112),* from

FIG. 110.



the *Proceedings of the International Medical Congress*, 1881, may help to show how clearly these observers described the morbid anatomy of caries.

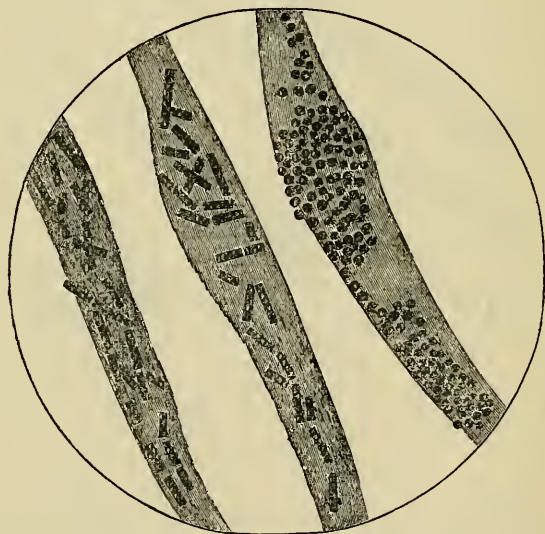
In decay in blocks of hippopotamus ivory worn on a plate, they observed similar appearances. These observers also made a large number of experiments and established important facts. In teeth exposed to the action of weak acid with perfectly aseptic conditions, solution of enamel went on so long as the acid was

* Owing to a mistake of the draughtsman the rods in these diagrams are depicted with square instead of rounded ends.

unexhausted and then ceased. On the other hand, where extracted teeth were exposed to septic influences immersed in organic *débris* such as exists in the mouth, the action of the organisms ("which constitute a living factory of acid") caused gradual decalcification of the whole tooth and destruction of the organic basis of dentine, the microscopical appearances very closely resembling those of natural caries.

Mr. Underwood has shown that the "tobacco-pipe" appearance is not peculiar to caries, but is to be seen whenever a re-agent renders prominent the sheaths of Neumann.

FIG. 111.

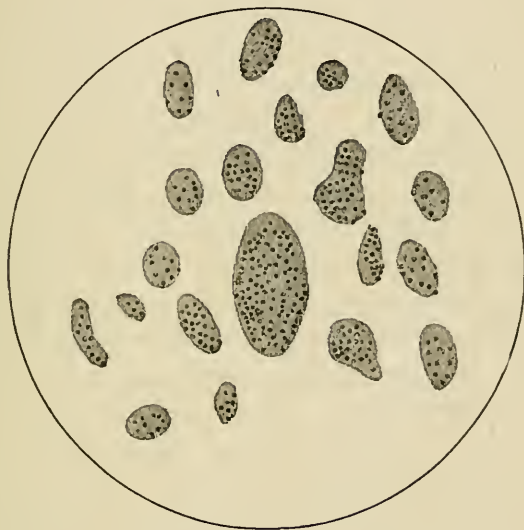

By a simple experiment-cultivation of organisms derived from carious dentine, Mr. Underwood also demonstrated the fact that organisms cause the characteristic pigmentation of caries — several varieties of organisms produce special colours, some black, some brown, some green.

Professor Miller (10), of Berlin, was the first investigator to follow the lines traversed by Messrs. Underwood and Milles. Dr. Miller first traced the derivation of the acid, the prime agent in caries. He demonstrated the

presence in the mouth of an acid-forming ferment of organic origin, and obtained a pure culture of the active organisms. He showed that these organisms, added to a fermentable mixture, gave rise within a few hours to formation of acid capable of decalcifying enamel and dentine.

FIG. 112.



By a series of experiments in production of caries artificially Professor Miller has carried investigation in this direction further than Messrs. Underwood and Milles. Tubes containing sterilised starch solution were attached to teeth within the mouth, access of saliva being allowed, and were left for six or eight hours. At the end of that time the contents of the tubes were found to display strong acid reaction, and this was easily proved to be due to fermentation with the presence of bacteria. By similar methods applied to dead teeth out of the mouth, Dr. Miller has produced artificial caries which cannot be distinguished by the microscope from true caries.

Opposing Theories.—In a recent work* I examined

* "Dental Caries," second edition. 1888.

exhaustively all the theories promulgated in late years which go counter to the views on caries which I have set forth in this book. I quoted the authors extensively, and the quotations alone sufficed to show the worthlessness, as well from a literary as from a scientific standpoint, of most of the writings. There exists altogether a vast mass of literature on the subject, out of which I selected what seemed most worthy of notice, but found that the greater part of it, when not purely fanciful hypothesis, consisted merely of the record of superficial impressions without foundation of demonstrable fact and unsupported by logical reasoning. These writings would be quite unworthy of notice under ordinary circumstances in any book which did not include among its readers inexperienced students. But unfortunately the writings in question have been put prominently forward, and without any indication of their real character, have been cited among recognised authorities in works addressed to students. I have therefore felt constrained to notice here such arguments from these writers as could be put into shape—and I have done so as briefly and generally as possible—so that the intelligent student may gauge their value for himself, and not imagine (as he otherwise might have done) that they had been passed over because unanswerable.*

Theories which have been set forth either in early or recent times, and which would, if proved, show the

* It is hardly necessary the student should trouble himself with fantastic theories such as that propounded and worked out at great length by the late Mr. Bridgman, and recently revived in America. Briefly stated, the hypothesis was to the effect that the dental tissues exist in different electrical conditions, and are liable under some circumstances—in conjunction with the fluids of the mouth—to develop a process of spontaneous electrolysis, resulting in destruction of the teeth through disintegration (caries) of the enamel and dentine !

falsity in part or entirely of the view which I have tried to make clear, may be divided into three categories. First, those that would make out caries to be a true disease, carried on by pathological action initiated within the tissues; second, those admitting the disintegration of enamel and dentine to be due to external agents, but insisting that these agents are powerless without prior occurrence of morbid changes in the tissues, which lessen their power of resistance and predispose them to attack; and thirdly, theories which admit that caries is entirely due to external agents, but maintain that the tissues—or at least dentine—are not passive under the process of disintegration, and assert that the process is accompanied by inflammatory phenomena, or some kind of vital reaction. I am, however, not aware of any modern author bold enough to support the first of these theories in its entirety. This view is confined almost exclusively to obsolete works composed before the anatomy of the teeth had been clearly made out, or their physiology properly understood.

Regarded in the light of modern science, the opinions of the early dental pathologists are not more absurd than those of workers in other departments. It was first necessary, before exact knowledge of disease could be obtained, that complete acquaintance with the structure of the tissues in health should be gained; and this was impossible before the perfection of methods of histological investigation. It was natural for old writers, ignorant of the real structure of enamel and dentine, to look upon these tissues as more highly organised than we now know them to be; to speak of their “vitality,” to suppose that they underwent constant nutritive changes; to identify the phenomena which disease made visible in the tissues with similar effects in more highly organised parts, and to classify these appearances as inflammation, atrophy and gangrene—conditions to which they, perhaps, bore a superficial resemblance.

It would be probably in most cases very unsafe to try to establish on *à priori* grounds alone the truth of an explanation of any series of morbid phenomena. But if the conclusive mass of evidence (set forth in previous pages) derived from observation and experiment did not exist, an argument based on consideration of the anatomy and physiology of enamel and dentine would alone suffice to prove that caries could be due only to external agents, and that the view which I have endeavoured to set forth must be essentially correct.

The student cannot have failed to perceive that enamel and dentine are anatomically quite peculiar, and are not closely comparable to any other human tissues. In their physical and chemical characters they most closely resemble dense bone; but even the densest bone is permeated by a free vascular supply, while these have none. Between them and other avascular structures, such as cartilage and the cornea, there is the vast difference that the latter are largely composed of cells, and are capable of carrying on physiological processes and of undergoing intrinsic degenerative and reparative changes.

Enamel is totally devoid of any elements whereby physiological changes could be brought about in it. A tissue incapable of physiological activity cannot become the seat of true pathological change. Not only is enamel incapable of intrinsic changes, but it is not in relation with any physiological organisation capable of acting upon it from within. To believe in the possibility of physiological activity in enamel, we must first believe that it contains the necessary elements, and next conceive some means by which the calcareous basis could assimilate nutritive material when conveyed to it; and we must then imagine the conveyance of new and effete material to and from the vessels of the pulp by way of the dentinal fibrils to its destination within the substance

of the enamel. To dentine the tissue with which alone enamel has relation similar remarks apply with almost equal force. The great bulk of dentine is composed of a homogeneous calcareous matrix, in which no trace of active cellular or other living structure can be detected. It is a tissue in which the minute fibrils alone can be said to possess any "vitality."

Structures constantly undergoing physiological changes contain tissue elements whose activity is demonstrable. They require for their maintenance in health a proper supply of nutritive material from the blood, as well as provision for removal of effete material. It is from failure or perversion of necessary physiological activity of this kind, and by this means alone, that parts can be brought into a state predisposing them to disease, or actual pathological change can be produced in them. We have only first to think of the anatomy of a tooth as a whole, and of that of enamel and dentine in particular, and more especially to think of the structure of enamel—the starting place of caries—and then to realise the nature of the physiological factors necessary in the production of malnutrition or impaired vitality leading to pathological change—we have only to bring these things vividly before our minds to perceive the absurdity of a belief in the possibility of such morbid processes originating in enamel.

It is beyond all things necessary, before adoption of any theory, that its foundations should be proved absolutely secure; and, as pathology must have its basis on anatomy and physiology, it is evident that no apparent pathological phenomenon irreconcilable with incontrovertible facts of those sciences can be accepted as real.

The account of caries given in this work starts from the established anatomical facts which are set forth in the opening chapters, and it has been recognised by the better class of recent writers, who have brought

forward arguments in opposition, that it would be necessary to overthrow those facts before a new theory could be founded. An attempt to do this has been made. An American observer—referred to in an earlier page—stated some years ago that by staining the tissue with chloride of gold he had demonstrated the presence of active organic matter regularly distributed between the enamel fibres. And this observation has been held by some writers to prove the possibility of physiological and pathological activity in enamel. There are, however, in the first place, grave doubts as to the correctness of the observation. It has neither been accepted nor confirmed by authorities, and from the result of my own researches I have no hesitation in denying its correctness. In this opinion I am confirmed by Mr. T. Charters White, one of the most accomplished dental histologists of the day.

We agree in the opinion, founded upon careful observation, that the amount of protoplasm between enamel fibres is really nil. The amount of organic material in enamel is altogether only from three to six per cent. It is in the vast majority of cases nearer the lesser than the greater amount. If even the whole of this material were “active protoplasm” equally distributed, it must exist in a state of such extreme tenuity that it might well be disregarded as an agent. Mr. White has stained very thin sections of recently extracted teeth with chloride of gold, but while the contents of the dentinal tubuli were coloured, not a trace of stain could be detected between the enamel fibres under the higher microscopical powers.* The difficulties in believing in

* It is possible to tint enamel in thin section with chloride of gold, and a section thus coloured (by Mr. Arthur Underwood) is shown in a reproduction from a photograph on an earlier page. To stain the whole texture uniformly is, however, a different thing from differentiating protoplasm regularly distributed between the prisms.

necessary nutrition of physiological elements in enamel have been already dwelt upon.

Gallippe and Hoppe-Seyler both have made some observations going to show that teeth (enamel and dentine) increase in density as age advances; but these observations are incomplete and fallacious, and it would be unsafe to base conclusions upon them. Since individual teeth of a set in the vast majority of cases vary considerably in structural character, it would be necessary in order to prove alteration in density to cut sections from the same tooth at different periods of its existence. But even this experiment would not be conclusive, for as we have seen, the density of different portions of a tooth may vary very much. The result of the experiment would be determined in accordance with the innate structural characters of the tooth. At one part it might yield enamel and dentine of the densest quality, at another it might yield tissue less dense owing to the presence of defective strata such as have been described on a previous page.

An experiment which every dental surgeon performs in practice daily is without any other evidence almost alone enough to prove that not only enamel but also dentine is too lowly organised to be capable of physiological action. This experiment consists of the common operation of filling or stopping teeth. It cannot be believed that tissues so highly organised as the hypothesis in question supposes would passively tolerate the presence of a foreign body like a mass of gold or other stopping forcibly wedged into their substance.

Relying upon the undoubted clinical fact that caries is very often started or accelerated during morbid states of the system, not accepting as sufficient the effects of the predisposing causes described in previous pages, and disregarding the experimental and clinical facts which negative the hypothesis, some writers argue that caries

must be influenced by causes acting from within. It has been already explained that all the phenomena of caries, including appearances visible to the naked eye and those disclosed by the microscope, are to be observed not only in pulpless teeth and in dead teeth replaced in the mouth as artificial substitutes, but also in blocks of ivory used for the same purpose. And not only is this the fact, but the remote as well as direct causes of decay in these dead substances when worn in the mouth are precisely the same as govern the onset of caries in living teeth—teeth with living pulps and living periosteum. Dead teeth and ivory blocks are under similar conditions neither more nor less liable to decay in the mouth than their neighbours implanted in the alveoli. Some few years ago, before the general use of vulcanite, artificial teeth were much more frequently constructed of gold plates with human teeth mounted upon them, and it was a fact of common observation—one which I was able fully to verify—that the durability of this kind of work varied much in different individuals and under changing circumstances in the same individual. Every dentist recognised that their durability depended very largely upon the quality of the enamel and ivory of teeth and blocks employed; if these were of the most solid structure they lasted much longer than if inherently weak. Their durability depended, secondly, on the health and personal habits of the wearer. In a mouth habitually neglected and where the frames were allowed to remain for long periods coated with decomposing *débris*, the teeth and blocks were speedily softened and destroyed, whilst on the other hand where the mouth and teeth were kept scrupulously clean the beginning of decay was relatively less frequent and its progress in like degree less rapid. A combination of bad health with neglect, giving rise to extreme vitiation of the buccal secretions, was with certainty accompanied

by destruction of the artificial teeth. It was proved, moreover, that when such dead teeth were attacked by caries decay began precisely in those situations where it would be most likely to attack a living organ—namely, in places favourable to the lodgment of decomposing particles, and on surfaces where a solution of continuity allowed access to exposed dentine; and that if cut surfaces were finely polished, so as not to allow the ready adherence of *débris*, these surfaces would, like those of a living tooth under similar circumstances, be much less liable to decay. In short it was amply proved that disturbances of the general health and local conditions exercised the same indirect influence upon ivory blocks as upon living teeth, and the effects were traceable onwards through the same series of events, namely, vitiation of the buccal secretions and putrefaction and fermentation of organic matter attended by development of micro-organisms, and formation of acids in the vicinity and on the surfaces of the teeth.

To all this must be added the fact that no observer has ever produced a specimen of enamel and dentine in which degenerative changes were present. If in some systemic states teeth were to undergo softening or degeneration, owing to abstraction of their solid constituents through the vascular system, the morbid process would surely begin, if not always, at least very often on the surface nearest the vessels—in the dentine forming the walls of the pulp cavity. No such appearances have ever been detected, but on the contrary, where softening or disintegration of a tooth takes place, it is always progressive from the external surface, the situation where agencies exist capable of producing the effects.

Some writers dwell much upon the occurrence of what they style acute caries, associated with general ill-health. A very common example is seen sometimes in patients

subjects of long-standing chlorosis. A set of delicate teeth extensively filled, which have gone on without serious outbreak of decay from late childhood till beyond puberty, in such cases often suddenly show renewed signs of general decay; well-made stoppings fail, and tooth after tooth is attacked by rapid caries. Precisely the same thing is often seen in women with delicate teeth during the child-bearing period. It must be recollected that a cause, however slight, if in action sufficiently long is enough to account for great effects, and ill-made enamel from the moment of a tooth's eruption is exposed to the constant or intermittent action of destructive agents.

These cases of acute caries are fully accounted for by the action of the predisposing causes which have been discussed, and may be safely ascribed firstly to presence of innate structural defects in the tissues; and secondly, to gradual solution of weak enamel by acid. It is easily conceivable that, in the course of months or years, patches of ill-made porous enamel become further weakened by gradual solution and allow readier access of acid-forming products, even into the substance of the tissue. Given such extensive areas of organically weak tissue, allowing infiltration of fluid and undergoing slow solution, and we can understand that a change in health involving vitiation of the secretions of the mouth and encouraging formation of acid, should often be accompanied by rapid breaking down of the previously weakened enamel. Enamel inherently defective often covers dentine of equally bad formation; and the enamel of ill-made teeth once penetrated by caries, the rapid destruction of the soft imperfectly calcified dentine which often follows need excite no astonishment.

All these facts added to others given in previous pages, have not sufficed to prevent acceptance of the theory that caries may be brought on by changes in the

dental tissues arising from within. It may be impossible to prove the falsity of these views. The reader must form his own judgment upon the facts which I have tried to lay fully and impartially before him.

The student conversant with the nature of inflammatory action—with the objective phenomena and the subjective symptoms which are comprised in the term inflammation—can hardly have failed to perceive that the physiological facts just discussed suffice to prove the impossibility of the occurrence of vital reaction of the nature of inflammation in dentine. The following facts may be recapitulated: Caries never commences in proximity to the vessels (on the walls of the pulp chamber), but always at the external surface, the point furthest removed from vascular influence; signs of inflammation, which invariably arise speedily in vessels bordering avascular tissues the seat of inflammation, are absent in caries; there are no tissue elements in dentine except the fibrils, which are capable of interstitial change; caries goes on unaltered and with precisely the same microscopical appearances when the pulp and therefore the fibrils are dead. If inflammatory corpuscles are present in carious dentine they must arrive there by traversing intervening dentine by way of the tubes from the vessels of the pulp—a supposition which is manifestly absurd.

The sole observation which could support the belief in question is the doubtful fact that carious dentine in some cases displays hyperæsthesia.

The errors of the few older although modern observers, who have believed in occurrence of inflammation in caries, arose from misinterpretation of the significance of apparent changes in the tissues. The masses of organisms, for instance, in the dilated tubes of carious dentine readily taking up colour might possibly be mistaken for inflammatory corpuscles by observers writing

at a period before the existence of micro-organisms was suspected in such a situation, and before their real nature had been ascertained.

It is scarcely credible, but nevertheless true, that in face of all facts and considerations an American writer* within late years has elaborately described what he styles inflammation of enamel and inflammation of dentine, and has described the constant presence in carious dentine of "nodulated protoplasmic bodies with nuclei and threads running from one to another," and states that in his judgment "it is this living matter which has been mistaken for organisms."

The publication of a statement of this kind seems hardly compatible with possession of an adequate knowledge of microscopical and bacteriological science, for not only are the tubes in caries filled with organisms and only with organisms, the forms of which are perfectly familiar to all competent observers, but each and all of them (except leptothrix, which will not grow transplanted from its peculiar habitat) can be separated, isolated and cultivated out of the mouth by the method now commonly practised by bacteriologists. By the performance of this simple yet crucial experiment this writer might have convinced himself of the falsity of his observation.

Relative Frequency of Caries in different Classes of Teeth.—It is a remarkable fact, and one that has some practical application (as was seen in the chapter on Irregularities), that the teeth are not all equally liable to be affected by caries. Series of cases have been tabulated from time to time by various observers, and these agree in the main with each other.

* This author must be taken as a fair sample of the class of writers just alluded to, and his statement as a specimen of the kind of fact upon which theories have been based, and then set out before students with a show of authority.

The following statistics of 10,000 cases collected by Magitôt show the relative frequency of caries in the different kinds of permanent teeth.

Central incisors	642	{ Superior	612
		{ Inferior	30
Lateral incisors	777	{ Superior	747
		{ Inferior	30
Canines	515	{ Superior	445
		{ Inferior	70
First bicuspid	1310	{ Superior	940
		{ Inferior	370
Second bicuspid	1310	{ Superior	810
		{ Inferior	500
First molars	3350	{ Superior	1540
		{ Inferior	1810
Second molars	1736	{ Superior	690
		{ Inferior	1046
Third molars	360	{ Superior	220
		{ Inferior	140
<hr/>		<hr/>	
10,000		10,000	

The first point which attracts attention in these tables is the great relative frequency of caries in the first molars; the next the much greater frequency of the disease in the front teeth of the upper than in those of the lower jaw. The latter circumstance may perhaps be partly accounted for by the fact that the lower front teeth are protected from the action of acid by the saliva with which, owing to their position, they are constantly bathed. It must, however, be admitted that no entirely satisfactory explanation of the ratio of frequency in the several classes of teeth has yet been afforded. The localisation and the incidence of caries are certainly determined mainly by the presence of inherent flaws in the enamel of the teeth attacked; but we cannot yet account for the fact that certain classes of teeth are more than others the seat of these defects.

Diagnosis.—The Diagnosis of Caries is usually simple. In a considerable proportion of cases patients are aware at an early stage of the disease that a tooth is affected, and more especially where food is apt to lodge in the cavity during mastication, or when decay begins on a part exposed to exploration by the tongue, which quickly perceives a roughened surface. But as many cavities are hidden, either under the free edge of the gum or in interstitial situations; as caries of enamel is unattended with pain, and as neither exposed dentine nor exposed pulp is invariably accompanied by pain, it is impossible to be sure that caries is not active in a mouth without careful examination of the teeth. For this purpose a mouth mirror and dental searching probes are needed. The probes are thin and needle-pointed, and bent in curves to pass round the contours of the teeth. In examining a mouth for caries each tooth should be separately explored: its fully exposed surfaces, the neck under the free edge of the gum, and the mesial and distal aspects. In these latter places the greatest care is often required: the fingers are apt to be deceived; small cavities are easily overlooked, or on the other hand a deposit of tartar or some other accidental roughness of outline, particularly along the neck of the tooth, may give a false impression of the existence of caries. In some few cases, to facilitate examination of surfaces in very close apposition, it is a good plan to press teeth apart by one or other of the methods described in a later chapter. The electric light in the form of a miniature incandescent lamp held within the mouth, which is now so commonly employed in dentistry is occasionally a useful aid in diagnosis. It renders the teeth semi-transparent and discloses discoloured surfaces in hidden situations.

Some appearances on the surface of the teeth and conditions of enamel which simulate caries occasionally present themselves; it is important they should not

be mistaken for decay. Patches of enamel of a yellow colour or of a white or opalescent hue differing from the shade of the rest of the tooth are not infrequently met with as innate structural markings on perfectly sound tissue free from other blemish. These marks are to be distinguished by their hardness and polish and by the absence of other signs of caries. When on front teeth, the existence of these markings is often well known to patients, who are aware the spots have remained unchanged since the eruption of the teeth. Thin layers of hard black or brown tartar often simulate incipient caries; careful examination will of course show the real nature of the case.

Discoloured pits and fissures not the seat of decay may be mistaken for carious cavities. In teeth of the most delicate structure, and in mouths where caries begins early in life and attacks many of the set, it becomes a question sometimes, especially when the patient is not kept under frequent observation, whether it may not be better to anticipate the onset of decay, and prepare and fill all fissures, whether carious or not, which give a lodgment to decomposing *débris*. Such a procedure would be quite unjustifiable in dealing with a set of strong teeth little affected by caries.

The depths of the sulci between the cusps of molars and bicuspidis are in a large proportion of teeth, the enamel of which is of first-rate quality, more or less stained and often have the appearance of decay. By careful exploration with a sharp-pointed probe it may be ascertained whether softening exists. Such discoloured lines often endure through life free from decay—sometimes they become gradually obliterated as the surface is worn by mastication. Every now and again, in one or another tooth, a fissure or a pit with smooth rounded walls will be found which is evidently merely a depression in the contour of the tooth, being covered with

dense polished enamel, although very often discoloured by deposit of tartar. Pits in "honeycombed" teeth are often of this character, and do not then call for immediate treatment.

PREVENTION OF CARIES.

THE remote or predisposing causes of caries, fully described in previous pages, are (1) innate structural weakness and defects in enamel; (2) vitiation of the buccal secretions; (3) crowding and irregularity of the teeth. The immediate cause of caries is the lodgment of acid, or of acid-forming *débris*, on the surface of the teeth or within defective spots—pits and fissures—inherent in the enamel. The prophylaxis of caries must be based on prevention of these causes.

The origination of ill-made dental tissue is a large subject, which cannot be more than touched upon in this work. There is gradual decrease in size of the jaws and teeth through savage and primitive races to those of the highest civilised type, and there seems good reason to believe, although it has not been demonstrated, that the teeth are of relatively inferior structure; but in this respect the dental development of the different civilised peoples seems to vary considerably.*

Ill-made dental tissues are often hereditary, and structural characteristics may often follow those of one parent only. Nothing is more common than to find, in members of the same family, teeth of one general type and quality, or teeth presenting in exactly the same situations flaws or patches of inferior formation. The

* Professor Flower, after examination and measurement of many thousands of skulls, has constructed a dental index, and in this the average size of the teeth of the gorilla being represented by 50·8, the Tasmanian by 47·5, and other savage races holding intermediate positions, the European stands at 40·5.

effects upon the teeth of hereditary syphilis and also of stomatitis occurring during the progress of enamel calcification have been discussed in an earlier chapter ; and although the typical teeth of Hutchinson—the significance of which is unquestionable—are present in only a small proportion of undoubtedly syphilitic children, their occasional occurrence clearly shows the power of hereditary disease to influence the development of enamel and dentine.

An intimate connection between dental mal-development and any other diathesis, besides the syphilitic, cannot be fully demonstrated, yet there are some of these constitutional conditions with which badly made teeth seem more or less associated. In this matter I am recording the results of my own observation alone. My experience goes to show that imperfect dental tissues are found in the majority of cases of scrofula. Phthisis is now known by no means to indicate invariably the tuberculous diathesis, and keeping distinctions in view, I would say that ill-made teeth are not at all a constant accompaniment of any form of phthisis, nor are they especially noticeable in a majority of patients of undoubted tubercular tendency. With rickets I have generally found inherently defective teeth. I can in no way associate faulty tooth development either with the rheumatic or gouty constitution. Indeed, with the latter both teeth and jaws are often of unusually massive and solid character.

In view of our limited knowledge of the causation of degeneracy of enamel and dentine, what general measures can be suggested likely to lead to improvement in the quality of the tissues, and to aid in the prevention of dental caries? Such a general question can be answered only in general form. Whatever tends to improve the physical development of a race should cause a relative improvement in the structural qualities of the teeth.

It may next be asked can we, by treatment, influence beneficially the developing teeth of the fœtus in utero, through a mother? The answer must be that little reliance can be placed upon treatment specifically directed to this end, and we must depend mainly upon measures for the amelioration of the mother's general health, and the eradication of any definite morbid constitutional taint. The treatment of these conditions is quite beyond the province of the dentist, although it is the duty of the dental physiologist and pathologist to explain the laws which should govern treatment directed to the developing teeth. To show that defective teeth might occasionally result from deficient supply of the necessary pabulum through the mother, several cogent facts have been brought forward. It has been pointed out that in a pregnant woman the union of a fracture is slow, the inference being that the lime salts are all required for the formation of the bones of the fœtus; and this is borne out by the fact that osteophytes and bony thickenings sometimes present in the early months of gestation become absorbed as pregnancy advances and bone begins to form in the fœtus. In presence of these facts a rule may be established that in every case of dyscrasia or cachexia during pregnancy, and particularly where there is a tendency to atrophy and bony wasting, there should be administered mineral nutrition, both through the medium of a suitable dietary and of the preparations of lime salts to be found in the pharmacopœia.

In previous pages the reasons have been given for the opinion that enamel once fully calcified is physiologically unalterable, and if this opinion is correct it follows that after the formation of enamel any attempt to prevent caries by improving the quality of that tissue must be futile. The exteriors of the crowns of all the temporary teeth—from caries of which children suffer so

much—are fully formed at birth; these teeth can therefore be influenced only through the mother. By this time the first permanent molars and the permanent incisors and canines are so far advanced in development that it is open to doubt whether treatment can have any effect upon the enamel.

It is difficult to believe that any treatment could influence cases in which a strong hereditary influence proceeding from the father gives a bias to dental development. A mother with good dental tissues will often bear children with defective teeth having the closest resemblance in form and structure to those of the father, who may be perfectly healthy, and in whom this may be the sole physical defect.

When the child is born, syphilis and specific diseases will receive their appropriate treatment, whilst the well-known rules of hygiene are enforced for the improvement of the general health. We are ignorant of the actual causation of defective enamel. It cannot be always due to lack of lime salts, or the whole skeleton would in every case be equally defective with the teeth. But as uncertainty exists, it may be better to err on the right side—especially as the error would be harmless—and enforce the rule that in every case in which ill-made tooth tissues are likely to appear an attempt by diet and therapeutics should be made to supply to the developing tissues the mineral constituents of which they may stand in need. This rule should, of course, especially be enforced in those diseases, such as rickets, in which the whole skeleton is ill-constructed. There is no difficulty in administering lime to an infant from birth. A child should have no food except its mother's milk, if this is of proper quality, up to at least the ninth month. Practically in the majority of cases this source is supplemented by cow's milk; which, of course, with well-managed children, is diluted and prepared in the

usual way to resemble human milk. It happens that lime water (*liquor calcis*) is found to be an admirable aid to the digestion of milk in infancy, and this can either be added to the supplementary food, or can be given separately.

It is impossible, particularly when both causes are present, to determine in any case the exact share which inherently weak enamel and vitiation of the secretions severally take in causation of caries, and when discussing the association of ill-made dental tissues with certain diatheses, it must therefore not be forgotten that some of these diatheses have as a common constant accompaniment vitiation of the secretions of the mouth. Thus one type of scrofulous subject—that with coarse features, muddy complexion, and long thick upper lip—has usually a chronic condition of congested buccal mucous membrane with secretion of viscid mucus. Again, rickets is often preceded and attended by a virulent form of acid dyspepsia.

In this way the prevalence of caries is to be accounted for among certain individuals or portions of the community whose physique and general health in other respects are not to a corresponding degree inferior, and whose dental tissues are not evidently of the worst structure. For example, the constant presence of dyspeptic troubles in some classes of factory operatives is enough to account for the rapid tooth decay from which they suffer. Dyspepsia due to sedentary habits and improper dietary—superabundance of coarse food and alcohol—is so common in some of these communities that it is regarded as a matter of course, and endured as one of those evils from which there is no escape.

The broad facts must be kept in view, that without acid, without a septic condition of the secretions of the mouth, caries is impossible; and that acid capable of dissolving enamel—and of more rapidly dissolving

enamel in proportion as the tissue is soft and ill-made—is always being formed in greater or less quantity in every mouth in which perfect cleanliness does not uniformly exist.

In combating this cause of caries, the patient's general health must first be considered. Probably every lapse from a perfect standard will be accompanied by a proportionate vitiation of the secretions of the mouth. The question of general health, is, however, for the physician, not the dentist. But even with perfect health and perfect dental tissues, caries may appear if organic *débris* be allowed to remain and decompose in contact with the teeth. The first thing, therefore, in the prevention of caries is to ensure mechanical cleanliness by the use of tooth-brush and tooth-pick. A tooth-pick properly employed is important. The use of those of quill or wood only should be allowed; metal may scratch and break the enamel. They should be used at night to clear away remains of food from between the teeth, before they receive their final brushing. Where the teeth are crowded and are of delicate structure, the use of fine silk thread passed between the teeth and rubbed to and fro supersedes the tooth-pick.

A simple inexpensive tooth powder calculated to do all that such a preparation can do to remove *débris* of food and to neutralise acid secretions may be composed of soap powder and precipitated chalk—about a drachm of soap to the ounce. To this may be added a few drops of carbolic acid or oil of cloves and of oil of eucalyptus. Care should be taken that the soap powder is fresh and of good quality, or a disagreeable flavour may be produced. A more pleasant and efficacious mixture would be represented by the following—powdered Castile soap one to three drachms, boric acid two drachms, powdered orris root one drachm, precipitated chalk one ounce. With fastidious patients it is well to add perfumes

which they prefer. Attar of roses, and oils of lavender, cloves, geranium and eucalyptus afford a choice, and with one or several of these it is possible to impart a delicate perfume to the powder and make it highly agreeable—an important matter with preparations intended for habitual use in the mouth. A dentifrice ought of course to be thoroughly triturated and reduced to impalpable powder.

In fevers and other diseases in which the patient is either too feeble or too listless to clean his teeth for himself, this should be done by an attendant. In such cases, and in all those where great vitiation of the secretions is present, as in the zymotic fevers and the dyscrasia of pregnancy, extra means should be adopted to prevent putrefaction and fermentation in the deposits which form upon the teeth. Thorough cleansing of the teeth in this way will often suffice to prevent toothache, which in certain conditions—particularly during pregnancy—is sometimes clearly due to irritation of carious cavities by the products of decomposition. Perchloride of mercury is by far the most potent drug for this purpose, and may be used in a few exceptionally severe cases. A solution of a strength of 1 in 5,000 is antiseptically equivalent to a 2 per cent. carbolic acid solution, which latter, although not more powerful than needed to prevent fermentation, is too strong to be used as a mouth-wash. A not unpleasant mixture of perchloride can be made if one grain be dissolved in one ounce of eau-de-Cologne or tincture of lemons. Of this a tea-spoonful is to be mixed with a wineglassful of water, and the mouth after thorough brushing of the teeth to be rinsed with it several times a day. The mixture approximates a strength of 1 in 5,000. Some patients complain of a lasting disagreeable metallic taste following use of the perchloride wash. To overcome this, and also to guard against the swallowing of even a minute quantity of

this very poisonous drug, the mouth may be well rinsed with warm water, or warm water to which has been added a little spirit of wine or eau-de-Cologne. Mouth-washes may be prepared with any of the antiseptics in common use—carbolic acid, chloride of zinc, or permanganate of potash. Pleasant and efficacious lotions may be composed of boric acid and tincture of myrrh, with lavender water and eau-de-Cologne, or tincture of lemons; and all lotions are much more likely to fulfil the desired end when used with a tooth-brush, friction being necessary to cleanse the teeth from shreds of food and adherent mucus. For this reason a powder, when it can be used, is to be preferred to a lotion, and in every case the importance of systematic sweeping and cleansing of the teeth and interstices by means of a thin flexible wooden or quill toothpick cannot be too strongly insisted upon.

The third main predisposing cause of caries—crowding and irregularity of the teeth—has been discussed in previous chapters. The measures which may be taken in prevention and cure of these conditions have been described; and the danger of setting up decay by prolonged or careless use of regulating instruments having been sufficiently dwelt upon, calls for no further reference here.

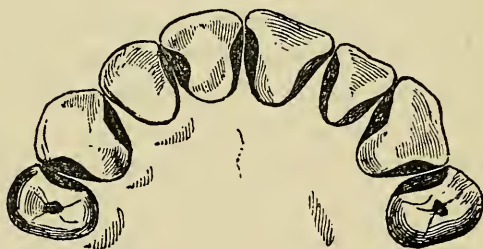TREATMENT OF CARIES.

The treatment of incipient caries may be confined in some instances to cutting away the diseased tissues, polishing the surface, and leaving it of such a form that it may be readily cleansed, and may not allow the adhesion of decomposing particles of food. This procedure is in imitation of the process of spontaneous arrest sometimes effected fortuitously during the progress of the disease which was described on an earlier page.

The treatment of caries by the simple operation of excision is applicable only in rare cases to the grinding surfaces of the teeth, but is commonly resorted to with success in dealing with decay of contiguous surfaces, especially those of the incisors and canines. The operation is performed under the most favourable circumstances when the enamel alone is affected, but it may be occasionally carried out with permanent advantage even when the dentine has been penetrated to some slight depth. As a rule it should not be undertaken in mouths where chronic inflammation and sponginess of the gums prevail; neither should it be proposed in any case when the carious surface extends below the gum. At the level of the gum it is desirable in most cases that a portion of sound tissue should remain projecting from each tooth, so as to prevent the cut surfaces from again gradually falling into close apposition, which they are apt to do in crowded jaws. The rest of the surfaces should be left perfectly

plane, and with such an inclination towards each other that the space between teeth is V-shaped, the wider part so directed as to be easily accessible to the tooth-brush and to the tongue, and subject to the constant beneficial friction of mastication. In forming surfaces in this manner it is sometimes necessary to cut away a considerable quantity of sound tissue. The amount which may be safely removed varies with the size of the tooth, but it must be borne in mind throughout, that if too much be removed the tooth may be left unbearably sensitive, owing to near exposure of the pulp. In the case of incisors and canines the excision of tissue may be confined always to a great extent, and sometimes entirely, to lingual surfaces, the teeth being thus preserved from perceptible disfigurement. The instruments required in the operation consist of enamel chisels and files; with the chisels—when applied in the direction of the enamel

FIG. 113.



fibres—the decayed tissue may be rapidly and painlessly broken down; with files of different degrees of coarseness the operation may be continued, and the surface made ready for the final polishing. This latter process is accomplished by rubbing the surfaces first with finely powdered pumice, carried on wet tape or on a strip of cane, to remove the file-marks, and afterwards with a strip of wet slate-stone, to make it perfectly smooth. The whole process of cutting and polishing is

of course much more perfectly and easily performed with the dental engine and the wheels, burs, and discs with which it is provided. Fig. 113 (from Arthur) indicates the most favourable form in which the interstices of the teeth can be left after this treatment. The sensibility of exposed dentine, varying in amount in different cases, which often remains for a time after the operation, may be rapidly diminished by application of zinc chloride, and the use of a lotion containing spirit.

One or two thorough applications of zinc chloride usually suffice to permanently deaden the surface. A small portion of solid chloride in powder, carried on a strip of wood or cane, may be rubbed over the moistened surface. A spirit lotion—rectified spirit or eau-de-Cologne answer well—may be used to moisten a length of tape with which the surfaces may get a daily rubbing.

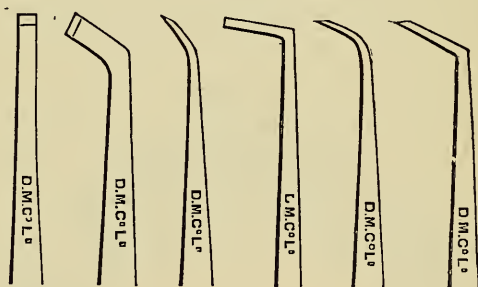
The operation of stopping or filling.*—When, owing to its extent or to other circumstances, caries cannot be dealt with by the method just described, it must be treated by the operation of stopping or filling the tooth. This operation comprises cutting out the diseased tissues and forming the cavity for retention of a filling, drying the cavity, and filling it with some suitable material. It also includes pressing teeth apart in

* The operation of stopping or filling teeth which forms a special complex branch of surgical handicraft, cannot be entirely learnt from books. Books can only supply instruction in general principles, with explanation of methods and description of means of operating. Book knowledge must be supplemented by tuition at the chair side, such as is provided at dental schools. Upon this part of his education the student enters prepared by previous training in mechanical dentistry; and by this time—unless he is devoid of natural aptitude and has mistaken his vocation—his fingers will be so trained that the simpler operations of dentistry, when understood, may appear easy to him, and he will be prepared to profitably commence a course of operations on extracted teeth as recommended in the Preface to the First Edition.

order to gain access to cavities in interstitial positions. The operation of filling is conducted always on the same principles, but its details vary considerably according to the position, character, and extent of decay. The present chapter will be restricted to the treatment of cases in which the central chamber of the tooth has not yet been laid open by caries, and in which the dental pulp is free from disease.*

The operation of filling, throughout all its details, is much facilitated by the use of a dentist's chair, which allows the patient to be firmly and comfortably placed in the most suitable position, raised when a tooth of the upper jaw, and lowered when a tooth of the under jaw, is to be filled, with the head tilted forwards or

FIG. 114.



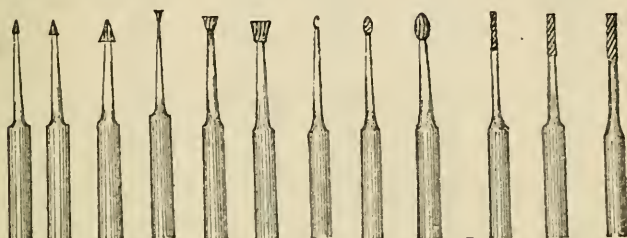
backwards, the face turned towards or from the operator, according to the position of the tooth and of the cavity of decay.

The instruments used in excising carious tissues consist of enamel—chisels, drills, and excavators. The chisels are sufficiently described by their name, both as

* To facilitate description more or less arbitrary division of the subject is necessary; but no student will attempt operations without thorough knowledge of the pathology, symptoms and diagnosis of the inflammatory sequels of caries.

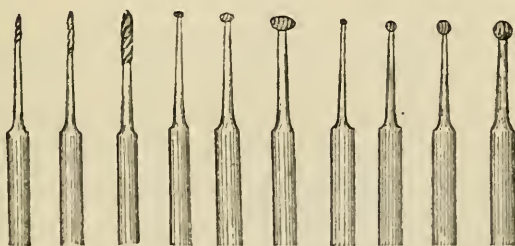
regards their nature and use. They are made with blades of different sizes, bent at various angles, so as to reach the decay wherever situated. A set sufficient for ordinary use is shown in fig. 114. With them the

FIG. 115.



carious enamel of the walls of cavities can be speedily broken down with but little pain to the patient. The chisel should be held firmly with the handle in the palm of the hand, the thumb being lodged securely against the tooth to control the instrument and to prevent it from slipping. It should be applied in the direction in which the enamel fibres run.

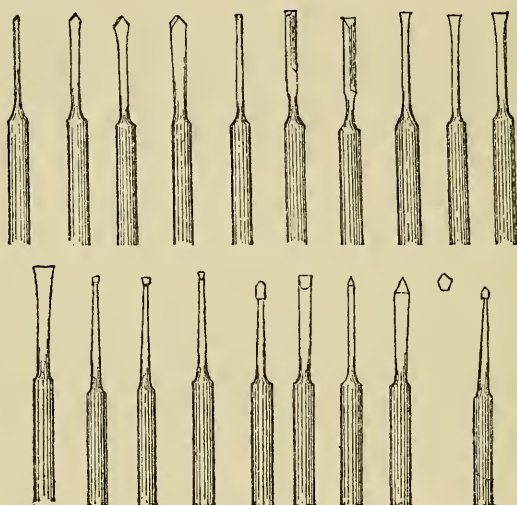
FIG. 116.



Dental drills are mostly of two kinds, the rose or bur-head, and the sharp-bladed drill. The cutting point of the rose-head forms a circular or conical file. It is used to open up the ragged orifices of cavities and to grind away the carious tissues within. Sharp drills

serve to open up small cavities and fissures in the enamel, to shape the cavity, and to cut retaining points into which the filling is to be dovetailed. The general character of these drills is sufficiently exemplified in the selection depicted in figs. 115, 116 and 117. These drills and many other useful varieties of cutting, filing and

FIG. 117.

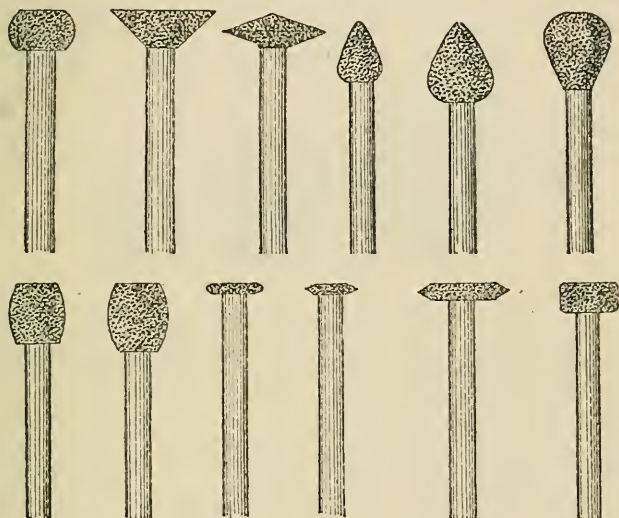


polishing instruments, are now usually employed in conjunction with the dental engine. This machine consists of a flexible shaft rotated by a band, which is driven by a treadle and fly-wheel. The extremity of the shaft which carries burs, grinding-wheels, drills and discs and cones of any desirable size and shape, revolves with great rapidity, and enables the operator to excise tissue with great facility, and speedily to reduce to smoothness the ragged or rough margins; and afterwards to polish all surfaces with exquisite nicety.

Wheels, discs and cones are illustrated in figs. 118, 119, 120, 121. All these shapes and patterns, and many others, are made in a variety of materials. For grinding

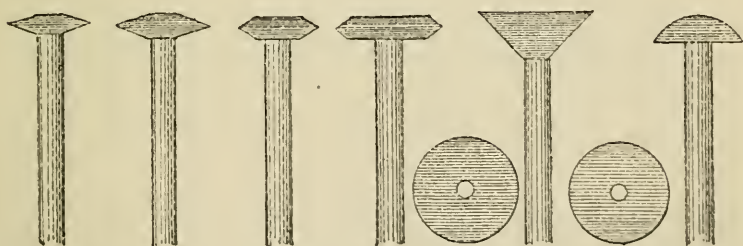
they are made of corundum of different degrees of coarseness; some having rapid cutting power, others, of finer texture fitted to reduce rough surfaces to smoothness

FIG. 118.



preparatory to polishing. For polishing purposes they are made of wood and of vulcanised india-rubber, and are used with levigated pumice, and with chalk or whitening.

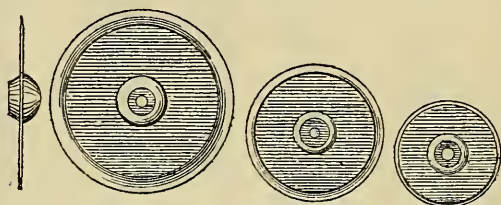
FIG. 119.



Others made of Arkansas stone produce a surface ready for burnishing. Again mandrils are provided which carry small discs of emery and sand paper admirably adapted for polishing some surfaces, especially in narrow inter-spaces.

Excavators serve to pare away dentine. They are made of all sizes, some with flat blades, some hoe-shaped, some spoon-shaped, and others sharp-pointed, and they are curved and bent at various angles to reach the differ-

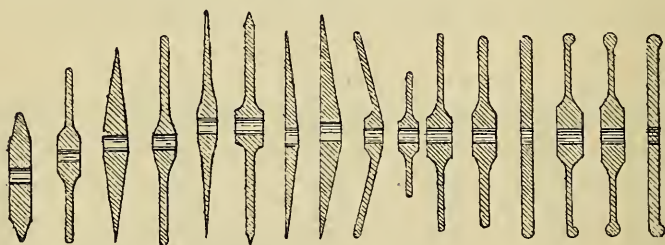
FIG. 120.



ently situated cavities, and some to cut with a pushing, others with a drawing movement. Useful forms of excavators are shown in fig. 122.

With regard to the performance of the preliminary step in the operation of filling, at present under dis-

FIG. 121.



cussion, it may be laid down in the first place as a rule, subject to important exceptions to be mentioned further on, that the whole of the carious tissues should be removed. If the orifice at least of the cavity be not formed of sound tissue, decay will proceed unchecked after the insertion of the filling. The beginner is most liable to err, by too limited use of the chisel and excava-

tor at the orifice, too free use in the depths of a cavity. It will be perceived at once that carious cavities are in form rarely either regular or symmetrical. Most often they assume an irregular star-shape, with numerous horizontal branches or carious channels running in different directions from the main cavity. If only one such shaft communicating with the exterior or covered with a thin shell of enamel be left, the durability of a stopping must of course be much curtailed. The danger

FIG. 122.



of overlooking and leaving unsound enamel is greatest at the margin of the free edge of the gum, and more especially in cavities on the mesial or distal surfaces. In these positions, although the difficulty of examining the seat of decay is great, the operator must satisfy himself that no unsound enamel remains. It is between the teeth and beneath the free edge of the gum that decay after filling is most apt to recur, for it is there that in spite of a patient's care particles tend most to lodge and decompose; and there that incipient caries if present is certain to progress. The more the tissue towards the neck of a tooth is excised the more difficult it becomes to form a solid foundation for a stopping, hence the young operator may be tempted to leave enamel about the condition of which he may feel doubtful.

To cut away solid tissue without sufficient reason is unjustifiable; but to carry the excavation as far as the margin of the cement is better than to leave exposed a layer of partly decalcified enamel, certain to speedily break down.

It very often happens that dentine beneath disorganised tissue appears stained to a brown or darker shade, whilst showing neither appreciable softening nor other physical change. It is seldom necessary to cut away tissue in this state; but whilst it must not be forgotten that the nearer the pulp is approached by a filling the greater becomes the risk of loss of a tooth, it must be also borne in mind that very nice discrimination is needed in leaving carious dentine in close proximity to the pulp. A pulp covered only by a layer of disorganised tissue must be looked upon as virtually exposed; being accessible to micro-organisms and septic matter. In cases where there is a history of inflammation of the pulp characterised by occasional attacks of throbbing pain, diagnosis is easy; but this symptom is often absent. Before inserting a permanent filling the operator must strive to satisfy himself not only by negative evidence—absence of symptoms of pulp irritation and inflammation—but also by careful exploration that the pulp is in no sense exposed, and that it is covered by a layer of dentine in which caries is not and has not been active.

In cases in which the pulp cavity is closely approached by decay and when the pulp is believed to be free from disease the greatest care must be exercised to avoid laying open the chamber, for if this accident happen the chances of saving the tooth are much diminished. When danger of the accident exists, the softened dentine from the depths of the cavity must be slowly and cautiously removed, and for this purpose excavators with spoon-shaped blades should be used, to avoid the danger

of a sharp point plunging through the softened tissues, and through a thin layer of sound dentine into the pulp chamber. If it be found that excision of all the affected dentine cannot be accomplished without risk, a general rule may be laid down subject to the cautions and reservations dwelt upon in previous paragraphs, that it is better to leave a layer of partly decayed tissue in the depths of the cavity. Carious dentine in the earliest stages of decay may be always left with safety in the deeper parts of cavities, for it can be brought into such a condition, and placed under such circumstances, as will prevent it from decaying further. Caries cannot go on without the influence of external agents, and all that is wanted in the case in question is to harden the partly decalcified dentine by abstracting completely its moisture, to render it perfectly aseptic, and to protect it by a filling from the action of external agents. Partially disorganised dentine may be treated by filling the cavity with a plug of cotton wool, saturated with a solution of gutta-percha and tannin in chloroform, or gum mastic in spirits of wine, with a dressing beneath, and the whole being renewed at intervals of a few days over as long a period as necessary. The dressing may be composed of absorbent cotton with absolute alcohol and iodol taken up on the moistened pellet. In many cases the drying of the tissue by means of a hot-air syringe, aided by application of alcohol, will suffice. This process is described on a later page.

There are no grounds upon which the deliberate exposure of a healthy pulp during the process of excavation can be justified. It is probable that a healthy pulp, exposed to the atmosphere alone, and no other irritation, will certainly pass into a condition of disease if not kept aseptic by art. This always happens in the case of a joint or other analogous structure wounded in a like

manner. The condition of an exposed pulp may be fairly compared to that of the tissues exposed in such a wound or in a compound fracture. The difficulties of rendering an exposed wounded pulp aseptic, and of keeping it in that condition during and after filling operations are very great. These are spoken of under the heading of treatment of exposed pulp. On the other hand the existence of a layer of slightly affected tissue treated as described, and enclosed beneath a filling in the depths of a cavity, can be productive of no harm. If the tissue be cut away it must be afterwards replaced by an artificial substitute. The application of this is difficult, it often sets up irritation, and even when of the most perfect construction it must be necessarily less adapted to its purpose than a layer of imperfect dentine.

In previous pages the sensibility of dentine in health and disease was described, and the fact was mentioned that the sensibility (which depends on the existence of a living pulp) varies very much in different individuals. Excision of carious tissue is thus always a more or less painful operation. In most cases, however, it will be found that it inflicts no more than an easily bearable amount of pain, when it is done rapidly with instruments thoroughly sharp. The suffering may be lessened in the few cases in which there appears hyperæsthesia or in which the patient cannot endure the pain, by applications which diminish the sensibility of dentine. Amongst applications in common use may be mentioned chloride of zinc and arsenious acid. But these substances, especially the latter, must be used always with extreme caution even in superficial caries, and being very apt to penetrate to the pulp and excite inflammation, they are entirely forbidden when the pulp is nearly approached by decay. Sensibility of dentine may be most safely and effectually lessened during excision by the use of ab-

solute alcohol and the hot air syringe, as described in the section on drying the cavity. Excavation will then be best done with the saliva entirely excluded throughout the operation, although a very considerable effect may be produced by drying the cavity and applying alcohol at intervals. Some operators prefer to exclude saliva throughout the operation of excising decay; and this plan answers well with sensitive dentine which needs obtunding.

In excavating the tissues preparatory to the insertion of filling it is not only necessary to remove decay, it is necessary often to cut away a considerable amount of sound tissue to render access to the cavity sufficiently easy, and it is mostly necessary to modify the form of the cavity to adapt it for the retention of a stopping. It will be presently seen that with one exception no class of materials used in filling teeth adhere as cements to the walls of a cavity—they are all retained by either plugging, wedging, or dovetailing. The simplest kinds of cavities are such as after removal of the decay assume the form of a hole or trench with vertical walls; and those which require most modification are such as have a narrow irregular orifice, and those which either wholly or partly take the form of a shallow saucer-shaped excavation. To pack a filling beneath the overhanging margins of a cavity being often impossible, these portions must be, when necessary, freely cut away, whilst, as it is also impossible to fix a plug upon a shallow concave depression, the walls of such a cavity must be rendered either vertical or slightly undercut, or retaining points must be formed. Retaining points are made by drilling small pits in different parts of the cavity. Into these pits portions of filling are packed, and to these portions more and more being securely joined, the whole mass is fixed immovably in position. The number, size, and depth of retaining points must be regulated according to the

circumstances of the case. They need never be very deep, and of course due care must be taken in using drills to avoid laying open the pulp cavity.

The annexed diagrams may serve to make this sub-

FIG. 123.

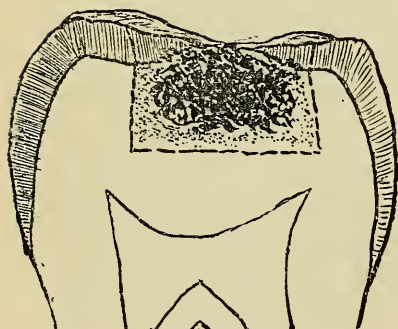
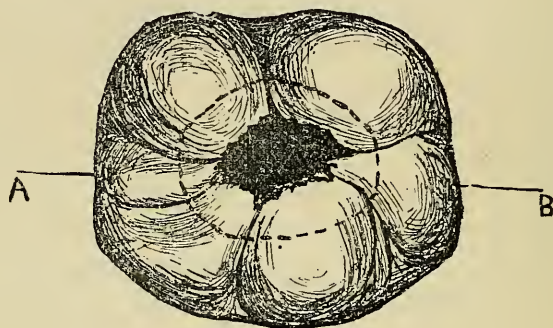


FIG. 124.

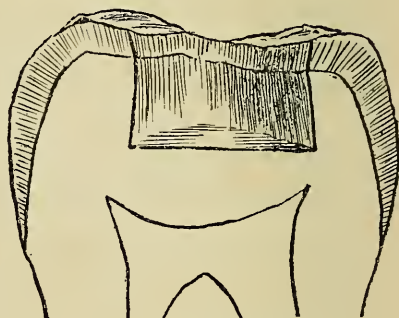

FIG. 125.

ject more clearly understood. Fig. 123 exhibits the aspect of the commonest form of simple cavity in the grinding surface of a molar. In such a cavity the overhanging enamel would require cutting back to the extent shown by the dotted lines. A section of same tooth (fig. 124) through line A—B (fig. 123) shows about the extent to which decay in such a case usually extends beneath the enamel. Fig. 125 shows section of same tooth, and

illustrates the preparation of a typical cavity for filling with cohesive gold. The walls are slightly divergent towards the floor of the cavity, sufficiently to give a wedge shape to the filling. On the other hand the enamel walls are bevelled back at the orifice sufficiently

FIG. 126.

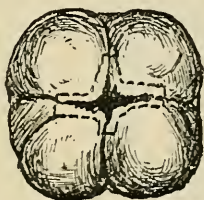
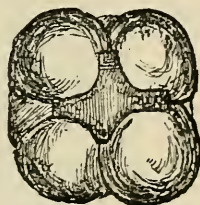
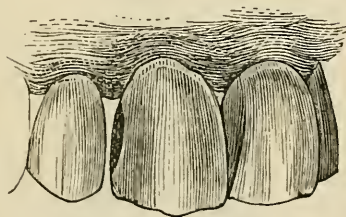


FIG. 127.



to avoid leaving a sharp edge against which it would be difficult to pack cohesive gold without chipping the enamel. If the cavity were intended for stopping with non-cohesive gold or any other filling, particularly amalgam, the edges should not be bevelled back, but should

FIG. 128.



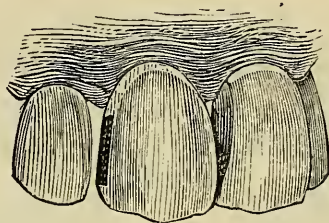
run in a line with the dentine walls. A thin edge of amalgam round the plug is likely, owing to the brittleness of the material, to gradually break away and leave a rough margin.*

Fig. 126 illustrates the preparation of a cavity when the

* The materials used for stoppings are described in later paragraphs.

decay is situated in the fissures of the crown of a molar. The dotted lines indicate about the extent to which it is necessary to cut back the enamel walls. Fig. 127 shows the same cavity prepared. In cutting out such a cavity

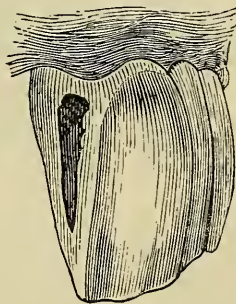
FIG. 129.



care should be taken to leave no sharp corners; they should all be well rounded off, to facilitate packing of the stopping.

Fig. 128 shows a cavity after excavation on the distal surface of an incisor. The cavity is of some depth towards its centre, but from that point slopes gradually

FIG. 130.

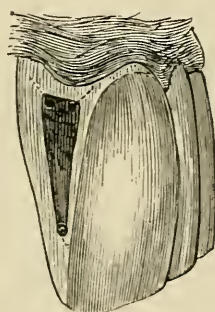


in every direction towards the lingual and labial margins, and towards the cutting edge and neck of the tooth. It forms, therefore, a uniformly concave saucer-shaped cavity incapable of retaining a filling. Such a cavity

might well be prepared by giving it the form of a trench, as shown in fig. 129, with slightly undercut walls, rendering it a little smaller at the orifice than within.

The next diagrams illustrate the formation of retaining points. A cavity of typical character on the distal surface of an incisor is shown in fig. 130. After removal of the carious tissues it forms a shallow concavity, broad at the upper part and sloping and narrowing towards the cutting edge of the tooth, near which point it terminates.

FIG. 131.



The preparation of such a cavity would consist, after slightly deepening the labial and lingual walls, in drilling two pits (as shown in fig 131) in the upper aspect, and one in the lower angle, of the depth and in the direction indicated by the dotted lines.

In the examples just illustrated the cavity is bounded by four solid walls; in the following there are only three walls, and consequently the mode of preparation is modified in some details.

Fig. 132 is an example of decay occurring in the side of an upper bicuspid. In these situations, and particularly with cavities on distal surfaces of bicuspid and molars, it is generally necessary to cut through the crown in order to get free access to the cavity. Enamel forming the grinding surface of a bicuspid or molar, unsupported

by a considerable thickness of dentine, will not long withstand the force of mastication even after insertion of a filling, and for this reason alone must be in many cases cut away. Small cavities, particularly on mesial aspects and where decay has not closely approached the masticating surface, may, however, often be effectually treated without cutting through that surface. The dotted lines indicate the extent to which it is usually necessary to cut back the enamel walls in the case

FIG. 132.

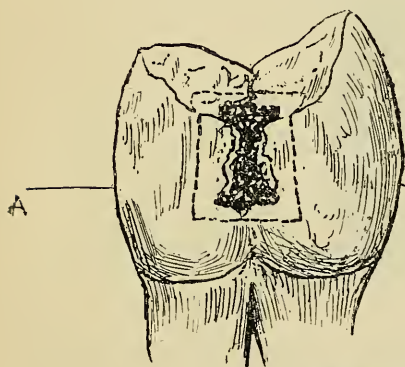


FIG. 133.

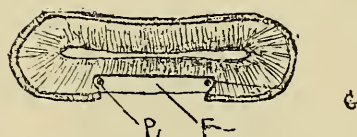
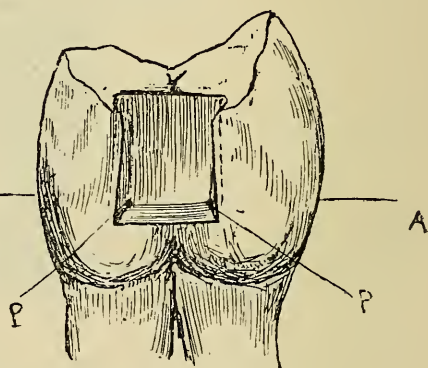


FIG. 134.

illustrated. This being done and decay removed, the cavity must be shaped as shown in fig. 133 and in section fig. 134. The floor of the cavity should be slightly wider than the mouth, and at the junction of the side walls with the inner one retaining grooves should be cut as indicated in dotted lines in fig. 133 and G in fig. 134. At the bottom of these grooves retaining points should be drilled (figs. 133 and 134, P P). The edges of the cavity should be finally rounded and well smoothed off.

Figs. 135, 136, 137, illustrate the preparation of a cavity where a portion of the side and cutting edge of a

FIG. 135.

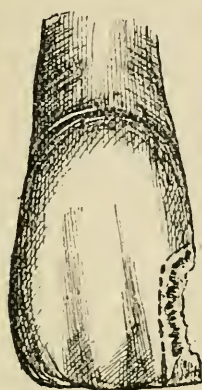
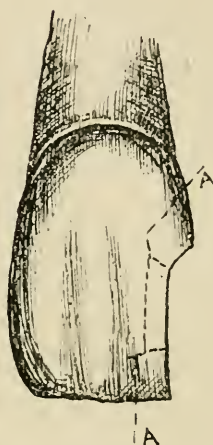
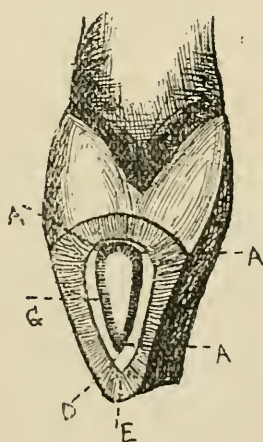


FIG. 136.



tooth are destroyed, and consequently part of the filling has no supporting walls.

FIG. 137.



The dotted lines in fig. 135 show the extent to which the enamel walls will have to be cut back in the preparation of the cavity.

Fig. 136 shows front view of tooth with cavity prepared showing the extent of tissue removed.

Fig. 137 is a side view of same tooth showing cavity prepared. In preparing a cavity of this nature for gold, if after the removal of decay there is left only a thin shell of enamel unsupported by dentine at the cutting edge, it will be necessary to cut it away, as illustrated in figs. 136 and 137. A thin shell of enamel in an incisor or canine which would not bear the force necessary in packing gold, may often be preserved by use of plastic cement and gutta percha.

In order to secure a gold plug in such a cavity it will be necessary to excavate an undercut groove all round. This groove should be cut in the dentine between the enamel and the pulp, so as to leave a supporting layer of dentine under the enamel and a protecting layer over the pulp, see figs. 137 and 152, in which the groove is marked G and U respectively. Three retaining points must then be drilled in positions indicated in figs. 136 and 137, marked A A A, care being taken not to approach the pulp or crack the enamel. Preparation of the cavities of this type is designed to provide for fixation of an immovable wedge-shaped mass of gold in the depths, upon which can be built more and more until the tooth is restored to its original form.

The later section on gold filling will be further explanatory of this subject.

Separating Teeth.—The difficulties which present themselves in dealing with cavities, which, being situated on the contiguous surfaces of teeth, are neither fully visible nor sufficiently accessible, must be overcome either by free chamfering, or by temporarily forcing the teeth apart. The beneficial effect of permanently separating teeth was explained in the section on the treatment of incipient caries, and the procedure there described must be adopted in the majority of cases

preparatory to the filling of the cavities in question. In treating incisors and canines the plan described in the section on incipient caries must be adhered to, and the chamfering must be as far as possible confined to the lingual aspect of the teeth. This suffices in most cases to render the cavity accessible to the filling instruments from behind, whilst the labial surface remaining intact, the normal appearance of the tooth is preserved, and the filling, unless large, is rendered invisible to casual observation. The instances in which it is better to force the teeth temporarily apart are those in which small cavities exist in teeth—especially front teeth—of otherwise sound structure, and where permanent separation would cause disfigurement. Sometimes the plan may be well adapted of chamfering the affected surfaces to some extent, and pressing the teeth apart in order to obtain the further space necessary for the use of the filling instruments.

The temporary separation of front teeth—incisors, canines and bicuspidis is easily effected by slipping between them a strip of india-rubber, and allowing it to remain for twenty-four hours. A very slight amount of pressure suffices for the object; the rubber should not therefore be thicker than the space which it is desired to make, and this space should not be greater than suffices to allow the use of the necessary instruments. If much force be exercised great pain is set up, and the presence of the rubber soon becomes intolerable. After the removal of the rubber the teeth fall together again in the course of a few hours, and the tenderness which the process has caused also rapidly subsides.

A similar effect can be produced by packing a plug of cotton wool, saturated with mastic cement, between the teeth, and allowing it to remain for a few days, renewing it at intervals till the desired effect is produced.

This plan is preferable with the molars and also in cases in which a mass of swollen gum projects into the cavity. Pressure of a plug of this kind causes masses of swollen gum to gradually shrink, leaving a clear way for the use of instruments.

In cases where the patient cannot endure the pressure of a strip of rubber between the teeth, separation can be effected more gradually and less painfully by narrow cotton tape. The patient may insert one thickness between the teeth, and after a few hours he will be able to double the tape, and so can go on gradually increasing the number of folds until he has used the number directed; three folds of tape are generally sufficient. It is often well after wedging teeth to insert a temporary filling for a few days, occupying the space obtained, so as to keep the teeth apart. This will give time for tenderness to subside, and will prevent pain from the force in condensing gold.

During the subsequent steps of a filling operation in interstitial cavities, the insertion of a wooden wedge between the necks of the defective teeth is often useful. A piece of compressed hickory of suitable size is cut so as to fit with a moderate degree of tightness the V-shaped space which naturally exists between the necks of the teeth. This is steadily pushed between the teeth, and the ends being cut short, it is allowed to remain until the filling is completed. The use of a wedge alone in this manner, in some cases in which the teeth are not closely in contact, is sufficient to afford room for the satisfactory performance of a filling operation. In using wooden wedges or screw separators, which also are sometimes employed to press teeth quickly apart, great care must be taken to avoid excessive force, for this may excite periostitis which, lingering in a chronic form, may lead, if not to the immediate loss, to permanent looseness and tenderness of the tooth. The wedge

often subserves the purpose of forcing away the gum and preventing it from bleeding, and from being wounded by files and other instruments; whilst the tooth is steadied, rendered more able to bear the force of plugging, and pain is thus diminished. A wedge also often serves to hold in position the rubber dam and a matrix.

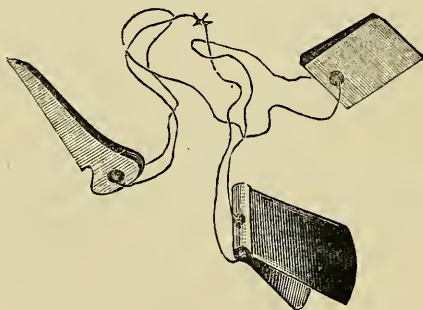
The making of permanent spaces between the teeth, by chamfering the surfaces is productive of nothing but good as a rule with the six front teeth; food is not apt to lodge for long in those positions, and with this plan stoppings are less visible and disfiguring. But in a considerable number of instances, spaces between grinding teeth are productive of discomfort to the patient, and this may be considerable or even intolerable in unfavourable circumstances. During mastication food is apt to be gradually forced into the spaces until the mass pressing upon the gum and neck of the tooth gives rise to great uneasiness or pain. To avoid this the chamfering ought, when possible, to be done as to allow the space to be easily cleared by the tongue, and indeed often the surfaces can be so bevelled that the difficulty is reduced to a minimum. The best treatment of interstitial cavities is by construction of what are termed "contour-fillings"—fillings which restore the original contour of the tooth. Such fillings call for skill and labour, and unless perfectly constructed they give rise to evils. With a wide space between the teeth the patient will be conscious of the lodgment of particles, and may take care to remove them; but with badly-made contour-fillings *débris* is likely to lodge and remain without the patient being aware of its presence, and decay will probably be soon started, and at the part most difficult of access—the neck of the tooth at the line of the gum.

Use of the Matrix.—When the contour of a tooth needs restoration the use of a matrix or artificial wall.

against which a filling can be packed and which can afterwards be easily removed is of great service.

Where decay is situated as in fig. 138 and there is only a small division between the teeth, a thin piece of polished steel can be cut to size and slipped between the teeth. Strips of steel of different widths and thicknesses can be obtained from instrument makers, and a piece should be selected wide enough to extend from below the cervical edge to the mouth of the cavity and of a thickness sufficient to fit tightly between the teeth, or it can be fixed by a wooden wedge. A simple form of matrix, the character of which is made clear by the illustration, is shown in fig. 138. Two sizes are enough for a

FIG. 138.



large number of simple cases. The wedge (shown in the cut) is used when necessary to fix the matrix. Where lingual and labial walls are destroyed to any considerable extent, a flat sided matrix will not serve if a contour filling is to be built. In these cases the matrix must provide a concavity of sufficient depth to allow of the building out of the stopping. Miller's matrix is specially adapted for cases of this nature. It is made in numerous shapes and sizes and in sets, so that one can be usually selected to suit any case. Fig. 139 shows this matrix in position and also two forms of the matrix.

Where the tooth is isolated or there are no neighbouring teeth to help retain the matrix in position, a matrix as shown in fig. 140 should be used. It consists of a shaped steel band which is passed round the tooth, and kept in position by a screw clamp. Fig. 140 shows the band and clamp and the matrix in position. A variety of sizes to suit different teeth are manufactured.

Another method of forming a matrix is to make in sheet lead a pattern of a band to envelop the tooth

FIG. 139.

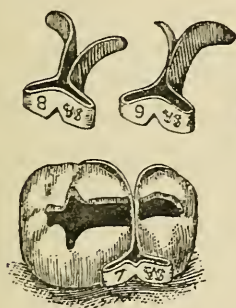
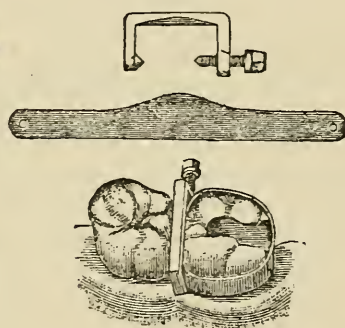


FIG. 140.



tightly. A piece of platinum or telephone plate is then cut to the pattern and the ends soldered together. The matrix is then ready for use and will be found to adapt itself accurately to the tooth if the pattern has been cut correctly. This kind of matrix possesses an advantage over any other in that it can be left in position; and when a large portion of the crown and side of a tooth has to be restored with amalgam it does away with risk of the stopping being dislodged before it has had time to set and harden. The presence of a matrix is apt to give the operator a false impression of solidity in the plug during building up a filling, and particular care must be taken in packing against the artificial metal wall.

Contour fillings ought to be built up to such extra size as will allow for reduction during finishing and

polishing; but as the use of the file mostly gives great pain below the line of the gum and at the level of the cement, it is advisable to leave as little as possible of surplus at that point.

Drying the cavity.—The cavity having been prepared for the reception of a filling, the next step consists in drying it and guarding against the access of moisture until the completion of the operation. The difficulty in accomplishing the latter part of this process is much greater in every case at some positions in the mouth than at others, whilst the extremely profuse flow of saliva in certain patients is even under favourable circumstances hard to control. The teeth situated at the anterior part of the upper jaw are the most easily managed, the orifices of the salivary glands being distant, and the fluid naturally gravitating towards the back of the mouth. In most cases during the filling of the upper incisors, canines, or bicuspid, the cavity may be kept dry by the insertion of a folded napkin beneath the lip, and across the lower front teeth, to prevent the tongue from carrying up moisture from beneath. The most useful form of napkins are made of moderately thick diaper and measure from three to four inches in breadth and from six to eight inches in length. This material if kept free from starch in washing will be found highly absorbent. The napkin can be folded or twisted into a loose coil and as it becomes saturated with moisture a dry one may easily be substituted without permitting the access of saliva to the tooth. Patients who cannot swallow with the mouth open may sometimes be allowed at intervals to close the lower teeth upon the folded napkin and so get rid of the accumulated saliva.

The duct of the largest salivary gland—the parotid—opens through the mucous membrane of the cheek, where it lies against the upper molars, and its flow must therefore be directed or controlled before these teeth can

be dried. Where the flow is not profuse, and particularly when the cavity is situated on the masticating surface, precautions such as described for the front of the upper jaw may suffice. A folded napkin may be laid between the cheek and alveolar border, and held in position by the fingers of the left hand. In other cases these measures may be supplemented by the temporary closure of the orifice of the duct. This may be accomplished by the application of clamps specially contrived for the purpose, or the exit of saliva may be sometimes prevented temporarily by a small patch of impervious sticking plaster.

In the lower jaw the exclusion of saliva during plugging presents more difficulties than in the upper. The saliva naturally accumulates on the floor of the mouth, and the movements of the tongue and the efforts of swallowing have a constant tendency to throw it over the crowns of the teeth. In patients who cannot swallow with the mouth open the difficulties are increased. Where the tooth has to be kept dry for no more than a few minutes, the influx of saliva may be guarded against by the insertion of a roll of napkin beneath the tongue and between the cheek and side of the jaw, the rolls being firmly held in position by the fingers of the left hand. It is important to apply the napkin to the floor of the mouth and not to attempt to hold down the tongue. In some cases an intelligent and steady patient may be trusted to hold a folded napkin with the fingers of the hand which least comes in the way of the operator. The patient may pass the forefinger over the teeth and press down the napkin, whilst with the other fingers and thumb he grasps the lower jaw. In this position the arm may be allowed to rest on the chest. With the lower jaw steadied in this way many patients are enabled to swallow with the jaws apart and are thus able to get rid of the saliva. An

instrument is made which consists of a flat metal band designed to lie within the lower jaw and hold firmly down a roll of napkin beneath the tongue. The band by a shaped arm passing over the front teeth is attached to a padded frame under the chin. A screw draws the parts together and provides the necessary pressure.

In the majority of simple ordinary cases it will be found possible to keep the tooth dry during the insertion of a filling by the means just described, which were those alone available until late years. There has, however, been recently introduced the contrivance known as the rubber dam. This simple invention enables the dentist to keep a tooth perfectly dry throughout the most prolonged operation. The dam is formed of a thin sheet of india-rubber specially prepared for these operations. A piece is taken a few square inches in size, and towards its centre is punched a small hole, one about as large as an ordinary pin-head being big enough for a molar. This hole is stretched and slipped over the tooth, so that the rubber closely embraces the neck and leaves the crown surrounded by an impervious dam. In practice it is found necessary to make a series of holes in the rubber the same distance apart as the crowns of several of the teeth adjoining the one to be operated upon, and to pass the rubber over them also. By this means the rubber is securely fixed and kept effectually out of the way.

Difficulties in applying and securing the dam arise where the teeth are in extremely close contact, and where, from the conical shape of their crowns, the elasticity of the rubber causes it to spring off. The first of the difficulties may be overcome by forcing down the highly stretched rubber by a thin strand of waxed floss silk. It is found that by the pressure of the tense thread the teeth can be forced slightly apart at the point where their crowns are in contact at the masticating surface,

and this point being passed, the rubber is readily carried down to the gum, at which position an interval invariably exists between the teeth.

In operating upon interstitial cavities it is advisable before applying the rubber to pass a silk thread between the teeth and ascertain that there are no sharp edges to split the dam while being placed in position. Tartar round the necks of the teeth likely to prevent either clamp, rubber or ligature from passing to its proper position at the neck of the tooth at its narrowest part must be removed, and this is of special importance with cavities in lower front teeth. To prevent the dam from springing off the tooth a steel clamp of suitable design may be used. Clamps are applied to the teeth with the aid of clamp-forceps. With these the clamp is carried to its position, opened and slipped over the tooth. The clamp grips tightly the neck of the tooth, and forms a projecting flange, under which the rubber slips, and is thus held secure. A great variety of clamps have been designed for this purpose, and a little experience

FIG. 141.

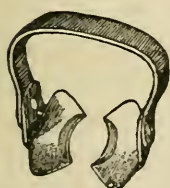

FIG. 142.

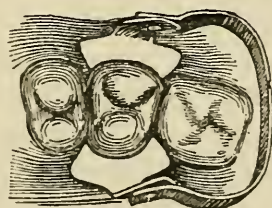


FIG. 143.



will soon teach the student those best adapted for his purpose. Figs. 141 and 143 illustrate two clamps (Buckman's). Fig. 143 is designed for molars and fig. 141 for bicuspid. Fig. 142 shows the bicuspid clamp *in situ*. In the drawing showing the application of the rubber dam (on page 201) the molar clamp is seen in position.

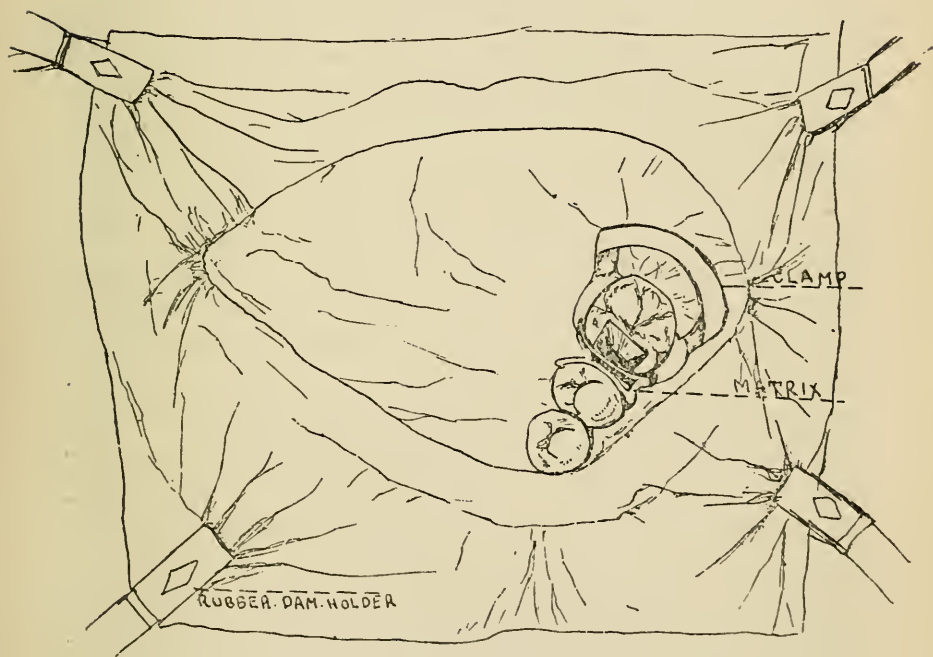
Having ascertained that the clamp fits the tooth firmly and will not spring off, the operator should fix it in position, and having punched clean holes without any cracks (which would cause the rubber to tear when stretched), he should with his two forefingers stretch the rubber and slip it over the bow of the clamp and then under the flanges. He should then in a similar manner slip the rubber over a sufficient number of contiguous teeth, so as to give him a clear view of the tooth to be filled; and as he slips the rubber over tooth after tooth he will find it usually necessary to carry it down between the teeth by means of silk thread. The thread is best left in each space until the rubber has been passed over all the teeth. The silk ligature must next be passed round each tooth once or twice, so as to carry the rubber below the edge of the gum. It can then be tied tightly with a surgeon's knot. It is important that this should be done to each tooth, for if the rubber be not tucked under the free edge of the gum moisture may ooze through. Should the clamp spring off the ligatures will retain the rubber in position until the clamp can be reapplied. Should the operator not be able from the position of the clamp to pass the rubber over it when it is fixed on the tooth, the flanges of the clamp may be passed through the hole in the rubber; the whole may then be fixed with the aid of the clamp-forceps. Care must be taken to neatly wrap the rubber round the blades so that it will not obscure the view whilst fixing the clamp on the tooth. Having fixed the clamp in position the rubber can generally be slipped easily under the flanges and fixed as described previously.

Fig 144 shows the rubber dam in position, held back neatly out of the way by two bands, one running round the back of the patient's head, the other round the neck. A molar clamp is shown in position, also a matrix (Miller's). The rubber is passed over the bicuspid so as

to give a clear view of the cavity. When used in conjunction with the dam a matrix is of course to be adjusted last, and with a wedge it assists to keep the rubber secure. The whole diagram illustrates a cavity in a left lower molar prepared and ready for the insertion of a filling.

The rubber dam gives less annoyance to the patient whilst answering the purpose better than any other

FIG. 144.



contrivance of the kind, besides which it leaves both hands of the operator free for the manipulation of stopping instruments. As an adjunct to the rubber dam several ingenious hydraulic automatic saliva-ejectors have in late years been introduced. These carry off the water as it accumulates on the floor of the mouth, do away with the necessity of swallowing, and prevent discomfort arising from flow of saliva out of the mouth.

The influx of saliva having been guarded against, the cavity has next to be dried—a comparatively easy matter. It may be done roughly by wiping the surface with absorbent cotton wool, or with bibulous paper, or amadou. It is, however, by no means easy to procure perfect dryness by mere wiping with these materials. Better to achieve this end several varieties of hot-air syringes have been devised, by which the moisture may be driven off by a current of heated air. These instruments are assisted in their action by the use of absolute alcohol, in the manner first suggested by the author. When applied to a wet surface, the alcohol, having a great affinity for water, combines with it, and evaporates. In this way it not only carries off superficial moisture, but it also abstracts water which the tissues intrinsically contain. Cavities to be dried with this fluid should be first wiped out with wool and then swabbed with a small pellet saturated with alcohol. After a pause of a moment to allow the spirit to unite with the water, the cavity can be again wiped with dry cotton, or the hot-air current may be thrown in. Rectified spirits of wine of ordinary strength, freely used, suffices for the purpose where the tissue to be dried is healthy, and not softened or saturated with water. The swabbing and wiping and drying with heated air can be repeated when called for, as in those cases already referred to under a previous heading, in which it is desired to harden a layer of dentine the seat of incipient caries, which to avoid exposure of the pulp must be left in the depths of a cavity beneath a filling. Like every other fluid which has a strong affinity for water, absolute alcohol will of course produce irritation if allowed to flow upon the skin or mucous membrane, although this will be but slight if the surface be wet and the quantity of spirit small. Accidents of this kind need not happen if ordinary care be taken.

The materials used in filling teeth may be conveniently arranged for the purpose of description according to their durability in the mouth. One (gold) only is practically imperishable, several others, although subject to slight physical and chemical changes, are sufficiently lasting to deserve the name of permanent filling, whilst a third group, being liable to more rapid decomposition, must be classed as temporary fillings. Permanent fillings are, of course, always intended to act as permanent substitutes for the tissues destroyed by disease. Temporary fillings—as was noted incidentally in the section on excavating the carious tissues—are used in the preparatory treatment of cavities. Further explanation of their employment in the same and in other ways will appear in after chapters.

Gold used for filling teeth is pure—without any alloy whatever—for in this condition alone it possesses the qualities necessary for the production of perfect plugs. It is prepared by the manufacturers in two forms—in foil and in a spongy mass. The leaves are produced by beating, the sponge is formed by precipitating the metal from a solution. The leaf gold suitable for filling teeth is much thicker than that which is used in gilding, and comes to hand in sheets about four inches square, the lightest of which weigh four grains. Thicker qualities are made to suit the fancy of different operators, and the exigencies of cases. Sheets from four to six grains in weight are the most generally useful. Two qualities of gold foil are manufactured for dental purposes, cohesive and non-cohesive, and these differ in the fact that pieces of the former pressed together do not cohere, whilst portions of the latter forced closely into contact become inseparably united. These peculiarities are due to difference in the molecular condition of the foils, the cohesive variety being more crystalline in character than the non-cohesive. The cohesive quality of all foils

is increased by annealing, and the non-cohesive variety may be rendered cohesive by the same operation. Annealing is performed either by heating the gold upon a metal tray or by passing pellets through the flame of a small spirit lamp when conveying them to the tooth. The cohesive property of pure gold (when in a certain molecular condition) is one that it possesses in common with some other metals, such as platinum, silver, tin, and lead, which are comparatively soft at ordinary temperatures. The cohesion is in fact due to welding, the metals being capable of union of this kind when in their cold state, just as iron and some others are when rendered plastic by heat. Sponge gold, owing to its perfectly crystalline form, is the most adhesive variety prepared for dental purposes. The cohesive property of gold is destroyed by moisture, but can be again restored by annealing.*

Tin foil, of which permanent fillings can be made, is composed of the pure metal. It is sent out by manufacturers in leaves of the same size as gold foil, and in thickness about the same as six-grain sheets of that metal. Pure tin, as just mentioned, can be welded in the cold state, but the union cannot be brought about unless the surfaces of the separate portions are bright and free from oxidation. This chemical change affects tin foil after a few hours' exposure to the atmosphere, and destroys to a great extent its cohesive property. This does not, however, much lessen its usefulness as a filling material. In plugging it is manipulated in the same way as non-adhesive gold foil.

Amalgam fillings come next to gold and tin in point

* Within late years great advances have been made by manufacturers in preparation of gold for dental purposes. It is supplied ready for use in a variety of forms—cylinders, pellets, and ribbons—and the operator is rarely obliged to undertake the preliminary manipulation which was formerly always called for.

of durability. These are all formed by combination of mercury, either with a single metal or with an alloy of several. Perhaps one of the first of these compounds used in dentistry was that composed of coin silver and mercury. The silver, reduced to filings, was rubbed up in a mortar with mercury, until a stiff pasty mass was formed, which became hard in the course of a few hours. This amalgam, although of considerable durability under favourable conditions in the mouth, had the disadvantages of becoming itself blackened by oxidation, and of gradually staining the tooth in which it was inserted. In spite of numerous attempts to do away with them, either or both of these imperfections in a greater or less degree are apt to occur with many of the amalgams since introduced; but in the better class of amalgams produced by manufacturers in late years these disadvantages have been reduced to a minimum. Most of these have as their basis silver alloyed with small quantities of tin, gold, and platinum, the alloy being reduced to filings to facilitate union with mercury.

Palladium amalgam, and copper amalgam, are each composed of pure metals with mercury. The palladium is manufactured for the purpose by precipitation, which produces a fine powder. Palladium amalgam does not stain the tooth, but its surface becomes intensely black. Copper amalgam is supplied in the form of small solid pellets—masses of amalgamated copper and mercury. To prepare it for use, a sufficient quantity is placed in an iron spoon, and held over the flame of a spirit lamp, until globules of mercury appear on the surface. It is then ground down in a mortar and forms a smooth paste, with an evident excess of mercury. It is then squeezed until much of the mercury having escaped, the mass assumes a drier and somewhat granular character. Copper amalgam being now manufactured of perfectly pure materials no longer presents the disadvantages to

which former stoppings of this kind were subject. It does not blacken the tooth ; nor does it usually become discoloured in any position where it is subject to friction : and it is harder than the earlier preparations and also less liable to waste by chemical action upon its surface.

It was proved some years ago by the experiments of Mr. Charles Tomes that all the amalgams then in common use underwent contraction during the process of hardening, although the extent to which this occurred varied considerably in the different compounds, and in some it was so slight as to be insignificant. The amount of contraction was ascertained, by obtaining the specific gravity of masses of amalgams when recently mixed and afterwards when hardened. In the former state their density was found to be always less than in the latter, the difference being, of course, due to contraction. It is obvious that when the shrinkage is more than infinitesimal in amount a permeable space must be formed between the filling and wall of the cavity during hardening of the amalgam, and in such a case the stopping must necessarily fail to arrest decay.

The following table from Mr. Tomes' paper exhibits a comparison of the weight gained (*i.e.*, shrinkage) by different amalgams while hardening :—

Palladium	·037
Sullivan's (copper)	·07
*Ash's	·14
*Smale's	·14
Tin and silver (55 to 45)	·35
Tin and silver (equal parts) . . .	·38

The compounds marked with an asterisk may be taken as fair specimens of the amalgams in ordinary use at the time these experiments were made.* These experimental

* Since this date, many years ago, considerable improvement has been brought about in the manufacture of amalgams ; so that many of the compounds now supplied are free from the defects of earlier products, and much more adapted in every way for their purpose.

results accord in the main with those of practice. Palladium and copper amalgams, when packed with due care, form plugs of greater durability than those composed of any other amalgam. It was once a common impression that many amalgams expand in hardening. This is a mistake, arising from the fact that some of these fillings in setting tend to change in shape—to shrink from the walls and protrude from the orifice of the cavity. It must be also borne in mind that an amalgam when hardened partakes more of the character of a chemical compound than of a mechanical mixture, and that although during the operation of filling one portion of amalgam may be used with more mercury than another, the mercury will be found equally diffused throughout the mass when the process of setting is at an end. And it seems probable that the change in shape of the mass which sometimes occurs may be due to absorption of mercury from those portions where it is in excess—often the outer portions—into those parts which contain less mercury. In theory it would appear that the contraction which accompanies the hardening of most amalgams must be alone an insuperable objection to their use for fillings; but practically in well-chosen cases amalgams manipulated with due skill and care endure for an indefinite period. The most favourable cases for amalgam fillings are those in which the general structure of the teeth is of good quality; the most favourable cavities such as are situated on the grinding surfaces of the teeth, or in situations where they are constantly subject to friction by the tongue or in mastication. The durability of an amalgam filling largely depends upon the amount of care which is bestowed on the preparation of the cavity. It must be borne in mind that amalgam does not adhere to the walls of a cavity, but is held as a plug by packing alone. It must, therefore, be thoroughly supported by

solid walls, and fixed in position by well-planned retaining points where needful. Amalgam does not answer well packed over a chamfered or bevelled edge, and therefore this shape should not be given to the inner margins of the orifice of a cavity where these materials are used. Too much care cannot be taken in finishing the orifice of the cavity, and by means of corundum points and the burring engine in rendering the inner margins of suitable form and perfectly smooth.

Many points with regard to the properties of amalgams are still undecided. Among them the question as to the proportion of mercury which it is best to use with the different compounds is still an open one, the balance of evidence being, however, in favour of the admixture of a quantity no greater than will suffice to produce a plastic mass, which becomes coherent under slight pressure.

In addition to staining the tissue, some amalgams have the effect of rendering the surface of dentine against which they rest extremely hard. This appears due to saturation of the tissue to some slight depth by the metallic salts set free during oxidation of the amalgam. In the case of copper amalgam the tissue in time becomes so hard as to resist effectually the further inroads of caries, and this effect doubtless has a share in increasing the permanence of this amalgam as a filling, counterbalancing the effect of the slight contraction which it undergoes whilst hardening.

In proportion to their bulk and to the nearness with which they approach the pulp, metallic fillings—whether of gold, tin or amalgam—being rapid conductors of heat, necessarily increase the susceptibility of teeth to changes of temperature. The increased susceptibility is as a rule most marked in teeth of delicate structure; and it is of course greatest in those cases in which prolongations of the pulp cavity run abnormally close to the

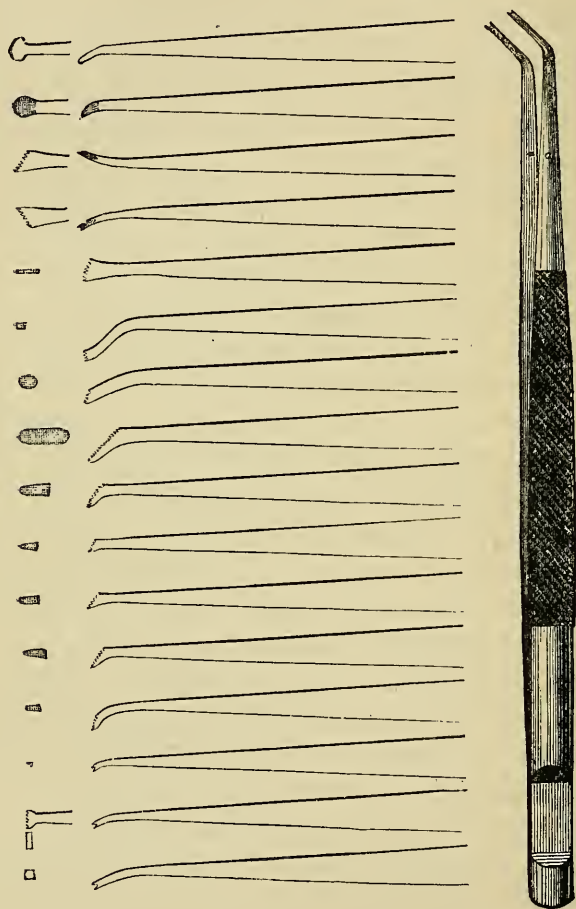
surface. In favourable cases the sensibility usually passes off with the lapse of time. In such cases a current of cold air or contact with cold or warm liquids excites a bearable sensation in the tooth which slowly subsides within a few moments. In unfavourable cases the pain continues for minutes or hours; and if the frequent irritation of the pulp to which the pain is due be allowed to go on it may pass into acute inflammation. To avert such an untoward event it is a good rule of practice to cover the depths of large cavities, or such as show uncommon sensibility, with a layer of non-conducting filling. A very thin layer suffices; and the plastic cements presently to be described are best for the purpose. Tin foil, which is a worse conductor than gold, may in some cases be well used as a foundation for large fillings of that metal.

Gutta Percha.—Among filling materials of a more perishable nature than the metallic compounds just described, to gutta-percha may be assigned the first place; indeed, although its physical characters render it unfit to sustain the wear of mastication, its durability as a filling in proper situations is very great. For dental purposes gutta-percha is prepared in the form known as Jacobs' and Hill's stoppings. These consist of gutta-percha bleached and intimately blended with silica, or some like substance in the form of an impalpable powder, to render the material harder and more durable.

Plastic Cements.—There has been introduced during late years a numerous class of useful compounds for fillings, to which various fanciful names have been given by manufacturers. Some of these are mainly composed of oxide of zinc mixed either with silica or marl. This pulverulent mixture, when required for use, is worked into a paste with a strong solution of zinc chloride. Chemical combination takes place, and a hard mass is rapidly formed, consisting of oxychloride of zinc, with the earthy ingredients mechanically mixed. These latter

serve to impart greater hardness to the filling. Chloride of zinc being extremely irritating this filling must not be used where the pulp is nearly exposed. Similar cements,

FIG. 145.



of which the main ingredient is phosphate of zinc, and which are both non-irritating and more durable than the oxychloride compounds, are now supplied by manufacturers.*

* In future pages the term "cement" is used to denote this last class of compounds.

Temporary Plugs.—For the purpose of sealing up cavities in the teeth for a few hours or days, nothing answers better than absorbent cotton wool saturated with a solution of gum mastic in spirit, or of gutta-percha in chloroform. After the insertion of the pellet the fluid evaporates, leaving a tough mass impervious to moisture. Soft highly plastic gutta-percha is also supplied for this purpose.

Instruments used in filling teeth.—A pair of plugging tweezers, a set of eighteen pluggers (Butler's pattern, fig. 145), and a mallet, will be found sufficient in filling the vast majority of cavities with gold. The tweezers are for the purpose of carrying portions of stopping into the cavity and fixing them there prior to consolidation. Of the pluggers seven or eight will have serrated wedge-shaped points, of various sizes, and bent at different angles convenient for reaching cavities wherever situated. These are used for carrying gold into position and in packing or welding it there. Foot-pluggers of different patterns will be included in the set. These serve to consolidate the component parts of the plug. In addition there will be four or five instruments with working extremities flat faced and serrated, and so bent or twisted on the shaft as to reach cavities to which straight foot-pluggers could not be applied. Lastly, there will be provided a burnisher, having a rounded highly polished steel point. The same set of instruments serve in filling with tinfoil.

In the construction of cohesive and non-cohesive gold fillings the consolidation and the welding of the metal is much facilitated by the aid of the mallet, an instrument which has come into general use in late years. A quick succession of sharp blows, carefully regulated, and given by a mallet of proper weight, does not inflict more pain upon the patient than the pressure of the hand alone, whilst the effect is to weld and condense the foil more

rapidly and thoroughly. The heads of hand mallets which are manufactured for this purpose are made of lead or some such soft metal, and weigh about two ounces. In order to facilitate the use of the mallet, and to leave one hand of the operator free, automatic instruments are now constructed to which a series of plugging points of various sizes and shapes can be adjusted as required. With these instruments the amount of force may be regulated with the utmost nicety to meet the exigencies of particular cases.

A set of instruments (six or eight) with smooth round steel points are most suitable for packing amalgams. If the points which are used with these materials be serrated, the rough surface soon becomes clogged with amalgam, which lodges and hardens there, forming a layer, which softened again by the mercury, is apt to mingle with an amalgam of another kind on a subsequent occasion.

A set of small spatulas are required for the insertion of oxychloride of zinc cement, and the blades of these may be advantageously made of silver or platinum, steel being rapidly oxidized and destroyed by these fillings. A similar set with smooth steel blades will suffice in packing phosphate cements; and a variety of spatulas and pluggers are provided for gutta-percha, and the insertion of temporary plugs of cotton wool and cement.

Filling with gold.—It has been already explained that two varieties of gold—non-cohesive and cohesive—are used in filling teeth, and that their difference consists in the fact that fragments of the former kind do not cohere when pressed together, whereas separate portions of the latter may be welded and united into a solid mass. Plugs of non-cohesive gold must be formed always by the wedging together of folds or layers of foil; whilst on the other hand, in fillings composed of cohesive gold, the mode of arrangement of the successive portions is of

little importance, provided they be made to unite with each other. Although portions of non-cohesive foil do not actually coalesce under pressure, they become sufficiently dense to take a high polish, to resist mastication perfectly, and to constitute a stopping absolutely impermeable to moisture. Indeed it is much easier to make a water-tight plug of non-cohesive than of cohesive gold. A cohesive gold plug can be perfectly built up only when it is composed of small pieces slowly and thoroughly welded together. If an attempt be made to consolidate a mass of cohesive foil it condenses on the surface beneath the instrument, and no amount of force which can be safely applied to a tooth is sufficient afterwards to affect the deeper portions which therefore remain imperfectly united and porous. The presence even of a trace of moisture, such as is liable to be deposited on the surface of the gold from the breath of the patient during the operation also prevents perfect welding from being accomplished. Either variety of gold, cohesive or non-cohesive foil or sponge, can be used exclusively in almost any cavity, but the properties of non-cohesive foil make it most useful in simple cavities—*i.e.*, those of the form of a hole or trench with vertical or nearly vertical walls—whilst the peculiar qualities of cohesive gold render it invaluable in irregular, difficult cavities, and where a plug has to be built up from a limited foundation. It is in many cases good practice to combine two kinds of foil, commencing with non-cohesive and using cohesive to build up the plug, or to key together securely the separate portions.

If the cavity be small in size and simple in form, the following method may be adopted. A sufficient quantity of non-cohesive foil—four to six grain sheets—is folded lengthwise by means of a spatula into narrow ribbons, each containing a third or a quarter of a sheet. These ribbons are next cut into short strips, which may be

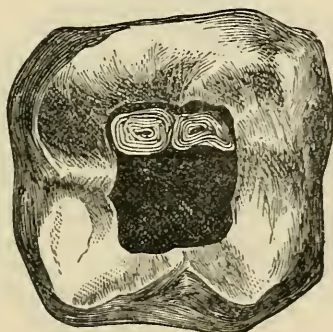
conveniently spread upon a wooden tray covered with smooth woollen cloth. The point of a wedge-shaped plugger is next pressed upon a few of the strips one after the other, which are thus fixed lightly to the instrument. The gold is thus carried into the tooth and lodged, so that one extremity of the folds rests on the floor of the cavity and the other protrudes from the orifice. Plugging forceps may be used to carry in the gold and lightly fix it in position. Portion after portion of gold is inserted in the same way, and forced against the walls of the cavity, until it becomes difficult to make the instrument enter. A smaller point is then used, and this is forced into the centre of the filling, the hole so formed being again filled with strips. The surface of the filling is next compressed by a broad, followed by a small, pointed instrument. Finally it is filed smooth, and then polished by means of slate stone and water followed by a burnisher. The whole process of reducing, shaping and finishing is best carried out with a succession of burs and wheels followed by polishing discs used with the dental engine. The surface of gold fillings should be left convex in shape, and slightly above the level of the surrounding tooth, unless the projection interfere with the bite. They should not overlap the margin of the cavity.

The procedure just described may be varied by the use of cohesive gold towards the end of the operation to fill the holes made by the perforating instrument. Again the entire cavity can be filled with cohesive gold. A loosely folded ball or pellet, or better a series of unannealed cylinders are packed on the floor of the cavity, and consolidated, and to this are one by one added annealed highly cohesive cylinders, each being thoroughly welded or kneaded to the mass by means of small pointed serrated instruments. Cohesive gold in the form of foil may be prepared for use in strips similar to those

of non-cohesive foil, just described, and like them may be carried into position on the point of a plugger; or portions of foil or cylinders may be fixed by the plugging tweezers, and afterwards condensed by other instruments.

Large cavities of simple form may be most rapidly and effectually plugged with cylinders or rolls of non-cohesive foil. The cylinders of cohesive and non-cohesive foil are to be obtained of the foil makers in great variety of sizes, and of the most exquisite plasticity, and this does away with the necessity of the operator preparing foil for use. They may, however, be prepared by the operator. They are formed by winding a ribbon of foil round the point of a thin broach. They should be of such a size that many

FIG. 146.

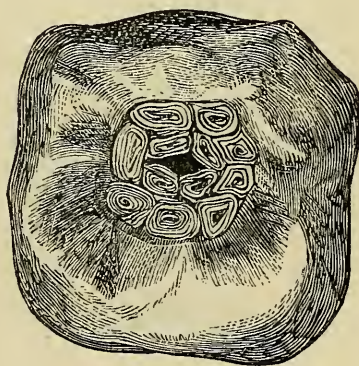


are required to fill the cavity, and of such a depth that when inserted endwise they project slightly from the orifice. Those used to commence the plug should be loosely rolled so as to be soft and malleable, but those for the latter part of the operation may advantageously be rolled more solidly or compressed slightly before insertion. In commencing the filling one of the cylinders is carried by the plugging forceps into the cavity and gradually condensed against one of the walls by a foot-plugger. Another and another are then introduced in the same way until the cavity is full. A wedge-shaped

instrument is then forced between the two last inserted cylinders, and the hole so made is filled with strips either of non-cohesive or cohesive foil. The rest of the surface may be next tested by a sharp pointed plugger, and at any point at which it may be made to enter gold is added. The surface of the plug is finally filed down and polished.

In cases in which cohesive gold is to compose the whole or the greater bulk of the filling, the first and most important step consists in fixing portions of gold securely in the cavity. Upon these portions more and more foil, in the form of strips or cylinders, is welded

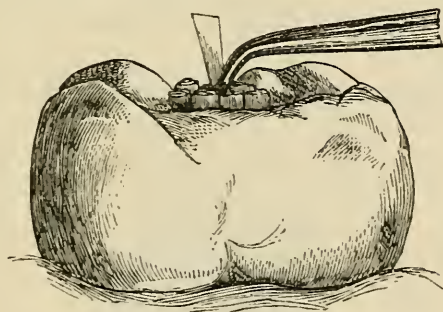
FIG. 147.



until the cavity is filled with a solid plug. In many instances the shape of the cavity after excavation allows of the secure formation of the foundation of the filling, or affords suitable positions for the packing of retaining points without further preparation, and the filling is commenced with strips, pellets, or cylinders. In some cases small pits, or retaining points of the kind already described must be cut, into which the gold being packed, the completed filling becomes dovetailed immovably in position.

The operation of filling with cylinders is illustrated in figs. 146, 147, 148. In the first of these the commencement of the filling is seen, two soft cylinders having been placed in position by the plugging forceps ready for consolidation, by the foot-plugger, against the wall of the cavity. The next diagram (fig. 147) shows a later stage of the operation, but the cylinders as depicted in the cut are insufficiently consolidated. The filling now approaches completion, the masses of gold are condensed, and a small central space alone remains to be plugged with strips of non-adhesive or fragments of adhesive foil. Fig. 148 exhibits this latter process in operation, and it also shows the extent to which a plug should project

FIG. 148.

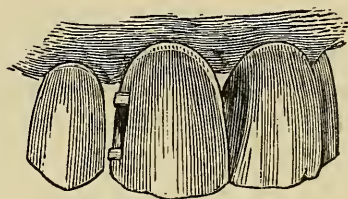


from the cavity before the surface is finally consolidated, filed smooth, and polished.

Fig. 149 shows a mode of beginning a filling with non-adhesive foil in a cavity of the trench-like form already described, and illustrated in figs. 128 and 129. The filling is commenced by fixing a mass of gold in the upper and lower extremity of the cavity. These masses may be composed of strips or small cylinders, and are so packed that they project slightly from the mouth of the cavity. The filling is completed by packing between these buttresses successive portions of foil in strips in the manner

described in speaking of small simple cavities. If cohesive foil be used, either partly or entirely, the filling may be commenced in the same way, or a loosely rolled pellet or cylinder may be packed on to the floor of the

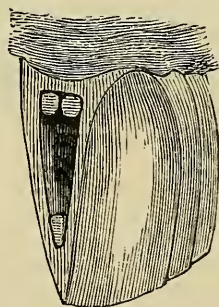
FIG. 149.



cavity, and the plug completed by welding to the first securely-fixed masses, portion after portion of foil in the form of cylinders, or strips, or pieces of loosely rolled ropes of foil.

Fig. 150 shows the commencement of a filling in the

FIG. 150.

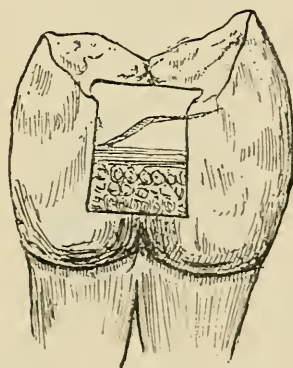


cavity already illustrated in fig. 131, three portions of gold being fixed in the retaining points there displayed. Each of these pits or points has been separately dealt with as a simple cavity, and packed with small cylinders or strips, each mass of gold projecting beyond the orifice of the main cavity. This part of the operation being

accomplished, the construction of a plug on one of the methods already described presents no difficulty. The same principles are applied to the filling of more complicated cavities in which retaining points are necessary, or in cases in which a plug has to be built up from a limited foundation. The first thing to be done is to form the points of support, anchorage, or foundation, care being taken that the masses of gold extend into the main cavity or project beyond its orifice when a filling on the wedging system is to be inserted.

A cavity of the character shown in fig. 133 may be filled with cohesive gold, used in the form of tape, folded to a suitable width and thickness. A sheet of No. 4 foil folded four times would make a suitable thickness, and it

FIG. 151.



should be cut into strips of such width that when used they do not obscure the view of the cavity. Finer strips should also be cut for filling the retaining points.

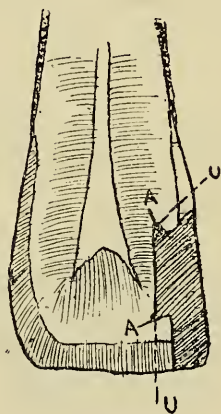
The retaining points, each treated as a simple cavity, should be first filled and then connected together by a bridge of gold. This will secure a firm foundation for the plug, on to which the gold can be packed layer by layer. Care must be taken that the grooves are filled with well-condensed gold and that the foil is well and

carefully packed over the outside edges of the cavity. In every cavity it is essential for success that each layer be well condensed before another is built upon it.

Fig. 151 illustrates another method of filling a cavity of this nature, specially applicable to cases where the decay extends to or below the gum.

A matrix having been fitted to the tooth, a layer of non-cohesive, closely rolled gold cylinders is packed at the bottom of the cavity, with their ends slightly projecting, and condensed. On this layer another is packed, and so on until the cavity is nearly half full. With a

FIG. 152.



sharp instrument retaining points should then be formed in the gold along the line of the grooves marked G in Fig. 134. These points should then be filled and bridged together by means of thin strips of cohesive gold and the remainder of the plug built up as described in the preceding paragraphs.

It is of course apparent that when filling a cavity in this manner the retaining points marked P P in figs. 133 and 134 are not required. It is a good plan before placing the non-cohesive cylinders in position to slightly

flatten them, so that more can be packed in a row and they can be the more easily condensed.

The strength (durability) of any stopping is in most cases only equal to that of its weakest portion; but the recurrence of decay owing to slight imperfection in a plug is much more likely to speedily ensue in positions such as exemplified in this case, along the line or below the level of the gum. Unless the most exquisite nicety both in packing and finishing be maintained in this part of the filling the labour bestowed on the rest of the plug will be mostly thrown away.

In dealing with a cavity such as shown in figs. 135, 136 and 137 the retaining points should first be filled, then the connecting grooves. This can be done with cohesive strips, and upon the foundation so formed a mass may be built up to the level of the surrounding walls and gradually carried over the cut margins of enamel and dentine until these are covered. The contour of the tooth may then be gradually restored by the welding on of more and more foil. Section of the tooth through the completed filling—A A indicating retaining points, U U the groove—is shown in fig. 152.

Examination of this figure will show that the weakest part of the plug is where the outside unsupported portion of the contour joins the portion wedged into the tooth. This is where the line of fracture generally runs when an accident happens; to avoid this the operator must be particularly careful to see that the gold is put on in thin layers and that condensation is perfect. Care should be taken in such cases that the gold tip is clear of the bite.

Filling with tinfoil.—This material is manipulated and packed in precisely the same way as non-cohesive gold foil.

Filling with amalgams.—Many of the remarks which have been made with regard to gold apply equally to amalgams. It has been already pointed out in a

previous page that the durability of these materials as fillings depends very much upon the mode in which they are manipulated. They should never be inserted in a mass, but should be thoroughly packed piece after piece, and retaining pits should be freely used on shallow sloping surfaces. It is important in packing to obtain absolute contact of the amalgam with the walls of the cavity, and to prevent a layer of mercury (which is often squeezed from the mass) from remaining around the forming plug. To achieve these objects it is first necessary to render the cavity absolutely free from moisture, and to keep it so throughout the operation. If the cavity throughout be surrounded with strong walls, or if a matrix be applied, and the dentine not highly sensitive, the amalgam may be used without excess of mercury—in a condition in which pressure is needed to consolidate it ; and considerable force may be exercised in packing the stopping. It is, however, often a very good plan to begin the stopping with amalgam soft through excess of mercury, and to express the surplus quantity in packing. This plan is especially useful where sensitive dentine is present, and particularly with patients who do not bear pain well—for example, in treating temporary teeth and first permanent molars in childhood. With this plan the first portions of soft amalgam are gently smeared over the floor and walls of the cavity. Then some folds of bibulous paper are carried in and the pluggers worked over this with gradually increasing pressure.

The globules of mercury as they exude are swept out of the cavity and away (over the rubber dam or napkin) by the paper held in the plugging forceps ; and the same procedure is repeated until the cavity is full ; amalgam towards the last being used with less mercury. With copper amalgam particularly, and in children's teeth it will be found that a pellet of cotton wool answers better than paper. It is not perhaps so effectual in forcing out

mercury, but it gets rid of enough, and it makes the operation either painless or much less painful than with use of an uncovered steel plugger. Cotton has no great tendency to adhere to the amalgam—hardly more than paper; and a few occasional adherent filaments are easily scraped away before a new portion of amalgam is added. With some amalgams it is recommended that besides driving out mercury in this way by force, tin foil should be applied at intervals to take up mercury from the surface of the stopping; and this procedure seems to render the amalgam harder and more perfect as a filling.

The time occupied in hardening varies very much with the different compounds—some are quick, others slow setting. Palladium sets during manipulation, and needs to be rapidly packed as soon as mixed. Other amalgams occupy only a few minutes, but most take several hours to become thoroughly hard. Amalgam stoppings must therefore, be shaped so as not to be injured whilst soft on closure of the teeth, and they must not be used in mastication until thoroughly hardened.

After amalgam has hardened it is of the utmost importance to file it level with the margins of the cavity, and to polish it. If this precaution be neglected overlapping portions of the filling in time break away and leave around a rough surface, which favours the adhesion of decomposing particles, and soon becomes the seat of carious action.

Filling with cements and gutta percha.—Preparation of cavities for plastic cements (the zinc compounds described) and for gutta percha does not in any essential respect differ from what is necessary with other materials; but the cements do not usually require retaining points, whilst gutta percha will rarely answer in any cavity where small retaining points are needed. The cements attach themselves with considerable tenacity to any surface which is rough and perfectly free

from moisture; they are the only fillings which can be securely fixed by mere adhesion to the walls of the cavity; they form perfectly water-tight stoppings, and are non-conductors of heat, and were it not for their perishable nature would perhaps constitute more perfect substitutes for the lost dental tissues than any other substance at present available.

Neither cements nor gutta percha answer well over chamfered external margins; they need enclosing within straight walls, particularly at the neck and cutting edges of the teeth. Cements and gutta percha require the exercise of such slight force in filling that they can be inserted in front teeth without sacrifice of thin enamel, against which it would be impossible to pack a metal stopping.

Cement stoppings are liable to waste at the surface, and the waste in many cases is due to slow solution, not to attrition. The waste from this cause varies very much in different mouths, no doubt in accordance with the conditions of the secretions. Neither these cements nor gutta percha are, however, fitted to long withstand the wear of mastication. Cements do not last well in situations where they are not constantly swept by the tongue, or otherwise guarded from prolonged contact with decomposing particles of food; in such situations gutta percha is much more durable.

In using gutta percha, pellets are softened on a metal tray over the flame of a spirit lamp, or by rapidly passing them to and fro over the flame, and packed into the cavity by means of heated instruments, great care being taken, while making the mass sufficiently soft, not to injure its texture by overheating or burning it.

In cavities not easily accessible, it is desirable not to add excess of this stopping as it is difficult and tedious afterwards to cut away superfluous portions. Any slight excess can be easily removed, and the surface rendered

smooth by wiping with a pellet of cotton wet with chloroform in which gutta percha is soluble. A small spatula having a thin fold of cotton round the end is useful to swab in this way surfaces between the teeth. External margins of a cavity which need it must be polished before insertion of gutta percha fillings. Cements do not last well at or below the level of the gum, and in a large number of cases it is good practice to fill the cavity at that part with gutta percha and complete the filling with cement.

With regard to choice of materials in cases ready for the reception of permanent fillings, some few remarks seem called for. There occur few cavities in which the insertion of a gold plug is impossible, and regarding the question from a *merely theoretical* point of view, it might be plausibly urged that the instances are rare in which use of any other material as a stopping intended to be permanent is justifiable. Practically, however, it is often not only justifiable, but necessary or expedient to employ other substances. In the first place the expense of gold-fillings puts them beyond the reach of the lower and of the poorest classes. Not only is the material more costly, but the expenditure of time and arduous labour far exceeds what is called for with other materials. In the next place, the operation of gold filling in large and difficult cavities is long, tedious, and frequently painful, and there are many patients who either cannot or will not submit to it. All being in readiness for the commencement of the operation—cavity prepared and saliva excluded—it is hardly possible construction of the largest and most elaborate amalgam filling—not including finishing and polishing—can occupy more than an

hour; such a case would require hours of close application if gold were used. Restlessness on the part of a patient adds much to the difficulties, and no doubt conduces often to failure under the hands even of the most skilful. A perfectly constructed amalgam or even cement stopping in a proper case must be better than an ill-consolidated one of gold, which although perhaps appearing solid on the surface, may yet allow of slow percolation of fluid around or through its substance. If there are any cases in which the use of gold seems imperative, these are cases of slight decay in teeth towards the front of the mouth. In such positions amalgams are very unsightly, they are apt to blacken on the surface in most mouths. Gutta-percha and cements in the small cavities in question do not answer well; besides they cannot be relied upon for many months, and need to be renewed over and over again in course of years on every sign of failure. Gold fillings once well done in such cases are extremely permanent, and are not more unsightly than others. In finishing them it is well in these situations to omit burnishing, and to leave the surface after fine smoothing with Arkansas stone; this renders them less conspicuous. Cases frequently present themselves, as for example, in neglected caries of a front tooth, in which a portion of the crown—the preservation of which, for the sake of the patient's appearance, is of great importance—is so extensively excavated as to form a mere thin shell of enamel, incapable of withstanding the force required in gold filling. In all instances in which the use of gold seems undesirable the substitute best adapted to the circumstances must be employed. Every practitioner sees numbers of fragile front teeth preserved for years by non-metallic cement stoppings, and such an apparently perishable material as gutta-percha. Among the poor, numbers of grinding teeth must be lost were there not available any such material,

at once so inexpensive and rapid of application as copper amalgam.*

Some points regarding permanent filling of teeth during childhood are discussed in a separate chapter.

* The student cannot be too strongly urged to thoroughly master the art of filling with gold ; this acquired, no other operation of dentistry can appear to him difficult or laborious.

EXPOSURE OF THE PULP. DISEASES OF THE PULP.

IN entering upon the study of diseases of the pulp it cannot be too constantly borne in mind that the pulp has not, like enamel and dentine, a peculiar pathology—totally differing in its phenomena from that of every other structure; and the morbid changes which occur in the pulp are in their nature essentially the same as similar inflammatory processes in other vascular tissues. It matters not whether an iris, a synovial membrane, a lung lobule, or a dental pulp be the seat of the morbid action, these processes are the same, modified only by the anatomical peculiarities of the part. In the case of the pulp there are to be considered such facts as that it is confined within the rigid walls of a chamber which allows neither of swelling, nor of the ready escape of exudations; that lesions of enamel and dentine are incapable of natural repair; and that the exposed surface does not tend to cicatrize, and therefore, if a pulp is to be preserved, it needs to be hermetically sealed beneath an artificial covering. It is probable that inflammation, to at least a small extent, always speedily supervenes upon opening of the pulp cavity by decay, and that it often precedes the actual exposure of the pulp. Any other analogous cavity, wounded, will speedily become inflamed if not kept aseptic by art. The condition of an exposed pulp might be, perhaps, broadly compared to

that of the tissues exposed in a wounded joint or in a compound fracture. Septic matter may slowly percolate to the pulp through an intervening layer of dentine; and organisms may proliferate along the fibrils through carious dentine, which to the naked eye appears healthy. A single minute particle of septic matter, inoculating the pulp, would probably originate inflammation. These facts explain the occurrence of inflammation even before decay has apparently quite reached the surface of the pulp. Dentine of inferior structure, containing much organic material and numerous imperfectly calcified spaces, would, of course, allow more easy passage for septic matter. In ill-made teeth the pulp cavity often extends in the crown—sometimes by a narrow process only—to a point abnormally near the surface. In such teeth numerous interglobular spaces are also commonly found in the dentine, and tissue readily permeable by fluids thus extends almost from immediately beneath the enamel to the pulp cavity. This accounts for the readiness with which inflammation often supervenes in the pulps of badly made six-year-old molars at an early stage of decay, or after excavation of a cavity, and insertion of a filling in childhood.

These considerations cannot be too steadily kept in view, together with the fact that as pathological processes in the pulp are in their essence the same as those occurring in all vascular structures, so treatment must be based on those general principles which form the common foundation of practice throughout the whole range of surgery.

Exposure of the Pulp.—In the last chapter the treatment of uncomplicated caries was discussed, and the precautions were described which ought to be taken to prevent the laying open of the central cavity of the tooth during excavation of carious tissue and preparation of the cavity for filling. In some cases this accident will

happen in consequence of abnormal extension of the chamber towards the surface.

The diagnosis of exposed pulp can be made certain only by careful examination with magnifying mouth-mirror and fine-pointed exploring probe. Pain, the only symptom, may not have occurred, and when existing it varies so much in amount and intensity in different patients, and under changing conditions in the same patient, that it is never safe to draw a conclusion from this symptom alone. In one case an exposed pulp, or even exposed dentine alone, will from the first give rise to frequent or continuous severe toothache; in another the pulp cavity may be fully open for months without the patient being aware of the fact. A pulp must be considered exposed not only when it is actually laid bare by complete disintegration of dentine, but also when it is covered merely by a disorganised layer of tissue permeable by fluids and micro-organisms. The practitioner, familiar as he ought to be with the internal anatomy of each class of tooth, and having in view the position and extent of the pulp in average examples, will in a vast number of cases in examining a carious cavity perceive at once whether decay has nearly approached the pulp; in many cases he will be tolerably sure there is exposure before he has actually verified the fact. The only cases in which doubt is likely to exist after excavation of the cavity are those in which the exposure is extremely small — sometimes it is almost microscopical, as when it occurs at the extremity of a minute projecting horn of the pulp chamber. It must be always recollected that the pulp chamber often extends abnormally near the surface, sometimes by narrow slit-like prolongations; and these occur most often in teeth with spinous crowns pinched in shape. Excavation and examination of a cavity where exposure of the pulp is suspected should be performed with caution and gentleness. To roughly plunge an

excavator or search-probe into a pulp inflicts a pang of exquisite pain, likely to be followed by a shock of greater intensity than is commonly recognised—a shock which may be seriously injurious to a delicate patient. If in a case of exposure the pulp be free from disease the operation of “capping” the pulp, followed by filling, may be performed. Such cases would be more particularly those in which accidental perforation of healthy dentine had occurred. The smaller the exposure the greater the likelihood that the pulp is not diseased. The healthiness of the pulp may be inferred from the history of the case, and the absence of the signs and symptoms of irritation and inflammation to be presently mentioned.

The object of capping an exposed pulp is to provide a covering which shall protect the sensitive structure from pressure and from changes of temperature. Various materials, such as quill, parchment, gold-beaters' skin, court-plaster and thin sheet cork, are used for the purpose by different operators. The smaller the opening into the pulp chamber the less solid the material composing the cap may be, and when the exposure is extremely slight a fragment of parchment paper or bibulous paper may answer the purpose. The smaller the exposure the easier it is to arrange and fix a cap in position. After excavation and preparation for filling the cavity should be freely washed out by means of a syringe with warm water containing a small quantity of carbolic acid (1 in 40), or another antiseptic of similar strength, and should then be dried. In this latter part of the operation in these cases neither alcohol nor hot-air syringe must be used. A piece of the chosen material having been cut of suitable shape and size is next carefully fixed by the plugging tweezers over the opening into the pulp cavity, resting upon the margins of the opening and closely in contact with, whilst at the same time not pressing upon, the subjacent pulp. Pressure

upon the pulp will surely excite inflammation. The cap being thus arranged, the filling of the tooth may be proceeded with. The success of the operation no doubt depends on the preservation of the pulp in a perfectly aseptic condition, and in the arrangement of a cap which while protecting shall not press upon the pulp. The cap and everything which is brought into contact with the pulp ought to be rendered aseptic by dipping in solution of carbolic acid (1 in 40); or, better, perchloride of mercury of equivalent strength, about 1 in 4,000; and the cavity should be repeatedly mopped out with the same solution.

Seeing that even in the best managed cases irritation, or even inflammation, of the pulp sometimes follows this operation, and that the danger of this mishap is increased after insertion of a metal plug, which requires great pressure in packing, besides being a rapid conductor of heat, it appears desirable to cover the cap and complete the filling with gutta-percha or with one of the cements which does not contain chloride of zinc, this substance having a very irritating effect upon the pulp. These fillings are non-conductors, can be inserted without pressure, and are readily to be removed on the occurrence of untoward symptoms. The first portion of the filling mixed very thin, mingled with a few fibres of cotton wool, can be conveyed as a very loose pellet to the cap and gently packed over its surface. A pulp slightly exposed may be covered with a thin paste of cement mixed with a small quantity of carbolic acid to render it aseptic, and over this more cement may be inserted. A cement filling may be trusted to endure at least for a few months; and within that time, if all go well, it may be excavated, with the exception of a protective layer over the depths of the cavity, and may be replaced by a more lasting material.

Such is the process of capping the pulp; but it must be

understood that the number of cases in which the operation can be performed with fair prospect of success is really very limited, and it will be found better practice in a vast majority to extirpate the pulp and fill the roots. In the first place it is very difficult to make perfectly certain that a pulp which has become exposed by caries, although apparently healthy and although perhaps remaining free from pain when covered by a dressing and temporary filling, may not have undergone pathological changes which prevent it from being brought into a healthy condition. Such a pulp if capped and sealed beneath a permanent filling may remain quiet for a short time but will probably sooner or later pass into a state of active disease. The cases are very exceptional in which exposure in a carious cavity is traumatic—that is due to a lesion of the pulp chamber through accidental perforation or removal of healthy dentine, and of course these cases would be the most favourable for capping. In the second place the operation to succeed calls for the most exquisite certainty in manipulation, so that owing either to the inaccessibility of the cavity or its unfavourable form, the difficulties in a great number of instances are almost insurmountable. The easiest cavity with exposure of pulp to deal with would be one in the centre of a molar crown with good solid walls around; perhaps the most difficult would be exemplified by one on the distal surface of the neck of a bicuspid. In a case like the latter the difficulties of manipulation are extreme, and with a cavity so shallow as it must be in that position it is all but impossible to fix a cap covered by a sufficient layer of non-conducting material over a living pulp. Similar difficulties will present themselves in numerous instances, and the operator must weigh the possibilities of failure under this treatment against those likely to occur under another.

Irritation of the Pulp. Etiology and Pathology.

—Dentine is intimately connected with the pulp by means of the fibrils which permeate it and endow it with sensibility. This connection renders intelligible the facts, first that influences may be communicated through the dentine to the pulp in consequence of disease or injury affecting that tissue; and secondly, that the condition termed irritation of the pulp occasionally is produced during the progress either of caries or of abrasion or erosion of the hard tissues long before the central chamber has been nearly approached or opened. When the pulp is insufficiently protected only by a thin layer of dentine it is of course liable to be acted upon more directly by external agencies.

Irritation of the pulp is pathologically nothing more than slight hyperæmia involving consequent pressure upon the nerve fibrils, and the condition may change to pronounced inflammatory action, especially in cases of caries, in which the dentine has displayed exalted sensibility, and in which metallic fillings, rapid conductors of changes of temperature, have been inserted without previous treatment, or without a non-conducting layer beneath. If a pulp could be examined during an attack of irritation it would be found the seat of increased vascularity, disappearing with the cessation of the attack. Pulp which have been subject to long-continued irritation probably become always more or less calcified. The newly-formed tissue is identical in structure with that already described as secondary dentine, and like it may be developed either in a layer organically united with the pre-existing tissue, or in isolated nodules scattered throughout the substance of the pulp. When a layer of secondary dentine becomes developed over the surface of a pulp it protects the latter structure, and where wasting of the hard tissues is in progress owing to attrition or erosion, it prevents exposure of the pulp, which would be otherwise in the end

surely brought about. Secondary dentine of this kind is often displayed in teeth which in course of years have been gradually ground down to the level of the pulp chamber by mastication. In such cases the pulp chamber when reached is often found perfectly obliterated at the surface by a mass of dentine united to the surrounding tissue and distinguishable only by its yellow colour and sometimes by its extra sensibility. In very rare cases a similar effect is produced during slowly advancing caries.

Diagnosis.—Irritation of the pulp is manifested by one symptom alone—namely, more or less dull aching pain, associated sometimes with a feeling of tenderness in the tooth, and with increased sensibility to changes of temperature, and it is not always easy to distinguish between this pain and the aching arising solely from exposed dentine. The absence of throbbing pain pathognomonic of inflammation of the pulp distinguishes irritation from the more serious condition. The increased sensibility to changes of temperature which most teeth display to some degree after insertion of large metallic stoppings, and which usually ceases gradually in time without untoward result, was described in the section on filling materials. Sympathetic toothache, or that occurring in a sound tooth in the neighbourhood of others the seat of advanced caries, has been ascribed to irritation of the pulp, but the pain in most of such instances is more probably neuralgic in character.

Treatment.—The treatment of irritation of the pulp varies somewhat in different cases, but the indications always are to remove the cause by protecting the exposed tissues from irritating influences, and to diminish the sensibility of the dentine. Where the dentine has become laid bare, owing to fracture of the tooth or to attrition or erosion and must remain ever after exposed, its sensibility may be destroyed by solid chloride of zinc. Saliva being excluded and the surface left moist

a small fragment of zinc chloride may be allowed to deliquesce upon it. Nitrate of silver acts equally well, but discolours the surface. Neither of these drugs must be used if the pulp be nearly exposed lest they penetrate and set up inflammation. The same effect may be more slowly produced by frequent friction of the surface with spirits of wine, or better by the occasional application of absolute alcohol, and with this treatment may be advantageously combined the use of tooth powders containing astringents such as tannin, with alkalies like carbonate of soda.

When irritation of the pulp exists in connection with caries—by far the most frequent cause—the permanent filling of the cavity is in the great majority of cases sufficient to effect a cure. Caution must, however, be exercised where abnormal sensibility of the dentine exists, and it must be remembered that in some few individuals the insertion of a metal filling in a cavity even of slight depth in the dentine is enough in time to excite acute inflammation of the pulp. The danger is necessarily in proportion with the extent of decay, and where the pulp is nearly approached it is well to shield it by a layer of non-conducting cement, in the manner which has been already described. The sealing up of a cavity for a few months with a non-conducting filling material, particularly cement, is often alone sufficient both to abate sensibility of the dentine and to cure irritation of the pulp. The cavity will have been of course excavated and prepared, and if then dried with absolute alcohol and the hot-air syringe the effect will be more sure.

Inflammation. Etiology, Pathology and Symptoms.—This is the commonest affection of the dental pulp. Its most frequent cause by far is caries which, having laid open the central chamber of the tooth, has exposed the sensitive structure within to the action of

the atmosphere and external irritants. It may arise from irritation communicated through the dentine when that tissue has been penetrated to a greater or less extent or may be excited by exposure to cold or frequent changes of temperature after insertion of a large metallic stopping. In rare cases it originates as an extension of inflammation which, having commenced in the periosteum, has involved the dental vessels and nerves in their passage to the pulp cavity through the foramina of the root. A blow on a sound tooth, loosening it or partly dislocating it, will occasionally be followed, sooner or later, after lapse of time, by acute inflammation of the pulp.

Inflammation of the pulp assumes either an acute or chronic form. Suppuration, ulceration, gangrene, or outgrowth of new tissue, or degeneration may result.

Pain is the most prominent symptom of acute inflammation of the pulp. It varies in amount according to the extent and intensity of the inflammatory action. It is more severe in some individuals than in others—in the young than in the old—and in all is increased by some derangements of the general health, of which pregnancy affords the most remarkable example. The greater pain in the young may be accounted for by the great size and vascularity of the pulp. The pulp becomes diminished in bulk by calcification and often undergoes degeneration as age advances. In pregnancy and in other disorders of health the pain frequently takes on the character of neuralgia—as will be explained in the chapter on that disease. At the commencement of an attack the pain is dull and aching, confined to the affected tooth, soon assuming a more intense lancinating or throbbing character—a character pathognomonic of this affection—and finally becoming almost intolerable, it appears to spread to the adjoining teeth and to the whole side of the head and face. The pain of this form

of toothache is more severe than arises in any other dental disease, and its severity is accounted for by the fact that the pulp, a highly vascular and nervous substance, is confined within the rigid walls of a chamber where swelling is impossible, and whence the inflammatory exudations cannot freely escape.

The tendency of acute inflammation of the pulp, which runs on unchecked, is to terminate in gangrene or sphacelus, but this termination is of most frequent occurrence when the pulp cavity is but slightly opened, or where the pulp is altogether confined beneath a layer of dentine, or beneath a filling. Under such circumstances, there being no room for swelling, and little or no escape for the inflammatory exudations, such tension or constriction is produced as soon causes death of the whole mass. The occurrence of death of the pulp may be recognized by the cessation of the more acute pain and by the insensibility of the dentine; whilst on examination the pulp is found devoid of sensation, softened and discoloured, and emitting a characteristic fetid odour. The entire tooth at the same time assumes a darker tint, and occasionally becomes stained to various hues in consequence of the diffusion of the colouring matter of the blood of the pulp through the dentine.

An attack of acute inflammation when the pulp is freely exposed rarely produces gangrene of the entire structure. The inflammation is sometimes limited to the exposed surface alone. In many cases, where extensive exposure permits it, swelling takes place, and the exudation having found vent the attack slowly subsides and assumes a chronic form, to be renewed again and again from time to time under the influence of increased irritation. An attack of acute inflammation is sometimes cut short by the patient's act of sucking the tooth. The air being exhausted from the cavity, the congested vessels are ruptured, bleeding takes place, and the tension is at once relieved.

If a pulp, the seat of acute inflammation, be examined recently after the extraction of a tooth the affected portion will be found deeply red in colour, the vessels being visibly injected, and small patches of extravasated blood will be observed upon the surface. Where swelling has been possible a red œdematous surface, studded with suppurating patches, may be found projecting into the carious cavity through the opening into the pulp chamber. Some amount of suppuration is almost always present, but it is generally confined to the exposed surface, and abscess in the substance of a pulp is rarely formed. The general characteristics of a pulp in which gangrene has supervened have been already mentioned. Close examination shows that the tissues in this condition exist sometimes as an ashy grey slough retaining the form of the pulp. In other cases the pulp tissues are reduced to a semi-fluid mass of a dirty reddish-grey or yellow colour. In this mass portions of the disintegrated walls of the blood-vessels, with numerous fat-cells interspersed, and disorganized nerve fibrils, may be traced by the microscope. There is a marked foul gangrenous odour. Pulps exposed for a considerable period to the atmosphere and external irritation, and having undergone repeated attacks of acute inflammation, although they may exhibit on the surface only congestion or very limited inflammation, often show on microscopical examination marked pathological changes in the deeper portions throughout their structure. These changes are similar to those found in all highly vascular and cellular structures the seat of inflammation. They very often partake of the character of fatty degeneration affecting both vessels and nerve fibrils. Caseous degeneration is sometimes recognizable, and atrophy is often well marked.

Diagnosis.—The diagnosis of acute inflammation rarely presents any difficulty. Careful examination must be performed, for the patient will often point to

the wrong tooth, and will frequently imagine that a broken-down neighbouring root—not the seat of active disease—is the cause of pain, which really arises in a cavity the existence of which had not been suspected. The character of the pain can hardly be mistaken, whilst in the vast majority of cases, there exists a carious cavity in which after excavation of the softened dentine the pulp is exposed and visible. Where the opening is extensive the surface of the pulp may be seen red and injected with blood or dotted with suppurating points, and it bleeds readily and freely if touched. From dental periostitis inflammation of the pulp may be distinguished by the fact that in that disease the earliest symptom is tenderness upon pressure, and slight elevation of the tooth in the socket, whilst, where the pulp is alone inflamed, it is not until a later stage of the affection—when, in fact, the inflammation has extended to the periosteum—that these symptoms are displayed. When the intimate connection of the vessels entering the pulp with those of the periosteum is considered, it will be obvious that some congestion of the periosteum or even periostitis must often accompany inflammation of the pulp; and care must be taken in diagnosis not to mistake the case for one of periodontitis alone.

A tooth the seat of acute inflammation of the pulp will always display some sensibility under percussion; but this will be comparatively slight until the whole pulp down to the apical foramen has become involved—and then the sensibility to percussion will not be very great. Percussion is performed by smartly tapping the surface or cutting edge of the crown in the direction of the root with a steel instrument, such as the handle of an excavator. Pressure on the tooth causes little pain unless the exposed pulp is pressed upon, and then very often a momentary pang of extreme severity is inflicted. On the

other hand, periostitis, by the time it had advanced to produce as much pain as accompanies acute inflammation of the pulp, would have rendered the tooth exquisitely sensitive to the least touch and so raised in the socket that the jaws could not be closed without great pain.

Treatment.—The treatment of acute inflammation of the pulp must be modified in accordance with the circumstances of the case and the phase which the process has assumed. In some instances the extraction of the tooth is called for; in rare cases the reduction of the inflammation and the conservation of the complete vitality of the tooth may be reasonably aimed at; whilst in a third group, forming the majority of cases, extirpation of the pulp and root filling is the proper treatment.

The extraction of the tooth is most frequently required in childhood, when the first permanent molar is the seat of disease. At this period an attack of acute inflammation usually runs a rapid course, the pain becomes excruciating, the inflammation quickly spreads to the periosteum, and the tooth becomes so exquisitely sensitive to the touch that manipulation of any kind is unbearable. The rapid spread of the inflammation in these cases is accounted for by the yet incomplete condition of the roots, the apices of which are represented by a portion of uncalcified pulp, freely communicating with the alveolar tissues. This condition in early childhood renders inadmissible any attempt at the destruction of the pulp by means of escharotics in the manner presently to be described. The advantages previously referred to, which in many cases accrue from the extraction of the first permanent molars (the teeth by far the most frequently the seat of caries in children), render their preservation inexpedient after the appearance of the second molars. In the temporary teeth, the roots of which are undergoing absorption, the course of acute inflammation of the pulp closely resembles that which takes place in the

permanent teeth at the same age. The treatment of these cases is more fully entered into in a separate section.

In the case of children, as in every other case of acute inflammation of the pulp in its earlier stages, the attack may be often cut short by removing the cause. With this view the cavity should be excavated, and in doing this with proper care it is possible to avoid pressing upon the pulp and inflicting severe suffering upon the patient. Spoon-bladed excavators, thoroughly sharp, are the best for this purpose. With them softened dentine may be scooped away without danger of the instrument plunging into the pulp. The sensibility is too extreme to allow the use of drills in the immediate vicinity of the inflamed surface. Carbolic acid will help to diminish the sensibility, and a minute quantity may be carried in at intervals during excavation on the blade of a spoon excavator and applied to the exposed surface.

Where a stopping is present it must either be perforated with a sufficiently large opening or entirely removed. This is best accomplished with sharp spear-pointed drills. If of amalgam the stopping may be the sooner broken up if as the drill proceeds a small quantity of mercury conveyed in the form of semi-liquid amalgam be applied to the surface and worked in with the drill. The mercury helps to disintegrate the mass.

Foreign particles pressing upon the pulp may be dislodged by the excavator, aided by the syringe and warm water, the free use of which should be continued to encourage bleeding from the exposed surface, should it occur. Great care being taken not to cause pressure, the cavity may be then lightly filled with a temporary plug of cotton wool saturated with mastic solution, over an antiseptic dressing such as a pellet of wool moistened with equal parts of carbolic acid and eucalyptus oil, oil of cloves, or eucalyptus oil and iodo; and external

irritation being thus guarded against, the inflammation will often subside. The dressing and temporary filling may be renewed at intervals of a few days. When all symptoms have disappeared—when pain and discharge have ceased and the exposed pulp surface is no longer red—the operation of capping the now healthy pulp and filling the tooth may be proceeded with. The rare cases favourable for this treatment are those in which the periosteum is unaffected, and in which the pulp fully retains its vitality, not having been partly destroyed by gangrene or ulceration resulting from former attacks of inflammation, and where the difficulties spoken of in the section on capping the pulp do not exist.

In acute inflammation of pulp following upon insertion of a permanent filling, as sometimes happens after capping, or when the pulp has been protected by but a thin layer of dentine, the tooth often passes in a few hours into a condition of such exquisite tenderness as to make the removal of the filling unbearable. In such cases it is good practice to drill a small hole through the tooth or stopping into the pulp cavity. This gives vent to the inflammatory effusions and relieves the pain. The filling being removed later the pulp can be dealt with as circumstances direct. This operation is also called for in those cases mentioned above, in which acute inflammation of the pulp occurs after injury—such as a blow—to teeth in which no cavity exists. In these cases, there being absolutely no vent for inflammatory exudation, the pulp will often, after a short course of the disease, be found sphacelated on opening the tooth.

From what has been urged in previous paragraphs it will be evident that in the vast majority of cases of acute inflammation preservation of the pulp is contra-indicated. The treatment in most cases consists in destroying its vitality by means of arsenious acid, in extirpating it, and afterwards permanently filling the chamber and

root canals as well as the external cavity of decay. A very minute quantity—less than $\frac{1}{20}$ th of a grain of the escharotic—is sufficient to destroy the vitality of the pulp of the largest molar. The arsenic for this purpose is reduced by trituration to an impalpable powder. The mode of applying it is as follows. The cavity having been excavated and dried, the arsenic is carried to the exposed surface of the pulp by means of a fragment of amadou or of bibulous paper or a few filaments of cotton wool rolled into a tiny pellet saturated with carbolic acid, and is then at once sealed in by a filling. It is important in the first place to ensure access as free as possible to the pulp by cutting away dentine when necessary; in the second place to apply sufficient arsenic to devitalize the pulp, not to set up merely inflammation. If the arsenic does not gain ready access or if too small a quantity be applied, the effect stops short at causing inflammation, and this in some cases extending to the periosteum leads to suppuration and loss of the tooth. When effectually applied arsenic rarely causes much suffering. If pain continue after a few hours the temporary stopping should be removed, and a renewed careful application ought to be made. The action of arsenic being usually rapid, the treatment of clearing the cavity and applying it often indeed serves to arrest almost instantly the suffering arising from an aggravated attack of inflammation of the pulp.

There are some disadvantages attending the use of wool with mastic solution or gutta-percha or other ordinary temporary stopping as a covering for the escharotic. With them it is sometimes difficult to avoid pressure upon the exposed pulp, an accident which is attended with great pain, whilst the liquid constituents of some fillings tend to wash away the pulp-destroying dose. These disadvantages are overcome by the use of bees'-wax as a temporary filling.

Small pieces of wax are carried by plugging tweezers to the cavity, and by means of a small heated spatula melted within the orifice, so as to effectually exclude saliva for a few hours. The spatula should have a wooden handle and a short metal blade, so as to avoid burning the patient's lips. Care must be taken to prevent arsenic escaping from the cavity on to the mucous membrane of the gum or cheek. If this occur a very painful ulcer may be caused. The accident is most likely to happen in cavities at the neck of the tooth and on the buccal aspect. Extra care must be taken in these cases to effectually seal the cavity, and to press away by wedging or by previous treatment the fold of swollen gum which so often is found encroaching upon the orifice.

The effects of arsenic upon the pulp are stated by Dr. Arkövy (1) to be as follows:-- It first produces hyperæmia followed by thrombosis; it is then taken up by the vessels, producing granular degeneration of their contents, and finally shrinkage and collapse of the vessel walls. The connective tissue and odontoblasts are unaltered, the other cells swell to three or four times their natural size. The axis cylinders of the nerves undergo granular degeneration. Arsenic has practically no effect upon dentine.

The temporary filling may be removed in about twenty-four hours, when a cautious examination may be made. It is only in a proportion of cases and particularly in single fanged teeth that application of arsenic is followed at once by total destruction of vitality and sensibility throughout the pulp. In most cases however the sensibility is so diminished that extirpation can be easily borne.

Sometimes apparent sensibility of the whole pulp is really due to a small shred in the depths of the canal which has escaped the action of the arsenic—pain arising

when pressure or traction is exercised at the surface. It happens, however, occasionally that in consequence of the smallness of the opening into the pulp cavity, or of the presence of nodules of secondary dentine preventing the free access of the escharotic, the deeper portion of the pulp will be found to retain its vitality. In these cases the opening into the chamber can be enlarged and the secondary nodules removed with the drill and a second effectual application of arsenic can be made.

The devitalization of the pulp of single rooted teeth—incisors and canines—can be effected instantaneously by means of instruments alone, but the pain is extreme unless the pulp has been previously destroyed to a great extent by disease when it is not so severe as might be supposed. The operation is performed by thrusting rapidly a thin flexible steel bristle to the apex of the canal, and rotating it so as to sever at once the vascular and nervous connections of the pulp. An anæsthetic (nitrous oxide answers well) should be given if great pain is anticipated.

It is not desirable to carry arsenic into the depths of root canals. Minute shreds of pulp may be destroyed by carbolic acid. Throughout the whole process of extirpation of a recent pulp carbolic acid is useful. It forms at once a local anæsthetic, an escharotic and an antiseptic. It can be conveyed on a pellet of cotton or carried in the blade of a spoon-shaped excavator to the pulp cavity and can then be gradually worked into the canals on the nerve extracting instruments or on a bristle with a few fibres of cotton. The properties which particularly fit carbolic acid for this operation render it less suitable than perchloride of mercury and some other antiseptics in procedures where escharotic action is not required.

Extirpation of the dead pulp of teeth with single and nearly straight canals is mostly a simple procedure, but

difficulties present themselves and often become great in teeth with several roots. A large proportion of such teeth present irregularities in the number of the roots ; both upper and lower molars often have extra roots, whilst the form and the size and shape of the canals vary extremely. The first step consists in cutting away the margins of the cavity of decay and laying open the pulp chamber so as to allow access to the canals and to permit passage of nerve extractors without great bending. The pulp chamber, which often contains nodules of secondary dentine, will be easily cleared by burs and excavators, and the *débris* having been syringed away the number, position, and direction of the root canals may be discovered. The cavity may next be dried, and moisture being excluded nerve extractors may be brought into use. The best extractors for general use are Donaldson's bristles. They consist of extremely fine, highly-tempered steel wire, having a single barb at the extremity. Others are made with a series of barbs, and these are most useful in the larger canals. These instruments are illustrated in figs. 153, 154, 155. In using nerve extractors the aim should be to remove the contents of each canal intact. This is to be done by passing the bristle to the apex of the canal, and rotating it so as to entangle and withdraw the mass ; but pulps can often only be removed piecemeal. Throughout the operation antiseptic precautions must be taken. Carbolic acid may be used so long as the pulp displays any sensibility ; afterwards perchloride of mercury in spirit—a strength of 1 in 1,000—may be used, and this can be pumped into the canals from time to time by means of a minute wisp of cotton on a bristle.

It is not necessary or desirable to use the drill to clear canals unless they are obstructed by secondary dentine or unless it be impossible otherwise to make certain the pulp is entirely removed. This is sometimes


the case where canals are very small in calibre and tortuous in direction, but a canal which will let pass the smallest bristle need not be drilled as a rule. Drills with thin flexible shafts and flame-shaped points are most useful for this purpose. They are depicted in fig. 156.

FIG. 153.

FIG. 154.

FIG. 155.

FIG. 156.



In neglected cases in which canals have been allowed to retain putrid contents long after death of the pulps—cases which will be presently discussed—it may be more commonly necessary to use the drill, but where the pulp is freshly destroyed deep drilling is to be avoided. It is, however, usually desirable to enlarge to a slight depth the orifices of the canals in the pulp chamber. To drill the whole length of a canal is a difficult operation, particularly in a distorted root. In an attempt to carry a

drill beyond a point where the canal makes a bend there is always great danger of perforating the root, and in all cases there is danger of wounding the alveolus through the apical foramen and setting up inflammation; and then there is also danger of breaking the drill, which must be of necessity fine, flexible and delicate. Neither a broken drill nor a nerve extractor nor other instrument must ever be allowed to remain. If they cannot be withdrawn they must be destroyed by tincture of iodine. The tincture must be worked in and a temporary plug inserted to give time for corrosive action upon the steel. Throughout the operation of drilling the instrument on each application must be dipped into carbolic acid or some other antiseptic.

Some slight hæmorrhage from the canal frequently follows the extraction of the pulp. When this has ceased the filling of the canals may be proceeded with. The canals, after cleansing by the syringe and cold water, should be dried. Solution of perchloride of mercury (1 in 1,000) in either absolute alcohol or strong rectified spirit should be used in this part of the process. Shreds of cotton wool soaked in the fluid should be passed into each root and allowed to remain for a few moments, evaporation being hastened by the hot-air syringe. By this means not only are the canals more thoroughly dried than is possible by any other means, but any minute particle of soft tissue which has escaped the nerve-extracting instruments is shrivelled and sterilised by the spirit and antiseptic, and is left in a condition in which after insertion of the filling decomposition is impossible.

For dressing and filling roots steel (Donaldson's pattern) bristles are required, and fine wire root-pluggers of different thicknesses. Some of the bristles have barbed points; some are only slightly roughened at the end. For mopping out canals a few fibres of cotton are

used with either a barbed or roughened bristle. When the cotton is to be left in the canal as a dressing or stopping a rough-ended bristle is used. The end with a few filaments of cotton is taken between the thumb and fore-finger, and with a twirl the cotton is wrapped round the bristle. The cotton is then dipped into the fluid which is to be conveyed into the canal, and then may be made to take up from a slab a small portion of iodoform or of tannin, or such like solid ingredients of the dressing. The loaded bristle is then passed along the root canal. To disengage the dressing the bristle is gently rotated in the direction the reverse of that which was used to wrap the cotton fibres round. To pack the fibres more tightly when they are to remain as a permanent filling the bristle is used as a plugger, or when the calibre of the canal admits it a stouter root plugger is substituted. To withdraw a cotton dressing a barbed bristle is of course used.

Various substances are used for filling roots. The best materials are such as are antiseptic in their properties, are non-conductors of heat, can be applied without enlarging the canals and without other manipulation likely to set up irritation, and can be easily removed should it be necessary. The objection to fillings of a perishable nature, which holds good in ordinary situations, does not apply in root filling where the material remains buried deeply beneath a plug and protected from the action of decomposing agencies.

There exists little if any difference of opinion as to the principles upon which permanent filling of roots ought to be based. Cotton wool saturated with antiseptic is one of the best materials for the purpose. The antiseptic may be either perchloride of mercury, iodoform, iodol, or hydronaphthol, or similar agents. The perchloride is perhaps the best. In all dental operations where antiseptic effects alone are needed—as throughout

the process of fang filling—perchloride of mercury, the most potent of all agents, possesses great advantages. The objections which limit the use of this drug in general surgery do not apply to dentistry, for practically the danger of its absorption or passage into the system in any poisonous quantity does not exist. Not more than a few drops of solution is used on any single occasion—a quantity which, if absorbed or swallowed, would not be harmful; but with ordinary care no more than an infinitesimal portion of the minute quantity used—if any—could possibly pass into the system.

The special value of the perchloride is due to the fact that one thorough application of a solution is enough to destroy micro-organisms, to sterilise organic matter, and put a stop at once to putrefaction and fermentation. It is not, like carbolic acid, an escharotic, and being colourless and odourless it does not disguise the presence of discharges. A 1 per cent. solution in absolute alcohol may be used for permanent root fillings. Shred after shred of absorbent cotton wet with the fluid is conveyed into the depths of the canal and packed as tightly as possible. The hot-air syringe is used at intervals to hasten evaporation of the fluid. Hydronaphthol in alcohol (1 in 20) may be used in the same way. On evaporation of the spirit these antiseptics remain mingled with the wool and deposited on the walls of the canal and perhaps in the dentinal tubes. The last third or quarter of the canal is filled with cement. The cement is mixed thin, and is best conveyed to the canal mingled with a few fibres of cotton wool.

In using iodol or iodoform (either of which may be used in the permanent filling of roots, alone or in conjunction with perchloride), each shred of cotton, wet with either alcohol or chloroform, is made to take up a portion of the solid from a slab before conveyance to the canal.

Where the canals are large and accessible, as in incisors and canines, they may be filled throughout with cement and cotton fibres. Cements are, however, apt to be pumped through the apical foramen, and if this happens—particularly if the cement be an oxychloride of zinc compound—periostitis will probably be excited. A paste composed of oxide of zinc and carbolic acid with cotton wool is used by some operators. Others employ shellac. This is passed into the canals in fine filaments previously prepared, and is melted *in situ* by means of heated wire, or it may be rendered fluid by introduction into the canal of a minute quantity of absolute alcohol.

Sufficiently long and wide experience warrants me in affirming that evil effects are least to be feared and the best and most permanent results are achieved by the use of antiseptic cotton wool for filling the deeper parts of canals; and this is, I believe, due in some degree to the non-conducting properties of the material, but most of all to the production and maintenance of a more perfectly aseptic condition than can be achieved by any other plan.

When the canals are filled and sealed the insertion of a permanent stopping may be proceeded with. It is, however, good practice in any case and imperative where untoward symptoms are feared, to insert a non-metallic filling and leave it for a few months, so as to guard the tooth for a time from sudden changes of temperature.

Filling fangs with gold, which was once considered the best practice, is a more laborious operation and presents no advantages over that just described. It is often necessary to open up the canals to a considerable extent before plugging instruments to carry in the gold can be made to enter, and it is difficult to maintain an aseptic condition. Gold is, moreover, a rapid conductor of heat; it is extremely difficult to remove when once

packed, and its use in fang filling is often followed by periostitis, a result which very rarely follows the use of antiseptic plugs such as those described and now most commonly used. Similar objections apply to amalgams.

It is only in occasional cases that the whole process of fang and cavity filling will be attempted at one sitting. Where several roots of one tooth are being dealt with it will often happen that one or other of the canals need more prolonged treatment than the rest. During the intervals between visits or in any case where it is desired to bring about and maintain an aseptic condition the canals, after treatment with alcoholic solution of perchloride and drying with hot air, may be filled with shreds of absorbent cotton charged with iodoform or iodol. The cotton fibres, moistened with either absolute alcohol or chloroform, are carried down the canals lightly twisted round the point of a steel bristle; and the fluid being driven off by hot air, the cavity is sealed with a temporary plug.

Chronic inflammation of the pulp arises from the same causes which originate acute inflammation, by far the most common being exposure of the pulp by caries. It often remains as a sequel to an acute attack, and again assumes a more active character from time to time under the influence of increased irritation.

The pain, usually of a dull aching or gnawing kind, is less severe than in acute inflammation, it may be almost altogether absent if there be a free vent for the discharges, or may be manifested at a distance in the form of neuralgia. The exposed surface is red and swollen, and pours out a thin puriform or serous secretion having a characteristic phosphatic odour. On examination the redness, which is due to injection with blood, is found to be confined to the superficial portion alone of the pulp. This condition may resolve itself into a process of ulceration under which the pulp gradually disappears; in

other cases degeneration and atrophy ensue, and effect complete destruction of the pulp, often with the occurrence of little or no pain.

In a certain number of instances chronic inflammation gives rise to the development of new tissue in the form of polypus of the pulp. This occurs mostly in young subjects, in teeth the crowns of which are extensively excavated by caries and with the pulp fully exposed. The new growth consists of a rounded fleshy mass, red or bluish-red in colour, occupying or projecting from the cavity of decay, and may attain a size between that of a small pea and a Spanish nut. It is usually covered with an offensive muco-purulent secretion. It bleeds readily if wounded, but displays but little sensibility. Examination shows that polypus is united with the pulp, from which it springs, and that it consists of a mass of rounded and spindle-shaped cells, supported by a small quantity of fibrous tissue, and provided with numerous comparatively large blood-vessels.

Treatment.—In cases of uncomplicated chronic inflammation of the pulp in which there is neither an outgrowth of new tissue (polypus), nor loss of substance from ulceration or gangrene, nor periostitis of marked extent, it is sometimes recommended that an attempt should be made to bring the structure into a healthy condition. With this object the cavity having been excavated and antiseptically cleansed, a dressing of carbolic acid on cotton wool may be lightly applied to the pulp, covered by a temporary filling. Later this may be followed by similar treatment with eucalyptus oil, the dressing being renewed at intervals of a day or two until all symptoms of inflammation have subsided. The operation of capping the pulp and filling the carious cavity must then be carried out in the manner already described.

I am strongly of opinion that with very rare if any

exceptions, cases of chronic inflammation are best treated by destruction and extirpation of the pulp and fang filling. This is to be carried out exactly by the same means and methods as prescribed for acute inflammation.

In cases in which there has occurred an outgrowth of new tissue sufficient to constitute a polypus, the extraction of the tooth is the sole treatment that can be recommended.

It frequently happens that after repeated attacks of acute or long-continued chronic inflammation the pulp is entirely destroyed. On examination the canals are sometimes found to contain the gangrenous pulp entire—an ashy grey-coloured, more or less coherent mass with the characteristic odour, or merely a semi-fluid mass of decomposing tissues. In other instances the pulp cavity and canals may contain only fluid and foreign particles, all trace of pulp tissue having disappeared. The existence of these different conditions is governed by the length of time which has elapsed since the death of the pulp. Very often years may have passed before the case comes for treatment. These cases are sometimes classed as “pulpless teeth.”

The treatment in these cases consists in thoroughly clearing out the canals, and in disinfecting them by the application of antiseptic agents.

These are the cases in which the use of the drill in the canals is more called for than after removal of a recent pulp. The dentine of the pulp chamber and canal walls will be, in most cases, to a greater or less degree softened and saturated with putrid fluid. In the pulp cavity free excavation may usually with advantage always be carried out, but the dangers attending the use of the drill in root canals (referred to on a previous page) must be kept in view. Wherever a bristle carrying a few shreds of wool can be made to pass, drilling is not indispensable. Free

swabbing with solution of perchloride in absolute alcohol will sterilise and render perfectly aseptic the putrid walls of the canals. Absolute alcohol completely abstracts water from the tissue and renders it eager to absorb the antiseptic fluid when next applied; and there can be little doubt the fluid passes into the substance of the dentine, and renders even that which is partly softened safe from putrefactive changes when shut in by stopping, and guarded from further access of external agents.

The utmost pains must be taken in manipulation not to force septic matter through the apical foramen or acute periostitis will probably supervene. The pulp chamber being cleared may be repeatedly well swabbed with antiseptic spirit. This with the hot-air syringe will cause speedy abstraction of the moisture from the root canals. The antiseptic may then be gradually pumped into the canals. By the time the depths are approached remaining organic *débris* will have been desiccated and sterilised, and the roots may be safely explored throughout and cleared of solid particles with barbed nerve extractors.

Thorough washing out of the canals with water with the special fine-nozzled syringe made for this purpose may be practised to ensure perfect removal of all *débris* after sterilisation; but when this is once effected the use of water is better not repeated unless charged with an antiseptic. In the great majority of cases of dead pulp or "pulpless teeth" the safest practice after thorough cleansing and disinfecting in the manner described is to dress the roots antiseptically at intervals of a few days to a week or so until all danger of untoward symptoms such as periostitis seems past; but in some instances in which the death of the pulp has been comparatively recent and in which decomposition of the canal walls is not present permanent filling may be performed without delay. It is, however, better to exercise

too much than too little caution. Root dressings may be composed of shreds of wool with perchloride or with iodol or eucalyptus oil or with these two latter combined. A few fibres of wool are lightly twisted round the non-barbed but roughened end of a bristle, and charged with the antiseptic are carried down the root. The cotton is then detached by reversing the turn of the bristle, and shred after shred is packed in the same way. A temporary filling easy of removal is then inserted. At each dressing the canals can be treated with absolute alcohol and perchloride. Although perchloride of mercury is the most powerful of antiseptics there are—it has been already remarked—a considerable number of drugs with similar properties such as iodoform, iodol and hydronaphthol of which the operator has choice. It is necessary to bear in mind the distinction between agents like the perchloride and carbolic acid and hydronaphthol—which are true germicides—and others like eucalyptus oil and boracic acid, which cannot be relied upon to destroy micro-organic life. The first class must be used to sterilise; the second may be employed to maintain a part in the aseptic condition.

For full account of other antiseptics used in surgery the student must turn to works on *materia medica*. The principles of their employment are the same in dentistry as in general surgery; but owing to the minute quantity necessary and to the non-absorbent qualities of dentine forming the pulp chamber more poisonous substances or stronger solutions may be used in treatment of teeth than could be applied to wounds of vascular structures.

The general principles which guide the operation of filling do not vary in insertion of permanent stoppings after extirpation of the pulp and root-plugging. It may be, however, useful to illustrate a typical case. Such a case is shown in figs. 157, 158, 159, which represent a second lower molar with two-thirds of the crown destroyed by

caries. The walls, which for a contour stopping are needed to stand considerable strain, must be cut back

FIG. 157.

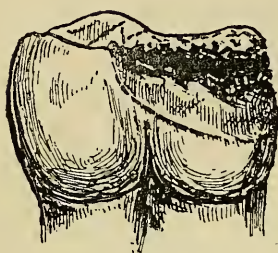
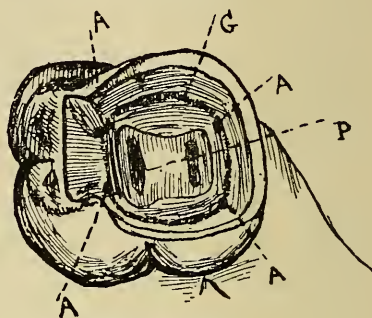
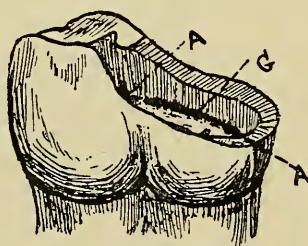


FIG. 158.



freely, and this should be done preliminary to clearing and filling the root canals. Figs. 158 and 159 show the roots filled and the cavity ready for a cohesive gold

FIG. 159.



filling. A A A A are retaining points, G is an uncut groove running round the cavity and connecting the retaining points, and P (fig. 158) shows the root canals. The retaining points would not be needed for an amalgam filling. It is a good plan in most cases, and particularly where very secure anchorage is called for, to commence a filling in the external portions of the root canals and in the pulp chamber. Teeth more broken down than in this example may often be restored by the operation of "crowning," which is described in a later chapter.

DISEASES OF THE DENTAL PERIOSTEUM.
 PERIODONTITIS. ALVEOLAR ABSCESS.
 PERIOSTITIS AND NECROSIS OF THE
 MAXILLÆ. DENTAL EXOSTOSIS. NECRO-
 SIS. ABSORPTION OF ROOTS OF PERMA-
 NENT TEETH. ABSORPTION OF ALVEOLI.
 PYORRHOEA ALVEOLARIS.

IN entering upon the subject of disease affecting the vascular covering of the teeth—the periosteum—and the structures with which it is connected, it is desirable to bear in mind considerations similar to those advanced at the opening of the chapter on diseases of the pulp, namely—that the pathology of these parts is in its nature the same as that of all similar vascular tissues, and the principles which guide treatment are therefore alike. Modifications which are called for in treatment in consequence of anatomical peculiarities of the parts, will be noted in their proper places. It may be remembered that cement is identical in structure with bone, but when normal in development forms only a thin avascular layer. It is intimately united with the dentine which it covers. The absence of vessels within the tissue accounts for the fact that when necrosis occurs the dead tissue, although it may be gradually removed by absorption through the vessels on its surface, does not like bone become detached to form an exfoliation or a sequestrum. This instance exemplifies pathological variation due to anatomical conditions.

Dental Periostitis. Etiology.—Inflammation of the dental periosteum (sometimes termed periodontitis) may

be confined to one tooth, or may involve several or all the teeth of each jaw. The former variety is that most frequently met with in dental practice, the commonest cause being extension of inflammation from a diseased dental pulp. Periostitis also often arises after the filling of a cavity in which portions of suppurating or decomposing pulp have been improperly left, and in which matter, not finding escape, penetrates to the depths of the root canals, reaches the periosteum and sets up irritation. Periostitis may extend from one tooth to those adjacent through the periosteum of the jaw, or may spread from the gums, inflammation of which, indeed, if at all extensive, always in some degree involves the periosteum. Periostitis may result from mechanical injuries of the teeth or alveoli, it may be caused by the continued inhalation of fumes of phosphorus, or may arise from rheumatism, syphilis or scrofula, or from cold, or from the effects of mercury upon the system (when however it is an extension from the gums), or from debility; whilst finally certain cases of general subacute or chronic periostitis, associated with absorption of the alveoli (*pyorrhœa alveolaris*), frequently present themselves, in which the cause can rarely be satisfactorily ascertained. Periostitis due to constitutional causes usually affects at once several or all of the teeth of one or both jaws.

Acute Periodontitis. Symptoms.—The symptoms of acute dental periostitis commence with a feeling of uneasiness in the affected tooth. In this condition the patient very often finds momentary relief by steadily biting on the affected tooth, no doubt through the emptying of the vessels which the pressure temporarily effects. The uneasiness increases in the course of a few hours into aching pain, accompanied by tenderness of the tooth, especially when pressed into the socket as in mastication. If allowed to continue these symptoms increase in inten-

sity. The pain becomes severe, and the sensibility of the tooth extreme; and the tooth is felt evidently protruded slightly from the alveolus, and loosened owing to swelling of the lining membrane. The neighbouring teeth become tender, the inflammation involves the gum and spreads thence to the cheek, which becomes swollen and œdematous—the œdema often extending to the palate and eyelid when an upper tooth is the centre of the disease. When lower wisdom teeth or molars are the seat of the disease, closures of the jaw, as described on an earlier page (under the heading "Impaction of Wisdom Teeth"), sometimes supervenes, and in most cases the movement of the jaw is more or less impeded by the inflammatory swelling. With these symptoms more or less febrile disturbance is associated in accordance with the extent of the inflammation and the condition of the patient's general health. The tongue is foul, the breath tainted, the skin is hot, and there are thirst and headache. At this stage suppuration takes place, pus is formed, points and finds its way to the surface of the gum, and this is followed at once by diminution of the pain and by slow subsidence of all the symptoms. The acute stage of such an attack, uninfluenced by treatment, usually lasts from three to ten days. Perfect recovery may take place, the inflammation may remain chronic, it may end in partial or complete necrosis of the tooth, or spreading to the periosteum of the jaw, may cause necrosis of bone to a greater or less extent.

Pathology.—The pathology of periodontitis is essentially the same as that of inflammation of other bone surfaces. There is first congestion, soon followed by exudation, which at the outset is composed of leucocytes and liquor sanguinis. This soon becomes replaced by pus, and as the fluid accumulates beneath the membrane the cement becomes gradually stripped. In this stage there is imminent danger that necrosis may ensue unless

the fluid find vent, and the periosteum again become attached to the cement. It is believed that in some cases, after partial destruction of the membrane, new periosteum may be formed as recovery takes place from granulation tissue.

On the extraction of a tooth the seat of acute periostitis, the periosteum in the early stage of the attack is found thickened, red, and injected; later it presents on its surface patches of lymph, and when pus has formed it is not uncommon to find attached to the extremity of the fang a distinct sac containing matter. This arises from suppuration of the internal layer of the periosteum, which becomes detached from the cement, thickened and dilated, and filled with purulent matter, as just described.

Diagnosis.—In diagnosis of acute dental periostitis there is not much room for mistake. The only disease with which it is likely to be confounded is inflammation of the pulp, and the main symptoms which differentiate this having been given in the last chapter, need not be repeated here. In inflammation of the pulp the seat of trouble lies within the tooth; in periostitis it is without. In the former general tenderness of the whole tooth to the touch does not appear until towards the end of an attack; in the latter it begins with the onset of inflammation. The two conditions commonly co-exist, and it has already been pointed out that acute inflammation of the pulp when extensive is usually associated with at least congestion of the dental periosteum—congestion which, if neglected, often runs on to inflammation.

Treatment.—The treatment of acute periodontitis must be governed by the cause of the disease and other circumstances, and although the great majority of cases yield to active measures, the question of extraction will sometimes arise. Teeth or roots which have been long the seat of chronic inflammation, or alveolar abscess, or which are extensively necrosed or are loose owing

to absorption of their alveoli, may be often extracted without hesitation on the appearance of an attack of acute periostitis, whilst it is sometimes necessary to sacrifice a tooth to cut short an attack and avert the dangers of suppuration. In cases of closure of the jaws immediate extraction of the tooth will also be frequently called for.

If extraction be deemed desirable there need be no hesitation in performing the operation at any stage of the affection. There is an error on this subject, which not only prevails to some extent among the more intelligent classes of the public but still lingers among some practitioners of surgery. The belief is that it is both difficult and dangerous to remove a tooth when great swelling and inflammation of the soft parts are present. There are, however, no grounds whatever for such belief. A tooth the seat of acute periostitis is always loose and protruding from the socket, and there are, therefore, no special difficulties attending its extraction. No harm can possibly arise from the operation, whilst, on the contrary, in cases in which it is called for, much good must follow, since the tooth constitutes the sole cause of the mischief. Its removal is usually enough to give vent to pent-up matter, to speedily relieve pain and to put an end to all urgent symptoms. On the other hand, it must not be forgotten that to save even truncated teeth or broken-down roots may be worth much trouble to the patient; brought into a healthy state and filled, or with artificial crowns attached many roots which formerly would have been thought beyond treatment, may now be permanently preserved in a useful condition.

If it be resolved to endeavour to save the tooth, and the case is seen in the earlier stages, attention must first be directed to the pulp chamber and root canals. It will often be found, where greater part of the pulp is dead, that a small portion retains its vitality in the

depths of a root—sometimes in one only of the roots of a molar—and from this portion of living tissue inflammation has extended to the periosteum. These living portions must be destroyed and removed; they always perish if the disease progress; and a living portion of pulp is very rarely found within a tooth in advanced periodontitis. Where gangrenous pulp is present and in “pulpless teeth” the canals must be cleared and brought into an aseptic condition by the methods described in earlier pages, the utmost care being exercised to avoid forcing septic matter through apical foramina. The pulp chamber and roots may then be dressed antiseptically and the orifice of the cavity of decay sealed with a temporary stopping. The dressing should consist of wool moistened with eucalyptus oil or weak solution of perchloride of mercury, and it should be loosely packed so as not to obstruct flow of discharge. Wool saturated with perchloride and dried forms a capital dressing. It is prepared in this form by manufacturers. Or a dressing with chloroform or absolute alcohol and iodol, which is easily dried on insertion by the hot-air syringe, may be used. The gum over the root may be painted with a mixture of equal parts of tinctures of iodine and aconite, or there may be applied capsicum plasters, such as are now prepared for this purpose.* If the tooth has been previously stopped the treatment of an incipient attack of periostitis will depend somewhat on the history of the case. If the root canals have recently been antiseptically filled and a permanent stopping inserted no alarm need be excited by slight lingering congestion about the root manifested by some uneasiness or tenderness, for this

* These plasters are made of small pads of felt and are easily applied to the gum over the root. They act as counter-irritants. They seem to relieve pain in many cases of incipient periodontitis and to hasten suppuration when this is inevitable.

very commonly occurs and it usually passes away in a few days. Capsicum plasters often seem to give relief in this condition. But if the previous history of the case is not accurately known, or if there is reason to suspect a septic condition of the pulp chamber, the stopping should be removed and the interior of the tooth dealt with in accordance with the conditions which it presents.

If the inflammation continue in spite of this treatment local abstraction of blood; incision through the gum to relieve tension and evacuate pus, and persistent use of hot fomentations within the mouth are the measures called for. Although leeching sometimes seems to do good, I have been most commonly disappointed in the effect. A leech can be applied by means of a leech glass, but it is often not easy to make it bite near the affected tooth. An incision short and carried well down to the bone may be made over the apex of the root as soon as swelling appears and even before pus can be detected.

In some few cases in which marked pyrexia appears, the administration of a brisk purge may be found beneficial. For some patients an ordinary saline draught, such as a Seidlitz powder, will suffice; to others, with muddy complexion, foul tongue and constipation, calomel or blue pill, with colocynth, may be administered, followed by a saline draught if necessary.

When suppuration has commenced, extra care must be taken not to obstruct flow of pus by the root canals, through which it often drains from the alveolus; and if the flow be considerable it is often best to leave the canals empty and the tooth unplugged until the acute stage is subsiding.

Very often cases do not present themselves until the later phases of inflammation have become developed. By this time the tooth is too sensitive to allow much manipulation. If a stopping is present it may, however, usually

be pierced to the pulp cavity without much pain by a sharp drill with the engine.

On subsidence of the acute symptoms antiseptic treatment of the roots may be cautiously recommenced. Eucalyptus oil or solution of hydronaphthol or of corrosive sublimate may be pumped up the root canals by means of a bristle and cotton fibres, and may be, in most cases, made to flow through the foramina into an alveolar abscess or fistulous tract when these exist. An abscess if it have not already broken, must be opened through the gum and injected or swabbed daily or at longer intervals with the same antiseptic. The opening should be made in a dependent position to encourage drainage, and if, as sometimes happens, the incision tends to heal and close before the abscess is cured it must be kept open by a strip of lint until the healing process is advanced. This is, however, rarely needed with a small abscess.

Chronic dental periostitis may arise from any of the causes which originate the acute form of the disease. It often remains as a result of an acute attack. Periodontitis due to constitutional causes is generally chronic, and rarely passes at all beyond a subacute stage. The symptoms comprise in a modified degree those present in acute inflammation. The teeth are tender on pressure, they are the seat of a varying amount of pain, they are more or less loosened and raised from their sockets, owing to the swelling within; and they are surrounded by reddened and swollen gum. On pressing the mucous membrane in some cases either pus or muco-purulent matter oozes from around the necks of the teeth, or escapes through a fistulous opening in the gum. These symptoms may continue for months or years until the teeth becoming completely loose, in consequence of absorption of the alveoli, are at last lost.

Roots, the seat of chronic inflammation, exhibit various pathological changes. The periosteum is always

thickened and more or less injected, and covered with patches of lymph. A complete sac, containing pus similar to those occurring in acute inflammation, is often found attached to the apex. In the same situation there are frequently found masses of fibrous tissue—hypertrophied root membrane—which are often undergoing ossification at the point of junction with the cement. In other cases exostosis or partial necrosis exist, and absorption of cement and dentine, indicated by a rough excavated surface, are commonly observable.

Treatment.—The question of the extraction of the affected tooth will arise in many instances, and must be decided in accordance with the circumstances of the case. The condition of the carious cavity (when one exists), the degree of loosening of the tooth owing to absorption of the alveolus, and the presence of symptoms indicating pathological changes in the cement, will determine whether there is a fair prospect of bringing the organ into a useful condition.

The first step in the treatment will consist in removing the cause—when discoverable—of the disease. When the inflammation is associated with disease of the pulp, or morbid conditions of pulp cavity and root canals, these must be dealt with by measures already described. Sources of local irritation, such as tartar deposited upon the necks of the teeth or completely necrosed neighbouring roots, must be removed. Local depletion is of considerable service, and blood may be abstracted by occasionally incising deeply with a scalpel the swollen gum occupying the spaces between the teeth. Some cases of alveolar abscess, although in some measure amenable to treatment, cannot be entirely cured. In these cases there usually exists some morbid condition, such as necrosis of the cement of the apex of the fang, which keeps up constant discharge. After treatment of an abscess and antiseptic filling of a tooth this discharge

is often so slight as to be unknown to the patient, and such teeth with minute fistulous openings leading to the end of the root may remain for many years useful and without giving rise to serious pain or trouble. In other cases of a similar nature every attempt to permanently fill a tooth is followed by alveolar abscess, owing to arrest of discharge through the root canals. Some of these cases may be dealt with by drilling a fine hole through the neck of the tooth into the root canal beyond the stopping—the canal being left unfilled. This, however, allows decomposition to go on beyond the filling and leads to gradual destruction of the tooth. An attempt has lately been made in intractable cases like these to revive John Hunter's operation of replantation or transplantation. Some practitioners advocate the extraction of the teeth, removal by scraping of the diseased portion, including periosteum and end of the fang, the insertion of necessary fillings and replantation of the tooth, which, it is stated, becomes re-united to the socket. That some cases so treated have run a satisfactory course is attested by unimpeachable authorities. Hunter had, and almost every one since Hunter who has performed the operation has had, successes. Of late this mode of treatment has been gaining advocates and perhaps deserves consideration; but evidently it ought to be practised only as a last resource, and after failure of ordinary methods of treatment.

In periostitis due to or aggravated by constitutional causes, attention must be directed to the general health. Rheumatism, syphilis, debility and mercurialization must each receive its appropriate treatment, but this falls beyond the province of a dental surgeon.

Alveolar Abscess.—Certain phases of the suppurative stage of dental periostitis constitute the conditions most commonly spoken of under the designation of alveolar abscess; and although the separation of this

subject from that of periostitis is artificial and arbitrary, some points may well be discussed under a distinct heading. This class of abscess is seen in its simplest and most familiar form in the ordinary gumboil, which consists of a collection of pus between the gum and the bone, external to the root of the tooth which is the seat of inflammation. In severer forms of dental periostitis the cheek having become involved in the inflammation, great swelling having taken place, and suppuration to considerable extent having ensued, the matter, if it do not find a ready exit into the mouth, may point and burst through the skin externally. Thus there results a fistulous tract between the diseased tooth and the surface of the cheek, which remains open and discharging as long as inflammation continues. This termination, although it occasionally supervenes upon suppuration around other teeth, much more commonly follows alveolar abscess connected with lower molars. Suppuration in alveolar abscess always commences in the socket at the surface of the tooth, but as soon as matter forms absorption of the bone is set up and the matter escapes into the surrounding tissues. The external alveolar plate being the thinner, is almost invariably alone perforated, and the perforation often takes place with great rapidity, a few hours sufficing for the formation of a hole in the bone of considerable size. In some chronic cases the thin alveolar plate becomes dilated and forms a bony cyst around the abscess.

Diagnosis.—Abscesses connected with diseased teeth are usually traceable without difficulty to their origin. The matter does occasionally, however, burrow through the soft tissue and appear about the palate, cheek, or jaws in situations so unusual that the relation of the discharge to the teeth is not at first suspected. In cases of abscess about the mouth or face, the origin of which is not otherwise evident, it is therefore de-

sirable that an examination of the teeth should be made. In most cases a loosened or necrosed tooth will be discovered, and often distinct thickening and swelling may be traced from the surface to the region of the tooth. In some instances, particularly if the pus have found free vent, the tooth may show little sign of disease, and in the absence of other cause, decayed teeth, especially those extensively filled may be suspected. Removal of a filling sometimes gives vent to pus, and establishes a diagnosis. In some instances pus finds its way into the antrum and produces empyema—described in a later chapter.

When the matter escapes through the cheek the symptoms closely simulate necrosis of the jaw. After a time the orifice of the sinus becomes surrounded by granulations, which often increase so as to form a papilla-like projecting mass, and from it issues a more or less constant secretion of purulent fluid. Such a case may be distinguished from necrosis of the bone by the following circumstances—first, there is as a rule but one sinus when a tooth alone is implicated, whereas when a sequestrum exists there are usually several; secondly, dead bone may be detected by the probe; and thirdly, if necrosis have not taken place the symptoms, as a rule, speedily disappear on the extraction of the tooth.

The treatment of alveolar abscess is necessarily associated with that of dental periostitis, which has been already described. In the acute stage incision into the swelling through the gum down to the bone and warm fomentations within the mouth are the principal measures called for. Poultices and warm moist applications to the cheek should be avoided, as they encourage the escape of the matter through the skin. Painting the skin with tincture of iodine may assist in averting this danger. It must be remembered that although most

cases either yield to treatment or subside after running a certain course, the progress of the disease may in the vast majority of cases be arrested at once by the extraction of the tooth—an operation which may be performed without hesitation when the tooth is useless owing to chronic disease or extensive decay, or when pus points beneath the skin and threatens to burst externally. This latter event will be known to be imminent when fluctuation close to the surface is recognizable, and when the skin over the pointing abscess looks dusky or livid, and feels thin, and ready to give way. If the escape of pus through the skin appears inevitable, the abscess should not be allowed to burst spontaneously, but should be opened as soon as unequivocal symptoms of pointing appear, in order to prevent the more disfiguring cicatrix which must otherwise result in consequence of destruction of a small portion of skin. Abscesses or fistulous tracts opening through the skin must be treated by dressing with eucalyptus oil or syringing with an antiseptic lotion. In cases where no dead bone exists such treatment, with the extraction of the tooth, which in these cases is always called for, rarely fails to bring about a rapid cure.

Chronic alveolar abscess sometimes assumes a cystic character. A case lately treated illustrates this form. The patient presented herself with a swelling about the size and shape of a small Spanish chestnut, which had existed many months along the external alveolar wall of the upper jaw extending from the first bicuspid to the wisdom tooth. The swelling was tense and slightly elastic, as though covered by very thin bone and fibrous tissue. The second bicuspid being necrosed and loose was extracted. A discharge of glairy fluid took place by the alveolus, through which a probe could be passed into the cyst. This opening soon healed and the cyst

remaining unchanged it was opened and kept open by a strip of lint. The case made no progress under frequent antiseptic injections and was next packed at daily intervals with strips of lint soaked in carbolic acid and eucalyptus oil (1 in 20). After a few dressings the cyst showed marked diminution in size, and the packing being discontinued it gradually contracted and became obliterated under frequent injection of perchloride of mercury (1 in 4,000).

Cases like this simulate disease of the antrum or jaw, but their true nature, which is also suggested by the absence of symptoms of graver disease, is to be discovered by careful examination. There is also (as in the case above described) mostly a clear history of alveolar abscess—gum boil—and the exciting cause—a diseased tooth—is usually present.

Periostitis and Necrosis of the Maxillæ.—The slight limited periostitis of the alveolus or jaw, which from the intimate relation of the parts is necessarily associated with the dental diseases just described, subsides in most cases on removal of the cause; but in some instances the inflammation continues or extends, and may terminate in suppuration, followed sometimes by necrosis, to a greater or less extent, of the bone, in consequence of detachment of the periosteum. On the other hand cases occur in which inflammation, involving both teeth and bone, originates, independently of the teeth, in the periosteum of the maxilla. This form of inflammation may be caused by injury, such as fracture of the alveoli during extraction in an unhealthy subject, or by any of those constitutional conditions which give rise also to dental periostitis, and which have been already enumerated. A form of necrosis which occurs at the period of the commencement of second dentition in children, especially such as are badly nourished, or who have been debilitated by attacks

of the eruptive fevers, has been styled exanthematous necrosis. The necrosis in these cases is usually confined to the alveoli of the temporary teeth, the bone being exfoliated and thrown off together with the teeth which it supports.

The Symptoms of periostitis of the jaw resemble in an aggravated form those attending the dental disease. There are violent pain and great swelling and œdema, accompanied by fever. The occurrence of suppuration is marked by rigors, and is often attended with increase rather than diminution of pain, unless the matter find immediate vent. The skin assumes a shining, erysipelatous aspect, and pits on pressure, and after a time the abscesses point and discharge pus through openings corresponding to the position of the diseased bone, to which they lead by fistulous passages. These sinuses are similar to those described as occurring in alveolar abscess discharging through the cheek. When necrosis has supervened the rough denuded surface of bone can be felt with the probe.

In exanthematous necrosis the symptoms commence in the gum, which, with the periosteum, ulcerates and lays bare the bone. This is accompanied by a discharge of fetid pus. It gives rise to little or no pain.

Treatment.—The treatment of general periostitis of the jaw lies beyond the sphere of dental surgery. It consists of local bleeding by means of leeches, and free incisions through the gum down to the bone, with assiduous application of warm fomentations. All sources of irritation, such as hopelessly decayed and necrosed teeth, must be removed. As soon as matter forms it must be evacuated by the bistoury. The general health will of course receive due attention.

When necrosis has supervened the treatment is directed to maintaining a free vent for the discharges, destroying their fetor by antiseptic lotions, and removing

the dead bone. In exanthematous necrosis the amelioration of the general health is the first care, locally detergent lotions are called for, but incisions or bleeding are strongly contra-indicated.

Detergent lotions may be composed of carbolic acid (1 in 40) or of Condy's fluid, half a drachm to the ounce; and it is a good plan not only to wash the mouth frequently with these fluids, but also to inject them by means of a syringe into the sinuses when these exist.

No attempt should be, as a rule, made to remove the dead bone until it has become detached from the living tissue, which event may not occur for many weeks or months, and will be known by the mobility of the sequestrum on examination. It is especially important that force should not be applied in extracting dead bone in the case of children, lest the rudimentary permanent teeth lying within the jaw be injured or removed in the operation.

By the time the sequestrum has become detached the orifices of the sinuses have usually become so enlarged as to allow the mass to be readily withdrawn by means of a pair of sequestrum forceps, but in some cases a few touches of the scalpel may be required to complete the operation. To avoid subsequent disfigurement the necessary incisions should be confined to within the mouth.

Dental exostosis consists of outgrowth of new tissue from the surface of the cement, and takes the form either of prominent rounded nodules or of smooth and regular masses connected with a large portion of the root. These outgrowths are in most cases situated towards the apex of the root. The new tissue is similar in structure to ordinary cement, except that the lacunæ are generally coarser, larger, and closer together, and that when developed in a considerable quantity it is frequently penetrated by vascular canals, which, proceed-

ing from the exterior, give off branches throughout the mass. Upper and lower molars affected with exostosis are shown in figs. 160 and 161.

FIG. 160.

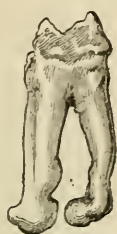
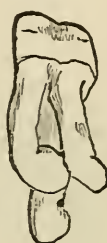
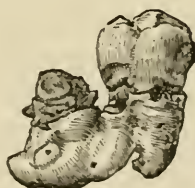FIG. 161.



The cause of exostosis is chronic periostitis. The development of new tissue is one of the most constant results of chronic inflammation of a low degree on cement, as on all bone surfaces. In chronic inflammation the periosteum becomes thickened and vascular, and coated with exudation. If the inflammation continue the exudation becomes organized into fibrous tissue, which, under favouring circumstances, undergoes ossification. The ossification commences upon the surface of the

FIG. 162.



root, and proceeds outwards, the soft tissue becoming dense and almost cartilaginous in texture prior to impregnation with earthy matter. It happens occasionally that roots of adjacent teeth become surrounded and

united by the same inflammatory exudation, and when this exudation becomes subsequently organized and ossified organic union of the teeth is brought about. Adjacent lower molars thus united are shown in fig. 162. Figs. 163 and 164 (from Wedl) illustrate rare examples of union

FIG. 163.

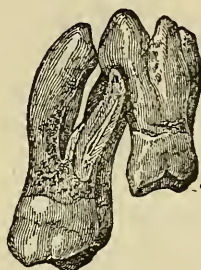
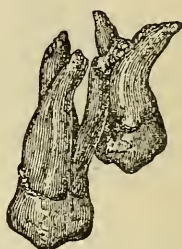

FIG. 164.



consequent upon exostosis involving roots of contiguous upper molars and wisdom teeth.

The Symptoms of dental exostosis are almost identical with those of chronic periostitis, and it is often difficult to distinguish between the two diseases. Exostosis may, however, exist without any distinct symptom being apparent, except, perhaps, slight congestion of the gum around the tooth; and teeth the seat of hypertrophy of the cement, although they may be the seat of no pain, sometimes give rise to facial neuralgia.

Treatment.—The only available treatment is extraction, an operation which may be performed when the tooth is the cause of severe or persistent pain, or is in any way a source of constant annoyance to the patient.

Necrosis.—Teeth derive their vitality from two sources—the central pulp and the periosteum. When from any cause the pulp has been destroyed and the cement entirely denuded of periosteum complete necrosis of the tooth results, and it is reduced to the condition of a foreign body. Complete necrosis of this kind is

occasionally met with, but cases are much more common in which the necrosis is only partial. The pulp may be destroyed, whilst the connection of the cement with the periosteum remains intact; or the pulp may retain its vitality, whilst the cement has to a greater or less extent lost its connection with the periosteum.

The causes, symptoms, and treatment of gangrene of the pulp have been described in previous pages.

The cause of necrosis of cement is periostitis, especially in its later acute phases. In these phases exudation takes place between the inner layer of periosteum and the cement; the vessels are torn and the periosteum destroyed, and the cement being left bare necrosis ensues. Necrosis is sometimes due to absorption of the gums and alveoli, and it may arise, especially in the case of the front teeth, from an injury, such as a blow, which has partly dislocated the tooth and severed at once its vascular connections.

A tooth entirely necrosed becomes the centre of suppuration and is speedily loosened and cast off, but if the necrosis affect a small portion only of the cement, the tooth—whether the pulp be living or not—may remain useful for an indefinite time without giving rise to important pain or irritation.

Necrosis of cement manifests itself by suppuration, the amount varying, of course, with the extent of the disease. The matter escapes through a fistulous opening in the gum, or wells up around the root from within the alveolus.

The necrosed surface of roots is rough and discoloured. The roughness is due to denudation of the periosteum and to absorption, which almost always affects to some extent the necrosed cement. In cases where the periosteum is entirely detached a thin probe can be passed along the root within the alveolus to near the apex. Roots in this condition exposed to the access of

saliva become coated with tartar or studded with small nodules, and the deposit is usually of the hard black variety.

The sole treatment of necrosis is extraction, but the operation is of course not called for so long as the tooth remains useful and free from severe pain.

Absorption of the roots of permanent teeth is a common accompaniment of chronic periostitis and of necrosis. If the roots, especially the apices, of teeth affected with these diseases be examined after extraction it will be found that they often display patches of roughened excavated surface closely resembling that presented by bone and by the roots of temporary teeth when undergoing absorption. Although instances are occasionally met with cases of complete or even of considerable absorption of the roots of permanent teeth are rare—no doubt because the teeth are usually lost before the process is far advanced. The disease, when extensive, manifests itself by loosening of the tooth. Extraction is the sole treatment.

Absorption of the alveoli occurs in many cases as an accompaniment of chronic dental periostitis, and calls for similar treatment. Very often it takes the form of pyorrhœa alveolaris.

Pyorrhœa alveolaris, slow wasting of the sockets and loosening and shedding of the teeth, seems if not a disease of modern life to be at least on the increase at the present time. The symptoms commence with inflammation of a very low degree appearing to affect simultaneously the free edge of gum and the alveolar periosteum. There is a discharge, usually slight in quantity, of muco-pus from within the edge of the gum. The gum and alveolus slowly waste until the tooth is lost; the bone in many cases wasting more rapidly than the gum. There is in most cases, although not invariably, deposit of tartar, often only in the form of hard

nodules around the denuded surface of the tooth, and beneath the swollen and loosened margin of the gums. In other cases tartar is deposited in enormous masses upon exposed surfaces of the roots. The inflammation is usually extremely chronic, with occasional subacute and, in later stages of the disease, acute exacerbations. The disease may at first affect one tooth only, but more commonly attacks several at the same time, subsequently extending gradually to the whole set.

It is not known whether this malady is of local or constitutional origin; and it is not known in which tissue it has locally its starting-point. Many suggestions unsupported by sufficient proof have been put forth as to its etiology and pathology, some giving its origin in general, others in local causes. It has been stated, but without any verification of the statement, that the affection is really due to ulceration or caries of the alveoli progressing from their edges onwards to the depths. On extraction of a tooth the centre of pyorrhœa alveolaris all inflammation ceases, and the alveolus at once assumes a healthy aspect. This fact would go to show that the disease belongs essentially to the tooth or its periosteum and is not due to an independent morbid condition of the investing bone.

I have formed the opinion that cases of this affection may be grouped into three classes, and that they are closely analogous to varieties of diseases of the hair commonly classed under the term "baldness." It must however be understood that the two maladies are not necessarily associated.

In one variety the inflammation and discharge continue extremely slight until the final stage; and the cases occur mostly in robust healthy individuals, although very often of the gouty diathesis, and with massive well-formed jaws and teeth free from caries. These cases are like those of simple premature baldness.

In a second group there is present either general debility, or one or another of the dyscrasiæ such as are so often associated with alopecia. A third class of cases resembles sycosis—although I do not suggest that their etiology is identical—and these are the cases of true pyorrhœa alveolaris. A similar comparison between this disease and affections of the hair has also been drawn by Mr. Jonathan Hutchinson.

The treatment is in the vast majority of cases extremely unsatisfactory, and although temporary improvement may appear and the progress of the disease seem checked for a time, it is very rare indeed that permanent good results are to be achieved. The treatment consists first in removing tartar with great care. The pouched interval which exists between the swollen margin of the gum and the neck of the tooth should be swabbed at intervals with a powerful antiseptic. Solution of perchloride of mercury, sulphate of copper, hydro-naphthol or pure carbolic acid may be used. When the last is used care must be taken to prevent it from flowing over the gums. This may be accomplished by using a thin silver probe, having its end bound with a small quantity of cotton wool to convey the acid to the part. The teeth should be kept scrupulously clean and an antiseptic lotion freely used. Teeth which become so loose as to be constant sources of irritation should be extracted. Where several teeth have been lost, great comfort will often be afforded by the adaptation of a perfectly-fitting frame of vulcanite to embrace the necks of the remaining teeth, and to hold artificial substitutes in the vacant places. The frames, which for the upper jaw should be on the "suction" plan, must closely surround the teeth without causing any strain upon them.

CARIES AND ITS SEQUELS IN INFANCY AND EARLY CHILDHOOD.

NEITHER in regard to their etiology, pathology, nor diagnosis do diseases of the temporary teeth differ materially from those of the permanent set, but there are some special points with respect to treatment which call for separate notice. The preservation of the temporary teeth until the period at which they should be naturally shed is important. They are needed for the performance of their function—mastication. If allowed to decay they give rise to suffering detrimental to health, especially in delicate children. Their premature removal is a frequent cause of irregularity of their successors.

Temporary teeth are very frequently affected by caries. As a preventive measure cleanliness cannot be practised too early. From the first until a child is old enough to do it for itself its teeth should be cleaned at least once a day. To rub the incisors with a wet cloth may suffice at first, but as soon as the temporary set is complete and the child is old enough to bear it without difficulty, a soft tooth brush may be used at least once in the twenty-four hours—preferably after the last evening meal so as to remove particles of food which may have accumulated during the day. The use of tooth powder, and antiseptic lotions when needed, may be begun as soon as the child is old enough to rinse its mouth. A child that has been taught this regimen as a part of daily hygiene will not be likely to omit it in later life.

Carious cavities in temporary teeth should be filled without delay. When the dentine is but slightly penetrated the pain of the operation is usually very slight and not sufficient to discompose the average infant. Enamel chisels and excavators are as a rule only needed; the use of the dental engine should be avoided as terrifying if not painful.

The object being only to preserve the teeth for a comparatively short period, no purpose is served by putting in fillings of great durability. In preparing the cavity the main point is to ensure a sound external margin and to cut away diseased tissue at the orifice to such an extent only as to ensure arrest of decay. It is best to leave in the depths all dentine except such as is disorganised and in the last stage of softening. Sealed under a stopping of suitable kind, dentine in this state—the removal of which would expose the pulp and probably lead to loss of the tooth—gives rise to no evil consequence. Cavities which do not penetrate deeply are best filled with copper amalgam. The antiseptic and preservative properties of this filling make it here particularly suitable. It can be used soft (with excess of mercury) and the end of the plugger should be enveloped in cotton as described in the section on amalgam filling.

In deep cavities non-conducting fillings are preferable to metal. Jacob's gutta percha and cements are the best. In deep cavities where the pulp is nearly exposed the first portion of the filling may be commenced with a loose pellet of absorbent cotton saturated with a thin semi-fluid mixture of cement; this being gently packed over the floor of the cavity the filling may be completed with the same cement in the usual way. When decay closely approaches the pulp great caution must be exercised; for if septic material has reached it, or if diseased, a pulp will probably become at once acutely inflamed on insertion of a filling. Where doubt exists it is well to

dress the cavity for a period at intervals of a few days to a week. The dressing may be composed of wool with eucalyptus oil and iodol, or wool moist (not wet) with carbolic acid or oil of cloves and sealed with a plug, either of wool saturated with mastic cement or with Hill's gutta percha.

In exposure of the pulp, if the period has nearly arrived when the tooth should be shed, the question of extraction for relief of pain may be considered, and of course if the tooth be loose or if other indications of the imminence of the eruption of its successor be present, there need be little hesitation in removing it. Roots of temporary teeth are no sooner fully formed than they commence to become absorbed, and therefore there is during most of the period of their existence very free communication between the pulp chamber and the alveolus. For this reason inflammation may quickly extend from the pulp to the periosteum and socket. In my experience attempts to destroy the pulp of temporary teeth by arsenic gives rise in the majority of cases to immediate acute dental periostitis. The only favourable cases for this treatment—very rare—are those in which it is possible to be tolerably certain that the teeth are at that period of their existence—a very brief period—when the roots are not in process either of formation or absorption, and when the apical foramina are at their smallest size. The difficulties of capping the pulp in temporary teeth are too great to warrant the attempt. For the relief of pain careful excavation of the cavity and applications of dressings—oil of cloves, or eucalyptus oil with iodol—under the usual temporary stopping, should be carried out. Carbolic acid repeatedly applied at intervals of days in the same way will in time destroy the pulp. After destruction of the pulp temporary teeth may in many cases be best left unfilled. If filling be performed the roots should be little interfered

with, and no attempt to clear the depths of the canals should be made. The pulp chamber may be filled antiseptically and the cavity of decay with gutta percha or cement. A minute hole may be then drilled through the neck of the tooth into the pulp chamber as a vent for discharges. Teeth treated in this way will often remain useful and comfortable for the short time during which their preservation is desirable. Alveolar abscess must be treated by opening of the cavity of decay so as to give free vent to discharge; while this is ensured pain does not commonly supervene. On subsidence of the acute symptoms the teeth are in many cases best left unfilled. Necrosis, manifested by loosening and discoloration of the tooth and persistent suppuration, may call for extraction. In neglected mouths there are often found remains of necrosed roots of temporary teeth lying around or wedged between the permanent set. Sometimes, through ulceration of the gum and external alveolar wall, apices of necrosed roots protrude, and by chafing cause ulceration of the mucous membrane of the cheek or lip. This in unhealthy unclean children may become extensive. The roots, which are always loose, must be extracted. Antiseptic lotions and attention to the general health, where called for, must then be prescribed.

The first molars are as a rule the most delicate of the permanent set, and are by far the most frequently in this set the seat of easily recognizable structural defects. They are very frequently affected by caries. The disease in numerous instances begins apparently as soon as the crowns are exposed to the fluids of the mouth. Where the enamel and dentine are ill-made throughout and progress of the disease is favoured by vitiation of the buccal secretions, such as exists in unhealthy or improperly-fed children, caries runs a very rapid course. Especially in children of families with

a bad dental history, these teeth need therefore closely watching from the first. They are commonly mistaken by parents for temporary teeth and allowed to fall into hopeless decay.

The considerations which govern the treatment of caries and its sequels in temporary teeth apply almost entirely during early childhood to the teeth under notice. Copper amalgam forms the best filling for simple cavities not closely approaching the pulp; for the latter class, cements, or fillings of that class are to be preferred. In many cases the intention will have been formed soon after the appearance of these teeth to extract them, in order to cure irregularity or relieve crowding at the proper time, *i.e.*, when the second molars shall be in place; but in cases where, as very often happens, the permanent preservation of the teeth is resolved upon, more perfect and durable stoppings may be in due course inserted. The treatment of exposure of the pulp, particularly in ill-calcified teeth where caries has attacked early and progressed rapidly, is in many instances unsatisfactory. Capping does not as a rule answer, and destruction of the pulp by arsenic is contra-indicated because of the largeness of the apical foramina. These very often remain patent for some years after complete eruption of a tooth. In these cases palliative measures and gradual destruction of the pulp by carbolic acid as used in similar conditions of the temporary teeth may be practised. If the teeth are of moderately good structure, have been the seat of caries progressing with comparative slowness, and have been in place for considerable time so that it is probable the roots are fully formed, destruction of the pulp by arsenic may be practised with fair prospect of success. If they are to be sacrificed later, which must be mostly necessary under the circumstances, the teeth may be dealt with and filled after the method recommended for temporary teeth under like conditions.

The chief danger to be guarded against is periodontitis, which if set up in these cases is apt to run an extremely acute course ending in suppuration. The pulp chamber and nerve canals must be cautiously cleared of their contents. If sensibility continues in the depths, owing to existence of living portions of pulp, these must be treated with carbolic acid. Arsenic must not be applied deeply in the root canals lest periosteal inflammation be excited. After thorough antiseptic treatment the pulp chamber and canals may be filled with iodol and wool, as described in a previous section. The filling may be completed with gutta percha or cement. Teeth treated in this way, when aseptic conditions are assured, will often remain for years without untoward symptoms. If inflammation of remaining shreds of pulp do supervene, it very often gives rise to little pain, there being free vent for exudation into the cotton filling; and if it become severe relief may in most cases be afforded by providing drainage by means of a perforation through the stopping or the neck of the tooth.

If these teeth—decayed, broken-down as they may be—can be kept free from inflammation and pain and retained by any means until the second molars are in place, the benefit accruing will often repay for the trouble expended; but many delicate children cannot bear the pain and fatigue of treatment, and in such cases teeth which might otherwise be saved must frequently be sacrificed for the immediate relief of suffering.

To fill with gold teeth which will surely need extraction after lapse of a few years is evidently labour thrown away; but in some children where the jaws are not crowded and the teeth are of good general structure—particularly in robust patients who bear operations well—it may be expedient to use gold at once. Decay in permanent incisors and canines usually occurring in interstitial positions, very often shows itself speedily after

eruption in delicate sets. In a vast majority of such cases the teeth are best kept filled with cement for a few years; with watchfulness to guard against failure of the stopping. In later childhood gold fillings may be inserted—a thin film of cement being left to coat the floor of the cavity when this is of sufficient depth.

DISEASES OF THE GUMS AND BUCCAL MUCOUS MEMBRANE. RANULA. GLOS- SITIS.

Inflammation of the Gums.—Inflammation of the gums may be due to various causes. Some amount always accompanies dental periostitis, and reference has been made to this variety in previous chapters. It may arise from irritation of tartar accumulated around the necks of the teeth, or from the presence of necrosed teeth and roots; it may be associated with disorders of the digestive organs, especially such as occur in pregnancy and in gouty subjects, and in those who habitually take alcohol to excess. It is also often caused by constitutional syphilis, it forms a prominent symptom in ptyalism and in chronic mercurialization, and it is present in some diseases which, like scurvy, are due to a depraved state of the blood.

The inflammation may involve a small part only of the gum or may attack the whole surface in each jaw. The limited variety is most commonly occasioned by local irritation; general inflammation of the gums usually arises from constitutional disorder.

Symptoms.—The gums are deep red or purple in colour, swollen, spongy, and tender, and they bleed on the slightest touch. Pus oozes or can be squeezed from around the teeth at the free edge of the gum, where ulceration also often occurs. If the disease continue for any length of time it always spreads to the dental periosteum, rendering the teeth loose and tender, and leading to absorption of the alveoli. Chronic inflamma-

tion sometimes leads to hypertrophy of the gum. The outgrowth is at first soft, but after the lapse of time may become hard and fibrous in character.

The treatment must be first directed to the removal of the exciting cause; all sources of local irritation must be done away with, tartar, and hopelessly loose and necrosed teeth being at once removed. The gums may be unloaded by free scarification, followed by warm fomentation, in the acute stage, and by astringents, such as tannin, in the chronic form. Where a fetid discharge exists detergent lotions may be prescribed, and the necks of the teeth may be swabbed with solutions of chloride of zinc or carbolic acid. Where the inflammation is associated with constitutional disorder local treatment is of secondary importance, and the remedies must be applied to the amelioration of the general health.

Hypertrophy of the Gums.—This malady sometimes results from chronic inflammation, but in many cases the causation is obscure. It is rare in the adult, mostly occurring in childhood, sometimes apparently associated with the scrofulous diathesis and also with some forms of idiocy. The hypertrophy generally extends along the whole alveolar border and often involves the submucous tissue, and may develop to such a degree as to almost conceal the teeth.

The treatment consists in attention to the general health, removal of all local sources of irritation, and the use of antiseptic and astringent lotions. In some few instances it has been found necessary to excise the hypertrophied mass.

Thrush is an inflammation of the mouth commonly occurring in infants, more rarely in adult subjects of debility. The entire mucous membrane is reddened and studded at parts with vesicles, especially inside the lips and on the tip of the tongue. These vesicles give place to patches of exudation, which are thrown off,

leaving the membrane exposed, ulcerated, and deeply red in colour beneath. With these symptoms there is fever and often diarrhœa. The treatment must be directed to the general health. Locally, soothing applications, such as lotions of glycerine or borax and honey, are most useful.

Aphthous, or follicular ulceration, occurs both in adults and in children. The first stage the malady takes the form of simple inflammation of the mucous membrane. In the next stage small, round, transparent vesicles appear, which burst, leaving small spreading ulcers with red and swollen margins. Both in this disease and in thrush, in some cases, the ulcers become coated with a layer of a microscopical parasite (*oidium albicans*). Besides constitutional treatment, which is of the first importance in this affection, the ulcers may be touched with sulphate of copper or nitrate of silver, and a lotion may be prescribed to destroy the vegetable parasite composed of sulphate of soda ʒj to ʒj.

Ulcers of the tongue and lips often originate from friction against the ragged edges of broken and decayed teeth, and ulcers in these situations arising from other causes—such as syphilis and dyspepsia—are frequently aggravated by similar irritation. Ulcers due to irritation of ragged teeth vary in size with the length of time they have existed, and they may attain large dimensions. They are of irregular form, with slightly hardened bases, and are situated, as a rule, on the surface of mucous membrane lying against the faulty tooth, those on the tongue appearing on the side and under surface. These ulcers when neglected may assume an aspect closely simulating epithelioma, and the resemblance is rendered more complete in some cases by induration of glands beneath the jaw, which accompanies them.

One of the commonest symptoms of constitutional syphilis is the occurrence of ulceration of the mucous

membrane of the mouth, which assumes various forms, sometimes not easily distinguishable in appearance from the varieties above described, due to other causes. Such cases can be diagnosed by their history, the presence of other symptoms indicative of syphilis, and by their obstinacy under any but specific treatment.

Treatment.—In all cases of ulcers in the neighbourhood of decayed teeth it is desirable to file down and polish rough and ragged surfaces. Should the ulcer be of a simple character it will then soon heal. The cure may be hastened by painting the surface with a lotion, such as nitrate of silver, two grains to the ounce of distilled water.

Cancrum Oris.—This comparatively rare disease is confined entirely to young ill-fed children inhabiting low crowded neighbourhoods. The disease may be well defined as sloughing phagedæna of the gums and cheeks. It may begin at any part of the mucous membrane, but in many cases makes its appearance at the edge of the gum about the necks of the central incisors, in the form of a yellowish or ash-coloured ulcer. Thence it spreads with great rapidity and speedily attacks the inside of the cheek, which is, however, often swollen, and the seat of ulceration from the first. The ulceration extends in the direction of the sockets of the teeth, destroying the gums and periosteum, and causing necrosis of the teeth and bone. The affected soft parts slough, and a large ragged ulcer of a dirty blackish appearance is formed, which sometimes perforates the cheek. A profuse discharge of fetid purulent fluid and saliva accompanies the progress of the ulceration. In the early stages, and until sloughing has commenced, there is little or no pain. The disease often ends fatally, the patient dying from exhaustion.

The treatment consists in supporting the patient's strength by nourishment, together with quinine, am-

monia, and brandy. Locally, the sloughing surface must be destroyed by nitric acid or acid nitrate of mercury, whilst detergent lotions are employed to destroy the fetor of the discharges.

Ranula.—When from any cause a duct of one of the salivary glands in the floor of the mouth becomes closed and the flow of secretion obstructed or prevented, the fluid collects and a species of cyst is formed. Such a cyst may attain a large size. Sometimes the closure of the duct is due to the formation of a salivary calculus within the duct; in many cases the cause is obscure. The cyst is found on one side of the floor of the mouth, and its nature in the vast majority of cases is easily recognizable, particularly when a calculus is present. In the latter case pain and swelling of the glands may be present—more often these symptoms are absent.

Treatment.—A calculus may be usually with ease pressed out of its position with an instrument or the finger nail; sometimes a touch with a scalpel may be needed. A small ranula will usually disappear after being opened and having its contents pressed out. If the opening tends to close and the cyst to refill, or if the ranula be large, a small piece may be snipped out with scissors. Sometimes besides these measures the inner surface of the cyst will need acting upon. This may be done by scraping gently the interior with a rough-ended probe or by mopping out the cyst occasionally with solution of nitrate of silver, four grs. to the ounce, or chloride of zinc, five grs. to the ounce, by means of a small probe bound at the end with a few filaments of cotton wool.

Glossitis.—This term is sometimes employed to distinguish inflammation of the tongue extending below the surface. It may be either acute or chronic, and the cause is very often difficult to discover. The symptoms are tenderness, pain and swelling, and often in-

creased flow of saliva. Movement of the tongue is impeded and in the later stages breathing may be interfered with. The symptoms may advance in severity until, pus having formed and an abscess having burst, they gradually subside. I have seen a case which went on to formation of a deep abscess, and which in the early stage was mistaken for dental periostitis, diseased roots being present to which the patient pointed as the seat of pain. Such a mistake ought not to occur if careful examination were made.

The treatment includes application of ice to diminish swelling, which answers better than hot fomentations in these cases. As soon as pus has formed or before, in order to diminish swelling or relieve tension, an incision may be made, but in performing this operation the danger of severe hæmorrhage must not be forgotten. The treatment of these cases is, however, beyond the province of a dentist.

ABRASION. EROSION. INJURIES— CONCUSSION, DISLOCATION, AND FRACTURE OF TEETH.

Abrasion.—As age advances the teeth become ground down by mastication. The enamel is first worn off, next the dentine suffers, and in time the pulp would be laid bare were it not that it almost invariably undergoes calcification on the surface *pari passu* with the slow destruction of the hard tissues. The amount of abrasion in every case depends of course on the density of the teeth, and on the kind of usage to which they are subjected, and to some extent on the bite—the manner in which the teeth articulate. If the bite be normal, abrasion of the front teeth rarely becomes excessive, but if these teeth meet edge to edge they may become worn down, sometimes even to the level of the gum. In rare cases, from some unexplained cause, the front teeth are ground down more rapidly than the molars, so that after a time, on closure of the mouth, the incisors of the opposing jaws cannot be brought into contact. Abrasion of the teeth of this slow kind is in most instances unattended with suffering, but it is occasionally accompanied by tenderness or pain due to exposure of sensitive dentine, or to approaching exposure of the pulp.

The treatment of abrasion of this kind is the same as that prescribed in a previous chapter for sensitive dentine and irritated pulp.

Erosion is a term used to designate a slow wasting

of certain surfaces of the teeth, occurring mostly along the necks, where it forms grooves of characteristic form. Erosion is distinct from, although sometimes mistaken for caries, and perhaps a summary of the points in which it differs from caries would contain almost all the knowledge we possess upon the matter. Like caries it is a destructive process proceeding from without inwards, but there the resemblance ceases. In erosion the tissue that suffers most is enamel; in caries, dentine. Erosion scarcely ever forms an undercut cavity; caries almost always does so. An eroded surface is always hard and polished; a carious surface always more or less soft and rough. Erosion shows no preference for fissures or sheltered crevices, but destroys those surfaces most constantly rubbed by the lips and tongue and washed by saliva. It presents often the appearance caused by friction of a band, but since it is often found in mouths where no artificial teeth have been worn, this hypothesis does not always explain its presence. Erosion cannot be due in many cases to the use of tooth-brushes or tooth-powders, for it is common amongst those who never clean their teeth. It is not due to the friction of opposing teeth, for it often attacks lingual, labial, proximal, and distal surfaces of the same tooth simultaneously. The suggestion that it is the effect of acids—acid saliva or acid mucus secreted by the gums—aided by constant friction, is most probable. It has this in its favour that the morbid process is precisely similar to decalcification, if the decalcifying surface be kept polished by constant rubbing. It is certain that erosion can be due alone to chemical and mechanical causes acting externally to the teeth; but it is rarely possible to ascertain why it attacks certain teeth by preference in each case, and why certain surfaces only of those teeth.

Mr. A. Underwood has shown that enamel of some teeth, the seat of erosion, is structurally defective;

granular in character, and more easily acted upon by acid than well made tissue. Dr. Black, of Chicago, has further shown that enamel exposed to a continuous current of slightly acid fluid undergoes wasting very closely resembling erosion. The existence of acid secretions which may be kept constantly in motion over the teeth by the movement of the tongue, cheeks and lips, seems enough to account for erosion. Its varying incidence would be accounted for by structural weakness in enamel occurring in different situations, and by the configuration of the teeth, which exhibits infinite variation in different individuals, and which exposes some surfaces more than others at once to the action of acid and to friction from the tongue and lips.

When eroded surfaces become sufficiently deepened to allow prolonged lodgment of decomposing *débris* softening may ensue, and the case becomes changed into one of caries.

The treatment consists in use of alkaline tooth-powder, such as prescribed at page 168, and in lessening the sensibility of exposed dentine by application of chloride of zinc. Where the erosion takes the form of grooves across the face of the teeth, it is good practice in later stages of the disease to undercut the margins of the excavations and fill them. This often permanently arrests the destructive process.

Fracture of the teeth may arise from injury, such as a blow upon the mouth, or may occur during mastication, as when a fragment of bone, a small gritty particle, or a shot in game is bitten upon. I have seen cases, and many are recorded, in which the crown of a tooth has been cleft in twain by accident during mastication. The teeth have been bicuspid or molars, some hard foreign body having lodged between the cusps during forcible closure of the jaws. In many of these cases the patients having experienced little pain at the

time seemed unaware of the accident, or having forgotten it and applying later complaining of uneasiness in the tooth, the character of the trouble was revealed by careful examination.

If the fracture, however caused, do not lay open the pulp cavity it will often suffice to file down the rough surface and carefully polish it. In other cases, if the fractured surface is of such a shape as to form a cavity, or so situated that filling appears desirable, a stopping may be inserted. If the pulp be exposed by the injury, and the fracture extend in a vertical direction and to more than a slight extent into the root, the extraction of the tooth may be called for, but if the fracture involve only the crown an attempt may be made to save the tooth, or at least the root. The pulp in most cases must be at once destroyed, after which fang-filling may be performed, or an artificial crown may be attached to the root in the manner elsewhere described. If the root be transversely fractured deeply within the socket, extraction will usually be called for. Some few cases are, however, recorded in which a root completely fractured transversely has united and the tooth has remained useful for years. The union in these cases was effected by deposition of cement and in some instances calcification of the exposed pulp at the seat of fracture. The question of supporting and protecting a fractured front tooth in the hope of repair taking place is therefore perhaps in some cases worth consideration.

Concussion.—A blow upon a tooth which may be followed by only slight immediate suffering will occasionally give rise to severe symptoms after lapse of months or years, when very often the injury has been forgotten by the patient. Injuries of this kind are very apt to occur to boys engaged in school games. A front tooth receives a hard knock, remains tender, perhaps somewhat loose, for some days, and then slowly recovers

and becomes firm again. After a time attention is again attracted to the tooth; it becomes either the centre of an attack of acute inflammation—alveolar abscess—or the seat of chronic periostitis. On examination the tooth is found free from caries and the pulp dead. This latter fact is evident from the characteristic darkened hue of the tooth and it can be proved by the heat test. A heated steel instrument applied to the crown over the situation of the pulp chamber does not give rise to sensation such as neighbouring teeth with living pulps display. The patient being questioned will usually recall the circumstances of an old injury. Care must be taken not to confound this condition with pyorrhœa alveolaris—a mistake which a novice might well make. In pyorrhœa the pulp in the vast majority of cases is alive, and the characteristic appearances of the gum with muco-purulent discharge from within its free edge cannot be mistaken by an experienced observer. Abscess following concussion, although often very acute, is sometimes extremely chronic, a large collection of pus slowly accumulating without much pain or other urgent symptoms. Sometimes the pus burrows to a distance.

Treatment.—Concussion at the time of injury calls for the same treatment as periostitis—rest, bleeding and hot fomentations. If the pulp be dead the case must be dealt with exactly in the manner prescribed for cases of death of the pulp following filling in caries. The pulp chamber can be opened by a drill. In upper and lower incisors and canines this opening should be made through the posterior surface of the crown in an oblique direction favourable for the admission of nerve instruments. The pulp chamber, which may contain the gangrenous pulp entire, but which will more often be found to contain fetid pus only, must be cleared and the canal dealt with in the manner already described at the same time that the abscess, if there be one, is opened and evacuated and treated as an ordinary alveolar abscess.

Dislocation of the teeth, and more particularly front teeth, is not an uncommon effect of blows upon the mouth. It may occur as an accident during extraction, as mentioned in a later page. Sometimes the tooth is only started from the socket or partly dislocated; sometimes it is completely dislodged.

Treatment.—If partly dislocated the tooth must be pushed back into the socket. In complete dislocation, if the case be seen within a few hours, the tooth may be replanted in the socket. The socket should be first washed out with syringe and warm water, to clear it of coagulated blood, and the tooth having been also cleansed and washed in an antiseptic lotion, such as carbolic acid 1 in 40, should be replaced in the socket. If but a short time has elapsed after the tooth was knocked out, if great care be taken to support the tooth by ligatures and to guard it from injury, it will in favourable cases regain its attachment to the socket, and may remain firm for years. In cases where the tooth has been separated for hours success is more likely to attend replantation, if the pulp be extracted through the apical foramen and the canal filled with antiseptic stopping. After this treatment, as also after replacement of a partly dislocated tooth, there may supervene an attack of acute periodontitis, which must be treated in the manner described on another page. In cases of partial dislocation death of the pulp may possibly occur either at once or apparently after an interval; and the case then calls for the treatment described for the same condition following concussion.

Cases in which teeth are driven by violence into their alveoli partake partly of the nature of dislocation, partly of fracture of bone; for it seems hardly possible for a tooth to be so dislocated without some splitting asunder of the alveolus. This accident seldom occurs except to the upper centrals and canines, and is

caused either by an upward blow or by a fall forward on the face. The treatment consists in drawing the teeth down to their proper level and supporting them by wires and ligatures, and pressing the bone when necessary into position. Inflammatory symptoms must be dealt with as they arise. The prognosis in adults is extremely unfavourable. Considerable inflammation usually supervenes, and the teeth become necrosed. Sometimes portions of fractured bone also exfoliate. In children recovery is more probable. This fact was exemplified in a case recently under treatment. A girl aged eight was thrown from a carriage on to the road upon her face. She was seen five hours after the accident. Beside other injuries it was found that one upper central incisor was missing, the alveolus being empty; whilst the other central and the laterals had been driven so far into their sockets that five-sixths of the crowns had disappeared, and their cutting edges were barely visible through the swollen gum. The teeth were separately grasped with forceps and slowly drawn down to their proper position. They were then so loose as to be with difficulty prevented from falling out. The alveolar walls were compressed where they seemed forced apart. The teeth were ligatured, but not very effectually, owing to absence of permanent teeth except the first molars. The child was kept for a time upon liquid diet. In this case perfect recovery took place. The teeth a year after the accident were firm in position, with living pulps and the bone had consolidated. The space previously occupied by the missing central had considerably diminished.

PIVOTING TEETH. PORCELAIN INLAYS.
CROWNING. BAR AND BRIDGE WORK.

AFTER the partial or complete destruction of the crown of a tooth by injury or disease, it is possible in many cases to attach permanently an artificial crown to the root by means of pegs or pivots fixed in the pulp canals—the pulp having been, of course, previously extirpated. The incisors and canines were once considered alone suitable for this operation, but the advance of antiseptic methods whereby the conservative treatment of decayed roots has been made more easy and certain has rendered possible successful practice of similar operations (modified to meet the different conditions) on any tooth. The roots should be free from disease. If periostitis exist, it must be treated, and even in cases where no symptoms are apparent it is good practice to dress the canals, and to plug them for a few days before permanently closing them. An attack of acute periostitis will often follow the operation if this precaution be not observed.

Pivoting Teeth.—In preparing an incisor or canine for pivoting the remaining portion of the crown must be excised. This is accomplished by means of a small saw, cutting forceps and suitable files. The edge of the root must be reduced to the level of the gum and its surface should be concave. The canal must be reduced to an equal calibre throughout, to near the apex. In these operations the dental engine will of course be used, The most suitable calibre for the canal is one that will

admit a wire of ordinary dental pin size. It often happens, however, that the canal has been already enlarged to a greater size by decay, and in such cases the softened tissue must be cut away, and the walls of the cavity rendered smooth. The canal in some of these cases must remain tapering in form.

A model of the part should then be taken by the following method. A wooden pin is cut to fit the canal and long enough to project slightly beyond the orifice when inserted. With this peg in place an impression of the root and adjacent teeth is taken in the usual way (plaster of Paris is preferable for the purpose), and in this the pin comes away. The cast which is prepared from the impression shows, on withdrawal of the peg, the size and diameter of the canal. An artificial crown can be fitted to the root and attached to a pin in the patient's absence.

The material of which the pivot is made will depend on the size of the canal. If of average size, metal—gold or platinum—answers best; if abnormally large, compressed hickory may be more suitable.

If of wire, the pin should fit the canal accurately but not tightly, and should be roughened or barbed. A succession of minute barbs can be made by drawing a sharp steel blade around the pin at close intervals. The pin is next bound with one thin layer of floss silk. The canal must next be dried antiseptically and the pivot tried lest the silk and barbs may have made it too tight. Cement is then mixed very thin, and some passed into the canal and the pivot thoroughly coated and soaked with the same. The pivot is then inserted. Some difficulty will be found in forcing it home until by working it to and fro a portion of the cement is allowed to escape. A moderate amount of force at the last may be exercised, through steady pressure, to drive in the pivot. Exclusion of moisture until the cement has hardened is desirable. This plan makes a very secure joint, and at the

same time ensures complete plugging of the canal to the apex. If the apical foramen appears unusually open, it must be closed by a short plug before insertion of the pivot.

If a wooden pin be used, the procedure is the same, save that no cement or silk is used. The pin should fit the canal so tightly as to require a slight amount of pressure to drive it home. When there the moisture of the mouth causes the wood to expand, and binds it with great firmness in position.

Root canals much enlarged by decay may often be made to securely hold a pivot by plugging. Gold or amalgam—copper amalgam answers well—may be employed. An iron pin may be inserted and the filling packed around. When the filling has hardened the pin can be withdrawn and a tooth prepared, the pivot, where amalgam is used, being of platinum. A more beautiful operation consists in inserting a gold tube and packing gold around.

Incisor and canine pivot teeth should be arranged to escape contact with the teeth of the opposing jaw, so far as possible, during mastication. Where the bite is close, a flat tooth is most suitable; where the bite is free, a tube tooth may be employed; for wooden pegs crowns of a special make are required.

Inlays.—There is wide scope for ingenuity in many cases of badly decayed front teeth—instead of pivoting—in preserving all that is sound and either inlaying the defective surface or restoring the broken crown with porcelain. For this purpose shaped fragments of artificial teeth are employed, and these sometimes may be the more effectually secured by soldering gold or other metal wires or strips to the platinum pins of the artificial teeth. The metal attachments are either carried into the root or into convenient angles of the cavity, and are there fixed by stopping. The durability of inlays de-

pende first on the skill with which the artificial fragment is shaped and keyed in position; secondly on the judgment exercised and pains taken in choosing and packing the cement or stopping which is to secure the inlay in place.

Crowning. Bar Work.—The operation of crowning bicuspid and molars also gives scope for a great deal of ingenuity, and the practitioner has the choice of a considerable variety of artificial crowns in porcelain and metal now supplied by manufacturers to meet the exigencies of cases. If the labial wall of the crown of a bicuspid is sufficiently strong it may be often preserved by a stopping having its foundation in the root and being strengthened by pivots secured in the canals. Otherwise, for the sake of the appearance, the patient will prefer a porcelain crown; or, if the lingual wall of the tooth still stands, a flat porcelain front on a pivot may be secured with filling to restore the crown. The molars are to be dealt with on similar lines. Pivots may be secured in all or either of the roots, and fillings may be built up around these. A beautiful operation consists in preparing a hollow gold crown to fit over a truncated tooth, fixing it in position with a mass of cement anchored and secured to a mass of stopping springing from the roots, in the canals of which pivots have been previously fastened.

Where a number of truncated teeth and roots exist in a mouth with intervals whence teeth have been lost, it is sometimes possible to fix upon them a row of artificial crowns permanently and securely. The teeth are mounted on a gold bridge or bar provided with pivots and projections, which are secured by stopping into the roots and cavities. Metal collars may be also carried round broken-down crowns. The choice of cases for this treatment calls for nice discrimination. Like all advances in the dental art it has become a field for

quackery. Patients are always anxious to avoid the employment of the usual plate for artificial teeth, which, of course, is dispensed with in bar work. But in many cases decayed teeth and roots, although they will carry safely a moderate-sized stopping, will not bear the greater strain which this kind of work puts upon them. Chronic periostitis may be excited or acute inflammation, which would necessitate removal of the work. Owing to the tension caused by the rigid metal frame with its firmly anchored attachments, acute inflammation around roots beneath a piece of bar work often runs a very virulent course, and it is exceedingly bad practice to fix work of this kind over roots the seat of pathological conditions likely to assume an active character. In some cases a very close bite leads to frequent fracture of the artificial crowns, which are then with difficulty repaired. In other instances it is impossible to construct an apparatus which can be kept clean without removal, the lodgment of decomposing particles beneath rendering the part foul and unhealthy.

Crown bar and bridge work falls within the province of every dental practitioner; but full description of the mechanical processes which it includes does not come within the scope of a manual of dental surgery.

SALIVARY CALCULUS OR TARTAR.

SALIVA, among its other constituents, holds in solution a small proportion of earthy salts, and these salts are very liable to be deposited upon the teeth in the form of a concretion—salivary calculus or tartar. There are indeed few mouths, however healthy, which are absolutely free from deposit of tartar, whilst in some individuals with disordered health, and with local conditions favourable to the formation, it accumulates in enormous quantities. In health the saliva secreted by the parotid, sublingual and submaxillary glands is alkaline, while that secreted by the buccal glands is slightly acid.

Diseases associated with disorders of the digestive organs and with vitiation of the secretions of the mouth predispose to the formation of tartar. It is deposited upon teeth which are not subject to the friction of mastication, and it is common to see the teeth of one side of the jaw covered by the concretion when the presence of tender teeth compels the patient to use the other side alone. It accumulates often in great masses around teeth the alveoli of which are undergoing absorption. Accumulation of tartar is in most cases greatest upon the external labial surfaces of the upper molars and on the lingual aspects of the lower front teeth, owing to the proximity of these surfaces to the orifices of the salivary ducts.

The density and colour of tartar vary considerably. When rapidly deposited it is soft and friable, and light

yellow in colour; when slowly formed it is hard and darker in colour—brown, greenish, or even quite black. Where great masses exist they are often composed of strata of varying colour and density.

Analysis of tartar shows its composition to be as follows:—

Earthy phosphates	79·0
Salivary mucus	12·5
Ptyalin	1·0
Animal matter.	7·5

This analysis is only approximate, the composition of tartar being very inconstant. When recently deposited the animal matter which chiefly consists of micro-organisms is greatly in excess. If allowed to remain, this animal matter dries up and the mass comes to consist mainly of lime salts.

According to Tomes, salivary calculus differs somewhat in chemical composition according to the situation in the mouth where it is deposited. Thus that formed near Steno's duct contains most carbonate of lime, whilst in that deposited on the lower incisors phosphate of lime preponderates.

Microscopical examination shows that the animal matter entering into the formation of tartar is made up of micro-organisms of every variety from huge bacilli to micrococci, and the *débris* of broken-down epithelial cells, whilst numerous filaments of leptothrix are always present in the mass.

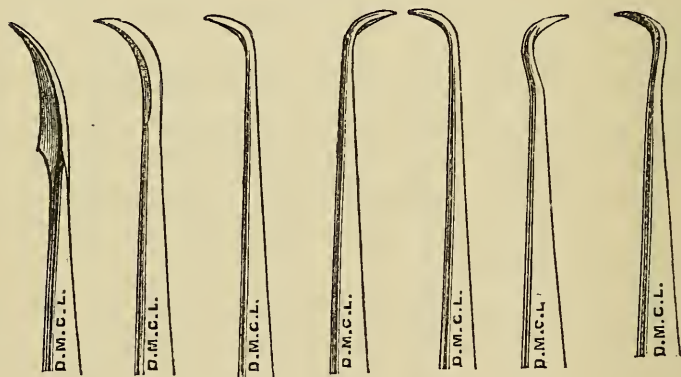
The peculiar green discoloration occurring upon the teeth of children, and most frequently affecting the labial surfaces of the front teeth, appears to be due to staining of Nasmyth's membrane, or possibly to a deposit of leptothrix. The discoloration produced by the bacteria most commonly present in the mouth is brown or yellow.

Deposition of tartar occasionally begins around the

necks of the teeth beneath the free edge of the gum, and, acting as a foreign body, it keeps up chronic inflammation of the gums and dental periosteum, and thus may constitute in some instances the sole cause of absorption of both gums and alveoli.

Treatment.—Careful use of the toothbrush and due exercise of the teeth in mastication will do much to retard and prevent the deposition of tartar, but where these fail the deposit, if of great extent, must be removed by suitable scaling instruments. Although tartar adheres tenaciously it does not of course penetrate; and unless as in honeycombed teeth the surface of enamel be

FIG. 165.



rough it is possible in most cases by careful manipulation to completely detach the concretion in scaly masses. To remove masses by scraping would be a long, fatiguing and unsatisfactory process. The aim should be to cut through the layer upon each tooth, and then by a levering movement to split it cleanly away in flakes. Scalers of various patterns light and well designed, a great advance on old-fashioned clumsy shapes, are now made. Some of these have chisel blades; others are thin and flexible, and some of each kind are curved to each

different surfaces. A useful set of scalers is shown in fig. 165. Chisel blades are not included in this set, nor one with a flat narrow thin curved blade fitted to pass round the necks of some teeth. Sometimes, as in lower front teeth when not very crowded, the passage from the front of a thin curved scaler through the spaces with the point of the instrument directed upon the surface of the enamel near the neck, will effect the dislodgment in one movement of the whole mass around the tooth.

Owing to congestion and swelling of the free edges of the gums, which almost invariably accompanies the presence of tartar, oozing of blood mostly goes on during scaling, and tends in spite of free syringing to hide the parts from view. Removal of the great bulk of the deposit having been effected, it is often well to wait a few days before completing the operation. In the interval the gums will have often become more healthy, and the remains of tartar may then be more certainly found and removed. In most instances where large deposit of tartar exists the gums and alveoli will be found more or less wasted by absorption; but sometimes absorption is slight, and the tartar is found attached to the necks of the teeth and overlaying without displacing the gum around. In some conditions, and especially in occasional instances of *pyorrhœa alveolaris*, tartar exists only in the form of hard small black nodules or separate small masses around the neck or surface of the root concealed beneath the gum. In neglected cases, where a large accumulation of tartar is found investing and binding together the teeth in one solid mass, caution must be exercised in proposing its removal. In such cases where great absorption of the alveoli has taken place the teeth will be found so loose as hardly to stand the force necessary in dislodging the tartar, or by loss of the covering and support which the tartar had afforded may be rendered so tender or so weakened as to call

for extraction—an operation to which the patient may very strongly object.

Superficial discoloration—such as occurs in children—is best removed by pumice powder, with water, and a wooden or cane point, or much more effectively and rapidly with the polishing discs and cones which are now used with the dental engine.

In the operation of scaling it is of importance not only that every particle of tartar be removed, but also that the surface of the tooth be left perfectly smooth, since a rough surface favours rapid redeposition. The teeth, when necessary, can be polished after the operation by the method just mentioned.

MORBID GROWTHS CONNECTED WITH THE TEETH.

Odontomes.—Under this name have been classified and described several varieties of malformed and monstrous teeth and neoplasms composed of confused masses of dental tissues. These growths being direct derivations from the teeth and their environment must be particularly interesting to the dental surgeon. Their etiology has been clearly made out only within late years. Much light was thrown upon the subject by the researches in earlier times of Forget, Broca, and Magitôt. In later years more knowledge was gained by the labours of Sir J. Tomes, C. Tomes, C. Heath, Salter and McEve. Mr. Bland Sutton (14) having collated all these authorities has lately gone over the subject himself, approaching it mainly from the point of view of evolution and embryology—a method through which he has elucidated many pathological problems of a similar kind. I am indebted to Mr. Sutton for a full account of his observations, as well as for several valuable illustrations, and in my description of these dental tumours I have endeavoured to embody an epitome of his work, which there can be no doubt is substantially accurate and complete.

It appears certain that odontomes can originate only during development of the teeth. At this period (as we have seen) the teeth are represented by soft tissues, which gradually assume the form of the future organs, and become calcified. During this stage of growth the formative elements may become the seat of partial or

general hypertrophy or other morbid action, followed by more or less complete calcification. The morbid process may be confined to the enamel organ, or to the dentine pulp, or may involve the follicle and all the tissues of the tooth. The most simple form of these growths is displayed in what have been called warty teeth—teeth which present nodules or excrescences projecting from some part of the surface. The excrescences most frequently spring from the neck of the tooth below the gum, and occasionally they assume the appearance of a supernumerary tooth lying in contact with the tooth to which they are attached. Section of these outgrowths shows them to be composed of dentine coated with enamel, and they sometimes contain a pulp cavity continuous with that of the tooth. The roots of warty teeth are often well formed, but in some cases, especially where numerous excrescences exist on the crown, the root is stunted and ill-formed. In these cases, along with hypertrophy of the tissues of the crown, there appears to have occurred arrest of development of the root.

On the other hand, cases sometimes occur in which the crown of the tooth is normal in form, whilst the root is abnormally large, and is composed of a confused mass of dentine and osseous tissue (cement), enclosing a vascular structure, doubtless the hypertrophied dentinal pulp. This subject has already been partly discussed in the section on abnormally formed teeth.

Another class of odontome consists of irregular masses of dental tissues mingled without definite arrangement, and bearing no resemblance to a tooth. The mass may not exceed in bulk the tooth whose place it occupies, or it may form a tumour of considerable size.

Still another variety of tumour is mainly fibrous in structure, containing scattered spots of calcification or imperfectly developed dental tissues.

Odontomes are usually either cystic or encysted, the

latter variety having no attachment to the surrounding structures except such as may have arisen from inflammatory adhesion.

The following is Mr. Bland Sutton's definition:—Odontomes are neoplasms composed of dental tissues in varying proportions and different degrees of development, arising from tooth-germs, or teeth still in the process of growth.

Using as the basis of a classification the parts concerned in the formation of a tooth, namely, enamel organ, dentine papilla, and tooth follicle, odontomes are grouped as follows:—

A. ABERRATIONS OF THE ENAMEL ORGAN.

Epithelial Odontomes.

B. ABERRATIONS OF THE FOLLICLE.

1. *Follicular Cysts.*
2. *Fibrous Odontomes.*
3. *Cementomata.*
4. *Compound Follicular Odontomes.*

C. ABERRATIONS OF THE PAPILLA.

Radicular Odontomes.

D. ABERRATIONS OF THE WHOLE TOOTH-GERM.

Composite Odontomes.

Aberrations of the Enamel Organ. *Epithelial Odontomes.*—These tumours are usually composed of a congeries of small cysts rarely over an inch in diameter, filled with mucoid fluid, separated by thin septa mostly fibrous but sometimes osseous.

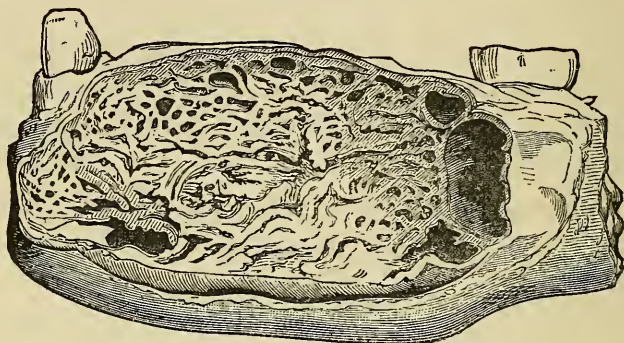
In typical specimens the tumour displays on section a congeries of cysts, in size very various.

Histologically, these tumours are principally composed of branching and anastomosing columns of epithelium. The stroma is composed of fibrous tissue.

The naked-eye appearance of these tumours, well displayed in fig. 166, is very characteristic.

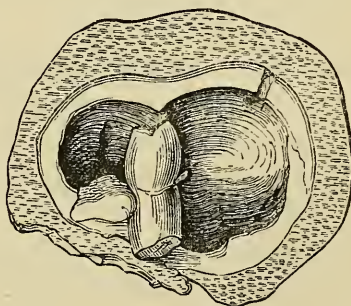
Aberrations of the Follicle. *Follicular Odontomes.*
—In this category Mr. Sutton includes dentigerous cysts, but as the term has been loosely applied to any cyst which bears teeth, even ovarian dermoids, he styles those connected with teeth *follicular* cysts or odontomes.

FIG. 166.



They arise in relation with teeth which have remained within the jaws—buried teeth, described in an earlier chapter. They are most frequently connected with molars. In the upper jaw the cyst may invade the antrum.

FIG. 167.



A glance at the relation of a tooth to its follicle will explain that if fluid accumulates between the tooth and follicle a cyst will be formed, and its size will depend

upon the amount of fluid. Sir J. Tomes first suggested that follicular cysts are due to the excessive formation, around a retained tooth, between the enamel and the wall of the follicle, of the fluid which, small in quantity, is normally found after the complete development of a tooth.

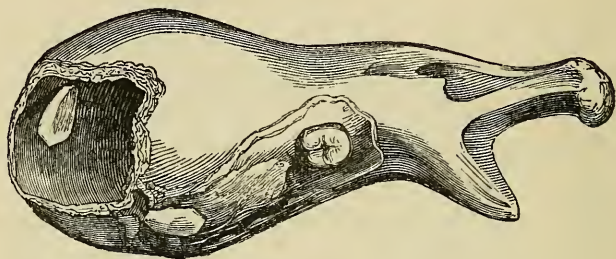
The thickness of the walls is very various, in some thin and crepitant, in others measuring half an inch or more. The contained teeth are often ill-developed. Sometimes the crown is well-formed, but the fang is imperfect or truncated as in the bicuspid in fig. 167, which represents a typical follicular cyst laid open. In a few specimens the tooth is loose in the cavity; occasionally it is inverted and not infrequently wanting.

The following case, with the illustration taken from Mr. Heath's work (4), will serve to exemplify the common course and history of dentigerous cysts, and also to make evident the importance of the rule that in cases of doubtful diagnosis the nature of tumours of the jaws should be put beyond question by incision and exploration before further operative procedures are undertaken.

In this case the cyst occurred in the lower jaw, and gave rise to a general expansion of the bone rather than a distinct tumour, but the disease was mistaken for a solid tumour. The patient was a girl aged thirteen. The tumour was large and resistant, occupied the left side, and had been growing six months. No opening could be detected, though there was a constant offensive discharge from the surface. The surgeon in charge of the case removed the left half of the jaw, from the symphysis to the articulation. The tumour (fig. 168) gave exit to a quantity of foetid pus on being opened, and it proved to be a bony cyst formed by expansion of the two plates of the jaw. The cavity was lined with a thick vascular membrane, and at the bottom the canine

tooth was seen projecting from the wall. The case was evidently, therefore, one of dentigerous cyst due to the non-development of the canine tooth, the contents of which had from some cause become purulent.

FIG. 168.

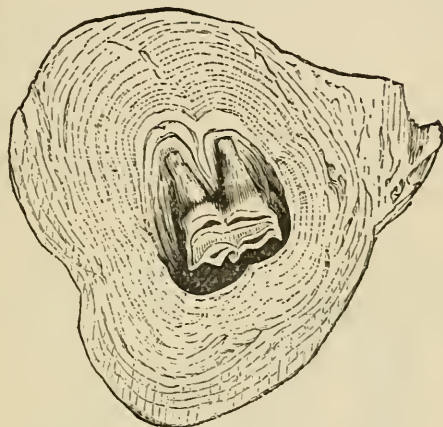

Fibrous Odontomes. — These growths Mr. Sutton traces to hypertrophy of the tooth sac—the capsule of the developing tooth. Under certain conditions this capsule becomes greatly increased in thickness and so thoroughly encysts the tooth that it is never erupted. Such thickened capsules are often mistaken for fibrous tumours especially if the tooth is small and ill-developed. Under the microscope they present a laminated appearance with strata of calcific matter.

Mr. Sutton considers there is good reason for the belief that rickets is responsible for some of these thickened capsules. It has long been known that in rickety children the teeth are late in appearing, and several years ago he pointed out that the delay might be attributed to abnormal thickness of the follicle. That the tooth sac should thicken in rickety children is borne out by the fact that this disease affects most particularly membranes engaged in the production of bone; and specimens are preserved in the museums which further support this opinion. Fig. 169 clearly shows the structure typical of this class of odontome.

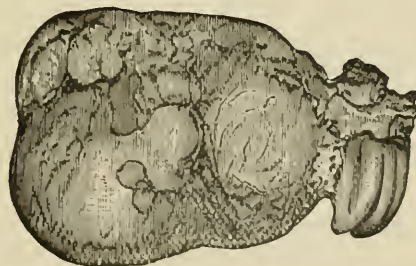
In fibrous odontomes there is found a well-formed tooth, although odontomes are usually devoid of all resemblance to teeth, so far as shape is concerned. In the upper jaw

FIG. 169.



odontomes often have a well-shaped tooth attached to them, as in Hare's case (see fig. 175); in the lower jaw they mostly consist of a conglomeration of dental tissues. This difference Mr. Sutton explains by the anatomical

FIG. 170.

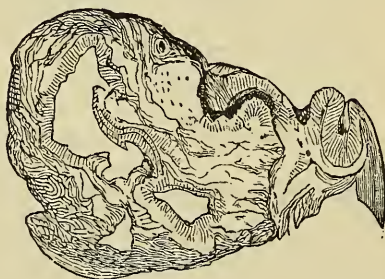


differences of the jaw bones. In the upper jaw odontomes invade and grow freely in the antrum, and attain a far larger size than is possible between the two resisting plates of the lower jaw.

Cementomata.—When the capsule of a tooth becomes enlarged, as in the odontomes just considered, and this thick capsule becomes ossified, the tooth will become embedded in a mass of cement. To this form of odontome the name cementoma is applied.

Among classical odontomes, the most typical specimen, which illustrates well the characters, macroscopical and microscopical, of a cementoma is that recorded by Dr. Forget from the lower jaw of a man aged forty. Before operating on the tumour, it was determined to extract a

FIG. 171.



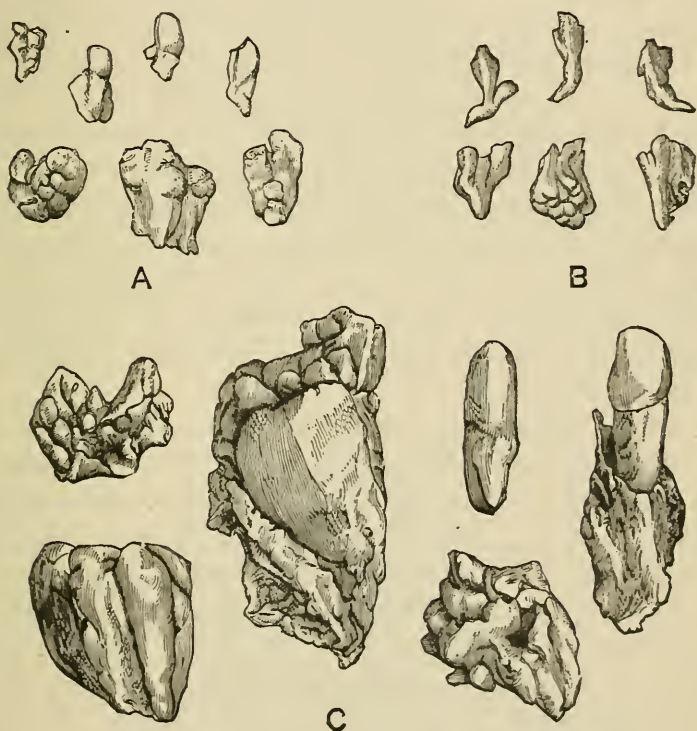
decayed molar, and the odontome came away with it. Under the microscope the tumour, which was of the size of a pigeon's egg, consisted of cement only (figs. 170 and 171). Broca gives a drawing representing a vertical section through this odontome. The shape, disposition, and structure of this odontome plainly show that it had its origin in an overgrown, ossified, dental follicle.

Compound Follicular Odontomes.—Mr. Sutton accounts for these growths on the supposition that they are derived from a thickened capsule which has ossified sporadically instead of *en masse*. The tumour will then contain a number of small teeth or denticles consisting of cement, or dentine, or even ill-shaped teeth composed of three dental elements, cement, dentine, and

enamel. The number of teeth and denticles in such tumours vary greatly, and may reach a total of three or four hundred.

Tumours of this character have been described by several observers. Amongst the most noteworthy may be mentioned the following:—

FIG. 172.



Tellander, of Stockholm, met with a case in a woman aged twenty-seven years. The right upper first molar, bicuspid and canine of the permanent set had not erupted, but the spot where these teeth should have been was occupied by a hard, painless enlargement, which the patient had noticed since the age of twelve years. Subsequently this swelling was found to contain

minute teeth. There were nine single teeth, each one perfect in itself, having a conical root with a conical crown—tipped with enamel; also six masses built up of adherent single teeth. The denticles presented the usual characters of supernumerary teeth. About a year afterwards a tooth was found making its appearance in the spot from which the host of teeth was removed. A few of the teeth are represented in the group A in fig. 172.

A similar case has been recorded by Sir John Tomes, the details of which were communicated to him by Mr. Mathias, whilst on medical service in India. A Hindoo, aged twenty, had a large number of ill-formed teeth united. Further search was instituted, until at last fifteen masses of supernumerary teeth and bone were removed. The soft parts rapidly healed, the deformity disappeared; the only peculiarity noticeable was the absence of the central and lateral incisors. The canines occupied their usual position. A few of the fragments are shown in fig. 172 C.

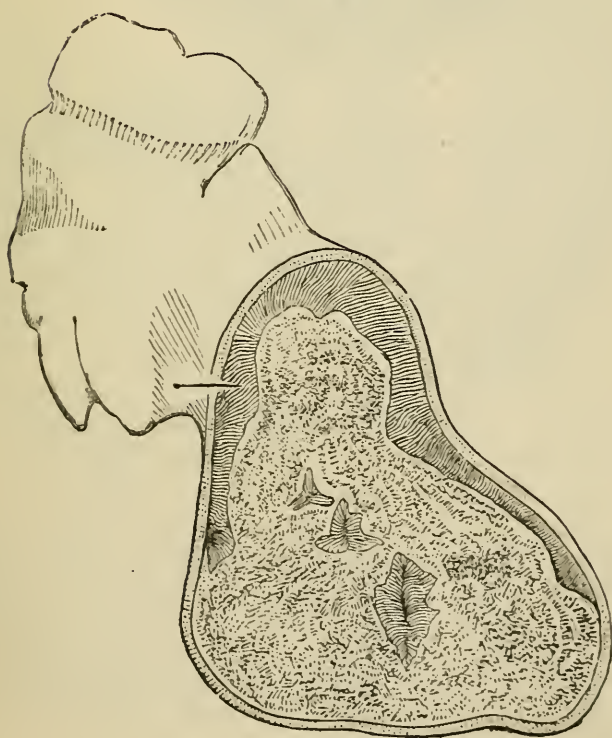
A third example of this remarkable condition has been recorded by Professor Windle and Mr. Humphreys. The case occurred in the practice of Mr. Sims at the Dental Hospital, Birmingham. The tumour occurred in the mouth of a boy aged ten years. It was found that neither the deciduous nor permanent right lateral incisor or canine had erupted. The space thus unoccupied was filled by a tumour with dense unyielding walls which occasioned no discomfort. On opening this cyst forty small denticles of curious and irregular forms were removed from the interior. Some of the denticles are represented in the accompanying drawing, fig. 172 B. The largest possessed fourteen cusps. Many were caniniform, with fairly well-formed crowns and roots, the former being covered with enamel. Some resembled supernumerary teeth, while others consisted of several small denticles cemented together.

Radicular Odontomes.—This term is applied to odontomes which arise after the crown of the tooth has

FIG. 173.

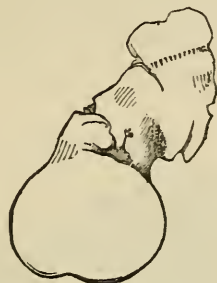

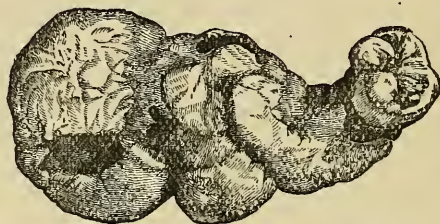FIG. 174.



been completed, and while the roots are in process of formation. As the crown of the tooth, when once

formed, is unalterable, it naturally follows that should the root develop an odontome, enamel cannot enter into its composition, which, for the most part, would consist of dentine and osteo-dentine in varying proportions, these two tissues being the result of the activity of the papilla.

FIG. 175.



The well-known specimen described by Salter, and represented in figs. 173 (natural size) and 174 (a magnified section), illustrates a typical radicular odontome. In this specimen the tumour is clearly connected with the fangs. The outer layer of the odontome is composed of cement; within this is a layer of dentine, deficient in the lower part of the tumour; within this is a nucleus of calcified pulp.

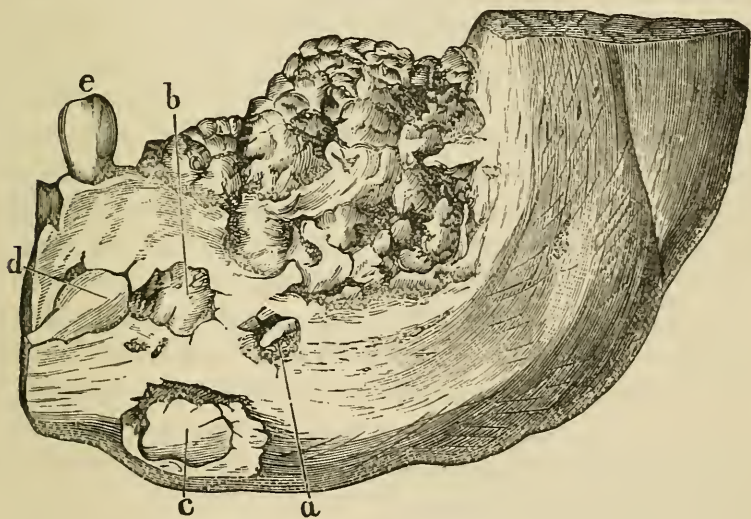
Mr. Hare, of Limerick, removed from the upper jaw of a man aged forty-one the odontome depicted in fig. 175. This specimen was originally described by Sir John Tomes in 1863, but it was examined and re-described in 1872 by Mr. Charles Tomes. The mass is invested by cement; inside this casing is a shell of dentine, the tubes radiating outward and disposed with some regularity. This dentine was deficient at the distal end of the tumour; its interior was filled with an ill-defined osseous material.

Aberrations of the whole tooth-germ. *Composite Odontomata*.—This is a convenient term to apply

to those hard tooth tumours which bear little or no resemblance in shape to teeth, but occur in the jaws, consisting of a disordered conglomeration of enamel, dentine, and cement. Such odontomes may be considered as arising from an abnormal growth of all the elements of a tooth-germ—enamel-organ, papilla, and follicle.

Not only is this class of odontomes composite in that the tumours comprised in it originate from all the elements of a tooth-germ, but they are composite in another

FIG. 176.



sense. In the majority of cases the tumour is composed of two or more tooth-germs indiscriminately fused. But they differ from the cementomata containing two or more teeth from the fact that the various parts of the teeth composing the mass are indistinguishably mixed, whereas the individual teeth implicated in a cementoma can be clearly defined.

Forget's well-known case is placed by Mr. Sutton in this class. The patient, a man aged twenty, had

suffered with disease of the lower jaw since he was five years old. Upon looking into the mouth, a round, smooth tumour, hard and unyielding, was seen occupying nearly the whole of the left side of the jaw. None of the teeth, beyond the first bicuspid, were present. The portion of jaw shown in the engraving (fig. 176) was removed by operation by M. Forget, under whose care the case came. Examination of this portion showed that the jaw between the first bicuspid and the ramus was converted into a cavity occupied by a hard, oval mass of the size of an egg, having an uneven surface covered here and there with minute tubercles invested by a layer of enamel. Section and microscopical examination proved the tumour to consist of dentine with enamel on the surface and dipping into crevices, at the bottom of which, as well as in other parts, portions of cement were found. Between the tumour and osseous walls enclosing it was a thick membrane of a fibro-cellular structure. M. Forget regarded the case as one of fusion and hypertrophy of the last two molars.

At the date of the occurrence of this tumour (1855) the exact nature of growths of this kind had not been clearly ascertained, and hence excision of a portion of the jaw was performed, instead of enucleation of the tumour, which evidently would have served equally well for the cure of the disease.

The letters *a* and *b* indicate portions of the tumour projecting through the bone; at *c*, where the enclosing bone is cut away, the crown of an inverted molar is seen lying between the tumour and the jaw; *d* is the second bicuspid lying beneath the first, *e*.

It is supposed that odontomes are more frequent in the lower than the upper jaw, but there is good ground for the belief that many such tumours have been erroneously described as exostoses of the antrum.

The strange specimen illustrated (fig. 54) on page 59,

described in the chapter on supernumerary teeth, serves to bridge the gap between what Mr. Sutton styles compound follicular cysts and composite odontomes.

Treatment.—Odontomes do not necessarily give rise to irritation or disease, and the variety in which the morbid changes are confined to the root may, on the contrary, remain in position for years, serving the purpose of a tooth. Should they, however, constitute a deformity, become a source of irritation, or the centre of inflammatory action, they must be removed. Their extraction can be accomplished in some cases by means of an ordinary tooth-forceps, and, should it be necessary, the bone may be divided by bone-forceps to facilitate the operation. The fibrous variety may be removed by similar means. The cyst having been laid open, the mass may be turned out with the handle of a strong scalpel or with a gouge or elevator.

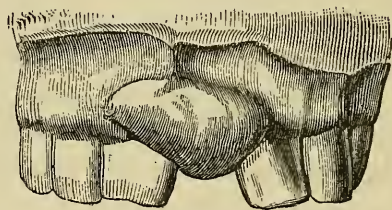
The treatment of cysts of the jaw, classed by Mr. Sutton as follicular odontomes, consists in laying them open freely, in removing teeth when these are contained within, and plugging the cavity with lint, so as to destroy the secreting surface. The incisions ought to be made within the mouth when possible, so as to avoid subsequent deformity.

It cannot be too strongly insisted that in all cases of tumour of the jaw of doubtful diagnosis exploratory incisions—within the mouth if possible—ought to be made to ascertain the true character of the disease, before a formidable operation like excision of the jaw is proposed. An operation of this magnitude and severity was—as we have seen—not infrequently performed for the removal of odontomes in former times before the real nature of these growths was recognised.

Epulis is a tumour, either fibrous or myeloid in character, attached to and springing from the maxillary periosteum. It generally commences between two teeth,

which become gradually pushed apart and loosened ; but it sometimes springs from a part of the bone distant from the teeth. It grows slowly and painlessly, forming a firm, rounded, often lobulated mass, covered with mucous membrane. The fibroid variety commonly ossify, the deposition of bone progressing from the point of attachment towards the surface. A case of epulis in its simplest form is shown in fig. 177, from Mr.

FIG. 177.



Heath's work. If neglected epulis sometimes reaches an enormous size, encroaches upon the cavities of the nose and eye, and produces great deformity. In the later stages it may ulcerate, and frequent hæmorrhages taking place, the growth closely simulates malignant disease. Epulis is believed to be due in some cases to irritation of decayed teeth or to injuries of the alveoli, such as sometimes occur in extracting teeth, but in most instances the tumour cannot be clearly traced to these causes. I have seen several cases in which a small fibrous tumour, identical in structure with epulis, in size between a pea and a spanish nut, was found attached and springing solely from the periosteum of a decayed tooth and having no attachment either to the gum or maxillary periosteum. Some specimens were presented to the Odontological Society. These cases suggest a possible origin of larger growths.

The treatment consists in cutting out the tumour,

together with the portion of bone from which it springs and from which, if allowed to remain, it would probably again grow.

Osseous Tumours, or exostoses of the jaws, are occasionally met with. The most common situation of exostoses is on the inner surface of the lower jaw, where they form hard, round, smooth protuberances. They sometimes spring from the angle, and they may also grow from the neighbourhood of the antrum and other parts of the upper jaw. Osseous tumours are slow in growth and painless, and are not commonly developed to such an extent as to cause inconvenience. Their cause is obscure, but in some few cases they would appear to be associated with persistent irritation—chronic periostitis—spreading from the teeth. There is evidence that these tumours are sometimes due to ossification of growths originally cartilaginous in structure.

The treatment is excision of the tumour, which may be called for if the growth become a source of deformity or inconvenience.

DISEASES OF THE ANTRUM.

Acute Inflammation.—The roots of several teeth are separated from the cavity of the antrum by merely a thin layer of bone—sometimes the roots of the first and second molars pass within and are covered only by a thin osseous film beneath the mucous membrane. From this anatomical condition it might be supposed that inflammation of the antrum would form a very frequent accompaniment or sequela to periodontitis affecting the neighbouring teeth; but it is by no means common. The symptoms of acute inflammation are throbbing pain, with great swelling of the cheek, accompanied by more or less feverishness. If the disease run on, the pain becomes more severe, extending to the nose and frontal sinus, and an erysipelatous blush appears on the skin. The gums are red, spongy, and swollen, and when suppuration occurs there is a discharge of pus from the nostril of the affected side, either when the patient inclines his head forward and towards the sound side or when he blows his nose; and pus may flow down the throat when he assumes a horizontal position. The formation of pus is attended by rigors. If the matter find vent through the natural opening into the nose the pain and other symptoms may subside, but if it do not find an exit the symptoms persist, and the walls of the antrum become distended. The walls may bulge outwards at their thinnest parts, or, encroaching upon the neighbouring cavities, may occasion pressure upon the contents of the orbit, with

protrusion of the eyeball, closure of the lachrymal duct, and blocking up of the nostril. These complications have arisen in neglected cases.

Acute inflammation of the antrum, except in its severest symptoms, resembles some cases of dental periostitis, and it is indeed often merely an extension of that disease from the periosteum of roots to the contiguous lining membrane of the cavity.

Inflammation of the antrum may also be caused by extension of inflammation from other contiguous nasal accessory cavities. It may also arise from injury to the bone, as from a blow on the face or in extraction of teeth, or may be due to the presence of a foreign body such as a tooth fang, which in an attempted removal has been forced into the cavity. Differential diagnosis between acute inflammation of the antrum and dental periostitis and alveolar abscess must be mainly based on the greater severity of the symptoms in the former than the latter. Discharge of pus from the nostril would with the other symptoms confirm a diagnosis. Where flow of pus by the nose was obstructed, distension of the walls of the antrum—*which must not, however, be confounded with mere external swelling*—would supervene, and would help to reveal the nature of a case.

Treatment.—The exciting cause must be removed, whether it be a root lodged within, or a decayed tooth in the neighbourhood of the cavity. The extraction of the tooth will often be followed by subsidence of the symptoms, the matter, if suppuration have occurred, escaping through the alveolus. If the matter do not freely escape, the opening may be enlarged by pushing a trocar through the bone in the apex of the alveolus, or an opening may be made through the external wall of the cavity. This operation must be followed by warm fomentations and the injection of warm water into the cavity. If the discharge continue after subsi-

dence of the acute symptoms, lotions of nitrate of silver or chloride of zinc may be thrown into the cavity.

It must be remembered that the internal surfaces of the antral floor and walls are not plane and smooth. They are always more or less broken up and divided by ridges of bone and folds of mucous membrane, so that often there are formed crypts or pouches in which a foreign body is apt to lodge, and in which pus is apt to accumulate and to become inspissated. A root having been forced in may thus not be easy to find and remove. It has been necessary in some cases to search the antrum with a silver probe, with a thin shaft capable of being bent to any curve or angle, and having a small saucer-shaped end with which to sweep the interior. If necessary the opening must be enlarged with a trocar; in some cases it might be possible to expel a foreign body through the opening into the nose by means of a strong current of water thrown through the cavity from the alveolus, the patient's head being meanwhile inclined forward and to the opposite side.

Empyema.—Empyema—chronic inflammation—of the antrum, although not a common affection, is of much more frequent occurrence than has been sometimes supposed. It arises from causes similar to those which excite acute inflammation, namely, extension of disease from the mucous membrane of the nose or accessory cavities, and dental disease. The latter is probably by far the most common cause. Dental periostitis with its sequels—necrosis and exostosis—may give rise to suppuration, and this extending to the mucous membrane of the antrum or pus flowing in may establish empyema. Pent-up discharges or septic matter from suppurating or gangrenous pulps, making their way through apical root foramina into the antrum, may also constitute a cause of empyema.

Among the most prominent symptoms of empyema is

discharge of foetid pus from the nostril of the affected side—a discharge which only occurs at intervals. As the ostium maxillare—the natural opening of the antrum into the meatus of the nose—is situated high above the floor of the cavity pus can only flow out when the antrum is full or when the head is inclined forward; in recumbency the pus may flow down the throat. Pain may be absent or may show itself only in the form of neuralgia or neuralgic headache. The patient is conscious of the foetid odour; but, unlike in ozæna, it is not usually perceptible to others. Nausea, depression of spirits and general derangement of health may be also present. When from any cause the flow of pus through the ostium is obstructed—but only in such cases—the walls of the antrum may become distended, and symptoms from pressure upon neighbouring parts—such as mentioned in a previous paragraph—may arise. With these latter conditions headache or pain is always present. The pain is often neuralgic in character and sometimes is referred to the teeth, which ache violently.

Diagnosis.—This is often difficult, the real nature of the case being in many cases masked by the existence of disease of the frontal sinuses or ethmoidal cells, or presence of nasal polypi or adenoid growths. Teeth which may have been the cause of the disease will often have been extracted months or years before the case presents itself for treatment.

The symptoms already named are those most characteristic. The periodicity of the discharge is almost pathognomonic. Diagnosis must be confirmed by careful examination by means of a nasal speculum, whereby pus may be seen flowing into the middle meatus from the opening if that be patent. If any tooth in the neighbourhood show symptoms of disease about the roots it should be extracted; and teeth containing large fillings, pulpless, or with dead pulps ought to be opened up and examined.

In the first case I saw with Dr. Felix Semon, in which owing to permanent blocking of the ostium, discharge through the nose was impossible, and in which the patient had suffered much from pressure upon the orbit, the diagnosis having been mistaken for a long period, there existed a first upper molar on the affected side containing a very large stopping, evidently involving the pulp cavity. The tooth was, however, perfectly free from all subjective symptoms, and although antral disease had been long suspected, the tooth being considered free from disease, had not been removed. On extraction of the tooth the palatine root was found extensively necrosed, and its alveolus was found to communicate with the antrum by an opening large enough to admit the end of an ordinary surgical silver probe. Pus forming around the apex of this root had evidently found free vent into the antrum, and thus pain in the tooth and symptoms of tension within the alveolus had been absent. Distension of the whole cavity had also in this case given rise to so much general pain in the region that it would be with difficulty localised.

When an opening into the antrum is found at the apex of a socket, or when an exploratory puncture is made it will often happen that pus does not flow although it exists within the antrum. It may be so inspissated as not to be liquid, or may be present only in some loculi of the cavity. It is best to throw in a current of water, when, if pus be present, it will soon show itself in the stream from the nose when the patient's head is inclined forward.

Treatment.—Empyema of the antrum lies on the borderland of dentistry and surgery, and in most cases the dentist and surgeon will be called upon to act together. The first point in treatment is removal of possible exciting causes, and when these exist in the teeth they must be dealt with in the manner suggested

in the preceding paragraphs. Free drainage and irrigation of the cavity with antiseptic lotions are the further measures most called for. In most cases where a diseased tooth exists it is best to effect drainage through the alveolus, but if the teeth are all healthy, or if teeth have been drawn and the alveolus has been allowed to heal and close up prior to commencement of treatment, it may in some instances be better to tap the antrum by a puncture above the alveolus—an operation which is easily accomplished with a small trocar. Tapping the antrum through an alveolus or the alveolar surface is a simple operation. The operator must be on his guard only against allowing a drill or trocar to plunge through the cavity into the floor of the orbit—an accident which might happen if a firm grip were not kept upon an instrument, or if a patient were to make violent movement.

When tapping is performed through the alveolus of a molar the socket of a buccal rather than of a palatine root should be chosen. From the direction of the latter there is danger of opening into the floor of the nose if the antral chamber be small; or, should the opening be successfully made, the slanting position it necessitates for the tube renders adjustment of the plate difficult to the patient. These points must be considered, whichever alveolus be chosen. When no tooth is present the opening should be made in the middle line of the alveolar ridge. For the purpose of making the opening there may be used a spear-headed drill (in conjunction with the dental engine) of about one-eighth of an inch in diameter and of such a length that while allowing a considerable thickness of tissue to be penetrated before entering the antrum, there is no danger of perforating the floor of the orbit, the nozzle of the hand-piece acting as a stop. The opening is then enlarged with a trocar of a size sufficient to ensure the passage of a tube of at least one-eighth of an inch in diameter; this trocar

is fitted with a movable collar, which acts as a stop and prevents it penetrating further than desired. A model is then taken in the usual way and a plate made with a tube reaching well into the antrum; the mouth of the tube should be fitted with a screw, so that it can be opened or closed at will, or it may have a wide funnel-shaped orifice and be kept plugged with cotton wool. If the patient be wearing a plate, the tube may be fixed through an opening in that. Drainage being thus provided for, whilst entry of foreign particles is guarded against, the antrum after being carefully freed by syringing from inspissated pus must be thoroughly irrigated once or twice a day with an antiseptic lotion, such as perchloride of mercury, 1 in 2000, or carbolic acid, 1 in 50, or hydronaphthol, 1 in 100. A syringe, with a long thin nozzle to pass well up the tube, worked by an elastic ball action, and capable of throwing a continuous stream through the cavity should be used, less efficient syringing being useless. The lotion should make its exit through the nose, the head being of course inclined forward. In cases where the ostium is not patent a counter opening may be called for. Cases of empyema are often extremely chronic and resist treatment for long periods. Whilst on the one hand care must be taken to ensure thorough drainage and irrigation, on the other hand the danger of keeping up irritation by too much syringing and the use of unsuitable lotions must not be overlooked.

Tumours of the antrum.—The antrum is sometimes the seat of dentigerous, cystic, fibrous and other tumours, which call for few special observations here after the general remarks upon morbid growths of the maxillæ which have been made in a previous chapter.

An occasional sign of tumour of the antrum is protrusion or displacement of the molar teeth. To establish a diagnosis, it is often a good plan to extract one of

these teeth and explore the antrum through the alveolus. In this way the author has, in several cases, detected the character of a morbid growth in an early stage—a matter of extreme importance where the tumour is of malignant nature. In one instance (reported in the *Transactions of the Odontological Society*) this procedure led to the discovery of a cancerous growth occupying the antrum. The performance of excision, before the deeper structures have become invaded by a rapidly-increasing tumour, may often be of vital consequence.

TOOTHACHE (ODONTALGIA). NEURALGIA, AND DISEASES OF THE NERVOUS SYSTEM.

Toothache (odontalgia), that is, pain within and around teeth, is a symptom, not a distinct disease; and it accompanies most of the pathological conditions of the teeth described in previous pages. Diseased teeth, which perhaps may not themselves be the seat of pain, excite in many instances aching or neuralgic pain in neighbouring or distant teeth, which may be themselves sound. Pain of this kind occurring more or less distant from its source is perhaps most often excited by chronic inflammation of the pulps of carious teeth, and the pain is not infrequently referred to teeth—perhaps sound teeth—of the other jaw. In other cases toothache is caused by diseased roots or impacted wisdom teeth. True facial neuralgia, not arising from dental disease, is commonly accompanied by violent toothache, and in such cases patients often undergo extraction of many sound teeth which seem the source of pain, without relief to their sufferings. In mouths where there exist either teeth affected with incipient caries or cavities formed by caries, or surfaces denuded by erosion, toothache—which may have been previously absent or slight—will often arise or increase on occurrence of vitiation of the buccal secretions, such as, for instance, arises sometimes during the dyscrasia of pregnancy. Treatment of this condition (the first step being free use of antiseptic tooth powders and lotions) has been discussed in previous chapters. Toothache—it must be borne in

mind—is in the vast majority of cases due to a local cause, although this is very often not discoverable without careful minute examination of all the teeth. It is only on failure to discover a local cause after such an examination carried out with extreme care that it is safe to pronounce a case one of true neuralgia. This subject is discussed in the following paragraphs.

Facial Neuralgia.—The fact is well known that irritation of a nerve commonly manifests itself by pain at some point distant from, instead of at, the seat of injury or disease. This phenomenon cannot be accounted for, yet nevertheless presents itself daily to clinical observation, and may be exemplified by the case of an inflamed liver giving rise to pain about the right shoulder, a diseased hip-joint producing pain at the knee, and an irritated tooth pulp exciting pain at remote parts of the head and face. Pain of this reflected or sympathetic character is called neuralgia. Neuralgia, or nerve pain in a part may also occur without the existence of any discoverable lesion. It may be caused by debility, by cold, or by malaria, or it may accompany pregnancy. It may be due to disease of the great nerve centres, the brain or spinal cord. Finally lesions of nerves not necessarily painful may give rise to neuralgia in consequence of disorder of the general health—thus cases are met with frequently in which the diseased pulps of carious teeth, previously the seat of little or no pain, give rise to severe neuralgia when the patient has become lowered by disease or by exhaustion.

In a paper read before the Odontological Society (June, 1889) Dr. Ferrier—summing up the facts recently demonstrated by Gaskell and other modern physiologists—showed that the fifth nerve possesses widespread relationship not only with cranial but also with visceral regions. Irritation in any region, even though not consciously felt there, is apt to be projected on territories

deriving their nervous supply from the same or closely-related nerve centres. In this way are to be accounted for the reflex or sympathetic neuralgias of the fifth nerve, such as toothaches and headaches, in cases where no local cause exists and which are well known to arise in connection with certain visceral disturbances. Of such disturbances no better example can be adduced than the familiar one of dyscrasia during pregnancy. Disordered health during the child-bearing period is in most cases largely associated with derangement of the functions of digestion—visceral disturbance—and in a large number of cases this is accompanied by neuralgia of the face and toothache.

The patient may suffer from facial neuralgia there existing neither diseased teeth nor local cause of any kind; or decayed teeth, which have previously ached but little may, owing to distant visceral disorder, become the seat of intense pain.

Neuralgic pain is usually of a plunging, lancinating or burning character, following the course of the nerve branches. It occurs in paroxysms which are often regularly periodic, the pain commencing at a particular hour of the day, lasting a certain period, and then disappearing completely for a time.

The pathology of neuralgia has not yet been clearly made out, and the causation of the disease is often extremely obscure. When we remember the physiological fact mentioned at the opening of this section, and consider that the fifth nerve which supplies the teeth is distributed also to nearly the whole of the head and face, it is at least not difficult to understand that diseases of the teeth may act as frequent exciting causes of facial neuralgia. And since, as is pretty generally acknowledged, there are no symptoms which serve to distinguish neuralgia due either to remote or to constitutional causes from that set up entirely by local disease, it is impossible to overrate the

importance of searching for lesions of the nerve in all cases in which doubt exists.

Any of the pathological conditions of the teeth which have been described in preceding sections are capable of giving rise to neuralgic pain, but among them all chronic inflammation of the pulp is the most frequent cause. In every case of facial neuralgia a careful examination of the teeth should be made. It is not sufficient to take the patient's assurance that his teeth are not decayed, or that he does not suffer from toothache. Patients are often unconscious of the presence of disease, and teeth which do not ache are frequently the excitants of distant neuralgic pain. Patients—for example—very often suffer for months or years from "ear ache," demonstrably due to impacted or diseased lower molars or wisdom teeth—teeth which either do not ache, or do not attract attention. In every case of pain in the ear where no other cause is readily discoverable the teeth should be examined. Isolated nodules of secondary dentine which are not infrequently found in the pulps of externally healthy teeth, seem often associated with neuralgia, though their existence can never be demonstrated till the tooth has been extracted and split open. The pulps of such teeth are probably sometimes the seat of irritation or extremely mild inflammation, due to some obscure cause.

In examining a case of neuralgia it is necessary that every tooth be examined separately. Cavities hidden in the interstices or below the gum must be sought for. Fine curved dental probes carefully passed over the neck and hidden surfaces of a tooth will often discover a cavity, perhaps having only a small external aperture, but passing deeply towards the pulp. The signs of necrosis, exostosis, inflammation, and thickening of the dental periosteum must not be overlooked. The teeth may be percussed one by one; a

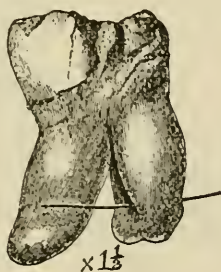
slight smart tap or two with a steel instrument directed upon the masticating surface will often reveal an extra sensibility in one or other of the set, which on further scrutiny may be found the seat of disease. A stream of cold water from a small syringe is also a useful test for extra sensibility. Decayed and broken-down wisdom teeth (common causes of neuralgia and especially of pain in the ear) are often, owing to their position, difficult to discover. They are in many instances placed at the extremity of the alveolar ridge, and in the upper jaw are invisible except with a mouth mirror; whilst in the lower jaw they are commonly hidden by folds of the cheek or by overhanging gum. Decaying in many instances before they are completely erupted, these teeth after the destruction of their crowns by caries are occasionally quite invisible, and their presence in the sockets can be ascertained only by passing a probe through the small fistulous tract in the gum which covers them. A condition similar to this may also exist in the case of any other tooth, and buried roots, especially when the seat of exostosis, are the excitants of neuralgia in numerous instances. Impacted lower wisdom teeth which may be free from decay are sometimes the cause of intense neuralgia. The neuralgia in such a case is doubtless due to direct pressure of the tooth upon the nerve trunk, which runs in close proximity to the root.

In one case of severe neuralgia in which I extracted an impacted lower wisdom tooth, it was found that the trunk of the inferior dental nerve had traversed a foramen in one root and a deep groove in the other. Complete anæsthesia of the parts supplied by the nerve immediately followed the operation, but recovery of sensation slowly returned in the course of months. Many cases have been recorded of a similar kind, although in none has the trunk of the nerve actually appeared in such close relation to a tooth. For the drawing of the tooth

(fig. 178), which is in the museum of the Odontological Society, I am indebted to Messrs. Tomes' work, in which the case is cited. The bristle shows the course taken by the nerve.

Although in cases of obstinate neuralgia there can be no doubt of the propriety of removing such diseased teeth as cannot be brought by treatment into a healthy state, it must be borne in mind that all decayed teeth need not be condemned to extraction. Neuralgia may be often cured by destroying inflamed pulps, and may be guarded against by filling cavities and protecting the sensitive structures of the teeth from irritation. In

FIG. 178.



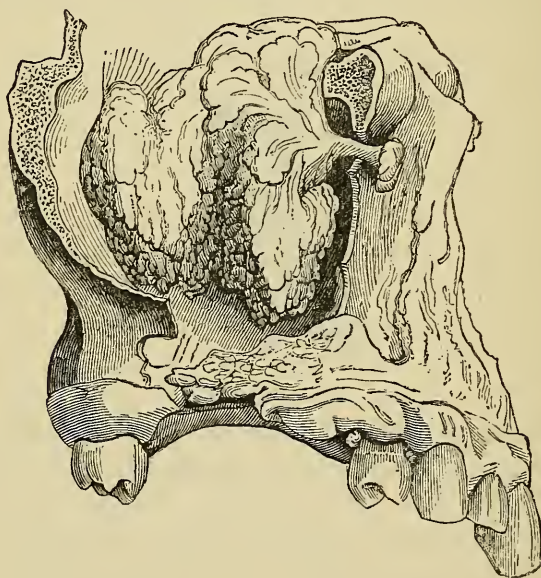
these operations care should be taken to avoid increasing the susceptibility of the teeth to changes of temperature. For this purpose any of the cements not containing chloride of zinc answer admirably, and in cases in which the pulp is protected only by a thin covering of dentine a layer of cement should be applied beneath the filling to the bottom of the cavity in the manner described in a former page.

Other surgical diseases besides those of the teeth may involve branches of the fifth nerve, and therefore originate neuralgia, and in every case of doubtful diagnosis it is necessary to examine as far as possible the whole course of the nerve. The nerve, or its branches,

may be compressed by a tumour or aneurism, or be affected by inflammation, exostosis, or necrosis of the bony canals through which they pass.

Mr. Bland Sutton (Clinical Society, 1889) has recorded a case in which a woman was supposed to be suffering from neuralgia due to bad teeth. Subsequently a slight displacement of the eyeball was detected, and a critical examination of the patient led to the diagnosis of a tumour entangling the infra-orbital nerve. The skin supplied by the palpebral, nasal, and labial branches

FIG. 179.



of this nerve was anæsthetic, yet she suffered agonising pain referred to that region. The anterior wall of the maxilla was removed by operation, and the antrum found occupied by a tumour. The whole of the maxilla was then removed, and Meckel's ganglion exposed and destroyed by the cauter. An admirable recovery resulted. On subsequent dissection the tumour was found

to be a myxoma springing from the infra-orbital nerve, and invading the orbit and antrum.

Fig. 179 is an accurate drawing of the tumour (for which I am indebted to Mr. Bland Sutton).

This unique case deserves notice for more than one reason. In the first place, in cases of intense neuralgia in the neighbourhood where every other sufficient cause is absent, it shows the necessity for careful examination of the antrum. A slowly growing tumour of the kind might keep up constant intense neuralgia for years before revealing itself by objective symptoms. In the second place, the case shows the desirableness of putting beyond doubt the character of a growth before performing such a serious operation as ablation of the whole maxilla. Had a correct diagnosis been made at an earlier stage in this instance, it can hardly be doubted that enucleation of the morbid growth would have sufficed.

Inflammation of the mucous membrane of the antrum may include the superior dental nerves. Empyema of the antrum, particularly when the cavity becomes distended by accumulation of pus, is mostly attended by severe facial neuralgia and toothache. Disease in the orbit may affect the first division of the fifth. One case is reported by Niemeyer in which a foreign body was imbedded in a branch of the nerve. Syphilitic nodes of the head are accompanied by pain, with nightly exacerbations of a character similar to neuralgia.

It has been suggested and with considerable show of reason, but without absolute proof, that extraction of teeth may act as a cause of neuralgia, particularly in patients with a predisposition to the disease. The operation undoubtedly gives rise to stretching and laceration of the delicate nerve-filaments which enter the tooth; and it is supposed either that changes may afterwards take place in the lacerated nerve-ends such as

are sometimes found in the nerves of amputated stumps the seat of neuralgia, or that the injury to the peripheral branches may in some way permanently influence the main trunk. If this be true, it is easy to understand that in facial neuralgia the removal of teeth not the origin of the pain may sometimes aggravate the evil for which relief is sought.

The discovery and removal of the exciting cause must be the first care in dealing with neuralgia, but the treatment of the predisposing causes must not be overlooked. It has been already pointed out that the state of the general health often determines whether we have to attack slight local pain or severe neuralgia. Conversely, with improvement of the general health the pain frequently disappears, although the exciting cause may remain. If the disease has been developed by any form of debility, or by malaria, full doses of quinine give almost always excellent results, and where this drug fails Fowler's solution of arsenic is said to prove effectual. Chloride of ammonium, 10 grs. every hour, gives often good results, and gelseminum and tonga are valuable remedies. Anæmia, rheumatism, the digestive disorders of pregnancy, and syphilis will each receive its appropriate treatment.

In those cases (by no means unknown) in which the cause of neuralgia, whether local, central or constitutional, cannot be discovered, an attempt alone can be made to destroy the excitability of the painful nerves. For this purpose electricity in various forms is employed. Cold, which diminishes for a time the excitability of the nerves, may be applied to the skin by means of ice or evaporating lotions; and ointments of aconite or veratria, or lotions of belladonna and chloroform, produce similar effects.

The division of the nerve at some point between the seat of pain and the brain, or (as section would be

speedily followed by reunion) the cutting out of a portion of the nerve, is a procedure which theoretically seems likely to prove efficacious by preventing communication between the affected nerve and the brain. The operation is sometimes attempted, especially when the pain appears to have its seat in the ramifications of the mental nerve. It is, however, seldom followed by permanently good results, and for three reasons: first, because it is difficult to pick out the nerve which is really the seat of pain, secondly, because it is difficult to get at and divide a part of the nerve between the brain and seat of the disease which excites the neuralgia, and lastly, because the divided parts very soon reunite. To overcome the last of these objections it has now become usual to cut out so great a length of nerve as shall effectually prevent reunion; and this procedure has in many cases proved successful. The point where division would succeed is, in many instances doubtless, so deeply placed that, even if discoverable, to reach it would be impossible. Stretching the nerve is considered by some most efficacious, but the second or third divisions of the fifth are very inaccessible for this operation.

Nervous Disorders. — Irritation of a peripheral nerve, besides exciting distant pain, may give rise to reflex irritation, or to functional disturbance of the brain or other great nerve centres, resulting in various phases of morbid action; and although dental diseases very rarely excite nervous affections of a nature more grave than neuralgia, yet there is abundant evidence that neuroses of the severer kind do occasionally result from irritation of the dental nerves. Reflex irritation may be transmitted both to motor and sympathetic fibres. Severe neuralgia of the face, for example, is sometimes accompanied by convulsion of the facial muscles, together with profuse flow of tears, saliva, and mucus, and perspiration on the skin at the seat of pain.

Esquirol and Ashburner relate somewhat doubtful cases in which mania and delusions accompanied difficult eruption of wisdom teeth, and were apparently cured by incisions into the gum over these teeth; and many not less questionable cases in which simple dental disease is set down as cause of grave neuroses are related by older writers. Sir J. Tomes reports two cases of epilepsy believed to be consequent upon diseased teeth, the seat of exostosis. Many cases of ophthalmic disease due to diseased teeth are recorded, and these have been accounted for on the supposition that irritation of dental branches of the fifth nerve may be transmitted through the ciliary system to the retina, producing hyperæmia and inflammation.

Neuralgia in or about the orbit is very commonly due to diseased teeth of the upper jaw; but the only case of eye disease more serious than neuralgia associated with the teeth which I have met with is the one here recorded. The occurrence of such a case tends to confirm the opinion of those ophthalmic surgeons who believe that similar instances are not uncommon. The case is more fully reported in the *Transactions of the Odontological Society* for 1883-84.

The patient was a middle-aged lady, unmarried, and of nervous temperament, who had suffered all her life from bad teeth, and at times from neuralgia. About the year 1880 her eyes began to be uncomfortable; she was troubled with pricking and smarting in them. In January, 1882, contraction of the muscles of the right side of the face came on, and she began to suffer from neuralgic pain on that side. In July of that year drooping of the right eyelid came on suddenly, and she discovered that she had lost the sight of her right eye. She then consulted Sir W. Hoffmeister, of Cowes, who, finding that her teeth were in a very bad state, and suspecting that they might be the cause of her ailments,

strongly advised her to have them attended to, but the patient refused.

In July, 1883, she consulted Dr. Ferrier, who found her suffering from contraction of the muscles of the right side of her face, with local hyperæsthesia; from neuralgia of that side of the face, and from inability to open the right eye, though she could do this with an effort. The closure of the eye was found to be due to spasm of the orbicularis muscle. The lens of the right eye was almost opaque. Finding that her teeth were in a very neglected state, and believing that this was the cause of the neuralgia and probably also of the cataract, Dr. Ferrier insisted that she should consult a dentist.

I found in the upper jaw the right canine broken down level with the gum, four necrosed carious front teeth and some molar roots covered with tartar. There was fixed to these teeth and stumps a vulcanite plate, also encrusted with tartar, which had not been removed from the mouth for several years. There was much inflammatory swelling and thickening extending from the roots towards the orbit. The gums were inflamed and tender, all the teeth having evidently been the centres of long-standing inflammation. In the lower jaw there were ten teeth, also coated with an enormous mass of tartar.

The upper teeth were extracted, the tartar from the lower teeth removed, and the mouth brought into a healthy state. The patient was then supplied with an upper set of artificial teeth. The result of this treatment was that the spasm of the facial muscles slowly subsided and did not recur, she was able to open the eye, and she lost the neuralgia. Her general health was also greatly improved, but there was of course no improvement in the state of the cataractous lens.

EXTRACTION OF TEETH.

THE indications for extraction have been given in the various chapters on irregularity and diseases of the teeth. A vast number of decayed teeth which might be saved are, however, too commonly extracted for the relief of easily curable transient acute pain. Acute inflammation of the pulp is by far the commonest source of pain for which extraction is demanded by patients. It is one of the conditions of dental disease, the pressing symptoms of which are most amenable to treatment, and this does not inflict so much suffering as extraction, nor does it demand greater skill on the part of the operator. The value of a particular tooth in different cases varies very much. For example, to extract an incisor or canine for the relief of pain due to inflammation of the pulp or any inflammatory condition certain to yield to suitable measures must, at the present day, be reckoned barbarous; whereas under the same circumstances extraction of a mal-placed useless wisdom tooth might be highly judicious and appropriate practice. Similar remarks apply to truncated teeth and roots. A tooth with a delicate crown which has been rapidly destroyed by caries will possess in numerous instances a massive root which may be preserved to hold a stopping or to support an artificial crown for many years. In most instances, but especially for the poor, it is better the patient should retain painless roots or decayed teeth, although unfilled, than go with edentulous jaws.

Before commencing the operation of extraction a careful examination should be made. For the reasons given in the chapter on toothache and neuralgia, it is first necessary, when the operation is for relief of suffering, to make sure that the tooth indicated by the patient is really the cause of pain. This being ascertained, the tooth may be minutely examined with mirror and probe. All instruments likely to be needed in the case should next be placed within reach. Delay in laying hands on these may prolong the patient's suffering. The effect of an anæsthetic so transient as nitrous oxide—that mostly used in dentistry—may pass off whilst time is lost in searching for instruments after the operation is commenced. In the majority of cases the teeth to be extracted are badly decayed. Deliberate scrutiny may show whether the tooth is likely to yield to a first attempt or whether the roots will need extraction separately. Seeing the uncertainty of the operation even with a sound tooth, inasmuch as it is never possible to ascertain positively beforehand whether roots may not be abnormal in size or shape, it is better in every case to have at hand root forceps and elevators suitable to deal with contingencies which seem likely to present themselves. It may be noted generally, first, that teeth of the upper jaw as a rule present less difficulties than those of the lower, the bone, particularly in the deeper parts of the alveoli, being comparatively less dense, compact and unyielding in the upper than in the lower jaw; and secondly, that teeth the seat of acute or chronic periosteal inflammation and suppuration being already loosened by the processes of disease, are proportionally more easily grasped and extracted than teeth not so affected.

No operation calls for greater readiness of resource than extraction. The contingencies which attend it occur suddenly, often without warning, and they mostly

need to be recognised and dealt with on the instant. To become a good extractor needs, therefore, thorough instruction and ample practice. Practice should be systematically carried out on the dead subject before the student is allowed to operate on the living. It is only in this way that he can so educate his sense of touch as to rapidly recognise the varying conditions which suddenly present themselves whilst wielding instruments during an operation.

The instruments employed almost exclusively are forceps. These are made with blades of various patterns adapted to fit the different classes of teeth, and to grasp without crushing them. Their edges are sharp that they may be readily insinuated between the edge of the gum and the neck of the tooth, and forced towards the socket.

No dental operation depends for success so much as extraction on the design and quality of instruments. With badly-made, blunt-edged forceps it is impossible to obtain a sufficiently firm and deep grip, and difficult to avoid crushing and splintering the tooth. Every pair of forceps ought in the making to be separately fitted to a tooth of average size. The steel should be of the best quality and temper, so that the blades may possess the requisite strength whilst not being thick and clumsy. The edges should be fine and should be kept sharp. They are very apt to be turned by forcible contact with the alveolar margin, and if this happens they should be carefully set before they are again used. If a cutler is not accessible, this can be done with a file, followed by a small water-of-Ayr stone hone, or better, with stone discs and the dental engine. A well-made forceps applied to a tooth ought in different stages of the operation to fit as accurately as the instruments represented in figs. 180, 181, 184, 187 and 189. The blades of a badly-designed forceps will often be found to exert great crush-

ing force at a single point only on the sides of the tooth instead of distributing the pressure evenly throughout.

The patient during extraction may be placed on a couch with the shoulders raised upon pillows and the head thrown back in a good light, the surgeon standing in some cases on the patient's right side, in some behind the head. This arrangement will serve for any tooth, and is particularly convenient for performance of prolonged operations with anæsthetics. For extraction of teeth of the lower jaw (of course where an anæsthetic is not used) the patient may be seated on a low chair or stool, with the head either firmly grasped between the operator's knees or held by an assistant, who at the same time may with one hand support and fix the jaw. If in a dentist's chair, the patient, when an upper tooth is to be drawn, should be thrown back at a moderate angle, with the head about as high as the surgeon's breast; for a tooth of the under jaw the chair should be almost upright and with the patient's head about on a level with the surgeon's hip.

An expert operator having a dentist's chair and usual appliances will in ordinary circumstances rarely need assistance in extracting a tooth. An assistant knowing what to do and how to do it is, however, always useful, and where rapidity is called for—as, for example, when nitrous oxide is used—may be very valuable. Standing behind the patient when upper teeth are to be drawn, he may firmly grasp and fix the patient's head and turn it when needful towards the surgeon. When lower teeth are to be removed the assistant may stand on the patient's left and with one hand steady the head, whilst with the other he takes a firm grip of the chin or jaw and presses it upwards and backwards so as to oppose the force exerted by the operator to enable him with certainty to thrust the instrument home and to set both hands free for the direct work of the moment.

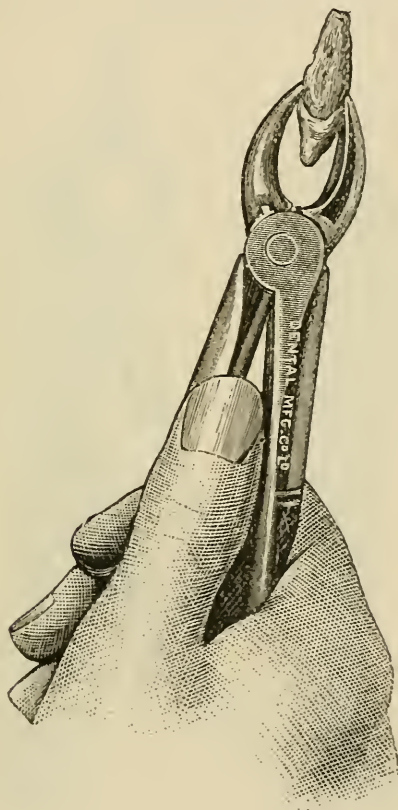
The operation of extraction consists of two distinct actions, first the seizure of the tooth, and second the loosening of its connections, and its withdrawal from the socket. It is upon the careful performance of the first step of the operation that success in the main depends.

The seizure of the teeth of each class is effected in the same manner. The forceps is lightly applied to the tooth, and the edges insinuated within the free edge of the gum. It is then pushed along the root, enough force being steadily exercised to drive the blades well round the root down to and within the edge of the alveolus. The grasp is then tightened, but not to such an extent as to crush the tooth, and the next step of the operation is proceeded with. As soon as the tooth is felt to yield the forceps may be pressed still deeper, so as to embrace the root within the socket, to obtain more power and to avoid breaking off the crown. It is the exception for any serious difficulty to present itself in the removal of a tooth effectually grasped in the way described, and the utmost care must therefore be taken to ensure this. The amount of resistance in any case cannot be discovered until the operation has advanced. A tooth which is loose to the touch may yet be held in place by wide-spreading or enlarged or exostosed roots; and teeth, especially molars, with small crowns often possess roots of disproportionate size. To carry out deliberately and fully the first stage of the operation is not to inflict unnecessary pain. Should the tooth prove of weak attachment very little more will be needed to extract it, whilst if it is firmly fixed the deep secure grip of the forceps will shorten and make certain the final stage.

It is not necessary, as it was with the obsolete key, to separate the gum from the neck of the tooth by means of the lancet before applying the forceps. The connection of these parts is slight, and moreover, they are divided

with greater readiness and certainty by the sharp cutting edges of well-made forceps than with a scalpel. The mode of holding forceps and applying them to teeth is shown in figs. 180, 181, 184, 187 and 189.

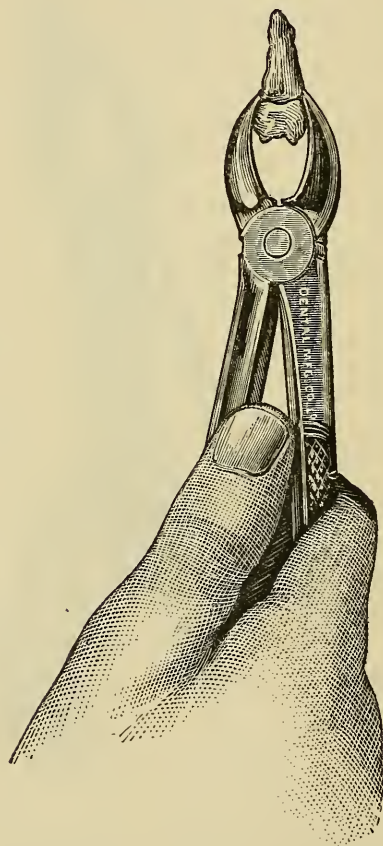
FIG. 180.



In the second stage of the operation the method of applying force is modified with each class of tooth, since the roots in each class vary in number, position, form, and size, and the investing bone offers less resistance in some directions than in others. This stage of the operation, although distinct from the first, is really

continuous with it, the whole procedure being effected with an even unbroken series of movements. The operation may be performed rapidly by a practised hand, but it must be remembered that an attempt to wrench a tooth from its socket by force, either wrongly directed

FIG. 181.



or recklessly applied, will, in most cases, result in fracture of the tooth, and may also inflict severe injury upon the jaw and surrounding parts.

The articulation of a tooth with its socket has been compared very appropriately to the impaction of a nail

in wood, and if the student considers and recognises the method necessary to draw a nail intact from its position *without injury to the surrounding wood*, he will perceive the principles upon which tooth extraction must also be carried out. The necessity of a deep grip has been already dwelt upon. It will be next evident that loosening movements must not be carried to excess in one

FIG. 182.




FIG. 183.

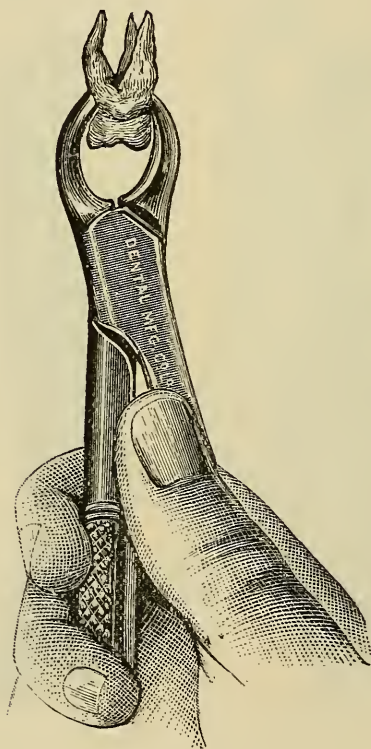


direction. Too far forcing outward or inward may instead of bending fracture alveolar walls or snap instead of loosening a twisted or curved root. In nearly every case forcible pulling besides loosening movements are needed to finally detach a tooth.

The forceps for the extraction of upper incisors is

shown in fig. 180. These teeth have conical roots, and their extraction is accomplished by rotating them to the slight degree necessary to loosen them, and pulling them downwards and a little forwards. Upper canines require a stronger but similar instrument, and they are removed by the same method. The roots of incisors and canines are often laterally flattened and besides

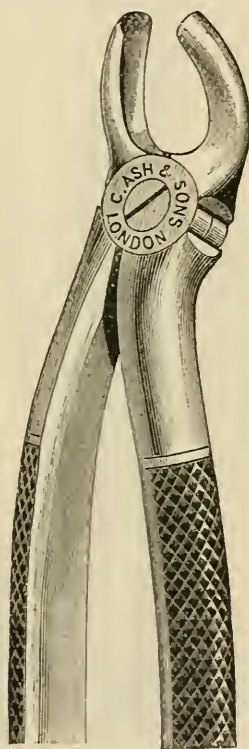FIG. 184.



curved, oftenest backwards. It is only when they are regularly conical and straight that they readily yield to a twisting movement, and it is mostly necessary besides to force them a little forward towards the weakest portion of their socket.

The forceps for upper bicuspid is shown in fig. 181. It resembles that used for the incisors and canines, but has narrower blades, and handles bent to clear the lower teeth. The upper bicuspid having roots flattened laterally cannot be rotated. They are loosened by forcing them steadily outwards. They are then moved to and fro from within outwards, and pulled downwards.

FIG. 185.



Two forceps are required for the upper molars, one adapted to the teeth of the right side, one to those of the left (figs. 182, 183). The outer blade is formed in two curves to contain the external roots, the inner blade is designed to grasp the internal root. A well-fitting

forceps applied to an upper molar is shown in fig. 184. The force in extracting these teeth is first applied in the outward direction, for the reason that the external alveolar plate offers less resistance than the inner, while the direction of the palatine root is such that it is likely to be snapped in an attempt to move the tooth at first inwards. As soon as the tooth yields it is moved from side to side, and pulled downwards.

FIG. 186.

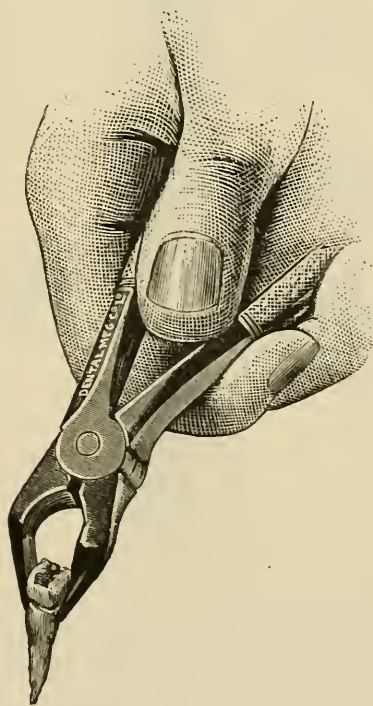


Upper wisdom teeth are extracted in the same way as upper molars. The removal of these teeth, however, rarely requires great force, their roots being often connate and the bone around being cancellated and soft. Ordinary molar forceps may be used for these teeth, but

they are more conveniently reached by an instrument—such as shown in fig. 185—specially curved to pass to their position at the extremity of the jaw.

Lower incisor roots are much flattened laterally. These teeth are therefore to be loosened by bending them forwards, and are then completely detached by a to-and-fro movement from within outwards, combined with an upward pull. The forceps for these teeth is depicted in fig. 186.

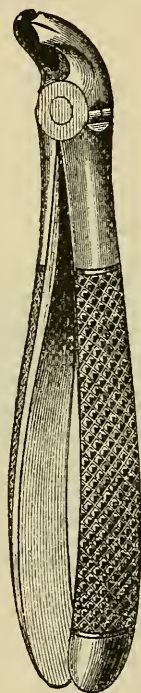
FIG. 187.



Lower canines, having somewhat conical roots, are loosened by a rotatory, combined with a forward movement, and drawn by an upward pull. The forceps closely resemble those used for the incisors.

The lower bicuspid, having roots flattened laterally, are extracted by forcing them outwards until they are felt to give, then moving them from side to side and at the same time drawing them upwards; the forceps is shown in fig. 187.

FIG. 188.

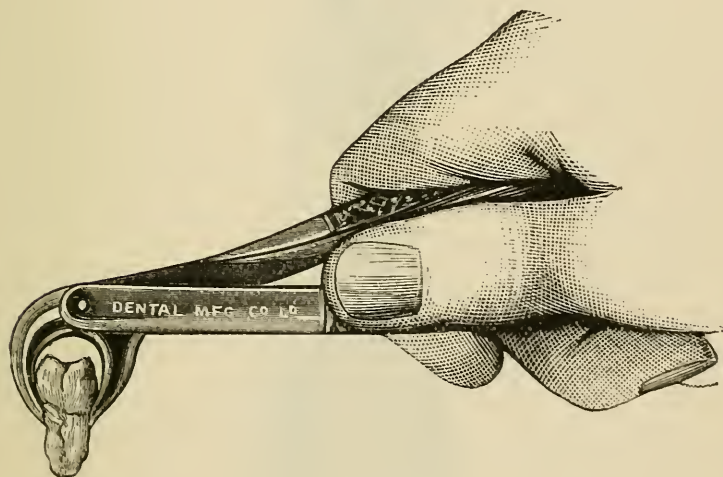


After applying forceps to lower bicuspid and molars the point of the thumb of the left hand may often be conveniently placed over the joint of the instrument whilst the fingers press the jaw upwards from beneath. In this way the forceps is guided in the desired direction, enough power is obtained to drive it home, and the instrument is prevented from coming into violent contact with the upper jaw at the moment the tooth leaves

the socket, whilst at the same time the danger of dislocating the jaw is guarded against. This accident has occurred in some cases.

The lower molars are as a rule the only teeth which commonly call for the exercise of great force in their removal; and this occasionally will try the strength of a powerful hand. This is owing to the great size of the roots, which are often spread or twisted within the jaw, and to the dense unyielding character of the bone

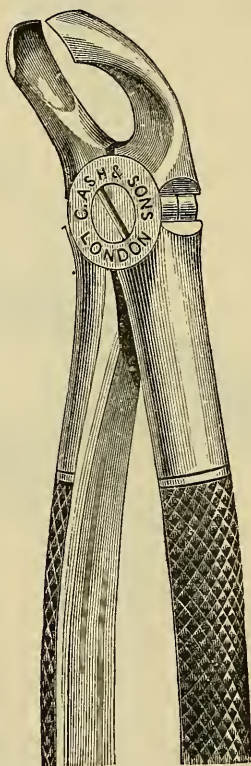
FIG. 189.



which envelops them. At the region of the first lower molar the external alveolar wall offers as a rule less resistance than the inner, and these teeth in extraction are best forced in the outward direction. About the second molar the external layer of bone becomes massive and dense, and these teeth yield most easily to force directed inwards. When started a lower molar is moved to and fro from within outwards and pulled upwards. Should the tooth offer great resistance, a backward and forward tilting movement may be practised by alter-

nately elevating and depressing the handle of the forceps the better to free the roots, which are curved more or less in the backward direction. The forceps for these teeth is shown in fig. 188, but those in which more powerful leverage is obtained through the blades being at a right angle with the handles are to be preferred

FIG. 190.



by an operator who has not a very powerful wrist. A forceps of this pattern in position is shown in fig. 189. Forceps of a similar design are made also for the other teeth of the lower jaw, and present some advantages over the ordinary pattern. Besides their more power-

ful leverage they allow a better view of the parts during the operation. The modifications in movements which the wielding of these forceps call for are too obvious to need description.

Lower wisdom teeth are extracted by the same method as the second lower molars, than which, however, they

FIG. 191.



require usually less force. A forceps, shown in fig. 190, is provided, with the blades bent at such an angle to the shafts as permits their ready application to these teeth. These teeth may be extracted with the elevator as described further on.

Extraction of roots.—Extraction of single roots which are not broken or decayed within the alveolus presents no greater difficulties than removal of the

whole tooth; and indeed it is the root and not the crown which is grasped in drawing a tooth, even where the tooth is entire. The extraction of roots is therefore carried out on the principles already described. The forceps is steadily pushed along the root, and a sufficient grip upon a sound portion obtained before an attempt is made to complete the operation. As the root yields,

FIG. 192.



the thrusting of the instrument deeper may be continued, and by giving the forceps at this time a slightly rotary movement, the blades are made to penetrate more readily. When the root is extensively decayed or broken within the alveolus the difficulties of root extraction begin. Forceps are used with smaller and more slender blades, that they may be more easily passed into the


socket and insinuated between the root and the surrounding bone. Fig. 191 shows a typical root forceps. These instruments are made of different sizes and strength, and with blades and handles curved and bent to reach all classes of roots. Application of the forceps to roots must be made with the utmost deliberation and care. The edges instead of passing round, are very apt to slip and rest upon the surface of the root in a position in which they cannot be forced deeper.

Properly-made forceps with keen-edged blades placed in accurate position around a root may in many cases be made to penetrate by a trephining movement. The blades of the forceps must be used as a trocar and by a rotatory action, aided by pressure, must be carried to a depth sufficient to ensure a firm hold. Sometimes a blade may be made to penetrate further along one side than another of a root, and then a judicious exercise of force may so start the root as to allow penetration of the other blade and completion of the operation. Fig. 192 represents a root forceps designed for the extraction of upper front teeth where so extensively hollowed by caries as to be readily crushed by an ordinary instrument. This instrument is provided with a screw, which is passed into the cavity before the blades are forced round the root. With this instrument I have had no experience, but it has been found useful by some operators.

In extracting roots of molars the procedure is guided by the extent of decay. If still firmly united together roots may be removed by the ordinary forceps (figs. 182, 183), used in the manner already described. Where it appears difficult to obtain a sufficiently deep hold with the ordinary instrument, forceps specially designed may be employed; but these are rarely necessary if forceps of ordinary design are kept with keen-edged blades. The special instruments are provided

with extra long and sharp-pointed blades, which are either thrust into the alveolus or forced through the alveolar plate. Fig. 193 shows an instrument of this

FIG. 193.




kind applied to the roots of an upper molar. Fig. 194 shows that used for the same purpose in the lower jaw.

In a large number of instances of broken down upper or lower molars, in which a deep hold is evidently needed, it is a good plan to use instead of the special instruments just described, a slender-bladed keen-edged stump

forceps, with blades as shown in fig. 191, but running into stouter shafts to resist the great force necessary with large teeth. The shape of the forceps and angle of the blades will be of course modified for different classes of upper and lower teeth. A careful examination having been made the operation is commenced by thrusting the blades with a trephining movement to a great

FIG. 194.



depth around a single root; in an upper molar very often two may be so grasped at once. It will often be found if a sufficiently deep hold is secured that not only the root actually seized, but the whole mass will come away, a mass which might have been crushed into fragments had a heavier instrument been employed; and should

one root only be withdrawn at the first effort, those remaining will commonly be so loosened as to be easily pulled out one by one.

If the body of the crown is so far decayed that the roots are nearly or altogether apart it is well to remove them separately. In some cases the external margins

FIG. 195.

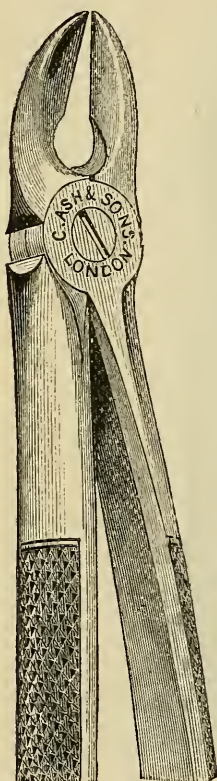
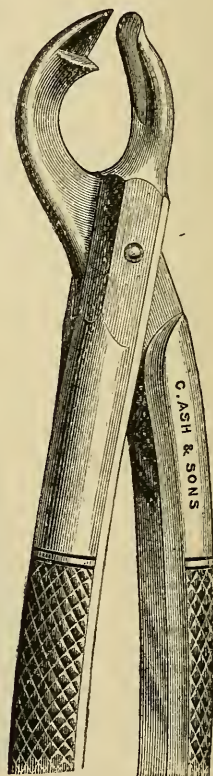


FIG. 196.



of molar roots having been broken or destroyed by decay the central uniting portion remains solid, and in this condition the mass cannot be grasped with a forceps. Where the pulp is dead the mass may be divided by a sharp spear-pointed elevator slowly and carefully worked

into the centre, or this may be better and more quickly done with a large spear-ended drill and the engine. Dividing forceps with cutting blades to be thrust into

FIG. 197



FIG. 198.

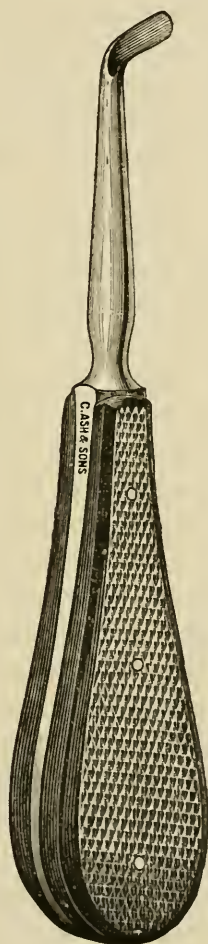
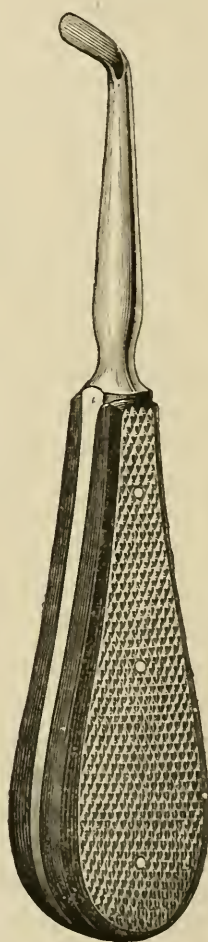


FIG. 199.



the socket are also useful. Two patterns of forceps for this purpose are shown in figs. 195 and 196. Similar instruments are made for lower teeth.

It may be here remarked that in extracting the roots of teeth of any class, *if they cannot be seized by other means*, there need be no hesitation in including the edge of the alveolus in the forceps, or in breaking through the thin alveolar walls. If this is done with due care the operation may be rapidly performed, whilst no permanent damage is inflicted, seeing that the small portion of bone forming the thin edge of the alveolus which is injured or broken away would be under ordinary circumstances soon removed by absorption after the extraction of the root.

The roots of upper molars being conical, may when separate be detached by a rotary movement; those of lower, owing to their flattened shape, require a rocking movement from within outwards; but the force must be modified in accordance with the resistance which is encountered in each instance in consequence of the varied shape and direction of roots. Other points in the extraction of roots are discussed in the next paragraphs.

Use of the Elevator.—The elevator, an instrument of great use in extraction of roots, consists of a stout handle carrying a steel shaft, which terminates in a narrow blade. The blade is thin, and concave on its inner surface, and has either a spear-shaped or a sharp horizontal edge. Various patterns are used by different operators, but the straight spear-pointed and the rectangular right and left instruments depicted in figs. 197, 198 and 199 suffice for all ordinary purposes. In applying the elevator the blade is thrust into the socket along the root until a solid surface is reached. The handle is then turned, so that the point of the blade impinges upon the root, and by a levering movement prizes it from the socket. In this procedure the fulcrum is necessarily formed, altogether or to a great extent, by the alveolar wall or by the adjoining tooth, and as the force exercised by the elevator is great, unless care be taken the former

may be extensively fractured or the latter dislodged. The elevator should be, therefore, firmly grasped, the fingers reaching close to the blade. The thumb and fingers of the left hand may in some instances serve partly or entirely as a fulcrum, and in every case they should be employed in guiding and supporting the instrument and controlling the force.

The elevator should not be, as a rule, inserted between the external alveolar wall and the root, this part of the bone being too thin to sustain much pressure. It should never be used for the extraction of upper wisdom teeth. The bone around these teeth is so weak as to be readily fractured by force in the direction in which it must be exerted by the elevator.

Some operators acquire uncommon skill in the use of this instrument, but the elevator—it may be said generally—ought not to be used for any operation which can be as well done with forceps. It is, in fact, not commonly called for except in extraction of the lower wisdom teeth and of bicuspid and molar roots of the lower jaw. Lower wisdom teeth may usually be prized from their sockets easily with the elevator, the force which it exerts being exactly in the right direction. A straight spear-bladed instrument (fig. 197) is best. This is thrust along the root at the anterior external margin of the alveolus, and as soon as a sufficient depth is reached on a sound surface of root the tooth can be gradually forced out of its socket by a levering upward and inward movement. When the tooth has been started the elevator can, when necessary, be pressed further along the root. The roots of lower bicuspids, molars and wisdom teeth may be removed with either the straight or right-angled elevator—the latter being the better for bicuspid roots and also when the instrument is to be applied to a distal surface. It will be sometimes found either easier or more expedient to attack a root at one side than the

other, the choice being governed by the position and extent of decay and the relations of neighbouring roots and teeth to the condemned root. The elevator is very useful for the removal of loose roots and fragments of roots, such as necrosed portions of temporary molars, which are so often in neglected mouths found lying attached within the gum around recently-erupted bicuspids. Other uses are found for this instrument in the dislodgment of impacted teeth and roots or partially erupted teeth. It is very often possible where a forceps could not be applied to insinuate the point of an elevator, and by a careful levering movement either to entirely dislodge a tooth or root, or so to loosen it as to render possible its removal by the forceps.

In cases of closure of the jaws due to impacted lower wisdom tooth or periostitis around molars, the elevator is often indispensable. In these cases, even with the aid of powerful lever or screw gags, it is commonly impossible to separate the jaws sufficiently to allow of the application of forceps. With an elevator the tooth may be however almost invariably reached, the swelling within the socket allows the blade to penetrate and the tooth may usually be gradually prized from its position.

Abnormal Teeth.—Although it has been almost sufficiently pointed out that teeth of the same class vary so much in the form of their roots in different instances that the operator must be prepared for difficulties or ready to modify procedure in all cases, the foregoing description of the operation of extraction has been mainly based on the supposition that the teeth to be removed were not of extraordinary or highly abnormal character. It must be now more particularly pointed out that greater difficulties may arise in consequence of extremely irregular formation of the roots. Thus they may be so curved, or, in the case of molars, so spread as to require much more than ordinary force

to remove them; indeed, the roots are sometimes so placed in the jaw that it is impossible to remove the tooth without snapping one or more of the roots or breaking away a portion of the alveolus. The shape of many roots renders impossible their removal unless piecemeal. The portion of the alveolus most liable to be thus fractured is the septum between the roots of the molars, and especially the lower molars. The roots of these teeth, wide apart at the neck, sometimes converge towards their apices, and cannot be separated from the plate of bone which they enclose.

If unusual resistance be met with, an abnormal arrangement of the roots may be suspected. Such being the case, the operator must proceed cautiously and deliberately to exercise a sufficient amount of force to overcome the obstruction; and as it is impossible to ascertain the precise form of the irregularity, it will be found safer in applying this extra force to follow the instructions given for the extraction of a normal tooth, slowly, cautiously and deliberately applying force in accordance with the direction in which resistance is encountered. In spite of due care it must—as just explained—happen occasionally that a portion of a root is left in the socket. The broken piece is sometimes loosened, and may be picked out with the root-forceps or elevator; but should the fragment, consisting only of the apex of the fang, remain fixed in its original position, it may be in some cases better to leave it rather than to inflict the injury upon the bone which its withdrawal would entail. It rarely gives rise to irritation, but in due course the changes which take place in the surrounding bone lead to its loosening or extrusion.

Drawings of abnormal teeth on previous pages, figs. 42 to 47, will suggest difficulties which may occur in extraction, and figs. 200, 201 and 202 may serve suffi-

ciently to further exemplify this subject. The size, shape and curvature of roots, it may be repeated, vary so extremely that it is impossible to typify variations.

The canine (fig. 200) obviously could not be removed without either leaving the curved extremity behind in the socket or extensively breaking away the investing bone. The lower molar (fig. 160) exemplifies "dove-tailing" of the roots of these teeth within the bone, which occasionally occurs. The presence of exostoses at the apices of the fangs of this specimen would render its removal entire hardly possible. Figs. 161 and 201 exhibit upper molars with similar irregularity of the roots,

FIG. 200.



FIG. 201.

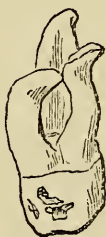
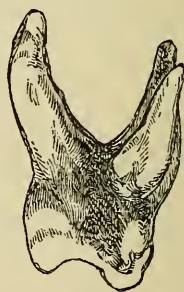
FIG. 202.



and fig. 202 depicts an upper molar of great size with unusually divergent roots. The difficulties which might present themselves in extraction of teeth organically united to their neighbours by exostosis, as illustrated in figs. 162, 163 and 164 are sufficiently obvious.

It sometimes happens that a molar with abnormal roots may be loosened, so as to move readily from side to side, but yet cannot be drawn by any amount of force which can be safely applied. In such cases the fangs of the teeth should be separated by cutting-forceps, and removed one by one. Cutting-forceps with blades fitted to be thrust into the alveolus for this purpose are shown in figs. 195, 196.

The Casualties of Tooth-Extraction.—On this subject Mr. Salter writes: “In estimating the casualties which may arise in extracting teeth it is well to consider the essential nature of the operations themselves. They are different from all or nearly all other surgical proceedings. In removing a tooth the operator wrenches or tears an organ from its living connection with the rest of the body, frequently by the exercise of great force. And this force is often applied with little intelligence—the operator being necessarily ignorant, from the hidden and varying nature of the parts, of many of the conditions with which he has to deal. I would not for a moment imply that the extraction of teeth does not require the application of dexterity with anatomical knowledge, but where great force has to be applied, that *per se* is adverse to mechanical delicacy. The force which the operator has to expend in removing a tooth is often very great indeed, occasionally one has to exercise the whole muscular power of the hand and forearm. It would be difficult to estimate, in measure of so many pounds, what is the force thus sometimes employed, but it must be immense; and with the exception of the reduction of dislocations of the larger joints, is probably in excess of that which is used in all other operations of surgery.”

From these remarks it may be inferred that minor casualties in the operation of tooth extraction must occasionally happen, even in the hands of the most experienced, and that therefore more serious accidents are likely to occur frequently in those of the reckless and unskilful.

The following list, compiled by Mr. Salter, probably includes every variety of casualty of this kind on record. Several of them have been already sufficiently referred to; others it will suffice merely to enumerate; the remainder will bear some further observations:—1. Breaking of tooth. 2. Breaking of jaw. 3. Taking

out wrong teeth. 4. Taking out two teeth instead of one. 5. Removing capsule of growing permanent tooth in extracting its temporary predecessor. 6. Tearing gum. 7. Wounds produced by slipping of elevator. 8. Extracted tooth falling into air passages. 9. Extracted tooth falling into pharynx and being swallowed. 10. Crushing the inferior maxillary nerve. 11. Dislocating the lower jaw. 12. Breaking one tooth in extracting another. 13. Cutting lip in removing a jagged extracted tooth. 14. Forcing tooth or tooth-fang into the antrum. 15. Forcing tooth-fang into an abscess excavation in maxilla.

Breaking Tooth.—Forceps being carefully applied, the deepest possible grip having been obtained upon the tooth and the force necessary to loosen it being carefully and deliberately exercised in the proper directions it will nevertheless sometimes occur, even in the most skilful hands, that the tooth will break—more or less of the roots remaining in the socket. This may be due to the extent of decay (which may not have been entirely ascertainable before the operation), which has rendered the crown and neck of the tooth too weak to stand the necessary strain, or it may happen because the roots are so spread or bent or twisted in shape that it is physically impossible they can pass from the alveolus intact. Previous examination will in some cases have prepared the surgeon for the occurrence of the accident, and he may often be able to recognize on the instant whether the remaining fragments of root have been loosened by his efforts or partly withdrawn from their sockets. Readiness to deal on the instant with the varying conditions presented under the circumstances, to perceive the uselessness of further immediate action, or to apply without hesitation stump forceps or elevator and complete the operation, can only be acquired by experience. Rather than make

ill-directed efforts, giving rise perhaps to severe suffering and injury, the operator had better pause whilst a careful examination is made. The extracted portions may indicate how much remains in the jaw. Exploration of the socket will show whether the fragments are loose and whether they remain in the depths or are partly withdrawn. It is of course as a rule desirable to extract every fragment of the condemned tooth, and the attempt should be persevered in to a due degree; but it must be obviously better to leave the deeper portions of roots for a time rather than risk the infliction of great injury upon the socket by prolonged efforts and use of great force. Moreover, it may be recollected that in cases of disease extraction of the greater portion of a tooth will in most cases suffice for the temporary, if not permanent, relief of the suffering for which the operation is demanded. This will be more particularly the case where the pain has arisen from inflammation of the pulp. Where periostitis is the disease pain is more likely to persist. The roots are, however, usually more easily extracted (as was previously explained) where inflammation to any great extent exists around them. But even in these cases urgent symptoms are often sufficiently mitigated by removal of the bulk of the tooth. This often suffices to give vent to pent-up pus and exudations, to excite bleeding and otherwise relieve the tension within the alveolus to which the pain is mainly due.

Broken Tooth and Pulp left.—In cases in which the crown of the tooth is broken away with or without a portion of root it mostly happens that the pulp comes away with the extracted portion; but in some instances the whole or a part of a living pulp remains attached to the broken roots within the socket. A pulp so exposed is exquisitely sensitive, and if left often becomes rapidly inflamed and gives rise to severe pain. If for any reason it is not desirable to extract the roots

the exposed pulp should be scooped away with a large keen-edged, spoon-bladed excavator. As the pain of this operation is extreme a general or local anæsthetic ought to be used. Free swabbing with a solution of cocaine, 20 per cent., answers well. Pure carbolic acid carefully applied, so as not to injure the surrounding parts, may be used for the same purpose. The acid diminishes sensibility and helps to destroy the pulp.

Breaking of Jaw.—Fractures involving the alveolus only to a slight extent occasionally occur, and are rarely followed by an untoward result. Fractures extending through the ramus of the lower jaw, or completely severing a considerable portion of the upper maxilla, have in rare instances been caused by the extraction of a tooth. This accident might happen either in consequence of inherent weakness of the bone or the existence of some abnormal form of the fangs of the tooth, such as already exemplified. This accident, like most of those in the above list, could be guarded against only by the application of the principles already inculcated in the general observations upon extraction of teeth. The treatment of fractured jaw due to this cause, which would not differ from that arising from other forms of violence, is described in another chapter.

Taking out wrong Tooth.—The possibility of the occurrence of this accident has been referred to in previous sections. Patients thus frequently present themselves and request that a certain tooth be extracted which on examination is found to be sound, or at least not the source of pain. In all cases in which doubt exists a careful inspection must be made to discover the offending tooth before an operation is attempted. It is often very difficult for a patient exactly to localise the seat of his trouble, and mistakes must occur when minute examination is omitted. The extraction of a wrong tooth in consequence of the slipping of the instrument is an in-

excusable accident. Should the instrument become displaced, the operation should be stopped until it is readjusted.

Taking out two Teeth instead of one.—The accidental extraction of two teeth instead of one may occur when force, as in using the elevator, is improperly exerted on an adjoining tooth. The author and others have recorded (*Transactions of the Odontological Society*) cases in which this accident has happened, although the utmost care was taken to avoid it—the movement of the condemned tooth forcing the adjacent one from its socket. The accident has most frequently happened in young and crowded jaws, and in cases where extensive caries of the mesial or distal surface of the first permanent molar had allowed the crown of the adjacent molar or bicuspid to fall somewhat within the cavity of decay and become impacted there. The accidentally extracted tooth, in such cases, should be instantly returned to its socket and pressed home. It will, in most instances, reunite within a few days, and remain apparently uninjured.

Some few cases are recorded in which, in extracting a temporary molar, the rudimentary permanent bicuspid, which lies within the diverging fangs of that tooth, has been also brought away. In such instances adhesion between the two teeth had probably existed as a result of previous inflammatory action.

Tooth falling into Air Passages.—The danger of this accident is one to be guarded against, particularly when a patient is under an anæsthetic. In such cases teeth slipping from the forceps ought to be instantly removed from the mouth. Several cases have occurred in which a tooth in these circumstances has fallen, or been drawn, into the glottis and passed into the lungs; and within the last few years an instance occurred in which the blade of a forceps was removed (by Sir W.

MacCormac in St. Thomas' Hospital) by operation from the bronchus of a patient into whose trachea it had fallen in an attempted extraction of a tooth during which the instrument was broken.

Tearing Gum.—Laceration of the gum, which was common with the obsolete key, ought not to occur with the forceps. It sometimes happens, however, that a tooth or root has become attached to the gum by strong fibrous adhesions, which are only discovered when, on loosening

FIG. 203.

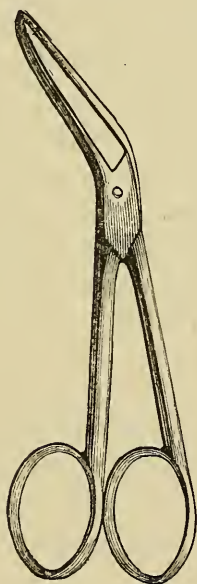
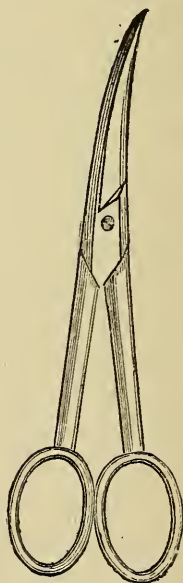


FIG. 204.



its bony connections and turning it out of its socket, the tooth still remains attached to the soft tissues of the jaw. In these cases, if the tooth were torn away, an extensive laceration of the gums might ensue. This is to be prevented by dividing the adhesions by a scalpel or scissors. Scissors for this purpose are shown in figs. 203 and 204.*

* Scissors of these patterns are very useful for excising gum overlying impacted wisdom teeth—see section on that subject.

Crushing the inferior Dental Nerve.—Several cases have been reported in which, after the extraction of a lower molar, sensation was lost at that part of the face supplied by the inferior dental nerve, which had evidently received some injury in the operation. This accident would arise from abnormal proximity of the nerve to the fang of the tooth.

In one case (described on an earlier page) under care of the author the roots of a lower wisdom tooth contained a groove and a foramen through which the inferior dental nerve had evidently passed. Complete loss of sensation over the region supplied by the nerve occurred at once on extraction of the tooth, but after lapse of a few months sensibility was again slowly but completely restored. No treatment was attempted.

Pain following the extraction of a tooth is usually slight and soon subsides unless periostitis exist. When this is present pain frequently, although not invariably, follows the operation, but this in slight cases mostly subsides within half-an-hour. Indeed, the removal of the tooth, by giving vent to exudations and relieving tension, very often puts an end at once to the pain of acute periodontitis. When pain continues, no inflammation being present, it will sometimes be found to be due to bending outward or partial fracture of the alveolar walls, whereby the periosteum is torn or stretched. This condition is often easily recognizable, particularly when a sharp margin of bone may be felt through the overlaying gum. Sometimes upon this injury, and occasionally in cases where none can be perceived, extremely painful but slight inflammation, mostly limited to the alveolus, supervenes. This may last some days, but rarely takes a bad course.

If bending out of the alveolar plates is detected it should be reduced by firm pressure between the thumb and finger. This is mostly a very painful procedure,

and an anæsthetic may be called for. It is a good rule of practice immediately after extraction of a tooth to close the alveolus in this way if the walls seem at all bent outwards. On withdrawal of the tooth the fingers may be at once applied and the procedure carried out before the patient recovers from an anæsthetic.

Inflammation of the alveolus and neighbouring bone is best treated with hot fomentations within the mouth and warmth without. Relief is afforded in some cases by frequent free syringing of the alveolus with water as warm as can be comfortably borne. Considering the amount of force exercised in the operation, it seems marvellous how few are the cases in which severe or extensive periostitis follows tooth extraction. The rare cases in which it occurs call for the treatment described in a previous chapter.

Hæmorrhage which follows extraction of teeth in most cases is extremely slight, and usually ceases within a few minutes. Occasionally, however, oozing goes on for a considerable time, whilst in rarer instances the flow is so severe as to require active measures for its arrest. The bleeding may be due to hæmophilia, or may result from laceration of an artery. The former variety, which usually takes the form of general capillary oozing, is by far the more common, but the latter, in which the blood issues in a jet, or in a full florid stream, is, although extremely rare, not unknown. The vessel liable to be wounded in extracting a tooth is the dental artery, or one of its branches, which may run in abnormal proximity to the root. In consequence of periostitis which has existed for a long period, capillary vessels, previously too minute to give rise to more than trivial bleeding, may become enlarged, so as to pour out when lacerated a considerable stream. It occasionally happens that hæmorrhage, which has ceased for a time after the extraction of a tooth, recurs after an interval

of hours or days, and this frequently happens with patients of the hæmorrhagic diathesis. Bleeding is apt to recur when the patient becomes warm in bed.

Treatment.—Slight hæmorrhage may be usually arrested by cold—the mouth being freely rinsed with cold water, or better with iced water; and cases which call for other measures beyond this are exceptional. Should the flow persist in spite of these measures, or should it be copious or arterial in character, the alveolus must be firmly plugged. The clots having been removed by syringing with cold water, a narrow strip of lint or a lightly twisted rope of absorbent cotton-wool is tightly packed into the alveolus by a blunt probe, fold upon fold, care being taken to pass it to the bottom of each division of the socket. This if effectually done will in most cases suffice, but if the bleeding continue from the margins of the socket a small compress of lint is placed in position, and pressure is kept up by causing the patient to bite forcibly upon it, and fixing the jaw by a bandage passed over the head and beneath the point of the chin. If greater pressure is needed a piece of gutta percha may be softened, and the patient be made to bite it forcibly upon the compress. A cork cut to shape answers the same purpose. Should the bleeding be severe, should much blood have been lost, or should there be reasons which make desirable the more certain instant stoppage of the flow, the plugs on insertion and compress may be charged with tincture of perchloride of iron or other styptic. The plug—which sometimes gives rise to irritation—may be carefully withdrawn after the lapse of twenty-four to forty-eight hours.

Seeing how effectually pressure may be maintained upon the whole bleeding surface by plugging the socket in the manner described, the instances must be extremely infrequent which call for other treatment. Such cases are, however, recorded. In these cases a

cast of the part might be taken, and a silver plate be struck up to cover the alveolus and the neighbouring teeth, extending well over the sides of the jaw, and leaving room for a lining. The alveolus being tightly plugged with styptic and wool, and a small compress applied, the plate, lined either with lint or softened gutta percha, would be then pressed into place.

Instances, although few and extremely rare, are recorded in which, after extraction of a tooth, every effort to arrest the hæmorrhage, including the last resource—ligature of the common carotid artery—failed, and the patient at last perished from loss of blood. In these cases (none so far as I am aware, have been reported in late years) the patients were highly hæmorrhagic, and in some of them injury—extensive laceration of gum—had been inflicted either in extracting the tooth or in attempts to arrest the bleeding afterwards.

Extraction of Temporary Teeth.—The evils resulting from premature extraction of temporary teeth have been pointed out in preceding chapters. Instances are extremely few in which extraction is really called for before the teeth have become loosened by absorption of their roots. The method of operating is exactly the same as for permanent teeth; and although special forceps may be occasionally useful a pair can be usually found among the ordinary set to answer all purposes. It must be remembered that the roots of the molars are much spread, and if they are entire the extraction of a tooth will need considerable force. This must be applied with caution lest the alveolus be badly broken or the underlying permanent bicuspid disturbed. For detaching loose crowns, and picking out necrosed roots and fragments from the gum an elevator answers admirably.

DISLOCATION AND FRACTURE OF THE JAW. CLOSURE OF THE JAWS.

DISLOCATION and fracture of the jaw—subjects dealt with fully in surgical works—are, except in so far as they immediately concern the dental surgeon, outside the scope of this book.

Dislocation is not likely to be brought before the dentist unless as an accident occurring under his own hands. It may happen during filling or extracting lower teeth, but is barely possible when due care to fix and support the bone is exercised. A jaw which has been dislocated is, however, very apt for some long time afterwards to slip out when the mouth is widely opened—as, for instance, in yawning—and therefore great care must be taken whilst operating on the teeth, especially on those of the lower jaw, of a patient who has suffered this injury.

Diagnosis.—The diagnosis can hardly be mistaken, particularly by a witness of the accident. The jaw is fixed and protruded and the mouth wide open; the flow of saliva increases, and the patient, having difficulty in swallowing, it dribbles from the mouth; articulation is difficult; the dislocated condyles can be distinguished by the fingers and a characteristic hollow may be perceived behind them. In rare cases the dislocation is unilateral.

Treatment.—To reduce the dislocation the surgeon firmly grips the jaw with one hand at either side, the thumbs being within and with their points applied upon the second molar and wisdom teeth. Pressure down-

wards is then exercised by the thumbs, whilst the chin is drawn upwards and a little forward. The dislocation seldom presents great difficulty, but in some few cases ether or chloroform may be needed either to spare pain or to cause muscular relaxation. The thumbs of the operator must be protected by thick bandages lest they be crushed by the teeth, which come together with force as the jaw springs into place.

Fracture of the jaw is not within the sphere of dentistry, but it has now become recognised that the dentist can do much in conjunction with the surgeon to render treatment more simple and certain, and to save suffering and disfigurement to the patient.

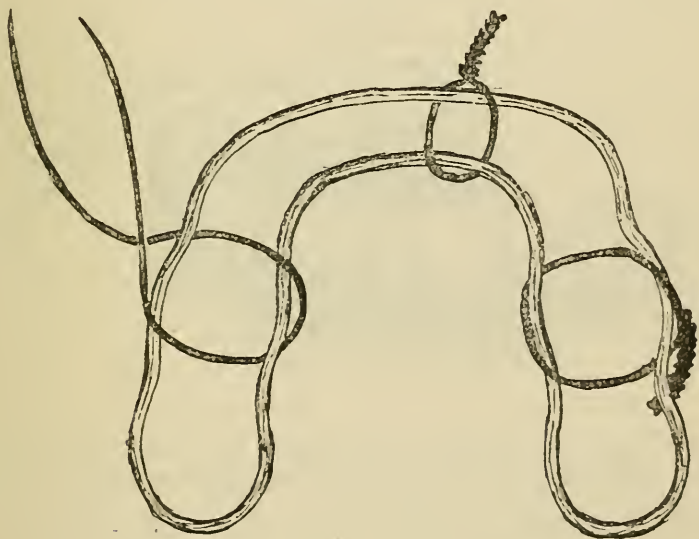
The Diagnosis of fractured jaw is simple. The history of the case rarely leaves room for doubt. The characteristic symptoms are increased mobility, deformity and crepitus. The most common seat of fracture is close to the canine, the next at the angle of the jaw.

Treatment.—Simple uncomplicated cases can be of course successfully treated by the old-fashioned gutta-percha outside splint and bandages; but even in these cases the dentist may be of great service. He can as a rule at once so fix the broken bone that the patient may from the first open his mouth to drink and eat—although of course he cannot masticate perfectly—and may be saved the discomfort, otherwise often unavoidable when the jaws are kept closed, of living for some weeks upon fluid sucked through the interstices of the teeth. The application of dental splints can be effected in simple cases by a surgeon; but even in the simplest cases the dentist may be useful. He can judge which teeth will best stand the strain of the dental splint and can avoid injury to delicate and stopped teeth. His services will also often be needed to deal with teeth broken or partly dislocated. Where the bone is fractured in more than one place and where fragments are

with difficulty kept in position the services of a dentist become almost indispensable.

By far the best instrument for treatment of fractured jaw is the simple wire splint devised by Mr. Hammond (figs. 205 and 206).^{*} By means of this apparatus the broken fragments can be at once permanently and immovably fixed. The splint takes up no appreciable room, and can with ease be kept perfectly clean. To make this splint a cast of the upper and lower jaws must be

FIG. 205.

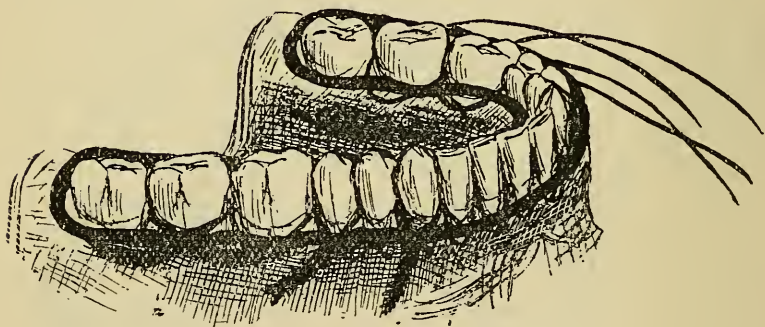


made. The teeth next the line of fracture are first ligatured with silk to steady the fragments. Wax may be used for the impressions which need not be deeper than the teeth; and if owing to swelling and pain there is difficulty in using a whole tray for the fractured

^{*} I am indebted to Mr. Hammond for these drawings which show the exact sizes of wire which he recommends for splints and ligatures.

jaw, half trays may be used. In some cases an anæsthetic may be needed in this part of the operation. If the cast shows displacement it is sawn apart and then fixed anew in position, guided by the bite of the upper model. A stout iron wire frame of the thickness depicted in the cuts is then moulded to the necks of the teeth and the ends soldered with silver solder. At some hospitals sets of splints in a few different sizes are kept in readiness; and it is found that one can usually be picked out to suit—with a little fitting—the majority of cases.

FIG. 206.



The splint is placed in position and secured by ligatures of thin iron binding wire round the necks of as many sound teeth as may seem necessary. The method of applying the ligatures, of securing them and turning the ends out of the way is made very clear by figs. 205, 206. It may be sometimes necessary to scale the teeth to facilitate passage of the wire through the spaces. It is well to tighten up the wires gradually on either side so as to equalise the strain, and the ligatures may need further tightening after lapse of a few days. An anti-septic lotion and a very soft tooth brush may be used to keep the parts clean. The treatment of teeth partly dislocated or fractured by the injury which has broken

a jaw does not differ from that already described for similar injuries in previous paragraphs, but badly damaged teeth at the seat of fracture likely to excite inflammation or interfere with union of the bone may call for removal.

Fractures extending through the body of the upper jaw are very uncommon, and they can be caused only by direct violence of an extreme degree. A case of this kind is reported in the *Transactions of the Odontological Society*, 1889, by Messrs. Ewbank and Ackery, under whose care at St. Bartholomew's Hospital it came. In this instance both bones were fractured and laterally displaced by a violent blow from a heavily laden swing. A good recovery took place. The patient was a lad in his teens. The point most dwelt upon in the treatment of this case was reduction of the displacement by means of the bite of the lower jaw, and fixation of the fractured bones by means of a modified Gunning splint. This splint, first described by Mr. Gunning, consists of a vulcanite or metal frame, having open spaces above and below, into which some or all of the teeth of either jaw may pass. These boxes being lined with gutta percha, the parts are fixed by pressing the teeth into the softened lining and bandaging the jaws together. A space is left at some convenient point through which food may be conveyed. This form of splint is especially useful in cases where both upper and lower jaw are injured.

Fractures involving the alveoli only are more common. They are due to the same causes and their treatment is similar. This consists in bringing the broken fragments into apposition, and securing them by wire ligatures passed round the teeth, or by a modification of the Hammond splint, or by a metal or vulcanite frame fitted to the palate and embracing the necks of the teeth behind. Such cases were referred to in the chapter

on injuries to the teeth. The prognosis, particularly in children, is favourable, except in cases in which the fractured portion of bone is entirely detached and the periosteum completely torn through. Under the latter circumstances necrosis is likely to follow.

Closure of the Jaws.—The only cases of this affection which are likely to come directly under the notice of the dentist are those which have been described in previous chapters as occurring in connection with impaction of lower wisdom teeth and with periostitis of the lower molars. Other causes of closure are ankylosis of the joint following inflammation; and contraction of cicatrices within the mouth and cheek, the result of injury, or of ulceration such as cancrum oris attended with great destruction of tissue. The diagnosis of these cases presents no difficulty; examination reveals their nature, and there is besides usually a clear history of disease leading up to fixation of the bone. The treatment of ankylosis consists in dividing the bone as close to the joint as practicable, and removing a small piece. The aim then must be to establish a false joint. In closure due to cicatrices although the prognosis is not favourable—cases rarely yielding permanently to the treatment—an attempt is sometimes made to gradually force the jaws apart by mechanical means; and in the construction of instruments the dentist in these cases might give valuable help. These cases, if at all severe, are usually dealt with by Esmarch's operation. This consists in cutting out a wedge-shaped piece of the lower jaw—the apex in front—extending backwards from the alveolar border, and with a base about an inch in length.

APPENDIX.

Methods of Preparing Sections of Carious Teeth for Microscopical Examination.* — Mr. Arthur Underwood has prepared a vast number of sections by the following simple method. The sections were hand cut from recently extracted teeth without any preliminary preparation whatever. A Baer's knife was used; the tooth being held in one hand, the knife in the other. With a little practice it is possible to slice off from the carious tissues sections of sufficient size (very small pieces serve the purpose) and thin enough for high-power examination. The sections are stained by immersion in methyl violet; or, if for photography, Bismark brown. Staining occupies about five minutes, at the end of which time the sections will look dark. They are next immersed in water (a watch-glassful) in order to wash out excess of dye. When the colour becomes faint purple or brown the sections are dried on blotting-paper. They are next dehydrated by immersion in spirit, but as this is apt to abstract dye watchfulness must be exercised—from two to five seconds usually suffices—and on withdrawal the drying is hastened by laying them on blotting paper. They are lastly immersed in cedar oil to clear them, again dried on blotting paper, and then mounted on slides with a drop of xylol balsam. The cover-glass ought not to be thicker than .004. With this method of preparation Mr. Underwood has been able easily to demonstrate micro-organisms under $\frac{1}{12}$ objective (oil immersion).

* To carry out the methods described some general knowledge of bacteriological microscopy is necessary. This may be obtained from current manuals.

Using the method which Mr. Pound adopted, the following materials are needed:—Absolute alcohol. Commercial alcohol (methylated spirit). Distilled water. Aniline oil. Carbolic acid. Potassium iodide. Iodine. Clove oil. Xylol. Canada balsam (dry). Shellac. Gentian or methyl violet. Fuchsine. Acid rubin and orange. Gum acacia. Swedish filter paper. Best thin slides and No. 1 glass circle covers.

(1.) *Formula of Gum Mixture for Freezing*.—Gum, 1 oz., water, 4 oz. When dissolved squeeze through muslin; then add camphorated spirit, 3 drops; and a few drops of carbolic acid to maintain the mixture aseptic.

(2.) *Aniline Gentian or Methyl Violet (Gram)*.—Saturated emulsion of aniline oil and distilled water. Filter twice. Take 20 cc. (cubic centimetres) of the filtrate; add 1 cc. of a saturated alcoholic solution of gentian or methyl violet.

(4.) *Potassic Iodide Iodine Solution (Gram)*.—Iodine, .5 gramme. Potassium iodide, 1 gramme. Distilled water, 150 cc. Add 20 cc. of water first, and when dissolved by shaking add remainder.

(5.) *Xylol Balsam*.—Balsam Canadensis (dry), dissolved in xylol (pure) to consistency of honey or syrup. After standing for a week or ten days, all dirt and *débris* will have become deposited; then decant off the clear solution into stoppered bottle.

(6.) *Shellac Varnish*.—Shellac, 1 part. Methylated alcohol, 4 parts.

(7.) *Strong Acid Rubin and Orange (commonly known as Rubin S.)*.—Acid rubin, saturated aqueous solution, orange, saturated aqueous solution. Mix equal parts.

(8.) *Dilute Acid Rubin and Orange*.—Add 1 cc. of No. 7 to water, 12 cc.

(9.) *Carbolic Fuchsine, Ziehl's*.—Fuchsine, 1 gramme, dissolved in absolute alcohol, 20 cc. Add carbolic acid 5 per cent., 100 cc. Before using, diffuse green scum by addition of a little alcohol.

Teeth after extraction should be immediately placed in alcohol (methylated spirits) for seven to fourteen days, to harden the softer carious portions. When hard the

carious dentine is cut out and soaked in water for twenty-four hours to get rid of the alcohol. Next it is immersed in gum mixture (No. 1) for twenty-four hours. Sections are then cut with Swift's ether freezing microtome, and then rinsed in water for a few minutes to wash out gum.

From water the sections are put into aniline violet solution (2) for three to six minutes, and then transferred to iodine solution (4) for two to four minutes, or till they turn brown. Next they are transferred direct to alcohol (not absolute), and washed till they appear completely decolorised. They are then washed in fresh alcohol, clarified in clove oil, and placed on a clean slide. All clove oil is now to be removed by carefully pressing filter paper on the section. Lastly a drop of xylol balsam is added, and a No. 1 cover glass is applied.

The aniline violet solution stains both organisms and tissue, and by the iodine solution the colour is fixed in the organisms—the solution contracting and at the same time fixing the stained protoplasm within the sheath of the organism. When once the stain is thus fixed the colour can be washed out of the tissue by means of alcohol.

When such a specimen after being mounted is examined under a suitable microscope, such as a Zeiss or the Swift's (Crookshank Model), with a 1 in. objective, blue streaks are seen. These on examination under a $\frac{1}{8}$ inch objective (Swift's) are definable as the case may be into masses of leptothrix, bacteria or micrococci within the dentinal tubes. An Abbé's sub-stage condenser is almost indispensable. If the morphology of the organisms is to be studied, a $\frac{1}{12}$ homogeneous immersion objective will be required.

If the structure of the tissue is to be brought out sections should, after coming out of alcohol, be placed in rubin and orange stain for five minutes, then washed in distilled water, dehydrated in alcohol, clarified in oil of cloves, and finally mounted in xylol balsam. In this procedure it is best to overstain the sections somewhat, and afterwards correct it by rinsing in water.

This method brings out the structure picture especially

in transverse sections. In some parts the tubes will be blocked with organisms, in another part tubes appear apparently healthy. In other parts the "pipe-stem" appearance is seen. Sometimes in vertical section stained with rubin S. globular dentine is well shown.

Cover-glass preparations of scrapings from a carious tooth show appearances when stained simply by carbolic fuchsin different from those produced by Gram's method. When stained by carbolic fuchsin the characters are not at all altered. By the Gram method, however, the organisms do not appear so thick; also other typical points and minute details are not shown.

When sections or cover-glass preparation on coming out of aniline violet are placed in iodine solution this acts as a mordant, and sudden contraction of the protoplasm takes place, which of course alters the minute characteristic details of the organisms. This is easily demonstrated in the case of bacillus anthracis. On staining a blood preparation of this organism with fuchsin the characteristic square-cut ends can be distinctly seen, but after staining a similar preparation by Gram's method, the bacilli appear shorter and more slender and with distinctly rounded ends.

Rubin stain was first used in this country by Watson Cheyne, in combination with Ehrlich's hæmatoxylin, and is perhaps the best stain for pathological and histological purposes ever introduced. One cannot appreciate this stain until he has used it for himself, and not until then do the selective powers become apparent, especially when compared with such a contrast stain as eosine.

It is absolutely necessary to preserve specimens that cover-glasses be thoroughly cemented with 2 or 3 coats of shellac varnish (6). It has been proved beyond doubt that specimens not so guarded will fade, even if kept in the dark.

INDEX.

- ABNORMAL development of jaws, 75
 Abnormally formed teeth, 49
 Abrasion of the teeth, 294
 Absorption of alveoli, 278
 " roots of permanent teeth, 278
 " " temporary teeth, 33
 Alveolar abscess, 268
 Alveoli, growth of, in first dentition, 28
 " " second dentition, 44
 Amalgams, 204
 Antrum, diseases of, 328
 " empyema of, 330
 Arsenious acid in treatment of pulp, 243
- BAR and bridge work, 304
 Buried teeth, 45
- CALCIFICATION of cement, 27
 " " dentine, 25
 " " enamel, 24
 Cancrum oris, 291
 Capping the pulp, operation of, 231
 Caries, 111
 " and its sequels in infancy, 281
 " diagnosis of, 160
 " incipient, treatment of, 171
 " in dentine, 128
 " in enamel, 129
 " organisms in, 115
 " pain during, 131
 " prevention of, 163
 " reaction in pulp during, 131
 " relative liability of different teeth to, 158
 " spontaneous arrest of, 135
 " zone of transparency in, 130
 Cavities, preparation of, for filling, 174
 Cement, development of, 27

Cement, exostosis of, 274
 „ necrosis of, 276
 „ structure of, 13
 Chronic inflammation of dental periosteum, 266
 „ „ pulp, 253
 „ wasting of alveoli, 278
 Closure of jaws, 390
 Concussion of teeth, 297
 Copper amalgam, 205
 Crown bar and bridge work, 304
 Crowning, 304
 Crystal, gold, 203
 Cylinder fillings, 215
 Cysts of the jaws, 314

DECUSSATION of enamel prisms, 9
 Defective dentine, 117
 „ enamel, 117
 Dental engine, 176
 Dentigerous cysts, 314
 Dentinal fibrils, 11
 „ tubes, 11
 Dentifrice, 168
 Dentine, defects in structure of, 117
 „ development of, 25
 „ papilla, 20
 „ secondary, 16
 „ sensibility of, 131
 „ structure of, 11
 „ treatment of sensitive, 182
 Dentition, permanent, 33
 „ supposed third, 48
 „ temporary, 28
 Development of jaws, 28
 „ teeth, 17
 Dilaceration, 55
 Dislocation of teeth, 299
 „ jaw, 385

ELEVATORS, 370
 Enamel, defects in structure of, 117
 „ development of, 24
 „ structure of, 7
 Epulis, 325
 Erosion, 294
 Eruption of permanent teeth, 33
 „ temporary teeth, 28
 Exanthematous necrosis, 273
 Excavators, 178

- Exostosis of cement, 274
 - „ jaws, 274
- Extraction of temporary teeth, 334
 - „ of teeth, 348
 - „ difficulties in, 372
 - „ hæmorrhage following, 382
 - „ pain following, 381
- Eye, diseases of, 342
- FANGS, union of, 57
- Filling, materials used in, 203
 - „ operation of, 173
 - „ with amalgams, 204
 - „ „ gold, 212
 - „ „ gutta percha, 223
 - „ „ cement, 223
 - „ „ tin, 221
- Forceps, extracting, 350
 - „ plugging, 211
- Fracture of teeth, 296
 - „ jaws, 386
- GEMINATION of teeth, 57
- Gold, filling with, 212
 - „ used in filling teeth, 211
- Glossitis, 292
- Gumboil, 268
- Gums, diseases of, 288
- Gutta-percha filling, 209
- HÆMORRHAGE after tooth extraction, 382
- Histology of dental tissues, 7
- Hypertrophy of gums, 289
- Honeycombed teeth, 50
- INFLAMMATION of dental periosteum, 259
 - „ gums, 288
 - „ periosteum of jaw, 272
 - „ pulp, 236
- Interglobular spaces, 12
- Irregularities of teeth, 62
- JAW, tumours of, 311
- Jaws, closure of, 390
 - „ dislocation of, 385
 - „ fracture of, 386
 - „ growth of, 28
 - „ malformations of, 75
 - „ necrosis of, 272

- LANCING gums, 30
 Leptothrix buccalis, 115
 Lotions, antiseptic, 169

 MAXILLÆ, development of, 28
 " V-shaped, 77
 Matrix, use of, 193
 Mechanical injuries to the teeth, 296
 Membrana eboris, 26
 Mercurial teeth, 50
 Micro-organisms in caries, 115
 Microscopical character of carious tissues, 126
 Moisture, methods of excluding, 196

 NASMYTH'S membrane, 14
 Necrosis, exanthematous, 273
 " of jaw, 273
 " teeth, 276
 Nervous disorders connected with the teeth, 336
 Neuralgia, 337

 ODONTOBLASTS, 26
 Odontomes, 311
 Odontalgia, 336
 Operation of extraction, 348
 " filling, 173

 PALLADIUM amalgam, 204
 Papilla, dentinal, 20
 Periosteum, dental, 13
 " inflammation of, 259
 " of jaw, inflammation of, 272
 Permanent teeth, 2
 Pivoting teeth, 301
 Polypus, 254
 Porcelain inlays, 301
 Pulp, atrophy of, 255
 " calcification of, 16
 " dental, 14
 " diseases of, 228
 " exposure of, 228
 " gangrene of, 238
 " inflammation of, 236
 " irritation of, 233
 " structure of, 14
 " ulceration of, 253
 Pyorrhœa alveolaris, 278

 RANULA, 292
 Replantation, 268

Roots of permanent teeth, absorption of, 278
 Rubber dam, use of, 198

SALIVARY calculus, 306
 Scaling, 308
 Second dentition, 37
 Secondary dentine, 16
 Sensitive dentine, treatment of, 182
 Separation of teeth, 190
 Shedding of temporary teeth, 33
 Silver amalgam, 204
 Sinus opening through cheek, 269
 " " " gum, 269
 Sponge gold, 211
 Stomatitic teeth, 50
 Stumps, extraction of, 363
 Supernumerary teeth, 57
 Sympathetic toothache, 336
 Syphilitic teeth, 50

TARTAR, 306

Teeth, abrasion of, 294
 „ anatomy and histology of, 1
 „ abnormally formed, 49
 „ concussion of, 297
 „ development of, 17
 „ dislocation of, 299
 „ erosion of, 294
 „ eruption of permanent, 37
 „ „ temporary, 28
 „ fracture of, 296
 „ gemination of, 57
 „ honeycombed, 50
 „ imbedded, 45
 „ irregularities of, 62
 „ mercurial, 50
 „ permanent, 1
 „ retained temporary, 35
 „ supernumerary, 57
 „ syphilitic, 50
 „ stomatitic, 50
 „ temporary, 5

Toothache, 336

Tooth powder, 168

Teething, disorders due to, 29

Temporary fillings, 211

Thrush, 289

Tongue, ulcers of, 290

Torsion, actual, 100

Tumours, cystic, 314

„ dentigerous, 314

ULCERATION of gums, 288

 " " lips, 290
 " " pulp, 253
 " " tongue, 290

WISDOM teeth, eruption of, 37

 " " impaction of, 37

ZONE of transparency in caries, 130

THE END.

A
CATALOGUE OF THE PUBLICATIONS
OF
BAILLIÈRE, TINDALL, & COX,
IN
MEDICINE, SCIENCE AND ART.

CONTENTS.

	PAGE
AIDS TO THE CLASSICS	<i>Back of Title</i>
ANATOMY	7, etc.
ART, ARTISTIC ANATOMY, ETC.	9, etc.
CHEMISTRY	12, etc.
MEDICINE, SURGERY, AND ALLIED SCIENCES	18, etc.
PHARMACY	25, etc.
STUDENTS' AID SERIES	31, etc.
VETERINARY MEDICINE AND SURGERY	34, etc.
PERIODICAL PUBLICATIONS	<i>P. 3 of wrapper</i>



LONDON:
20, 21, KING WILLIAM STREET, STRAND.
[PARIS; MADRID.]
1890.

* * Baillière, Tindall and Cox have special facilities for the disposal of authors' works in the United States and abroad; being in almost daily communication with the principal houses and agents.

AIDS TO THE CLASSICS.

TEXT, TRANSLATION AND COPIOUS NOTES, together with an account of the Author and his works.

- Ovid.** *Metamorphoses.* Lib. I. Price 2s.
Cicero. *Oratio Prima in L. Catilinam.* Price 1s.
Cicero. *De Amicitia.* Price 2s.
Sallust. *De Catilinæ Conjuratone.* Price 1s. 6d.
Cæsar. *De Bello Gallico.* Lib. V. and VI. Price 2s.

TEXT AND NOTES.

- Cæsar.** *De Bello Gallico.* Lib. I. Price 1s.
Cæsar. *De Bello Gallico.* Lib. II. Price 1s.
Cæsar. *De Bello Gallico.* Lib. VII. Price 1s. 6d.
Horace. *Carminum.* Book III. Price 1s. 6d.
Horace. *Carminum.* Book IV. Price 1s.
Livy. *Book XXII.* Price 1s. 6d.
Ovid. *Epistolæ ex Ponto.* Lib. I. Price 1s.
Ovid. *Tristia.* Lib. I. Price 1s. 6d.
Ovid. *Metamorphosoen.* Lib. II. Price 1s.
Ovid. *Metamorphosoen.* Lib. XI. Price 1s. 6d.
Cicero. *Pro Lege Manilia.* Price 1s. 6d.
Cicero. *De Senectute.* Price 1s.

TRANSLATIONS IN LITERAL ENGLISH.

- Cæsar.** *Gallic War.* Book I. Price 1s.
Cæsar. *Gallic War.* Book II. Price 1s.
Cæsar. *Gallic War.* Book VII. Price 1s.
Horace. *Odes.* Books III. and IV. (together). Price 1s.
Ovid. *Metamorphoses.* Book II. Price 1s.
Ovid. *Metamorphoses.* Book XI. Price 1s.
Ovid. *Pontic Epistles.* Book I. Price 1s.
Ovid. *Tristia.* Book I. Price 1s.
Ovid. *Tristia.* Book III. Price 1s.
Livy. *Book XXII.* Price 1s. 6d.
Cicero. *Pro Lege Manilia.* Price 1s.
Cicero. *De Senectute.* Price 1s.
Virgil. *Æneid.* Book I. Price 6d.
Virgil. *Æneid.* Book V. Price 6d.
Virgil. *Æneid.* Book XII. Price 9d.
Virgil. *Georgics.* Book II. Price 6d.

ALPHABETICAL INDEX OF AUTHORS.

	PAGE
ABERCROMBIE (J.) On Tetany in Young Children	13
ADAMS (W.) Deformities (in Gant's Surgery)	27
ALLAN (J. H.) Materia Medica Tables	21
ALLEN (Alfred) Microscopical Science	23
BAKER (Benson) How to Feed an Infant	24
BANHAM—Veterinary Tables.....	34
BARRAUD (H. R.) Picture of the International Medical Congress	20
BARTON (J. K.) The Diagnosis of Syphilis	28
BEACOCK (J.) Prize Essay on Breeding Cattle, etc.	34
BENNETT (E. E.) Veterinary Surgeon's Diary and Dose-book	36
BERNARD (Claude) and HUETTE'S Text-book of Operative Surgery	28
BLACK (C.) Atlas of the Male Organs of Generation	8
BLACKLEY (C. H.) Hay Fever, its Causes and Treatment	19
BLAKE (Carter) Translation of Fau's Anatomy for Artists	9
BODDY (E. M.) History of Salt.....	27
BOWDICH (Mrs.) Confidential Chats with Mothers	13
BOYD (Stanley) Movable Atlas of the Foot, its Bones and Muscles	8
BROCHARD (J.) Practical Guide for the Young Mother.. ..	24
BROWN (George) The Student's Case-book	11
——— Aids to Anatomy	7, 31
——— Aids to Surgery ..	28, 32
BROWNE (Lennox) The Throat and its Diseases.....	29
——— Movable Atlases of the Throat and Ear	8
BROWNE (W. J.) The Moon, its Influence on Weather	22
BURKE—Tropical Diseases of the Horse	34
BURNES (A. G.) The Specific Action of Drugs.....	34
BURTON (J. E.) Translation of Ebstein's Gout	18
CAMERON (Chas.) Microbes in Fermentation, Putrefaction, and Disease ...	23
——— The Cholera Microbe and How to Meet It	13
——— A Romance of War	30
CAMERON (Sir C. A.) History of the Royal College of Surgeons in Ireland	19
CAMPBELL (C. M.) and HARRIES (A.) Lupus, a Clinical Study	27
——— Skin Diseases of Infancy and Early Life.....	27
CANTLIE (Jas.) Atlas of the Hand	8
——— Text-book of Naked-Eye Anatomy	7
CARMICHAEL Prize Essays	22
CARTER (R. Brudenell) Training of the Mind... ..	23
CASSELLS (J. Patterson) Deaf-mutism and the Education of the Deaf-mute	14
CHARCOT (J. M.) Bright's Disease of the Kidneys.....	20
CLARK (Percy) Medical Laws.....	21
CLARKE (E. H.) The Building of a Brain	11
COCKLE (John) Contributions to Cardiac Pathology	19
——— Insufficiency of the Aortic Valves... ..	19
COFFIN (R. J. Maitland) Ob-tetrics	24
COLE (A. C.) Microscopical Research	23
COOPER (R. T.) On Vascular Deafness	16
COSGRAVE (C. M.) Botany, Glossary of	11
COTTERELL (Ed.) The Anatomist's Vade Mecum	9
COURTENAY (E.) Practice of Veterinary Medicine	34
CRUISE (F. R.) Hydropathy	19
CULLIMORE (D. H.) Consumption as a Contagious Disease	14
——— The Book of Climates	13
DALBY (Sir William) Politzer on Diseases of the Ear	15
DARLING (W.) Anatomography, or Graphic Anatomy	9
——— The Essentials of Anatomy	9

	PAGE
DARTNELL (G. M.) Notes on Anatomy	7
DAWSON (W. E.) Guide to the Examinations of the Apothecaries' Society	16
DAY (W. H.) Irritable Brain in Children	11
DENNIS (Hy. J.) Second-Grade Perspective Drawing.....	10
——— Third-Grade Perspective Drawing	10
DOLAN (T. M.) Whooping Cough, its Pathology and Treatment.....	30
——— Summary of New Remedies	23
DOWSE (T. Stretch) Apoplexy.....	9
——— Syphilis of the Brain and Spinal Cord.....	11
——— Skin Diseases from Nervous Affections	27
——— The Brain and the Nerves	11
——— Movable Atlas of the Brain and Skull	8
DRAGENDORFF (Prof. G.) Plant Analysis	26
DRYSDALE (C. R.) Nature and Treatment of Syphilis	28
DRYSDALE (John) The Protoplasmic Theory of Life.....	28
——— Germ Theories of Infectious Diseases	29
DUDGEON (R. E.) The Sphygmograph	27
DUFFY (G. F.) Note-taking	23
EBSTEIN (Prof.) The Treatment of Gout	18
EDRIDGE-GREEN (F. W.) Memory	22
EDWARDS—Diseases of Children	13
EVANS (C. W. De Lacy) How to Prolong Life?	29
——— Consumption : its Causes, Treatment, etc.	14
FAU (J.) Artistic Anatomy of the Human Body	10
——— Anatomy of the External Form of Man	10
FEARNLEY (W.) Text-book for the Examination of Horses.....	34
FINNY (F. M.) Clinical Fever Chart	17
FITZGERALD (H. P.) Dictionary of British Plants and Flowers ...	10
FLAXMAN (J.) Elementary Anatomical Studies for Artists	9
FLEMING (G.) Text-book of Veterinary Obstetrics	34
——— Text-book of Veterinary Surgery	34
——— Actinomykosis	35
——— Roaring in Horses	35
——— Practical Horse-Shoeing	35
——— Animal Plagues, their History, Nature and Treatment	35
——— Contagious Diseases of Animals	35
——— Tuberculosis.....	35
——— Human and Animal Variolæ	35
——— Heredity and Contagion in the Propagation of Tuberculosis	35
FOTHERGILL (J. Milner) Chronic Bronchitis	11
——— Aids to Diagnosis (Semeiological) ...	14, 31
——— Aids to Rational Therapeutics.....	29, 32
——— The Physiological Factor in Diagnosis	15, 26
——— The Physiologist in the Household	26
——— Diseases of Sedentary and Advanced Life ..	24
——— Vaso Renal Changes	20
——— What to Ask	15, 31
FOY (Geo.) Anæsthetics : Ancient and Modern	9
FUCHS (Dr.) The Causes and Prevention of Blindness	17
GANT (F. J.) Text-book of the Science and Practice of Surgery	27
——— Diseases of the Bladder, Prostate Gland, and Urethra	10, 30
——— Examinations by the Conjoint Board	16
——— Students' Surgery	27

	PAGE
GARMARY (J. J.) Surgery on the Cadaver	28
GERSTER (A. G.) Aseptic and Antiseptic Surgery.....	28
GIRAUD-TEULON—Anomalies of Vision	17
GLOVER (J. G.) Medical Reform	22
GORDON (Chas. A.) Our Trip to Burmah	11
——— Life on the Gold Coast	7
——— Lessons in Military Hygiene and Surgery	19
——— A Manual of Sanitation	19
——— Rabies and Hydrophobia	19
——— Reports of the Medical Officers of Chinese Service	13
——— Experiences of an Army Surgeon in India	20
GORDON (T. Hurd) Aids to Practical Chemistry	31
GORE (Albert A.) Our Services Under the Crown	22
——— Medical History of African Campaigns	7
GRAY—The Pocket Gray, or Anatomist's Vade-Mecum	9
GREEN (F. W. Edridge) Memory	22
GREENWOOD (J.) Laws Affecting Medical Men	21
GREENWOOD (Major) Aids to Zoology	30, 33
GRESSWELL (J. B. and A. G.) Manual of Equine Medicine	35
GREVILLE (H. Leicester) Student's Hand-book of Chemistry.....	12
GRIFFITHS (W. H.) Text-book of Materia Medica and Pharmacy	21
——— Notes for Pharmacopœial Preparation.....	25
——— Posological Tables.....	26
GUBB (Alfred S.) Aids to Gynæcology	18, 31
GUBB & GRIFFITHS. Materia Medica and Pharmacy	21
GUBLER (Professor) The Principles and Methods of Therapeutics	29
HAIG-BROWN—Tonsillitis	29
HALTON (R. J.) Short Lectures on Sanitary Subjects	20
HARRIS (Vincent) Manual for the Physiological Laboratory.....	26
HARRIES and CAMPBELL (A.M.) Lupus: a Clinical Study.....	27
HARTMANN (Prof.) On Deaf-mutism, Translation by Dr. Cassells.....	14
HAYNES (Stanley) Healthy Homes	19
HEATLEY (G. S.) Practical Veterinary Remedies	35
HEIBERG (Jacob) Atlas of Cutaneous Nerve Supply	23
HEMMING (W. D.) Aids to Examinations ..	15, 31
——— Aids to Forensic Medicine	17, 31
——— Otorrhœa	16
HEPPEL—Analytical Conic Sections	18
HEWITT (Frederic) Anæsthetics	9
HILL (J. W.) Principles and Practice of Bovine Medicine	35
HIME (T. W.) Cholera: How to Prevent and Resist It... ..	13
——— The Practical Guide to the Public Health Acts.....	26
HOGG (Jabez) The Cure of Cataract	17
——— The Impairment of Vision from Shock	16
——— Parasitic or Germ Theory of Disease	29
HOPGOOD (T. F.) Notes on Surgical Treatment	28
HORNER (Professor) On Spectacles	17
HOWAT (G. R.) How to Prevent and Treat Consumption	14
HUSBAND (H. Aubrey) Handbook of Forensic Medicine	17
——— Aids to the Analysis of Food and Drugs.....	17, 31
——— Handbook of the Practice of Medicine.....	22
——— Student's Pocket Prescriber	26
HUTCHINSON (Jonathan) Guide to Diseases of the Eye.....	16
INCE (J.) Latin Grammar of Pharmacy	25

	PAGE
INTERNATIONAL MEDICAL CONGRESS.....	20
JACOB (A. H.) The General Medical Council	21
JAMES (Brindley) Replies to Questions in Therapeutics.....	33
JAMES (M. P.) Laryngoscopy and Rhinoscopy in Throat Diseases	29
——— Therapeutics of the Respiratory Passages	29
——— Vichy and its Therapeutical Resources	30
JENNINGS (C. E.) On Trans-fusion of the Blood and Saline Fluids	30
——— Cancer and its Complications	11
JONES (H. Macnaughton) The Diseases of Women	18
JUKES-BROWNE (A. J.) Palæontology (in Penning's Field Geology)	18
KEETLEY (C.R. B.) Guide to the Medical Profession.....	21
——— Annals of Surgery	28
KENNEDY (Hy.) An Essay on Fatty Heart.....	19
LAFFAN (T.) The Medical Profession (Carmichael Prize Essay) ..	21
LAMBERT (J.) The Germ Theory of Disease	35
LEASK (J. G.) Questions at Medical Science Examinations	16
LEDWICH (E. L') Anatomy of Inguinal and Femoral Regions	9
LEE (R. J.) Lectures on Diseases of Children ..	13
LEONARD (H.) The Pocket Anatomist	9
——— Bandaging	10
——— Hair	18
LE SUEUR Analytical Geometry, Straight Line and Circle	18
LETHEY (Hy.) The Sewage Question	27
LIAUTARD (A.) Animal Castration.....	35
——— Lameness of Horses	35
LITHGOW (R. A. Douglas) From Generation to Generation	19
LOWNE (B. T.) Aids to Physiology	25, 32
LUNN (C.) The Philosophy of Voice	30
——— Artistic Voice in Speech and Song	30
MACKENZIE (Sir M.) Diseases of the Throat (in Gant's Surgery)	27
MADDICK (Distin) Stricture of the Urethra	27
MAGNÉ (Dr.) How to Preserve the Sight.....	17
MAPOTHER (E. D.) A Manual of Physiology	25
——— Chronic Skin Diseases. 3s. 6d.	27
MARTIN (J. W. & J.) Ambulance Work	7
MASSE (J. N.) Text-book of Naked-Eye Anatomy.....	7
MCARDLE (J. S.) Notes on Materia Medica.	21
MCBRIDE Anatomical Outlines of the Horse	36
McLACHLAN (John) Anatomy of Surgery	28
MEARS (W. P.) Schematic Anatomy	9
MELDON (Austin) A Treatise on Gout	18
——— Skin Diseases	27
MEYRICK (J. J.) Stable Management in India.....	36
MILLARD (H. B.) Bright's Disease of the Kidneys.....	20
MILNE (Alex.) The Principles and Practice of Midwifery	23
MOLONY (M. J.) Rupture of the Perineum	27
MOORE (E. H.) Clinical Chart for Hospital and Private Practice.....	28
MORDHORST (Carl) Rheumatism. Its Treatment by Electric Massage ...	27
MORGAN (John) The Dangers of Chloroform and Safety of Ether	7
MORRIS (Malcolm) The Skin (in Gant's Surgery)	27
MUCKLEY (W. J.) Student's Manual of Artistic Anatomy.....	9
——— A Handbook for Painters and Art Students on the Use of Colours	14

	PAGE
MURRAY (R. Milne) Pregnancy.....	8
MUTER (J.) Key to Organic Materia Medica	21
——— Manual of Analytical Chemistry	13
——— Introduction to Pharmaceutical and Medical Chemistry	13
NALL (S.) Aids to Obstetrics	24, 32
NAPHEYS (G. H.) Handbook of Popular Medicine	15
NATIONAL SOCIETY FOR PREVENTION OF BLINDNESS	17
NORTON (A. T.) Text book of Operative Surgery	28
——— Osteology for Students	24
——— Affections of the Throat and Larynx	29
——— Clinical Lectures on Hoarseness	31
——— Movable Atlas of the Skeleton.....	8
ORMSBY (L. H.) Deformities of the Human Body	14
——— Phimosis and Paraphimosis	25
——— Chart of Surgical Appliances	28
OWEN (E.) Selected Subjects in the Surgery of Infancy and Childhood	13
PALFREY (J.) Atlas of the Female Organs of Generation	8
PALMER (J. F.) How to Bring up Children by Hand	24
PARRISH (Ed.) A Treatise on Pharmacy	25
PENNING (W. H.) Text-book of Field Geology	18
——— Engineering Geology	18
——— Notes on Nuisances, Drains, and Dwellings	20
PETTENKOFER (Von) Cholera : How to Prevent and Resist it.....	13
POLITZER (Prof.) The Ear and its Diseases	15
POWER (Hy.) Movable Atlas of the Eye, and the Mechanism of Vision	8
——— Diseases of the Eye (in Gant's Surgery)	27
POWER (D'Arcy) Handbook for the Physiological Laboratory	26
POYSER (R.) Stable Management of Troop Horses in India	36
PRATT (W.) A Physician's Sermon to Young Men	23
PROCTOR (Richd.) The Stars and the Earth	10
PSYCHOLOGICAL ASSOCIATION'S Handbook for Attendants on the Insane.....	20
PURVES (L.) Aural Diseases (in Gant's Surgery)	27
RABAGLIATI (A.) The Classification and Nomenclature of Diseases	15
REMSEN (Ira) Principles of Theoretical Chemistry	12
REYNOLDS (R. S.) The Breeding and Management of Draught Horses.....	36
RICHARDS (J. M.) A Chronology of Medicine	22
RICHARDSON (B. W.) The Healthy Manufacture of Bread	17
RICHARDSON (Thos.) Chemistry in its Application to the Arts, etc.....	12
RIVINGTON (W.) The Medical Profession (First Carmichael Prize Essay)...	22
——— Medical Education and Organization	21
ROBERTSON (William) A Handbook of the Practice of Equine Medicine...	36
ROCHE (J.) Hernia and Intestinal Obstruction	19
ROCHET (Chas.) The Prototype of Man, for Artists	10
ROTH (M.) Works on Deformities, Gymnastic Exercises, etc.	18
ROTH (W. E.) Elements of School Hygiene.....	19
——— Theatre Hygiene	19
ROUTH (C. H. F.) Overwork and Premature Mental Decay.....	24
——— On Fibrous Tumours of the Womb	24
——— On Checks to Population	25
SALISBURY (J. H.) The Salisbury Plans of Treating Disease	15
SARCEY (F.) Mind your Eyes.....	17
SCHOFIELD (A. T.) Examination Cards —Pathology.....	16, 24
——— Minor Surgery and Bandaging	16, 28
SEILER (C.) A Compendium of Microscopical Technology	23

	PAGE
SEMPLE (R. H.) Diphtheria, Its Causes and Treatment	15
———— Movable Atlas of the Human Body (Neck and Trunk)	8
SEMPLE (C. E. A.) Aids to Botany	11, 31
———— Aids to Chemistry	12, 31
———— Aids to Materia Medica	21, 32
———— Aids to Medicine	22, 32
———— Aids to Pharmacy	25, 32
———— Diseases of Children	13
———— The Voice Musically and Medically Considered	30
———— The Pocket Pharmacopœia	25
SEWILL (Hy.) Movable Atlas of the Teeth	4
———— Dental Caries and the Prevention of Dental Caries	14
SHARMAN (J. S.) Notes on Inorganic Materia Medica	21
SIMON (W.) A Manual of Chemistry	12
SMITH (F.) Manual of Veterinary Hygiene	36
SPARKES (John C. L.) Artistic Anatomy	10
SQUIRE (P. W.) Posological Tables	26
STEVENS (Geo. T.) Nervous Diseases	23
STRAHAN (J.) Extra-Uterine Pregnancy	26
STUDENTS' AIDS SERIES	32
SUTTON (H. G.) Handbook of Medical Pathology	24
SWEETING (R. D. R.) The Sanitation of Public Institutions	20
SYMINGTON (J.) Anatomy of the Child	7
TEULON (G.) The Functions of Vision	17
THIN (George) Introduction to Practical Histology	19
THOMSON (W.) Transactions of the Academy of Medicine in Ireland	29
THOROWOOD (J. C.) Consumption; its Treatment by the Hypophosphites	14
———— The Treatment of Bronchial Asthma	10
———— Aids to Physical Diagnosis	15, 31
THUDICHUM (J. L. W.) The Physiological Chemistry of the Brain	11
———— Aids to Physiological Chemistry	26, 32
———— Aids to Public Health	26, 32
———— Polypus in the Nose	26
———— The Coca of Peru, and its Remedial Principles	14
TICHBORNE (Professor) The Mineral Waters of Europe	23
TIDY (Meymott) and CLARKE (Percy) Medical Laws	21
TIMMS (G.) Consumption; its Nature and Treatment	14
———— Alcohol in some Clinical Aspects, a Remedy, a Poison	7
TOMSON—Medical Electricity	16
TRANSACTIONS of Royal Academy of Medicine in Ireland	wrapper
TUCKEY (C. Lloyd) Psycho-Therapeutics	20
TYSON (J.) The Urine, a Guide to its Practical Examination	30
UNDERWOOD (Arthur S.) Aids to Dental Surgery	15, 31
WAGSTAFFE (W. W.) Atlas of Cutaneous Nerve Supply	23
WALLACE (J.) Localised Peritonitis	25
WALLER (B. R.) Interstitial Nephritis	23
WALSHAM and POWER—Surgical Pathology	28
WILLIAMS (Maurice) Materia Medica	20
WILLIAMSON (J. M.) Ventnor and the Undercliff	30
WILLSON (A. Rivers) Chemical Notes for Pharmaceutical Students	12
WILSON (J.) A Manual of Naval Hygiene	20
WINSLOW (L. S. Forbes) Fasting and Feeding	17
———— Aids to Psychological Medicine	32
WORTHINGTON (L. N.) Chemie, Botanique Zoologie	30
———— Thérapeutique	30
WITKOWSKI (G. J.) Movable Atlases of the Human Body	8, 17

AN
ALPHABETICAL INDEX OF WORKS,
IN
MEDICINE, SURGERY, SCIENCE AND ART,
PUBLISHED BY
BAILLIÈRE, TINDALL, & COX.

- Africa.** A Contribution to the Medical History of our West African Campaigns. By Surgeon-Major ALBERT A. GORE, M.D., Sanitary Officer on the Staff. Price 10s. 6d.
- Africa.** Life on the Gold Coast. A Description of the Inhabitants, their Modes and Habits of Life; Hints to Travellers and others in Western Africa. By Surgeon-General GORDON, M.D., C.B., Hon. Physician to the Queen. Price 2s. 6d.
- Alcohol**, in some Clinical Aspects: A Remedy, a Poison. By GODWIN TIMMS, M.D., M.R.C.P. Lond., Senior Physician to the North London Consumption Hospital. Price 1s.
- Ambulance Work.** Questions and Answers on "First Aid to the Injured." By JOHN W. MARTIN, M.D., and JOHN MARTIN, F.R.C.S. Twelfth thousand. Price 1s., net.
- Anæsthetics.** The Dangers of Chloroform and the Safety and Efficiency of Ether in Surgical Operations. By JOHN MORGAN, M.D., F.R.C.S. Second thousand, price 2s.
- Anæsthetics.** Selected Methods in the Administration of Nitrous Oxide and Ether. By FREDERIC HEWITT, M.A., M.D. Cantab. Lecturer on Anæsthetics at the London Hospital. Price 2s. 6d.
- Anatomy.** Aids to Anatomy. By GEORGE BROWN, M.R.C.S., Gold Medallist, Charing Cross Hosp. Price 1s. 6d. cloth, 1s. sewn.
- Anatomy.** Text Book of Naked-Eye Anatomy. With 113 Steel Plates, designed under the direction of Professor MASSE. Text by JAS. CANTLIE, M.B., C.M. (Honours), F.R.C.S., Charing Cross Hospital. Third Edition. Plain, 25s., coloured, 50s., half calf.
- Anatomy. Notes on Anatomy.** By GEORGE MEADOWS DARTNELL, L.R.C.S. Part I.—Upper Extremity. Price 1s.
- Anatomy.** Anatomy of the Child. With 14 coloured plates and 33 woodcuts. By JOHNSON SYMINGTON, M.D., F.R.S.E., F.R.C.S.E., Lecturer on Anatomy, Edinburgh. Price 42s.

Anatomy. Human Anatomy and Physiology, illustrated by a series of Movable Atlases of the Human Body, showing the relative positions of the several parts, by means of Superposed Coloured Plates, from the designs of Prof. G. J. WITKOWSKI, M.D. Each part complete in itself.

Part I.—Neck and Trunk. With Text Descriptive and Explanatory of the physiology and functions of the several parts. By ROBERT HUNTER SEMPLE, M.D., F.R.C.P., Lond. Price 7s. 6d.
The same enlarged to Life Size. Price £2 2s. 0d.

Part II.—Throat and Tongue, showing the Mechanism of Voice, Speech, and Taste. Text by LENNOX BROWNE, F.R.C.S. Edin. Price 7s. 6d.

Part III.—The Female Organs of Generation and Reproduction. Text by JAMES PALFREY, M.D., M.R.C.P. Lond., late Senior Obstetric Physician, London Hospital. Price 7s. 6d.

Part IV.—The Eye and the Apparatus of Vision. Text by HENRY POWER, F.R.C.S., Senior Ophthalmic Surgeon to St. Bartholomew's Hospital. Price 7s. 6d.

Part V.—The Ear and Teeth. The Mechanism of Hearing, and of Mastication. Text of the Ear by LENNOX BROWNE, F.R.C.S.E. The Teeth by H. SEWILL, M.R.C.S. Price 7s. 6d.

Part VI.—The Brain and Skull. (Cerebrum, Cerebellum, and Medulla Oblongata). Text by T. STRETCH DOWSE, M.D., F.R.C.P. Edin. Price 7s. 6d.

Part VII.—The Male Organs of Generation. Text by D. CAMPBELL BLACK, M.D., Physician to the Glasgow Royal Infirmary. Price 7s. 6d.

Part VIII.—The Skeleton and its Articulations, showing the Bones and Ligaments of the Human Body and Limbs. Text by A. T. NORTON, F.R.C.S. Price 7s. 6d.

Part IX.—The Hand; its Bones, Muscles and Attachments. Text by JAS. CANTLIE, M.B., F.R.C.S. Price 7s. 6d.

Part X.—The Foot; its Bones, Muscles and Attachments. Text by STANLEY BOYD, M.B., B.S., Lond., F.R.C.S., Assistant Surgeon, Charing Cross Hospital. Price 7s. 6d.

Part XI.—The Progress of Gestation: a Synopsis of Practical Obstetrics. Text by R. Milne Murray, F.R.C.P. Edin., M.B. Edin. Price 7s. 6d.

* * No such simple, reliable, and comprehensive method of learning the several parts, positions, and functions of the body has hitherto been attempted; the entire Series being unique, will be most valuable to the Teacher, the Student, and to all who wish to become acquainted with the anatomy and physiology of the human economy.

- Anatomy.** The Essentials of Anatomy. A Text-book for Students, and a book of easy reference to the Practitioner. By W. DARLING, M.D., F.R.C.S., and A. L. RANNEY, M.D. 12s. 6d.
- Anatomy.** The Pocket Gray, or Anatomist's Vade-Mecum. Compiled from the works of Gray, Ellis, Holden, and Leonard. By E. COTTERELL, L.R.C.P., M.R.C.S. Enlarged edition, 3s. 6d.
 "A marvellous amount of information condensed into a remarkably small space."—*Med. Press.*
- Anatomy.** The Pocket Anatomist. By H. LEONARD, M.D. Enlarged Edition illustrated. Price 3s. 6d.
- Anatomy.** Schematic Anatomy; or Diagrams, Tables and Notes treating of the Association and Systematic arrangement of Structural Details of Human Anatomy. By WILLIAM P. MEARS, M.B., Professor and Examiner in Anatomy at the University of Durham. Profusely illustrated. Price 7s. 6d.
- Anatomy of the Inguinal and Femoral Regions in relation to Hernia.** By E. L'LEDWICH, Lecturer on Anatomy in the Ledwich School of Medicine, Dublin. Price 3s.
- Anatomography;** or, Graphic Anatomy. A new method of grasping and committing to memory the most difficult points required of the student. By W. DARLING, M.D., F.R.C.S. Eng., Professor of Anatomy in the University of New York. Price 1s.
- Anæsthetics:** Ancient and Modern. Their Physiological Action, Therapeutic Use, and Mode of Action. By GEORGE FOY, F.R.C.S., Surgeon to the Richmond Hospital. Price 3s. 6d.
- Apoplexy.** Diagnosis and Treatment of Apoplexy. By T. STRETCH DOWSE, M.D., F.R.C.P.E., formerly Medical Superintendent, Central London Sick Asylum. Price 1s.
- Army Hygiene.** Lessons in Military Hygiene and Surgery. By Surgeon-General GORDON, M.D., C.B., Hon. Physician to H.M. the Queen. Illustrated. Price 10s. 6d.
- Artistic Anatomy.** Anatomy of the External Forms of Man, for the use of Artists, Sculptors, etc. By Dr. J. FAU. Used at the Government School of Art, South Kensington. Twenty-nine plates. Folio; New edition. 42s. coloured, 24s. plain.
- Artistic Anatomy.** Elementary Anatomical Studies of the Bones and Muscles, for Students and Schools, from the drawings of J. FLAXMAN, R.A. Lately used as a Text-book in the Art Schools at South Kensington. 20 plates, with Text, price 2s.
- Artistic Anatomy.** The Student's Manual of Artistic Anatomy. With 25 etched plates of the bones and surface muscles of the human figure. By W. J. MUCKLEY. Used at the Government School, South Kensington. Second edition. Price 5s. 6d.

Artistic Anatomy. Elementary Artistic Anatomy of the Human Body. From the French of Dr. FAU. With English Text. Used at the Government School of Art, South Kensington. Price 5s.

Artistic Anatomy. Description of the Bones and Muscles that influence the External Form of Man. With 43 plates. By John C. L. SPARKES, Principal of the National Art Training School, South Kensington. Adapted as a text-book at the Government Art Schools. Price 7s. 6d.

Artistic Drawing. Second Grade Perspective (Theory and Practice), containing 21 block illustrations, 20 plates, and many examination exercises. Used at the Government Science and Art Schools. By H. J. DENNIS, Art Master, Lambeth School of Art, Dulwich College, etc. Price 2s. 6d.

Artistic Drawing. Third Grade Perspective, for the use of Art Students. By H. J. DENNIS. Used at the Science and Art Schools. In two parts 7s. 6d. each. Part 1, Angular and Oblique Perspective. Part 2, Shadows and Reflections; or, half-bound leather in one vol., price 15s.

Artistic Drawing. The Prototype of Man, giving the natural laws of Human proportion in both sexes. A manual for artists and professors of drawing. By CHAS. ROCHET, of Paris. Price 1s.

Artists' Colours. Their Preparation, Uses, etc. (See Colours.)

Asthma. On Bronchial Asthma—its causes, Pathology and Treatment. Lettsomian Lectures. By J. C. THOROWGOOD, M.D., F.R.C.P. London, Senior Physician to the City of London Hospital, for Diseases of the Chest. Third edition. Price 3s.

Astronomy. The Stars and the Earth; or, Thoughts on Time Space, and Eternity. With Notes by R. A. PROCTOR, B.A., Fourteenth thousand, price 1s.

Ataxia. Nervous Affections associated with the Initial or Curative Stage of Locomotor Ataxy. By T. STRETCH DOWSE, M.D., F.R.C.P.E. Second Edition, price 2s.

Bandaging. A Manual for Self-instruction. By C. H. LEONARD, M.A., M.D., Professor of Diseases of Women in the State College, Michigan. With 139 illustrations. Price 3s. 6d.

Bladder. On Diseases of the Bladder, Prostate Gland, and Urethra. BY F. J. GANT, F.R.C.S., Senior Surgeon to the Royal Free Hospital. Fifth edition. Price 12s. 6d.

Botany. A Dictionary of British Plants and Flowers; their names, pronunciation, origin, etc. By H. P. FITZGERALD. Price 2s. 6d.

Botany. Aids to Botany. Outlines of the Elementary Facts, including a Description of some of the most important Natural Orders. By C. E. ARMAND SEMPLE, B.A., M.B. Cantab., M.R.C.P. Lond. Price 2s. 6d. cloth ; 2s. paper wrapper.

Botany. The Student's Botany. Encyclopædic Glossary. By E. MACDOWEL COSGRAVE, M.D., Lecturer on Botany, Carmichael College. Price 2s. 6d.

Brain. The Building of a Brain. By E. H. CLARKE, M.D. (author of "Sex in Education"). Price 5s.

"Carefully and elegantly written, and full of sound physiology."—*Lancet*.

Brain. On Irritable Brain in Children. By W. H. DAY, M.D., M.R.C.P. Lond., Physician to the Samaritan Hospital for Women and Children. Price 1s. 6d.

Brain. The Physiological and Chemical Constitution of the Brain, based throughout on original researches. By J. L. W. THUDICHUM, M.D., F.R.C.P., Lond. Price 10s. 6d.

Brain. Syphilis of the Brain and Spinal Cord, showing the part which this agent plays in the production of Paralysis, Epilepsy, Insanity, Headache, Neuralgia, Hysteria, and other Mental and Nervous Derangements. By T. STRETCH DOWSE, M.D., F.R.C.P. Ed. Second edition, illustrated. Price 7s. 6d.

Brain. The Brain and Nerve Exhaustion (Neurasthenia). By the same author. Price 2s. 6d.

Bronchitis. Chronic Bronchitis: its Forms and Treatment. By J. MILNER FOTHERGILL, M.D. Edin., M.R.C.P. Lond. Second Edition. Price 4s. 6d.

"It bristles with valuable hints for treatment."—*British Medical Journal*.

"The pages teem with suggestions of value."—*Philadelphia Medical Times*.

Burmah. Our Trip to Burmah, with Notes on the Ethnology, Geography, Botany, Habits and Customs of that Country, by Surgeon-General GORDON, C.B., M.D., Physician to the Queen. Illustrated with numerous Photographs, Maps, Coloured Plates, and Sketches in gold by native Artists. Price 21s.

"We lay downy this book, impressed with its many beauties, its amusing sketches and anecdotes, and its useful instructive information."—*The Times*.

Cancer and its Complications. The Local Origin of Cancer from the Various Parts of the Body, Preventive and Curative Treatment, etc. By C. E. JENNINGS, F.R.C.S. Eng., M.S., M.B. Price 3s. 6d.

Case-Books. Students' Case-book. For recording cases as seen, with full instructions for methodising clinical study. By GEORGE BROWN, M.R.C.S., Gold Medallist, Charing Cross Hospital. Third thousand, cloth. Price 1s. net.

Chemistry. Aids to Chemistry. By C. E. ARMAND SEMPLE, B.A., M.B. Cantab., M.R.C.P. Lond.

Part I.—Inorganic. The Non-metallic Elements. Price 2s. 6d., cloth ; 2s. paper wrapper.

Part II.—Inorganic. The Metals. Price 2s. 6d., cloth ; 2s. paper.

Part III.—Organic. Cloth, 2s. 6d. ; paper, 2s.

Part IV.—Tablets of Chemical Analysis. Price 1s. 6d. and 1s.

"Students preparing for Matriculation at the London University, and other Examinations, will find it simply invaluable."—*Students' Journal*.

Chemistry. A Manual of Chemistry ; a complete guide to Lectures and Laboratory work for beginners in Chemistry, and a text-book for students in Medicine and Pharmacy. By W. SIMON, Ph.D., M.D., Professor of Chemistry. Sixteen woodcuts, and coloured plates representing 56 Chemical reactions. Price 15s.

Chemistry. Chemistry in its Application to the Arts and Manufactures. A Text-book by RICHARDSON and WATTS.

Parts 1 and 2.—Fuel and its Applications. 433 engravings, and 4 plates. Price £1 16s.

Part 3.—Acids, Alkalies, Salts, Soap, Soda, Chlorine and its Bleaching Compounds, Iodine, Bromine, Alkalimetry, Glycerine, etc., their Manufacture. Price £1 13s.

Part 4.—Phosphorus, Mineral Waters, Gunpowder, Guncotton, Fireworks, Aluminium, Stannates, Tungstates, Chromates and Silicates of Potash and Soda, price £1 1s.

Part 5.—Prussiate of Potash, Oxalic Acid, Tartaric Acid, tables, plates, and wood engravings, price £1 16s.

Practical Treatise on Acids, Alkalies, and Salts : their Manufacture and Application. In three vols., being Parts III., IV., V. of the above work, price £4 10s.

Chemistry. The Principles of Theoretical Chemistry, with special reference to the Constitution of Chemical Compounds. By IRA REMSEN, M.D., Ph.D., Professor of Chemistry in the John Hopkins University. Third Edition, enlarged. Price 7s. 6d.

Chemistry. The Student's Hand-book, with Tables and Chemical Calculations. By H. LEICESTER GREVILLE, F.I.C., F.C.S. Second Edition. Price 6s.

Chemistry. Chemical Notes for Pharmaceutical Students. By A. RIVERS WILLSON. Second edition, price 3s. 6d.

"Of exceeding value to students going up for examination."—*Pharmaceutical Journal*.

- Chemistry.** A Short Manual of Analytical Chemistry for Laboratory Use. By JOHN MUTER, Ph.D., M.A., F.C.S. Price 6s. 6d.
- Chemistry.** An Introduction to Pharmaceutical and Medical Chemistry, Theoretical and Practical. With Analytical Tables and copious Index. By the same Author. Price 10s. 6d.
- “Very useful and original; brought up to the latest date.”—*Chemical News*.
- Children.** Selected Subjects in the Surgery of Infancy and Childhood. Being the Lettsomian Lectures for 1890 delivered at the Medical Society of London. By EDMUND OWEN, F.R.S.C., Senior Surgeon to the Hospital for Sick Children; Surgeon to St. Mary's Hospital. Illustrated. Price 3s. 6d.
- Children.** The Diseases of Children their History, Causes and Treatment. By C. E. ARMAND SEMPLE, B.A., M.B. Cantab., M.R.C.P. Lond., Physician to the North-Eastern Hospital for Children. Price 6s.
- Children.** Lectures on the Diseases of Children delivered at the Hospital for Sick Children. By ROBERT J. LEE, M.D. Cantab., F.R.C.P. Lond. Second edition, enlarged. Price 3s. 6d.
- Children.** Confidential Chats with Mothers. By Mrs. BOWDITCH. Price 2s.
- Children.** On Tetany in Young Children. By J. ABERCROMBIE, M.D., M.R.C.P. Lond. Price 2s.
- Children.** Modern Therapeutics of the Diseases of Children, with Observations on the Hygiene of Infancy. By T. F. EDWARDS, M.D. Price 12s. 6d.
- China.** Reports of the Medical Officers of the Chinese Imperial Maritime Customs Service, from 1871 to 1882, with the History of Medicine in China. Compiled by Surgeon General GORDON, M.D., C.B., Physician to Her Majesty the Queen. Price 21s.
- Cholera:** How to Prevent and Resist it. By Professor VON PETTENKOFER and T. WHITESIDE HIME, A.B., M.B. Second edition. Illustrated. Price 3s. 6d.
- Cholera.** The Cholera Microbe and How to Meet It. Read at the Congress of the British Medical Association. By CHARLES CAMERON, M.D., LL.D., M.P. Price 1s.
- Climatology.** The Book of Climates in all Lands. A Handbook for Travellers, Invalids, and others in search of Health and Recreation. By D. H. CULLIMORE, M.D., M.R.C.P. Lond., Surgeon in H.M. Indian Army (retired). Cloth limp, price 4s. 6d.

Coca. The Coca of Peru, its Remedial Principles, and Healing powers. By J. L. W. THUDICHUM, M.D., F.R.C.P. Price 1s.

Colours. A Hand-book for Painters and Art Students, on the use of Colours, Vehicles, etc. By W. J. MUCKLEY. Price 3s. 6d.

Consumption. Consumption as a Contagious Disease ; the Merits of the Air of Mountains and Plains. By D. H. CULLIMORE, M.D., M.R.C.P. Lond., formerly H.M. Indian Army. Price 5s.

Consumption. Consumption and its Treatment by the Hypophosphites. By JOHN C. THOROWGOOD, M.D., F.R.C.P. Lond., Physician to the City of London Hospital for Diseases of the Chest, Victoria Park. Third edition, price 2s. 6d.

Consumption. A Re-investigation of its Causes. By C. W. DE LACY EVANS, M.R.C.S. Eng. Price 2s. 6d.

Consumption. How to Prevent and Treat Consumption. By G. RUTLAND HOWAT, B.A. Lond. Price 2s. 6d.

Consumption. An Essay on Consumption : Its True Nature and Successful Treatment. By GODWIN W. TIMMS, M.D. Lond. Second edition, revised and enlarged, price 10s. 6d.

Consumption. Tuberculosis from a Sanitary and Pathological Point of View. By G. FLEMING, C.B., F.R.C.V.S., President of the Royal College of Veterinary Surgeons. Price 1s.

Deafness. (See Ear.)

Deformities. The Nature and Treatment of Deformities of the Human Body. By LAMBERT H. ORMSBY, M.B. Dub., Surgeon to the Meath Hospital and Dublin Infirmary. Price 5s.

Deaf-mutism. On the Education of Deaf-mutes by Lip-Reading and Articulation. By Professor HARTMANN. Translated by Dr. PATTERSON CASSELLS. Price 7s. 6d.

"The instruction of deaf-mutes is here rendered easy."—*Athenæum*.

"We can honestly recommend it to anyone seeking for knowledge."—*The Lancet*.

Dental Surgery. A Manual of Dental Surgery : Including Special Anatomy and Pathology. For Students and Practitioners. By HENRY SEWILL, M.R.C.S., L.D.S. Eng. Third edition, revised, rewritten, and much enlarged, with upwards of 200 illustrations, chiefly original, price 10s. 6d.

Dental. Dental Caries and the Prevention of Dental Caries. By HENRY SEWILL, M.R.C.S. and L.D.S. Eng. Second edition. Price 2s. 6d.

Dental. Aids to Dental Surgery. By ARTHUR S. UNDERWOOD, M.R.C.S., L.D.S. Eng. Price 2s. 6d. cloth; 2s. paper.

Dental. Journal of the British Dental Association. Monthly, price 6d.

Dermoids. A Course of Lectures delivered at the Royal College of Surgeons, England, 1889, on "Evolution in Pathology." By J. BLAND SUTTON, F.R.C.S., Hunterian Professor, Royal College of Surgeons. Price 3s., profusely illustrated.

"We commend the study of this book to all interested in the elucidation of pathological problems."—*The Lancet*.

Diagnosis. The Physiological Factor in Diagnosis. By J. MILNER THOROWGOOD, M.D., M.R.C.P. Lond. Second Edition. Price 7s. 6d.

"An exceedingly clever and well written book, put together in a very plain, practical, and taking way."—*Edinburgh Medical Journal*.

Diagnosis, Aids to. Three Parts. Price 1s. and 1s. 6d. each.
Part I.—Semeiological. By J. MILNER FOTHERGILL, M.D.

Part II.—Physical. By J. C. THOROWGOOD, M.D., F.R.C.P.
New edition. Containing the three parts. Edited by Dr. THOROWGOOD. In one volume. Price 3s. 6d. cloth.

Part III.—What to Ask the Patient. By J. MILNER FOTHERGILL.

"A mine of valuable information."—*Edinburgh Medical Journal*.

Diphtheria. Diphtheria, its Causes, Pathology, Diagnosis, and Treatment. By R. HUNTER SEMPLE, M.D., F.R.C.P. Lond. Second edition, price 2s. 6d.

Diseases.—The Classification and Nomenclature of Diseases. By A. RABAGLIATI, M.A., M.D., Senior Surgeon Bradford Infirmary, Surgeon to the Children's Hospital. Price 2s. 6d.

Diseases. The Salisbury Plans of Treatment by Alimentation of the Diseases produced by Unhealthy Feeding. By J. H. SALISBURY, M.D. Price 2s. 6d.

Domestic Medicine. Handbook of Popular Medicine for family instruction, colonists and others out of reach of medical aid. By G. H. NAPHEYS, A.M., M.D. With movable plate and 100 illustrations. Price 7s. 6d.

Ear. Text-book of the Diseases of the Ear and adjacent Organs. By Professor POLITZER, of Vienna. Translated by Sir W. DALBY, M.B. Cantab., F.R.C.S. Second Edition in the press.

"The work of a recognised master."—*British Medical Journal*.

- Ear.** On Unrecognised Lesions of the Labyrinth. Being the Cavendish Lecture for 1890. By ALEX OGSTON, M.D., C.M., Regius Professor of Surgery in the University of Aberdeen. Illustrated. Price 1s.
- Ear.** On Vascular Deafness. By ROBERT J. COOPER, M.D., Trinity College, Dublin. Price 3s. 6d.
- Ear.** Otorrhœa; or, Discharge from the Ears: Causes and Treatment. By W. DOUGLAS HEMMING, F.R.C.S. Ed. Price 1s.
- Electricity.** Electricity in General Practice. By W. BOLTON TOMSON, M.D., Musgrove Scholar, Treasurer's Gold Medallist, St. Thomas's Hospital. Price 2s. 6d.
- Etiquette.** A few Rules of Medical Etiquette. By a L.R.C.P. Lond. Price 1s.
- Examinations.** Aids to Examinations. By W.D. HEMMING, F.R.C.S. Ed., and H. AUBREY HUSBAND, M.B., F.R.C.S. Being Questions and Answers on Materia Medica, Medicine, Midwifery, Pathology, and Forensic Medicine. Price 1s. 6d. cloth, 1s. paper.
- Examinations.** A Guide to the Examinations of the Conjoint Board in England, and for the Fellowship of the College of Surgeons, with Examination Papers. By F. J. GANT, F.R.C.S. Sixth edition, revised and enlarged. Price 5s. net.
- Examinations.** A Guide to the Examinations of the Apothecaries' Society of London, with Questions, Tables on Materia Medica, etc. By W. E. DAWSON, L.S.A. Second edition. Price 2s. 6d.
- "May be studied with great advantage by a student, shortly before presenting himself for examination."—*British Medical Journal*.
- Examinations.** The Irish Medical Students' Examiner. Examination Questions at the University of Dublin, Royal University, King and Queen's College of Physicians, Royal College of Surgeons, and Army and Navy Competitions. Price 2s. net.
- Examinations.** Examination Questions on the Medical Sciences, including the Army, Navy and University Examinations. Selected and arranged by JAMES GREIG LEASK, M.B. Abdn. Second edition. Price 2s. 6d.
- "Dr. Leask's questions are particularly suitable for pure examination study. Students should test themselves thereby."—*British Medical Journal*.
- Examination Cards:** Questions and Answers. By A. T. SCHOFIELD, M.D. Pathology, 2 sets, 9d. each. Minor Surgery, Bandaging, etc., 9d.
- Eye.** Student's Guide to Diseases of the Eye (Aids Series). By J. HUTCHINSON, jun., F.R.C.S., Ophthalmic Surgeon to the Great Northern Hospital. Cloth, 2s. 6d.; paper, 2s.

Eye. The Cure of Cataract and other Eye Affections. By JABEZ HOGG, M.R.C.S., Consulting Surgeon to the Royal Westminster Ophthalmic Hospital. Third edition. Price 2s. 6d.

Eye. On Impairment or Loss of Vision from Spinal Concussion or Shock. By the same Author. Price 1s. 6d.

Eye. The Functions of Vision and its Anomalies. By Dr. GIRAUD TEULON. Translated by LLOYD OWEN, F.R.C.S.I., Surgeon to the Midland Eye Hospital, Ophthalmic Surgeon to the Hospital for Sick Children Birmingham. Price 5s.

Eye. Movable Atlas of the Eye and the Mechanism of Vision. By Prof. G. J. WITKOWSKI. Price 7s. 6d. (See Anatomy.)

(The following four works have been translated for the National Society for the Prevention and Cure of Blindness.)

Mind your Eyes. By F. SARCEY. Price 2s. 6d.

The Causes and Prevention of Blindness. By Professor FUCHS, University of Liege. Price 7s. 6d.

How to Preserve the Sight. By Dr. MAGNÉ. Price 6d.

On Spectacles, their History and Uses. By Prof. HORNER. Price 6d.

Fasting and Feeding, Psychologically considered. By L. S. FORBES WINSLOW, M.B. Cantab., D.C.L. Oxon. Price 2s.

Fever. On the Endemic Hæmaturia of Hot Climates, caused by the presence of Bilharzia Hæmaturia. By F. H. H. GUILLEMARD, M.A., M.D., F.R.G.S. Price 2s.

Fever Charts. Daily Clinical Fever Charts, to record the progress of a case of continued or eruptive fever. By F. MAGEE FINNY, M.D. Price 5s.

Food. Aids to the Analysis of Food and Drugs. By H. AUBREY HUSBAND, M.B., F.R.C.S., Lecturer on Public Health, in the Edinburgh Medical School. Price 1s. 6d., cloth; 1s. paper.

Food. The Healthy Manufacture of Bread. By B. W. RICHARDSON, M.D., F.R.S. Price 6d., paper cover; cloth 1s., with Vignette.

Foot. Movable Atlas of the Foot; its Bones, Muscles, etc. By Prof. WITKOWSKI. Price 7s. 6d. (See Anatomy.)

Forensic Medicine. The Student's Handbook of Forensic Medicine and Public Health. By H. AUBREY HUSBAND, M.B., F.R.C.S.E. Sixth Edition. Price 10s. 6d.

Forensic Medicine. Aids to Forensic Medicine and Toxicology. By W. DOUGLAS HEMMING, F.R.C.S.E., and H. AUBREY HUSBAND, M.B., F.R.C.S.E. Fifth thousand, price 2s. 6d. cloth, 2s. paper.

Geology. Field Geology, with a Section on Palæontology. By W. HY. PENNING, F.G.S., of H.M. Geological Survey, and A. J. JUKES-BROWNE, B.A., F.G.S. With woodcuts and coloured map. Second edition, revised and enlarged, price 7s. 6d.

"Others have taught us the principles of the science, but Mr. Penning, as an accomplished field-geologist, introduces us to the practice."—*The Academy*.

Geology. Engineering Geology. By the same Author. Illustrated with coloured maps and woodcuts, price 3s. 6d.

"A full and lucid description of surveying and mapping, the diagnosing of the various minerals met with, the value of sites, rocks, etc."—*Popular Science Review*.

Geometry. Aids to Analytical Geometry. I. The Straight Line and Circle. By A. LE SUEUR, B.A. Cantab. Second Edition, 2s.

II. The Conic Sections, with solutions of questions set at the London University and other Examinations by GEORGE HEPPEL, M.A. Cantab. Price 2s.

Gout. A Treatise on Gout. By AUSTIN MELDON, M.K.Q.C.P., F.R.C.S.I., Senior Surgeon Jervis Street Hospital, Consulting Physician Dublin General Infirmary. Tenth edition, price 2s. 6d.

Gout. The Nature and Treatment of Gout. By Professor EBSTEIN of Gottingen University. Translated by J. E. BURTON, L.R.C.P. Lond. Price 3s. 6d.

Gymnastics. A Short Sketch of Rational Medical Gymnastics ; or, the Movement-Cure. By M. ROTH, M.D., F.R.C.S. Eng. With thirty-eight engravings, price 1s.

The Prevention and Cure of Many Chronic Diseases by Movements. Same Author. With 90 engravings, price 5s.

Paralysis in Infancy, Childhood, and Youth, and on the Prevention and Treatment of Paralytic Deformities. Same Author. 3s. 6d.

The Prevention and Rational Treatment of Lateral Spine Curvature. (Gold Medal of the International Health Exhibition, 1884.) 200 engravings. Price 5s.

Gynæcology. The Diseases of Women and their Treatment. By H. MACNAUGHTON JONES, M.D., F.R.C.S.I., F.R.C.S.E., Examiner in Midwifery, Royal College of Surgeons, Ireland. Fourth edition. Illustrated, price 10s. 6d.

"The work of a mature and experienced authority."—*British Medical Journal*.

"Of exceptional merit drawn from a field of wide personal experience."—*Medical Press*.

Gynæcology. Aids to Gynæcology. By ALFRED S. GUBB, M.R.C.S., L.R.C.P., Obstetric Assistant and Gold Medallist Westminster Hospital. Cloth 1s. 6d., price 1s.

Hair. The Hair: its Growth, Care, Diseases, and Treatment. By C. H. LEONARD, M.A., M.D. Illustrated, price 7s. 6d.

Hand. Movable Atlas of the Hand ; its Bones, Muscles and Attachments. By Prof. WITKOWSKI. Price 7s. 6d. (See Anatomy.)

Hay Fever : its Causes, Treatment, and Effective Prevention ; Experimental Researches. By CHAS. HARRISON BLACKLEY, M.D. Second edition, revised and enlarged, price 10s. 6d.

"A piece of real honest work, original and instructive."—*Lancet*.

Heart. On Insufficiency of Aortic Valves in Connection with Sudden Death. By JOHN COCKLE, A.M., M.D., F.R.C.P., Physician to the Royal Free Hospital. Second edition, price 2s. 6d.

Heart. Contributions to Cardiac Pathology. By the same Author. Price 2s. 6d.

Heart. An Essay on Fatty Heart. By HENRY KENNEDY, A.B., M.B. Physician to the Whitworth Hospitals. Price 3s. 6d.

Heredity and Disease. From Generation to Generation. By DOUGLAS LITHGOW, LL.D., M.R.C.P., Lond. Price 4s. 6d.

Hernia and Intestinal Obstruction. By J. ROCHE, M.D. 6d.

Histology. Introduction to Practical Histology. By GEORGE THIN, M.D. Price 5s.

History of the Royal College of Surgeons in Ireland. By Sir C. A. CAMERON. Price 10s. 6d.

Hydrophobia. Inoculation for Rabies and Hydrophobia. A Study of the Literature of the subject. By Surgeon-General C. A. GORDON, C.B. Price 2s. 6d.

Hydrophobia. Comments on the Reports of the Committee on M. Pasteur's Treatment. By Surgeon-General C. A. GORDON, M.D., C.B. Price 2s. 6d.

Hydropathy. Notes of Visits to Contrexéville and Royat-les-Bains. By F. R. CRUISE, M.D. Price 6d.

Hygiene. Nature's Hygiene. By Kingzett. Third Edition, 7s. 6d.

Hygiene. Lessons in Military Hygiene and Surgery, from the Franco-Prussian War. Prepared on behalf of Her Majesty's Government. By Surgeon-General GORDON, M.D., C.B., Hon. Physician to the Queen. Illustrated, price 10s. 6d.

Hygiene. A Manual of Sanitation ; or, First Help in Sickness and when Wounded. Alphabetically arranged by the same. Cloth, 2s. 6d., sewn, 1s.

"A most useful and practical manual, and should be placed in the hands of officers and men alike."—*The Graphic*.

Hygiene. The Elements of School Hygiene for the Use of Teachers and Schools. By W. E. ROTH, B.A. Price 3s. 6d.

Hygiene. Theatre Hygiene, a study in construction, safety and healthy arrangement. By W. E. ROTH, B.A. Oxon. Price 1s. 6d.

Hygiene. Healthy Homes. By STANLEY HAYNES, M.D., M.R.C.S., F.R.G.S. Price 1s.

- Hygiene.** Notes on Nuisances, Drains, and Dwellings. By W. H. PENNING, F.G.S. Second edition, price 6d.
- Hygiene.** Short Lectures on Sanitary Subjects. By RICHARD J. HALTON, L.K.Q.C.P., L.R.C.P. Ed., L.R.C.S.I., etc. Price 5s.
- Hygiene.** A Manual of Naval Hygiene, with Instructions and Hints on the Preservation of Health and the Prevention of Disease on board Ship. By JOSEPH WILSON, M.D. 2nd ed., 10s. 6d.
- Hygiene.** The Sanitation of Public Institutions. The Howard Prize Essay. By R. D. R. SWEETING, M.R.C.S., Medical Superintendent of the Western Fever Hospital. Price 3s. 6d.
- Hypnotism.** Psycho-Therapeutics. Treatment by Sleep and Suggestion. By J. LLOYD TUCKEY, M.D. Second Edition, price 3s. 6d.
- India.** Experiences of an Army Surgeon in India. The Treatment of Wounds, Injuries and Diseases incidental to a Residence in that Country. By Surgeon-General GORDON, M.D., C.B., Hon. Physician to the Queen. Price 3s. 6d.
- International Medical Congress.** The Commemorative Portrait-Picture of the International Medical Congress, 1881. Designed and executed by Mr. BARRAUD; nearly 700 Likenesses of Members, representing Medicine and Surgery in every part of the world; special sittings accorded for every Portrait.
- The Picture is Printed by the New Permanent Carbon Process in two Sizes:—*
- | | | | |
|--|---------|----------|---------|
| EXTRA SIZE, 47 × 30, MOUNTED, BUT UNFRAMED | £7 10s. | FRAMED - | £10 0s. |
| POPULAR SIZE, 29 × 20, MOUNTED, BUT UNFRAMED | £3 3s. | FRAMED - | £4 10s. |
- Kidneys.** Vaso-Renal Change *versus* Bright's Disease. By J. MILNER FOTHERGILL, M.D. Ed. Price 7s. 6d.
- Kidneys.** Bright's Disease of the Kidneys. By Professor J. M. CHARCOT. Translated by H. B. MILLARD, M.D., A.M. Revised by the Author, with coloured plates, price 7s. 6d.
- Knee-Joint.** The Surgery of the Knee-Joint, and the Responsibility placed on the Physician and General Practitioner by the Modern Process of Surgery. By C. B. KEETLEY, F.R.C.S., Senior Surgeon to the West London Hospital, and Surgeon to its Orthopædic Department. Cloth, price 1s. 6d.
- Lunacy.** Handbook for the Instruction of Attendants on the Insane. Prepared by a Committee of the Medico-Psychological Association. With Appendix containing Lists of Asylums and Licensed Houses. Price 2s.
- Materia Medica.** Comprising the Drugs contained in the Schedule issued by the Conjoint Board of the Royal College of Physicians and Surgeons. Arranged by MAURICE WILLIAMS, Principal of the City School of Chemistry and Pharmacy. Price 3s. 6d.

Materia Medica. Table of Doses. By J. H. ALLAN, F.C.S.
Price 6d., cloth.

Materia Medica. A Key to Organic Materia Medica. By JOHN MUTER, Ph.D., M.A., F.C.S., President of the Society of Public Analysts. Third edition, price 12s. 6d.

Materia Medica. Aids to Materia Medica and Therapeutics. By C. E. ARMAND SEMPLE.

Part I.—The Non-metallic and Metallic Elements, Alcoholic and Ethereal Preparations, etc. Cloth 2s. 6d., paper 2s.

Part II.—The Vegetable and Animal Substances. 2s. 6d., 2s.

Part III.—Classification of Remedies. Cloth, 1s. 6d., paper, 1s.

Part IV.—New Remedies of the British Pharmacopœia. Cloth 2s. 6d., paper 2s.

Part V.—Tablets of Materia Medica. Price, cloth 1s. 6d., paper 1s.

Materia Medica and Pharmacy. A Text-Book for Medical and Pharmaceutical Students preparing for Examination. By W. HANDSEL GRIFFITHS, Ph.D., F.C.S., F.R.C.P. Ed. Third edition. Edited by A. S. GUBB, L.R.C.P. Lond., M.R.C.S., Gold Medallist, Prizeman in Materia Medica, Westminster Hospital. Price 7s. 6d.

"A book of great value . . . a standard text-book."—*Edin. Med. Journal*.

"One of the ablest, if not the best, work on the subject in our language."—*Med. Press*.

Materia Medica. Notes on Inorganic Materia Medica, and its Chemistry. By J. S. SHARMAN. Second edition. Price 1s. 6d.

Materia Medica, Notes on Materia Medica and Therapeutics. Mineral Drugs, Part I. By J. S. MCARDLE. Price 1s.

Medical Education. Medical Education and Organization. The Hunterian Oration for 1880. By WALTER RIVINGTON, B.A., M.B., F.R.C.S., Surgeon to the London Hospital. Price 1s.

Medical Etiquette. A Few Rules of Medical Etiquette. By a L.R.C.P. Lond. Price 1s.

Medical Laws. Medical Law for Medical Men: their Legal Relations popularly explained. By Professor MEYMOTT TIDY, M.B., F.C.S., Barrister-at-Law, and PERCY CLARKE, LL.B., Solicitor. Leather, gilt edges, price 4s.

Medical Laws. The Laws Relating to Medical Men. By JAMES GREENWOOD, Barrister-at-Law. Price 5s.

"Admirably suited as a guide to the busy practitioner, who frequently runs great risks of becoming involved in legal penalties, in consequence of an imperfect knowledge of the law."
—*Glasgow Medical Journal*.

Medical Profession. A Guide to the Medical Profession in all its branches, including the Public Services. By C. R. B. KEETLEY, F.R.C.S. Second Edition, revised and enlarged. Price 3s. 6d.

Medical Profession. The Medical Profession: the First Carmichael Prize for 1879. By WALTER RIVINGTON, B.A., M.B., F.R.C.S. Price 6s.

BY SAME AUTHOR AND ON SAME SUBJECT.

The First Carmichael Prize Essay for 1887. Price 15s.

The Second Prize Essay, 1879. By T. LAFFAN, L.K.Q.C.P.I., M.R.C.S. Ed. Price 4s.

BY SAME AUTHOR AND ON SAME SUBJECT.

The Second Prize, Essay 1887. Price 7s. 6d.

Medical Profession. Medical Men and Manners of the Nineteenth Century. By a Physician. Third Thousand, price 3s.

"At times scathing, at others amusing, the author is never dull, and writes as one who knows the many blots on our system, and honestly tries to remedy them."—*Medical Press*.

Medical Reform. A Letter to the Right Hon. A. J. Mundella, M.P. By JAMES GREY GLOVER, M.D. Edin. Price 1s.

Medical Reform. The General Medical Council: Whom it Represents, and How it should be Reconstructed. By ARCHIBALD HAMILTON JACOB, M.D. Dub., F.R.C.S., Surgeon-Oculist to His Excellency the Lord Lieutenant. Price 1s.

Medicine. Aids to Medicine. By C. E. ARMAND SEMPLE, B.A., M.B., Cantab., M.R.C.P. Lond.

Part I.—General Diseases. Price 2s. 6d. and 2s.

Part II.—The Urine, Kidneys, Stomach, Peritoneum, Throat, and Esophagus. Third Thousand, price 2s. 6d. and 2s.

Part III.—Diseases of the Brain, Nervous System, and Spinal Cord. Third thousand, price 2s. 6d. and 2s.

Part IV.—Fevers, Skin Diseases. Price 2s. 6d. and 2s.

Medicine. A Chronology of Medicine from the Earliest Times. By J. MORGAN RICHARDS. Price 10s. 6d.

Medicine. Student's Handbook of the Practice of Medicine. By H. AUBREY HUSBAND, M.B., C.M., B.Sc. Fourth edition revised and enlarged. Illustrated. Price 7s. 6d.

Medico-Military Services. Our Services under the Crown. A Historical Sketch of the Army Medical Staff. By Surgeon-Major A. GORE, M.D., Sanitary Officer on the Staff. Price 6s.

Memory. Its Logical Relations and Cultivation. By F. W. EDRIDGE GREEN, M.B., B.S. Durham, M.R.C.S., L.R.C.P. Lond. Price 6s.

Meteorology. The Moon and the Weather: the probability of Lunar Influence reconsidered. Showing how storms and depressions may be predicted. By WALTER J. BROWNE (St. Petersburg). Second edition, price 3s.

Microbes, in Fermentation, Putrefaction, and Disease. By CHAS. CAMERON, M.D., LL.D., M.P. Price 1s.

Professor Tyndall, F.R.S., writes :—" Matthew Arnold himself could not find fault with its lucidity, while as regards knowledge and grasp of the subject I have rarely met its equal."

Microscopical Science. Methods of Microscopical Research. By A. C. COLE. Price 5s.

Microscopical Science. The Journal of Microscopy and Natural Science. Edited for the Postal Microscopical Society by ALFRED ALLEN. Quarterly with plates. Price 1s. 6d.

Midwifery. The Principles and Practice of Midwifery and Diseases of Women. By ALEXANDER MILNE, M.D., Vice-president of the Obstetrical Society of Edinburgh. Second edit., price 12s. 6d.

Mind. The Training of the Mind for the Study of Medicine. A Lecture delivered at St. George's Hospital. By ROBERT BRUDENELL CARTER, F.R.C.S., Surgeon to the Hospital. Price 1s.

"A remarkable address."—*The Lancet*.

"No one can read it without learning and profiting much."—*Students' Journal*.

Mineral Waters. The Mineral Waters of Europe. A complete Analytical Guide to all the Bottled Waters, and their Medicinal and Therapeutic Values. By PROFESSOR TICHEBORNE, LL.D., F.C.S., President of the Pharmaceutical Society of Ireland, and M. PROSSER JAMES, M.R.C.P. Lond., Lecturer on Therapeutics, London Hospital. Price 3s. 6d.

"Such a book as this is simply invaluable."—*The World*.

Morals. A Physician's Sermon to Young Men. By WILLIAM PRATT, M.A., M.D., etc. Eighth thousand, price 1s. cloth.

"The delicate topic is handled wisely, judiciously, and religiously, as well as very plainly."—*The Guardian*.

Morals. Revelations of Quacks and Quackery. With Facts and Cases in Illustration of their Nefarious Practices. By "DETECTOR." Thirtieth thousand, price 2s.

Nervous Diseases. Functional Nervous Diseases, their Causes and Treatment. By GEO. T. STEVENS, M.D., Ph.D. With plates. Price 12s.

Nerve Supply. Atlas of Cutaneous Nerve Supply. By JACOB HEIBERG, M.D., and W. W. WAGSTAFFE, F.R.C.S., containing 10 plates in colours. Price 4s. 6d.

New Remedies. A Summary of New Remedies: their Physiological Action and Therapeutic Uses. By THOS. M. DOLAN, M.D. Price 2s. 6d.

- Note-book.** Suggestions for a plan of taking notes in medical cases. By GEO. F. DUFFEY, M.D. Dublin. Price 6d.
- Nursing.** Questions and Answers on Nursing, for St. John's Ambulance Associations, Nursing Institutes, and Nurses generally. By JOHN W. MARTIN, M.D., author of "Ambulance Work." Twelfth thousand. Price 1s. 6d. nett.
- Nursing.** How to Feed an Infant. With an Appendix on the Common Ailments of Infancy, with their Hygienic and Curative Treatment. By BENSON BAKER, M.D. Price 1s. 6d.
- Nursing.** How to bring up Children by Hand. By J. FOSTER PALMER, L.R.C.P. Price 6d.
- Nursing.** Practical Guide for the Young Mother. From the French of Dr. BROCHARD, Director-General of Nurseries and Crèches, with Notes and Hints by a London Physician. Price 2s.
- Obstetrics.** Aids to Obstetrics. By SAMUEL NALL, M.B. Cantab., M.R.C.P. Lond., First Class Honours Nat. Sci. Cambridge, Resident Obstetric Assistant, St. Bartholomew's Hospital. Tenth thousand. Price 2s. 6d. cloth, 2s. paper wrapper.
- Obstetrics.** Hints for Midwives on Pregnancy and Labour. Abstracts of a Series of Lectures by H. MACNAUGHTON JONES, M.D., M.C.H., F.R.C.S. Price 1s.
- Obstetrics.** On Fibrous Tumours of the Womb: their Pathology, Diagnosis and Treatment. By C. H. F. ROUTH, M.D., M.R.C.P. Lond., Physician to the Samaritan Hospital. Price 3s. 6d.
- Obstetrics.** Hints for the use of Midwives preparatory to their Examinations. By R. J. M. COFFIN, F.R.C.P. Ed. Price 1s.
- Old Age.** The Diseases of Sedentary and Advanced Life. By J. MILNER FOTHERGILL, M.D., M.R.C.P. Lond. Price 7s. 6d.
- Osteology.** Osteology for Students, with Atlas of Plates. By ARTHUR TREHERN NORTON, F.R.C.S., Surgeon to, and Lecturer on Surgery at, St. Mary's Hospital. Atlas and Text in one volume, 7s. 6d.; in two volumes, 8s. 6d.
- "The handiest and most complete hand-book of Osteology."—*The Lancet*.
- Overwork.** Overwork and Premature Mental Decay: its Treatment. By C. H. F. ROUTH, M.D., M.R.C.P. Lond. Fourth edition. Price 2s. 6d.
- Pathology.** Handbook of Medical Pathology. By H. G. SUTTON, M.B., F.R.C.P. Lond., Physician to, and Lecturer on Pathology at, the London Hospital. Price 5s.

"Such a work is to be accepted with gratitude for the thoughts it contains, and the facts on which they are based."—*The Lancet*.

Pathology. Handbook of Surgical Pathology. Edited by W. J. WALSHAM, M.B., F.R.C.S., and D'ARCY POWER, M.B. Oxon., F.R.C.S. Second edition, price 9s.

"An embodiment of the most modern pathological teaching."—*The Lancet*.

Pathology. Examination Cards. Arranged as questions and answers for self-examination. By A. T. SCHOFIELD, M.D., M.R.C.S. Complete in two sets of cards, price 9d. nett per set.

Mr. Jonathan Hutchinson, F.R.C.S., writes: "It is an invaluable means of self-tuition."

Peritonitis. Localised Peritonitis: its Etiology, Diagnosis and Treatment. By JOHN WALLACE, M.D., Professor of Midwifery in the Victoria University. Illustrated. Price 1s.

Pharmacopœia. The Pocket Pharmacopœia. A Précis of the British Pharmacopœia, including the Therapeutical Action of the Drugs, their Natural Orders and Active Principles. By C. ARMAND SEMPLE, M.D., M.R.C.P. Price 3s. 6d.

Pharmacopœia. Notes on the Pharmacopœial Preparations for Pharmaceutical Students. By HANDSEL GRIFFITHS; revised by A. S. GUBB, L.R.C.P., M.R.C.S. Price 3s. 6d.

Pharmacy. Latin Grammar of Pharmacy, for the use of Students, with an Essay on Latin Prescriptions. By JOSEPH INCE, A.K.C.L., formerly Examiner and Member of Council, Pharmaceutical Society. Fifth Edition. Price 5s.

Pharmacy. Aids to Pharmacy. By C. E. ARMAND SEMPLE, M.B. Cantab., M.R.C.P. Lond. Cloth, price 2s. 6d.; paper, 2s.

Pharmacy. A Treatise on Pharmacy. A Text-book for Students, and a Guide for the Physician and Pharmacist. By EDWARD PARRISH. Fifth edition, revised by T. S. WIEGAND, F.C.S. With 300 illustrations, half-bound morocco, price 30s.

"There is nothing to equal Parrish's Pharmacy in any language."—*Pharmaceutical Journal*.

Phimosis. Its Causes, Symptoms, and Treatment; with a description of the ancient rite of circumcision. By L. H. ORMSBY, M.D., F.R.C.S.I., Lecturer on Clinical and Operative Surgery at, and surgeon to, the Children's Hospital, Dublin. Price 1s.

Physics. A Manual of Physics. By M. PEDDIE, D.Sc., Lecturer on Physics in the University of Edinburgh. University Series of Manuals. In the press.

Physiology. Aids to Physiology. By B. THOMPSON LOWNE, F.R.C.S., Arris and Gale Lecturer, and Examiner in Physiology Royal College of Surgeons of England. Fourth thousand, illustrated. In two parts 2s. each, or in one vol., cloth, 4s. 6d.

"As 'aids' and not substitutes, they will prove of real value to students."—*Medical Press*.

"Certainly one of the best of the now popular 'Aid Series.'"—*Students' Journal*.

- Physiology.** A Manual of Physiology. By STEWART GUY. University Series of Manuals. In the press.
- Physiology.** The Physiologist in the Household. By J. MILNER FOTHERGILL, M.D., M.R.C.P. Part I.—Adolescence. Price 1s.
- Physiological Chemistry.** Aids to Physiological Chemistry. By J. L. THUDICHUM, M.D., F.R.C.P., Lond., St. Thomas's Hospital. Cloth, price 2s. 6d. Wrapper, 2s.
- Physiological Factor in Diagnosis.** By J. MILNER FOTHERGILL, M.D., M.R.C.P., Lond., Physician to the City of London Hospital for Diseases of the Chest. Second edition. Price 7s. 6d.
- Physiological Laboratory.** Manual for the Physiological Laboratory. By VINCENT HARRIS, M.D., M.R.C.P., Examiner in Physiology, Royal College of Physicians of London, and D'ARCY POWER, M.B. Oxon., Curator of Museum, St. Bartholomew's Hospital. Fourth edition, price 5s. 6d.
- “This manual is already well and favourably known, and the new edition contains many valuable additions.”—*Lancet*.
- Plant Analysis.** Quantitative and Qualitative. By G. DRAGENDORFF, Professor of Chemistry and Pharmacy in the University of Dorpat. Translated by HY. G. GREENISH, A.I.C. 7s. 6d.
- Polypus** in the Nose and other Affections of the Nasal Cavity; their successful treatment. By J. L. W. THUDICHUM, M.D., F.R.C.P. Lond. Sixth edition. Price 1s.
- Population.** On the Evils, Moral and Physical, likely to follow, if practices, intended to act as checks to population, be not strongly discouraged and condemned. By C. H. F. ROUTH, M.D., F.R.C.P. Second thousand, price 1s.
- Posology.** Posological Tables: a Classified Chart, showing at a glance the Dose of every Official Substance and Preparation. By HANDSEL GRIFFITHS, Ph.D., L.R.C.P. Fifth edition, revised by PETER W. SQUIRE, F.L.S., F.C.S., price 1s.; or mounted on linen, rollers, and varnished, 3s. 6d.
- Pregnancy.** The Diagnosis and Treatment of Extra-uterine Pregnancy. By JOHN STRAHAN, M.D., M.Ch. (The Jenks Triennial Prize Essay awarded by the College of Physicians, 1889.) Price 4s. 6d.
- Prescriptions.** The Student's Pocket Prescriber. By H. AUBREY HUSBAND, M.B., F.R.C.S.E. Price 1s., cloth.
- Public Health.** The Practical Guide to the Public Health Acts and Correlated Acts, for Officers of Health and Inspectors of Nuisances. By THOS. WHITESIDE HIME, B.A., M.B. Leather, gilt edges, price 5s.
- Public Health.** Aids to Public Health. By J. L. THUDICHUM, M.D., F.R.C.P., Lond. Price 1s. 6d. cloth; 1s. paper wrapper.

- Rheumatism.** Its Treatment by Electric Massage, etc., in connection with the Wiesbaden Thermal Waters. By CARL MORDHORST, M.D. Kiel. Price 1s.
- Rupture of the Perineum.** Its Causes, Prevention and Treatment. By MICHAEL JOSEPH MOLONY, M.R.C.P., L.R.C.S. Price 2s. cloth, 1s. 6d. paper.
- Salt.** History of Salt, with Observations on its Medicinal and Dietetic Properties. By EVAN MARLETT BODDY, F.R.C.S., F.S.S., L.R.C.P. Price 2s. 6d.
- Sewage.** The Sewage Question: Reports upon the Principal Sewage Farms and Works of the Kingdom, with Notes and Chemical Analyses. By the late Dr. LETHEBY. Price 4s. 6d.
- Skeleton.** Movable Atlas of the Skeleton and its Articulations, showing the Bones and Ligaments of the Human Body and Limbs. By Prof. WITKOWSKI. Price 7s. 6d. (See Anatomy.)
- Skin Diseases of Infancy and Early Life.** By C. M. CAMPBELL, M.D., C.M. Edin. Price 5s.
- Skin. Scabies:** its Causation, Diagnosis, and Treatment. By ARTHUR HARRIES, M.D. Price 6d.
- Skin.—Lupus.** A Pathological and Clinical Investigation. By ARTHUR HARRIES, M.D., and C. M. CAMPBELL, M.D. Price 1s.
- Skin.** Some Diseases of the Skin produced by derangements of the Nervous System. By T. STRETCH DOWSE, M.D., F.R.C.P.E. Price 2s.
- Skin.** The Treatment of Chronic Skin Diseases. By E. D. MAPOTHER, M.D. Price 3s. 6d.
- Skin.** The Classification, Correct Dietary, and New Method of Treating Diseases of the Skin. By H. S. PURDON, M.D., Physician to the Belfast Hospital for Skin Diseases. Price 2s.
- Sphygmograph.** The Sphygmograph: its History, and use as an aid to Diagnosis. By R. E. DUDGEON, M.D. Price 2s. 6d.
- Stricture.** Stricture of the Urethra: its Diagnosis and Treatment. By E. DISTIN MADDICK, F.R.C.S. Edin., late Surgeon R.N. 4s.
- Surgery.** The Science and Practice of Surgery, a Complete Text-book. By F. J. GANT, F.R.C.S., Senior Surgeon Royal Free Hospital. Third edition, with nearly 1,100 engravings. 2 vols., price 36s.
- "The entire work has been revised to present the modern aspects of Surgery."—*Lancet*.
 "Does credit to the author's thorough surgical knowledge."—*British Medical Journal*.
- Surgery.** The Student's Surgery: a Multum in Parvo. By F. J. GANT, F.R.C.S. 850 pp., illustrated. Price 10s. 6d.
- "It well fulfils the object for which it is written." *The Lancet*.
 "From the student's point of view it is a necessity."—*British Medical Journal*.

- Surgery.** The Rules of Aseptic and Antiseptic Surgery, for the use of Students and General Practitioners, with 248 engravings and 3 chromo-lithographic plates. By A. G. GERSTER, M.D., Professor of Surgery at the New York Polyclinic. Price 15s.
- Surgery. Operative Surgery on the Cadaver.** By JASPER J. GARMANY, A.M., M.D., F.R.C.S. Price 8s. 6d.
- Surgery.** Aids to Surgery. By GEORGE BROWN, M.R.C.S. Parts I. and II., price 1s. 6d. and 1s. each.
- Surgery.** The Text-book of Operative Surgery. With 88 beautifully engraved steel plates, after BERNARD and HUETTE. Text by ARTHUR TREHERN NORTON, F.R.C.S., Surgeon to, and Lecturer on Surgery at, St. Mary's Hospital. Second Edition, half calf, plain, 25s.; hand coloured, 50s.
 "Of the highest merit as a guide to operative surgery."—*Students' Journal*.
 Student's Surgery. An abridgment of the above. 13s. 6d.
- Surgery. Annals of Surgery.** A monthly Review of Surgical Science and Practice, published simultaneously in America and London. Edited by L. S. PILCHER, M.D., and C. B. KEETLEY, F.R.C.S. Price 2s., or 21s. per annum post free.
- Surgery.** The Anatomy of Surgery. By JOHN McLACHLAN, M.B., M.R.C.S. With 74 illustrations. Two vols., price 10s.
- Surgery, Minor—and Bandaging.** Cards for Self-examination by means of Questions and Answers. Arranged by A. T. SCHOFIELD, M.D. Price 9d. nett.
- Surgical Pathology.** Handbook of Surgical Pathology. By W. J. WALSHAM, M.B., F.R.C.S., and D'ARCY POWER, M.B., F.R.C.S. Second Edition, price 9s.
 "An embodiment of the most modern pathological teaching."—*The Lancet*.
- Surgical Operations.** Chart of Instruments and Appliances required. By C. H. ORMSBY. Price 2s. 6d., or mounted on linen, varnished, with rollers, 7s. 6d.
- Surgical Treatment.** Notes on Surgical Treatment and Minor Operations. Designed especially for House Surgeons and Students. By T. F. HOPGOOD, L.R.C.P., M.R.C.S. Surgeon to the Sunderland Infirmary. Price 2s. 6d.
- Syphilis.** The Diagnosis of Syphilis. By J. K. BARTON, M.D., F.R.C.S.I. Price 1s. net.
- Syphilis.** The Nature and Treatment of Syphilis and the other so-called Contagious Diseases. By C. R. DRYSDALE, M.D., M.R.C.P. Lond., F.R.C.S. Eng. Fifth edition. Price 5s.
- Temperature Charts** for Recording the Range of Temperature, Pulse, Respiration, History, Progress, and Treatment of Cases, By E. W. MOORE, M.D., M.R.C.P. Price 1d. each, 9d. per dozen, or mounted, similar to a blotting-pad, 50, 3s. 6d.; 100, 7s.

Theories of Disease. A Parasitic or Germ Theory of Disease: the Skin, Eye, and other affections. By JABEZ HOGG, M.R.C.S., Consulting Surgeon to the Royal Westminster Ophthalmic Hospital. Second edition, price 2s. 6d.

Theories of Disease. The Germ Theories of Infectious Diseases. By JOHN DRYSDALE, M.D., F.R.M.S., President of the Liverpool Microscopical Society. Price 1s.

Theories of Life. The Protoplasmic Theory of Life. By JOHN DRYSDALE, M.D., F.R.M.S. Price 5s.

Theories of Life. How to Prolong Life? Showing the Diet and Agents best adapted for a lengthened prolongation of existence. By C. W. DE LACY EVANS, M.R.C.S. Second edition. Price 5s.

"A good account of the changes which occur with the advance of age."—*Lancet*.

Therapeutics. The Principles and Methods of Therapeutics. From the French of ADOLPHE GUBLER, M.D., Professor of Therapeutics in the Paris Faculty of Medicine, price 18s.

Therapeutics. The Therapeutics of the Respiratory Passages. By PROSSER JAMES, M.D., Lecturer on Materia Medica and Therapeutics at the London Hospital. Price 10s. 6d.

"Dr. Prosser James has produced a scholarly treatise"—*New York Medical Record*.

"It must be pronounced as sound and good."—*Lancet*.

Therapeutics. Aids to Rational Therapeutics, for the guidance of Practitioners and Senior Students. By J. MILNER FOTHERGILL, M.D. Second edition. Price 2s. 6d., cloth; 2s., paper wrapper.

Throat. Movable Atlas of the Throat, and the Mechanism of Voice, Speech, and Taste. By Prof. WITKOWSKI. (See Anatomy.)

Throat. Diseases of the Throat. A Practical Guide to Diagnosis and Treatment. With 220 typical illustrations in chromolithography and numerous wood engravings. By LENNOX BROWNE, F.R.C.S. Edin., Senior Surgeon to the Central London Throat and Ear Hospital. Third edition. Price 21s.

Throat. Affections of the Throat and Larynx. By ARTHUR TREHERN NORTON, F.R.C.S., Surgeon to St. Mary's Hospital. Second edition, illustrated, price 6s.

"Short, simple, and thoroughly practical instruction."—*Medical Times*.

Throat. Laryngoscopy and Rhinoscopy: in the Diagnosis and Treatment of Diseases of the Throat and Nose. With hand-coloured plates and woodcuts. By PROSSER JAMES, M.D., M.R.C.P. Fifth Edition. Price 6s. 6d.

Throat. Tonsillitis in Adolescents. By C. HAIG-BROWN, M.D., C.M., Medical Officer to the Charterhouse. Price 3s.

Transactions of Societies. Transactions of the Academy of Medicine in Ireland. Published annually. Edited by WILLIAM THOMSON, M.A., F.R.C.S., with numerous plates and woodcuts. Vols. I. to VI. (1883-8). Price 14s. each.

Transfusion. On Transfusion of Blood and Saline Fluids. By C. EGERTON JENNINGS, F.R.C.S.. Third edition, with Preface by SIR SPENCER WELLS, Bart., 4s. 6d.

Urine. The Urine; a Guide to its Practical Examination. By J. TYSON, M.D., Professor of Morbid Anatomy in the University, and President of the Pathological Society of Philadelphia. Fifth edition, with numerous illustrations, price 7s. 6d.

"We think it the most practically useful guide we have on the subject."—*Medical Record*.

Urinary Diseases. Diseases of the Bladder, Prostate Gland, and Urethra. By F. J. GANT, F.R.C.S., Senior Surgeon to the Royal Free Hospital. Fifth edition, enlarged. Price 12s. 6d.

Ventnor and the Undercliff. By J. M. WILLIAMSON, M.D. M.B. Edin., Hon. Surgeon to the National Hospital for Consumption. Second edition, price 1s.

Vichy. Vichy and its Therapeutical Resources. By PROSSER JAMES, M.D., M.R.C.P. Lond.; Lecturer on Materia Medica and Therapeutics at the London Hospital. Price 2s. 6d.

Voice. The Philosophy of Voice. Showing the right and wrong Action of the Breath and Vocal Cords in Speech and Song. By CHARLES LUNN. Sixth Edition. Price 3s.

Voice. Artistic Voice in Speech and Song. Dedicated to Mr. Sims Reeves and Mr. Santley. By the same Author. 1s.

Voice. The Voice Musically and Medically Considered. By C. ARMAND SEMPLE, M.B. Cantab., M.R.C.P. Lond., Physician to the Royal Society of Musicians. Part I. Musical, price 1s.; Part II., Medical, price 2s.; or in one vol., cloth, 3s. 6d.

War. A Romance of War; or, How the Cash Goes in Campaigning From the Evidence before the Committee of the House of Commons on the Egyptian Campaign. By CHARLES CAMERON, LL.D., M.P. Second Thousand. Price 1s.

Whooping-Cough. Its Pathology and Treatment. Fothergillian Prize Essay. By THOS. M. DOLAN, M.D., F.R.C.S.E. Price 3s. 6d.

Zoology and Comparative Anatomy, Aids to. By MAJOR GREENWOOD, M.D., Honours. Price 2s. 6d., and 2s.

Chimie Inorganique et Organique. Botanique Zoologie. Notes servant à la préparation de l'examen du premier doctorat. Recueillis et Publiés par LEWIS NICOLAS WORTHINGTON, Docteur en Médecine de la Faculté de Paris. Price 10s.

Thérapeutique Ligatures des Arteres. Tracheotomie et Laryngotomie. Notes servant à la préparation de l'examen du quatrième doctorat. Recueillis et Publiés par LEWIS NICOLAS WORTHINGTON, M.D. Paris, etc. Price 10s.

THE STUDENTS' AIDS SERIES.

Specially designed to assist Students in committing to memory and grouping the subjects upon which they are to be examined.

Aids to Analysis of Food and Drugs. By H. AUBREY HUSBAND, M.B., F.R.C.S. Price 1s. 6d. cloth ; 1s. paper.

Aids to Anatomy. By GEORGE BROWN, M.R.C.S., Gold Medalist, Charing Cross Hospital. Price 1s. 6d. cloth ; 1s. paper

Aids to Botany. By C. E. ARMAND SEMPLE, B.A., M.B. Cantab., M.R.C.P., Lond., late Senior Examiner in Arts at Apothecaries' Hall. Third Thousand. Price 2s. 6d. cloth ; 2s. paper wrapper.

Aids to Chemistry. By the same Author.

Part I.—Inorganic: Non-Metallic Substances. 2s. 6d. and 2s.

Part II.—Inorganic: The Metals. 2s. 6d. cloth ; 2s. paper.

Part III.—Organic. Price, cloth 2s. 6d.; paper 2s.

Part IV.—Tablets of Chemical Analysis. 1s. 6d., 1s.

Aids to Practical Chemistry. Especially arranged for the Analysis of Substances containing a Single Base and Acid Radicle. By T. HURD GORDON. Price 2s. 6d. cloth ; 2s. paper.

Aids to Dental Surgery. By ARTHUR S. UNDERWOOD, M.B., M.R.C.S., Lecturer on Dental Surgery at the Dental Hospital of London. Price 2s. 6d. cloth ; paper wrapper 2s.

Aids to Diagnosis. Part I.—Semeiological. By J. MILNER FOTHERGILL, M.D., M.R.C.P. Lond. Price 1s. 6d. cloth ; 1s. paper.

Part II.—Physical. By J. C. THOROWGOOD, M.D., F.R.C.P. Lond. Price 1s. 6d. cloth ; 1s. paper wrapper.

Part III.—What to Ask the Patient. By J. MILNER FOTHERGILL, M.D., M.R.C.P. Lond. Price 1s. 6d. cloth ; 1s. paper. The three in one vol., 3s. 6d.

"A mine of valuable information."—*Edinburgh Medical Journal*.

Aids to Examinations. Being Questions and Answers on Materia Medica, Medicine, Midwifery, Pathology, etc. By W. DOUGLAS HEMMING, F.R.C.S., and H. AUBREY HUSBAND, M.B., F.R.C.S. Third thousand. Price 1s. 6d. cloth ; and 1s. paper.

Aids to Forensic Medicine and Toxicology. By W. D. HEMMING, F.R.C.S.E., and H. AUBREY HUSBAND, M.B., F.R.C.S.E. Third Thousand. Price 2s. 6d. and 2s.

Aids to Gynæcology. By ALFRED GUBB, M.R.C.S., L.R.C.P., Obstetric Assistant and Gold Medalist, Westminster Hospital. Cloth, price 1s. 6d. ; paper wrapper, 1s.

Aids to Materia Medica and Therapeutics. By C. E. ARMAND SEMPLE, B.A., M.B. Cantab., M.R.C.P. Lond.

Part I.—The Non-Metallic and Metallic Elements, Alcoholic and Ethereal Preparations. 2s. 6d. cloth; and 2s. paper.

Part II.—Vegetable and Animal Substances, 2s. 6d. and 2s.

Part III.—Classification of Remedies, 1s. 6d. and 1s.

Part IV.—New Remedies. 2s. 6d. and 2s.

Part V.—Tablets of Materia Medica. Price 1s. 6d. and 1s.

Aids to Medicine. By the same Author.

Part I.—General Diseases. Lungs, Heart, and Liver. Price 2s. 6d. and 2s.

Part II.—The Urine, Kidneys, etc. 2s. 6d., 2s.

Part III.—The Brain and Nervous System. 2s. 6d. and 2s.

Part IV.—The Fevers, Skin Diseases, &c. Price 2s. 6d. and 2s.

Aids to Obstetrics. By SAMUEL NALL, B.A., M.B. Cantab., M.R.C.P. Lond., late House Physician and Resident Obstetric Assistant, St. Bartholomew's Hospital. Price 2s. 6d., 2s.

Aids to Ophthalmic Medicine and Surgery. By JONATHAN HUTCHINSON, jun., F.R.C.S. Cloth, 2s. 6d.; sewn, 2s.

Aids to Pathology. (*In preparation.*)

Aids to Pharmacy. By C. E. ARMAND SEMPLE, B.A., M.B., Cantab., M.R.C.P. London. Cloth, price 2s. 6d.; paper wrapper, 2s.

Aids to Physiology. By B. THOMPSON LOWNE, F.R.C.S., Examiner in Physiology, Royal College of Surgeons. Fourth thousand. In two parts price 2s. each, or in one vol., cloth, 4s. 6d.

"Certainly one of the best of the now popular Aids Series."—*Students' Journal*.

Aids to Practical Physiology. By J. BRINDLEY JAMES, M.R.C.S. Price 1s. 6d., cloth; 1s., paper.

Aids to Physiological Chemistry. By J. L. THUDICHUM, M.D., F.R.C.P. Lond., formerly Lecturer on Physiological Chemistry, St. Thomas's Hospital. Price 2s. 6d. and 2s.

Aids to Psychological Medicine. By L. S. FORBES WINSLOW, M.B., D.C.L. Oxon. Price 1s. 6d. and 1s.

Aids to Public Health. By J. L. THUDICHUM, M.D., F.R.C.P. Lond. Price 1s. 6d. cloth, 1s. paper.

Aids to Surgery. In two parts. By GEORGE BROWN, M.R.C.S. Price 1s. 6d. and 1s. each, or in one vol., 2s. 6d.

Aids to Rational Therapeutics. By J. MILNER FOTHERGILL, M.D., M.R.C.P. Lond. Price 2s. 6d. and 2s.

Replies to Questions in Therapeutics. By BRINDLEY JAMES, M.R.C.S. Price 1s. 6d. cloth, 1s. paper wrappers.

Aids to Zoology. By MAJOR GREENWOOD, M.D. Honours in Zoology, University of London. Price 2s. 6d., and 2s.

Aids to Analytical Geometry.

The Straight Line and Circle. By A. LE SUEUR, B.A. Cantab. Second Edition, price 2s.

The Conic Sections, with solutions of questions set at the London and other University Examinations. By GEORGE HEPPEL, M.A., St. John's College, Cambridge, Member of London Mathematical Society. Price 2s.

WORKS

ON

VETERINARY MEDICINE AND SURGERY.

Amateur. Horses: their Rational Treatment and the Causes of their Premature Decay. By AMATEUR. Price 5s.

——— An Abridgment of the above. By the same Author. Price 1s.

Banham. Tables of Veterinary Posology and Therapeutics. With Weights, Measures, etc. By GEORGE A. BANHAM, F.R.C.V.S. Price 2s. 6d.

Beacock. Prize Essay on the Breeding, Rearing, and Fattening of Cattle and Sheep, and proper treatment of Cows at time of Calving. By JOSEPH BEACOCK. Price 3d.

Burke. The Tropical Diseases of the Horse. By R. W. BURKE, M.R.C.V.S., A.V.D. Second Edition. Price 5s.

Burness—Mavor. The Specific Action of Drugs, an Index to their Therapeutic Value. By A. G. BURNES and F. MAVOR, President of the Central London Veterinary Society. Price 10s. 6d.

Courtenay. The Practice of Veterinary Medicine and Surgery. By E. COURTENAY. Price 10s. 6d.

“Written in a clear and concise style: will form a welcome addition to the library of the horse-owner, and those who take an interest in domesticated animals generally.”—*Mark Lane Express*.

Fearnley. A Text-Book on the Examination of Horses as to Soundness. Lectures delivered at the Royal Veterinary College, Edinburgh. By Professor FEARNLEY, with an Appendix on the Law of Horses and Warranty. Price 7s. 6d.

“Free from technical terms, and eminently fit for every horse dealer's or owner's library.”—*Illustrated Sporting News*.

Fleming. A Text-Book of Veterinary Obstetrics, including the diseases and accidents incidental to pregnancy, parturition and early age in the Domesticated Animals. By GEORGE FLEMING, LL.D., F.R.C.V.S., F.R.G.S., President of the Royal College of Veterinary Surgeons, Principal of the Army Veterinary Department. Profusely illustrated. Cloth, price 30s.

“Has filled up a void in a more satisfactory and complete way than any other member of his profession could have done.”—*The Field*.

“No man who makes any pretensions to veterinary science or stock breeding can dispense with this work.”—*Live Stock Journal*.

——— A Text-Book of Operative Veterinary Surgery. Part I., price 10s. 6d. Part II. (*In the Press*.)

Fleming. The Contagious Diseases of Animals: their influence on the wealth and health of the nation. Price 6d.

——— Animal Plagues; their History from the Earliest Times, Nature, and Prevention. Vol. I., to 1800, price 15s.

——— Vol. II., from A.D. 1800 to 1844. Price 12s.

——— Actinomykosis. An Infectious Disease of Animals and Mankind. Price 1s.

——— On Roaring in Horses (**Laryngismus Paralyticus**). Its History, Pathology and Treatment. With coloured plate and woodcuts. Price 6s.

——— Tuberculosis from a Sanitary and Pathological point of view. Price 1s.

——— Human and Animal Variolæ. A Study of Comparative Pathology. Price 1s.

——— Practical Horse Shoeing. With 37 illustrations. 2s.

——— The Influence of Heredity and Contagion on the Propagation of Tuberculosis. By G. FLEMING, F.R.C.V.S., HERR A. LYDTIN, and M. VAN HERTSEN. Price 6s.

Gresswell. A Manual of the Theory and Practice of Equine Medicine. By J. BRODIE GRESSWELL, M.R.C.V.S., and ALBERT GRESSWELL, M.R.C.S. Eng. Second edition enlarged. Price 10s. 6d.

BY THE SAME AUTHORS.

Equine Hospital Prescriber. Price 2s. 6d.

Bovine Prescriber. Price 2s. 6d.

Veterinary Pharmacopœia. Materia Medica and Therapeutics. Price 10s. 6d.

Diseases and Disorders of the Horse. A Treatise on Equine Medicine and Surgery. Price 5s.

Heatley. Practical Veterinary Remedies. A useful Handbook on Medicine. By G. S. HEATLEY, M.R.C.V.S. Price 3s. 6d.

Hill. Principles and Practice of Bovine Medicine and Surgery, with woodcuts and coloured plates. By J. WOODROFFE HILL, F.R.C.V.S. Price 36s.

Lambert. The Germ Theory of Disease, Concisely and Simply Explained. By JAMES LAMBERT, F.R.C.V.S., Army Veterinary Department. Price 1s.

Liautard. Animal Castration. By A. LIAUTARD, M.D., H.F.R.C.V.S. Price 7s. 6d.

——— Lameness of Horses and Diseases of the Locomotor Apparatus. Price 10s. 6d.

McBride. Anatomical Outlines of the Horse. By J. A. McBRIDE, Ph.D., M.R.C.V.S. Third edition. Illustrated. Price 8s. 6d.

Meyrick. Stable Management and the Prevention of Diseases among Horses in India. By J. J. MEYRICK, C.B., F.R.C.V.S., Principal Army Veterinary Surgeon in Egypt. Formerly Superintendent of Horse Breeding for the Punjab. 2s. 6d.

Poyser. The Stable Management of Troop Horses in India. "The Collinsian" Prize Essay. By R. POYSER, F.R.C.V.S. Price 2s.

Reynolds. The Breeding, Rearing, and Management of Draught Horses. By RICHARD REYNOLDS, M.R.C.V.S. Price 3s. 6d.

Robertson. A Handbook of the Practice of Equine Medicine. By WM. ROBERTSON, F.R.C.V.S., late Principal of the Royal Veterinary College, London. Second edition. Price 25s.

Smith. A Manual of Veterinary Hygiene. By FREDERICK SMITH, M.R.C.V.S., Army Medical Department, Lecturer on Veterinary Hygiene in the Army Medical School, Aldershot. Price 10s. 6d.

Veterinary Diagrams in Tabular Form. With coloured and plain engravings. Size of sheet $28\frac{1}{2}$ by 22 inches.

No. 1.—The External Form and Elementary Anatomy of the Horse. Price 3s. 6d., or mounted on roller and varnished, 6s. 6d.

No. 2.—The Age of Domestic Animals. Price 2s. 6d., or mounted on roller and varnished 5s. 6d.

No. 3.—The Unsoundnesses and Defects of the Horse. Price 2s. 6d., or mounted on roller and varnished, 5s. 6d.

No. 4.—The Shoeing of the Horse, Mule and Ox. Price 2s. 6d., or mounted on roller and varnished, 5s. 6d.

No. 5.—The Elementary Anatomy, Points and Butcher's Joints of the Ox. Price 3s. 6d., or mounted, 6s. 6d.

Price per set of Five, 12s. ; or mounted, 27s.

The Veterinary Journal and Annals of Comparative Pathology. Monthly, price 1s. 6d. Annual Subscription 18s., prepaid. (Foreign postage extra.)

The Veterinary Surgeon's Diary, Note and Dose Book, including also the Acts and Orders of Council relating to the Profession. Annual. Price 3s. 6d., leather, or 2s. 6d., cloth.

PERIODICAL PUBLICATIONS.

The Medical Press and Circular. Established 1838. Published every Wednesday in London, Dublin, and Edinburgh. Price 5d. ; £1 1s. per annum, post free, in advance.

The Hospital Gazette (and Students' Journal). A Weekly Review of Medicine, Surgery, and the Collateral Sciences. The only Paper that represents the whole body of Medical Students. Price 2d. ; 8s. per annum, prepaid.

Journal of the British Dental Association. A Monthly Review of Dental Surgery. Published on the 15th of each month. Price 6d., or 7s. per annum, post free.

Annals of Surgery. A Monthly Review of Surgical Science and Practice, published simultaneously in New York and London. Price 2s. monthly, or 21s. per annum, post free.

Agricultural Diary. By E. E. BENNETT.

The Australasian Medical Gazette. Monthly, 2s., or yearly post free, price 21s.

The Analyst. The Official Organ of "The Society of Public Analysts." Monthly, price 6d. ; 5s. per annum, paid in advance.

The Veterinary Journal, and Annals of Comparative Pathology. Monthly, price 1s. 6d. ; 18s. per annum, prepaid.

Quarterly Journal of the Postal Microscopical Society. Edited by Mr. ALFRED ALLEN. Price 1s. 6d.

Transactions of the Royal Academy of Medicine in Ireland. Annual volumes, 14s.

Foreign postage extra.

DIRECTORIES.

The Australian Medical Directory and Handbook, including New Zealand, Tasmania, etc. Price 15s.

The Official Register of the Royal College of Veterinary Surgeons ; published in accordance with the Act of Parliament. Price 2s. net.

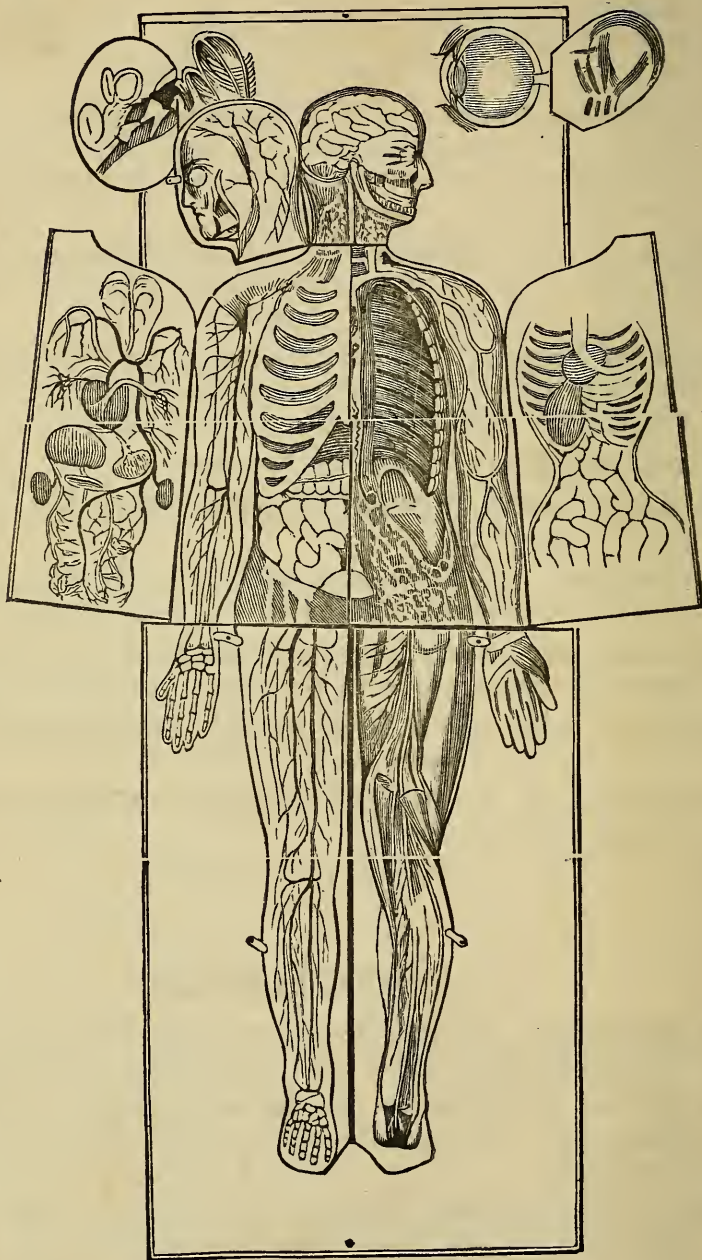
Commercial Directory for Spain, its Colonies and Dependencies. containing 500,000 Names and Addresses of the Commercial Houses, Public Officers, Offices, etc., etc. Annual, price 25s.

Veterinary Surgeons' Diary and Note-book. (Yearly.) Price 3s. 6d., leather ; 2s. 6d., cloth.

Baillière, Tindall, and Cox's

NEW PHYSIOLOGICAL MANIKIN.

Life size, Anatomy of the Internal Organs, and all Surgical Operations. Coloured to nature,
mounted on linen and varnished, in polished wood, folding-up case. Price £5 5s. net.



Manikin partially opened, showing a portion of the Interior Organs.

SOUTH PROPERTY

Se8

1890

RK501

Sewill

RK501

Se8
1890

COLUMBIA UNIVERSITY LIBRARIES (hsl.stx)

RK 501 Se8 1890 C.1

Dental surgery, including special anatom



2002387026

